



Original Article

# UGT1A1-related Bilirubin Encephalopathy/Kernicterus in Adults

Jie Bai<sup>1,2#</sup>, Lu Li<sup>1#</sup>, Hui Liu<sup>3</sup>, Shuang Liu<sup>2</sup>, Li Bai<sup>2</sup>, Wenyan Song<sup>4</sup>, Yu Chen<sup>1,2\*</sup> and Zhongping Duan<sup>1,2\*</sup>

<sup>1</sup>Fourth Department of Liver Disease (Difficult & Complicated Liver Diseases and Artificial Liver Center), Beijing You'an Hospital Affiliated to Capital Medical University, Beijing, China; <sup>2</sup>Beijing Municipal Key Laboratory of Liver Failure and Artificial Liver Treatment Research, Beijing, China; <sup>3</sup>Department of Pathology, Beijing You'an Hospital, Capital Medical University, Beijing, China; <sup>4</sup>Department of Radiology, Beijing You'an Hospital, Capital Medical University, Beijing, China

Received: 12 November 2020 | Revised: 15 January 2021 | Accepted: 4 February 2021 | Published: 11 March 2021

## Abstract

**Background and Aims:** Bilirubin encephalopathy/kernicterus is very rare in adults. This study is aimed to investigate the clinical manifestations and genetic features of two patients with *UGT1A1*-related kernicterus. **Methods:** Sanger sequencing analysis was performed to identify *UGT1A1* gene mutations in the patients and their families. Bioinformatics analysis was used to predict the potential functional effects of novel missense mutations. Clinical manifestations and biochemical parameters were collected and analyzed. **Results:** Two patients with Crigler-Najjar syndrome type II (CNS2) developed kernicterus in adulthood. Sanger sequencing identified a compound heterozygous mutation in the *UGT1A1* gene in patient 1, which was inherited from his mother (G71R) and his father (c.-3279T>G; S191F). Patient 2 carried three heterozygous mutations, namely G71R, R209W and M391K; among which, the M391K mutation has not been reported before. Multiple prediction software showed that the M391K mutation was pathogenic. Symptoms were relieved in the two patients after phenobarbital and artificial liver support treatment. Patient 1 also underwent liver transplantation. **Conclusions:** Adults with CNS2 are at risk for kernicterus. Phenobarbital treatment is beneficial for maintaining bilirubin levels and preventing kernicterus.

**Citation of this article:** Bai J, Li L, Liu H, Liu S, Bai L, Song W, et al. *UGT1A1*-related bilirubin encephalopathy/kernicterus in adults. *J Clin Transl Hepatol* 2021;9(2):180–186. doi: 10.14218/JCTH.2020.00108.

**Keywords:** Kernicterus; *UGT1A1*; Crigler-Najjar syndrome type II; Phenobarbital.

**Abbreviations:** ACLF, acute-on-chronic liver failure; ALT, alanine aminotransferase; AST, aspartate aminotransferase; BMR, bilirubin-albumin molar ratio; CNS2, Crigler-Najjar syndrome type II; CT, computed tomography; DPMAS, double plasma molecular adsorption system combined with plasma exchange; GS, Gilbert syndrome; Ig, immunoglobulin; TB, total bilirubin; UCB, unconjugated bilirubin; *UGT1A1*, uridine diphosphate glucuronosyl transferase 1A1.

#These authors contributed equally to this work.

\*Correspondence to: Sujun Zheng and Zhongping Duan, Fourth Department of Liver Disease (Difficult & Complicated Liver Diseases and Artificial Liver Center), Beijing You'an Hospital Affiliated to Capital Medical University, No. 8, Xitoutiao, You'anmen, Fengtai District, Beijing 100069, China. ORCID: <https://orcid.org/0000-0002-6367-5764> (SZ). Tel: +86-10-83997127, E-mail: zheng-sujun@ccmu.edu.cn (SZ); Tel: +86-10-63291007, E-mail: duan@ccmu.edu.cn (ZD)

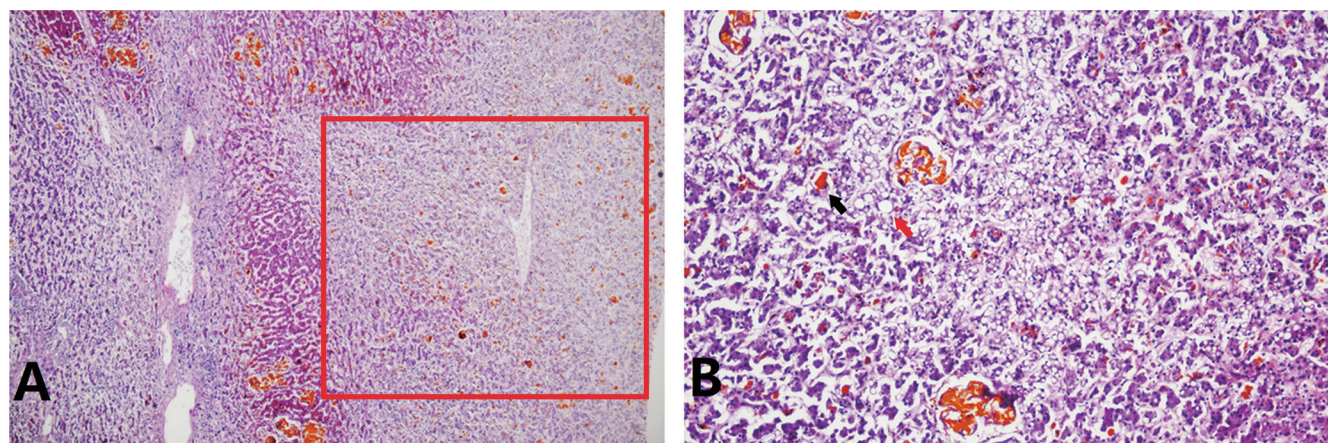
## Introduction

Bilirubin encephalopathy/kernicterus is an uncommon disabling neurologic disease caused by the toxicity of unconjugated bilirubin (UCB) to the basal ganglia and various brain stem nuclei.<sup>1</sup> Neonatal jaundice is quite common, affecting 60–80% of newborns, as a whole.<sup>2</sup> However, severe hyperbilirubinemia (>20 mg/dL), which may potentially lead to kernicterus and neurodevelopmental complications, is very rare, accounting for less than 2% of newborns.<sup>3</sup> The incidence of kernicterus is about 0.2 to 2.7 cases per 100,000 live births.<sup>1</sup> Common risk factors may include preterm delivery, hemolytic disease [glucose-6-phosphate dehydrogenase deficiency and ABO hemolysis], perinatal infection and exclusive breastfeeding.<sup>1,4</sup>

For adults, elevated UCB caused by hemolytic disease and inherited non-hemolytic unconjugated hyperbilirubinemia (bilirubin glucuronidation defects) is relatively common. Bilirubin glucuronidation is regulated by the uridine diphosphate glucuronosyl transferase 1A1 (*UGT1A1*) enzyme. It is encoded by the *UGT1A1* gene, which is located on chromosome 2 (2q37), and covers a promoter, enhancers, and five exons. According to the severity of *UGT1A1* enzyme deficiency, inherited unconjugated hyperbilirubinemia can be classified into Crigler-Najjar syndrome type I (CNS1), Crigler-Najjar syndrome type II (CNS2), and Gilbert syndrome (GS).<sup>5,6</sup> CNS1 is the most severe form, determined by a complete lack of bilirubin glucuronidation, and patients exhibit a toxic level of hyperbilirubinemia ( $\geq 340 \mu\text{mol/L}$ ) shortly after birth.<sup>7</sup>

CNS1 patients usually suffer from bilirubin encephalopathy, and are prone to death within the first 2 years of their lives.<sup>8,9</sup> At present, orthotopic liver transplantation is the only radical treatment.<sup>10,11</sup> CNS2 is characterized with not very high bilirubin (from 103 to  $<340 \mu\text{mol/L}$ )<sup>12</sup> and the bilirubin glucuronidation is less than 10% of normal level but not completely eliminated.<sup>13</sup> Although the phenotype of CNS2 is less severe, patients with CNS2 remain vulnerable to brain injury throughout life, especially in the setting of concurrent diseases, after injury, or during surgery.<sup>14</sup> Poddar et al.<sup>15</sup> reported a case of kernicterus in a CNS2 child due to a dramatic increase in UCB caused by hemolysis. GS is a mild hyperbilirubinemia (from normal level up to 80–100  $\mu\text{mol/L}$ ) that occurs in 5–10% of the population,<sup>12</sup> with approximately 70% reduction in bilirubin glucuronidation.<sup>16</sup> GS is considered as a benign condition without neurological damage and treatment requirement.

At present, there are few reports of kernicterus in adults.



**Fig. 1. Liver histopathology of patient 1 revealed massive and submassive necrosis, cholestasis and steatosis.** (A) Hematoxylin-eosin stain, 40 x. (B) Hematoxylin-eosin stain, 200 x. Massive and submassive necrosis, cholestasis and steatosis are indicated by the red box, and black and red arrows, respectively.

Here, we aimed to report two CNS2 adults with *UGT1A1* mutations who developed kernicterus.

## Methods

### Subjects and sample collection

The patients and all family members received careful clinical examinations and laboratory assessments by experienced physicians in Beijing You'an Hospital, Capital Medical University. Fasting blood samples were collected from all participants; clinical manifestations and biochemical parameters were collected and analyzed.

This study was approved by the Ethics Committee of Beijing You'an Hospital, Capital Medical University, and a written informed consent form was obtained from all participants.

### DNA extraction and screening for the mutations in *UGT1A1*

Genomic DNA was extracted from whole blood using a QIAamp DNA Blood Mini Kit (Qiagen, Hilden, Germany), according to the manufacturer's protocol. The promoter, all five exons, exon-intron boundaries, and a region in the distal promoter (the phenobarbital response enhancer module, PBREM) of *UGT1A1* were amplified by PCR technology, then purified through agarose gel electrophoresis and sequenced using a 3730XL sequencer (Applied Biosystems Inc., Foster City, CA, USA). Finally, Sanger sequencing data were compared and analyzed by SeqMan software (DNASTAR, Madison, WI, USA).

### Bioinformatics analyses

Potential functional effects of novel missense mutations were predicted by PolyPhen-2 (<http://genetics.bwh.harvard.edu/pph2/index.shtml>), SIFT (<http://sift.jcvi.org/>), PROVEAN (<http://provean.jcvi.org/index.php>), MutationTaster (<http://mutationtaster.org/>), FATHMM (<http://fathmm.biocompute.org.uk/>), InterVar (<http://wintervar.wglab.org/>), and MutPred2 (<http://mutpred.mutdb.org/>). The grade of conservation of the mutant nucleotides was determined by PhastCons and PhyloP.

## Results

### Patient 1

The patient was a 32-year-old man with a 30-year history of jaundice. In May 2020, he lost his appetite after drinking (about 500 mL beer, 20 g ethanol). He took Chinese medicine (unknown pharmaceutical ingredients) for a week, but the symptoms were not alleviated. Then, he developed dizziness, headache, and mild neuropsychological disorder. Liver function results were abnormal, with decreased albumin (23.8 g/L) and increased aspartate aminotransferase (commonly referred to as AST; 148U/L), alanine aminotransferase (commonly referred to as ALT; 54 U/L), total bilirubin (TB, 411.8  $\mu\text{mol/L}$ ), indirect bilirubin (266.3  $\mu\text{mol/L}$ ) and direct bilirubin (145.5  $\mu\text{mol/L}$ ). Blood routine test showed a high proportion of neutrophils (81.5%) and a decrease in hemoglobin (109 g/L). His prothrombin time activity was 42% and the Coombs test was negative. Blood ammonia (16  $\mu\text{g/dL}$ ), fasting plasma lipids, autoantibodies profile, anti-neutrophil cytoplasmic antibody, and immunoglobulins (Igs) including IgG, IgA, IgM, and IgE were normal. The viral hepatitis markers were negative. Computed tomography (referred to as CT) and magnetic resonance imaging showed hepatosplenomegaly (Supplementary Fig. 1). Brain CT scans were normal (Supplementary Fig. 1). The patient was diagnosed with acute-on-chronic liver failure (ACLF), CNS2 and kernicterus, and received oral phenobarbital, albumin infusion, and anti-infection therapy.

One week after admission, the patient suddenly manifested hematemesis and showed restlessness, then lost consciousness. TB, indirect bilirubin, and blood ammonia levels increased to 532.3  $\mu\text{mol/L}$ , 379.1  $\mu\text{mol/L}$ , and 123  $\mu\text{g/dL}$ , respectively. Gastroscopy revealed cardiac mucosal laceration syndrome (Mallory-Weiss syndrome). The patient was treated with hemostasis, sedation, intramuscular injection of phenobarbital, and artificial liver support treatment of double plasma molecular adsorption system combined with plasma exchange (DPMAS) and plasma exchange. Later, the patient's consciousness gradually recovered and he underwent liver transplantation. Histopathology of the removed liver showed massive and submassive hepatocyte necrosis, cholestasis, and steatosis (Fig. 1). The patient is now in a relatively stable state. Table 1 and Fig. 2 show his blood test results.

Sanger sequencing of the *UGT1A1* gene identified a compound heterozygous mutation in this patient, which was in-

**Table 1. Biochemical characteristics of patient 1**

Characteristics	Reference	Days after admission											
		1	3	8 <sup>a</sup>	13 <sup>b</sup>	15 <sup>c</sup>	16 <sup>c</sup>	17 <sup>c</sup>	18	24	25 <sup>c</sup>	26	
TB ( $\mu\text{mol/L}$ )	5–21	411.8	513.6	532.3	616.4	570.3	353.8	453.3	417.8	524	561.5	378.5	
IB ( $\mu\text{mol/L}$ )	<7	266.3	370.6	379.1	450.1	427.7	274.9	374.3	352.7	428.6	490.4	330.4	
DB ( $\mu\text{mol/L}$ )	–	145.5	143	153.2	166.3	142.6	78.9	79	65.1	95.4	71.1	48.1	
ALB (g/L)	40–55	23.8	27.8	27.4	39.4	35.9	35.7	46.2	43.3	41.3	42.2	43.2	
BAMR	–	1.1	1.2	1.3	1.0	1.0	0.7	0.6	0.6	0.8	0.9	0.6	
ALT (U/L)	9–50	54	60	62	64	130	81	79	75	108	93	75	
AST (U/L)	15–40	148	152	147	164	366	207	206	184	207	191	150	
GGT (U/L)	10–60		114		99								
ALP (U/L)	45–125		474		412								
TBA ( $\mu\text{mol/L}$ )	<10		175.3		122.8								
WBC ( $\times 10^9/\text{L}$ )	3.5–9.5	6.68	5.54	8.26	7.47	7.02	7.2	6.87	4.21	6.25	4.08	7.69	
N%	40–75	81.5	71.1	80.1	83.2	75.8	72.8	72.7	83.4	75.9	71.6	90.1	
HGB (g/L)	130–175	109	112	105	80	82	78	85	80	65	62	68	
PLT ( $\times 10^9/\text{L}$ )	125–350	145	138	128	85	87	81	90	89	85	70	75	
Amon ( $\mu\text{g/dL}$ )	19–54	16	25	123	79	20	8	25	48	59			

<sup>a</sup>The patient's neuropsychiatric symptoms deteriorated after hematemesis.

<sup>b</sup>The patient underwent plasma exchange.

<sup>c</sup>The patient underwent DPMAS and plasma exchange.

Abbreviations: %N, proportion of neutrophils; ALB, albumin; ALP, alkaline phosphatase; Amon, blood ammonia; BAMR, Bilirubin-albumin molar ratio; DB, direct bilirubin; GGT,  $\gamma$ -glutamyl transferase; HGB, hemoglobin; IB, indirect bilirubin; PLT, platelets; TBA, total serum bile acid; WBC, white blood cell.

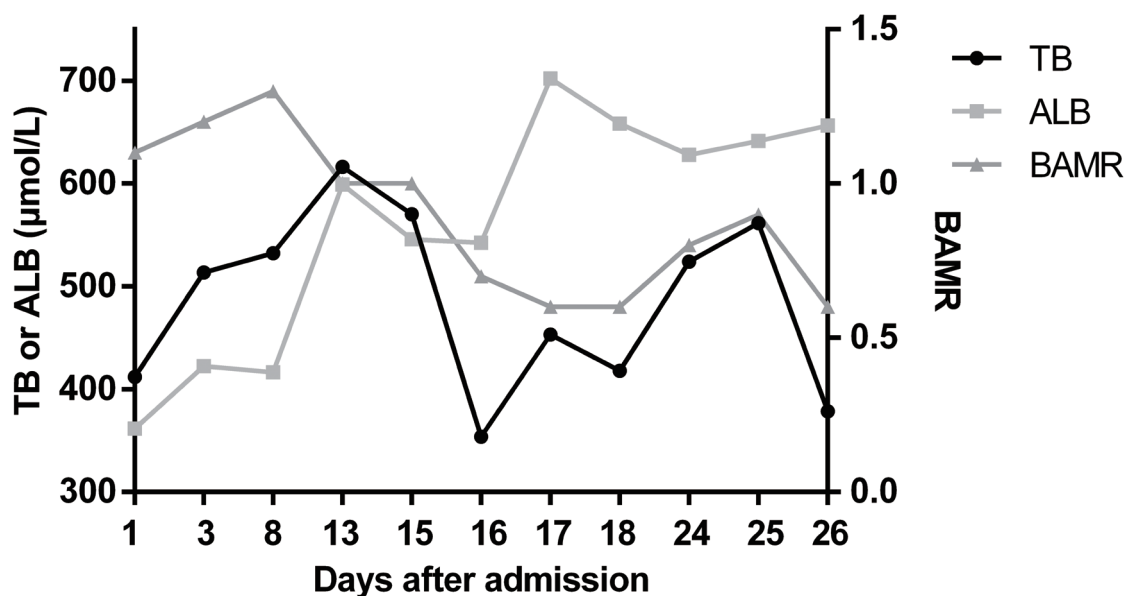
herited from his mother (c.211G>A, p.G71R) and his father (c.-3279T>G; c.572C>T, p.S191F) (Fig. 3 and Supplementary Fig. 2).

Interestingly, the patient's elder sister also showed jaundice since childhood. Her TB was about 400  $\mu\text{mol/L}$ . She was diagnosed with CNS2 but had never developed kernicterus. In addition, the patient's father had mild unconjugated hyperbilirubinemia (TB of 32.1  $\mu\text{mol/L}$ , indirect bilirubin of 23.2  $\mu\text{mol/L}$ ) and was diagnosed with GS. They were both also found to carry the same compound heterozygous mutation as the patient (Fig. 3).

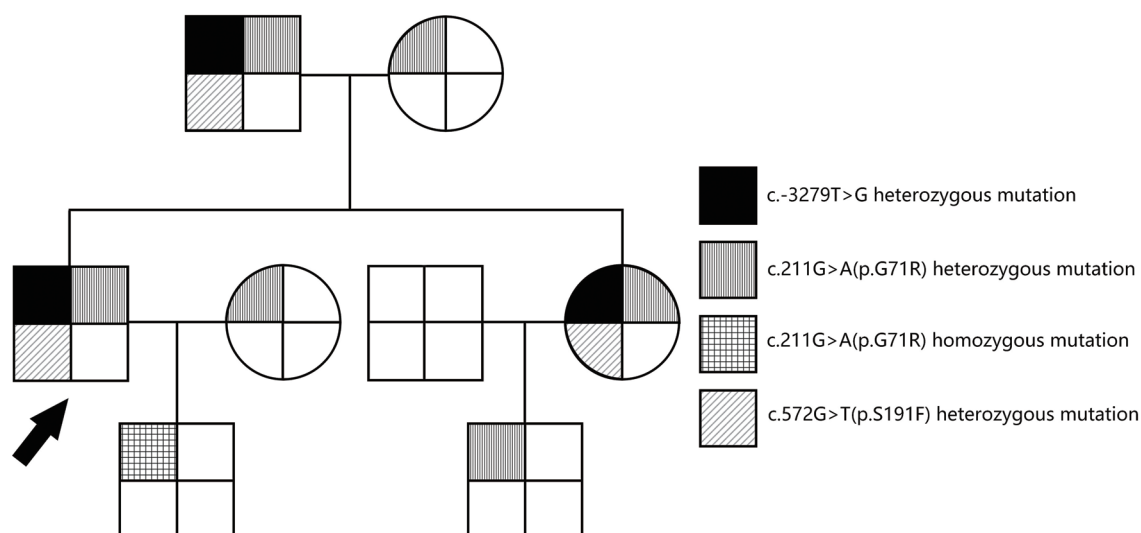
bin of 23.2  $\mu\text{mol/L}$ ) and was diagnosed with GS. They were both also found to carry the same compound heterozygous mutation as the patient (Fig. 3).

### Patient 2

The patient was a 35-year-old man. He had been suffer-



**Fig. 2. BAMR in patient 1 after admission.**



**Fig. 3. Family pedigree of patient 1.** The arrow indicates patient 1.

ing from jaundice since birth, with TB ranging from 70–80  $\mu\text{mol/L}$ . In adulthood, his TB levels were about 300  $\mu\text{mol/L}$ . At the age of 31, he developed right upper abdominal pain and severe jaundice. His TB level had been found to have increased to above 500  $\mu\text{mol/L}$ . The patient was diagnosed with gallbladder stones, cholecystitis and CNS2. After treatment with antibiotics and oral phenobarbital, the patient's pain was relieved and TB was reduced to 300  $\mu\text{mol/L}$ . Later, the patient experienced repeated abdominal pain, fever, and severe jaundice. In November 2019, he became lethargic and unresponsive after a fever. Then, he developed limb convulsions and urinary incontinence. The patient was admitted on November 15, 2019.

The results of liver function showed decreased albumin (21.5 g/L) and increased AST (222 U/L), ALT (57 U/L), TB (417.4  $\mu\text{mol/L}$ ), and direct bilirubin (195  $\mu\text{mol/L}$ ). The proportion of neutrophils (88.1%) and blood ammonia (112  $\mu\text{g/dL}$ ) were elevated. The Coombs test was negative. The fasting plasma lipids, autoantibodies profile, and anti-neutrophil cytoplasmic antibody were normal. Cerebrospinal fluid results did not suggest central nervous system infection. Abdominal ultrasonography showed gallstones, cholecystitis, and splenomegaly. Brain CT scans were normal.

Sanger sequencing of the *UGT1A1* gene identified three heterozygous mutations, namely G71R (c.211G>A), R209W (c. 625C>T), and M391K (c.1172T>A) (Supplementary Fig. 3). The M391K mutation has not been reported before. Seven software programs were used to predict the pathogenicity of the mutation. As shown in Supplementary Table 1, all software programs showed that the M391K mutation was pathogenic or damaging. The PhastCons score of the mutation was 1, and the corresponding PhyloP value was 2.307, suggesting the high conservation of this amino acid.

The patient was treated with antibiotics, sedation, intramuscular injection of phenobarbital, and artificial liver support treatment with DPMAS and plasma exchange. The patient's neurological status gradually returned to normal. Table 2 and Fig. 4 show the results of his blood investigations.

## Discussion

High concentrations of UCB can cause nervous system damage, known as bilirubin encephalopathy or kernicterus. In

general, kernicterus is found in infants and young children, especially those who are premature and/or have hemolysis.<sup>1,17</sup> On one hand, the blood-brain barrier of newborns and children is immature. On the other hand, the albumin/bilirubin-binding capacity and tissue-binding capacity vary significantly among newborns, and these values are particularly low for premature babies.<sup>18</sup> Kernicterus in adults is a rare condition. To date, there are only two published cases.<sup>19,20</sup> In one case, the disorder was associated with liver failure.<sup>19</sup> The other case was an adult with CNS2, who developed kernicterus after laparoscopic surgery.<sup>20</sup> This report describes two new cases of adult kernicterus associated with *UGT1A1* mutations (CNS2).

CNS2 is usually caused by missense mutations in the *UGT1A1* gene, which reduces enzyme activity but does not eliminate it.<sup>21,22</sup> Most patients with CNS2 have homozygous missense mutations or compound heterozygous mutations.<sup>23</sup> This explains the milder phenotype and inducibility of the residual enzyme activity by phenobarbital administration. Variants c.211G>A (p.G71R) and c.1456T>G (p.Y486D) are the most frequently reported mutation sites in Asian CNS2 patients.<sup>24–26</sup> In our patients, *UGT1A1* sequencing analysis was performed. Patient 1 is a compound heterozygote with mutations c.-3279T>G, G71R, and S191F. His father and sister share the same *UGT1A1* genotype as him, and were diagnosed with GS and CNS2, respectively. But none of them suffered from kernicterus. The above evidence suggests that the same genotype may result in different phenotypes and clinical manifestations. A possible explanation is that a multifactorial etiology including hormonal, environmental, and genetic factors contributes to the development of inherited diseases. Besides, liver histology suggested massive and submassive hepatocytes necrosis and cholestasis, consistent with ACLF and CNS2, respectively.<sup>27,28</sup> Histopathology also showed steatosis, but the related mechanism is not clear. Before the onset of ACLF, Patient 1 drank about 20 g ethanol (500 mL beer) and then took traditional Chinese medicine for 1 week. Considering the relatively small intake of ethanol and the complex composition of Chinese medicine (although the composition is unknown), we speculated that Chinese medicine was the main cause of his acute liver injury, and eventually lead to his ACLF on the basis of Crigler-Najjar syndrome.

Patient 2 is heterozygous for the mutations G71R, R209W and M391K. The mutations G71R, S191F, and R209W are

Table 2. Biochemical characteristics of patient 2

Characteristics	Reference	Days after admission							
		1	4	5 <sup>a</sup>	7 <sup>b</sup>	8 <sup>b</sup>	9	12 <sup>b</sup>	13
TB (μmol/L)	5–21	417.4	527.7	547.3	448.9	432.5	342.1	486.2	257.1
IB (μmol/L)	<7	222.4	320	360	322.8	322.9	260.4	361.8	217.5
DB (μmol/L)	–	195	207.7	187.3	126.1	109.6	81.7	124.4	39.6
ALB (g/L)	40–55	21.5	31.7	32.8	32.1	35	29.6	33.4	26.7
BAMR	–	1.3	1.1	1.1	0.9	0.8	0.8	1.0	0.6
ALT (U/L)	9–50	57	58	59	58	63	71	88	63
AST (U/L)	15–40	222	249	233	171	160	171	191	169
GGT (U/L)	10–60		78	76	73	74		112	
ALP (U/L)	45–125		513	460	327	282		334	
TBA (μmol/L)	<10		159.1	148.9	137.4	136.6		133.8	
WBC (×10 <sup>9</sup> /L)	3.5–9.5	12.77	5.56	6.22	8.35	9.46	6.24	10.6	
N%	40–75	88.1	76.6	79.9	79.8	84.7	79	86.7	
HGB (g/L)	130–175	116	108	105	102	102	93	93	
PLT (×10 <sup>9</sup> /L)	125–350	237	161	176	176	188	156	173	
Amon (μg/dL)	19–54	41	107	116	81	74	108	75	89

<sup>a</sup>The patient underwent DPMAS and plasma exchange.

<sup>b</sup>The patient underwent plasma exchange.

Abbreviations: %N, proportion of neutrophils; ALB, albumin; ALP, alkaline phosphatase; Amon, blood ammonia; BAMR, Bilirubin-albumin molar ratio; DB, direct bilirubin; GGT, γ-glutamyl transferase; HGB, hemoglobin; IB, indirect bilirubin; PLT, platelets; TBA, total serum bile acid; WBC, white blood cell.

located in exon 1 of the *UGT1A1* gene, and have been shown to be associated with CNS2 (moderate hyperbilirubinemia).<sup>29</sup> The mutation c.-3279T>G is located in the phenobarbital response enhancer module, which is related to GS (mild hyperbilirubinemia).<sup>30</sup> The M391K mutation has not been reported yet. All prediction software indicated that the mutation is pathogenic. PhastCons and PhyloP showed a high degree of amino acid conservation, suggesting that the mutation has a great impact on amino acids and the

protein. According to the variant classification criteria of the American College of Medical Genetics and Genomics and the Association for Molecular Pathology,<sup>31</sup> the novel M391K mutation is pathogenic to CNS2 in this patient. The effect on the *UGT1A1* enzyme's activity needs to be further verified through cell experimentation. In summary, the mutation site, number, and genotype of *UGT1A1* are related to bilirubin level.

The pathogenesis of kernicterus has not been fully elu-

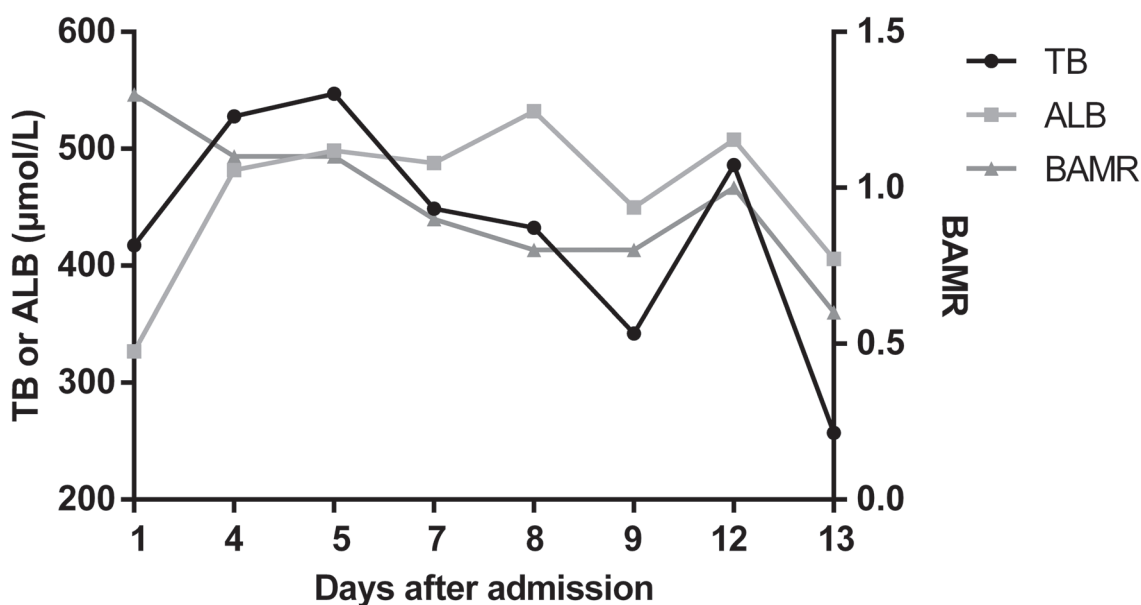
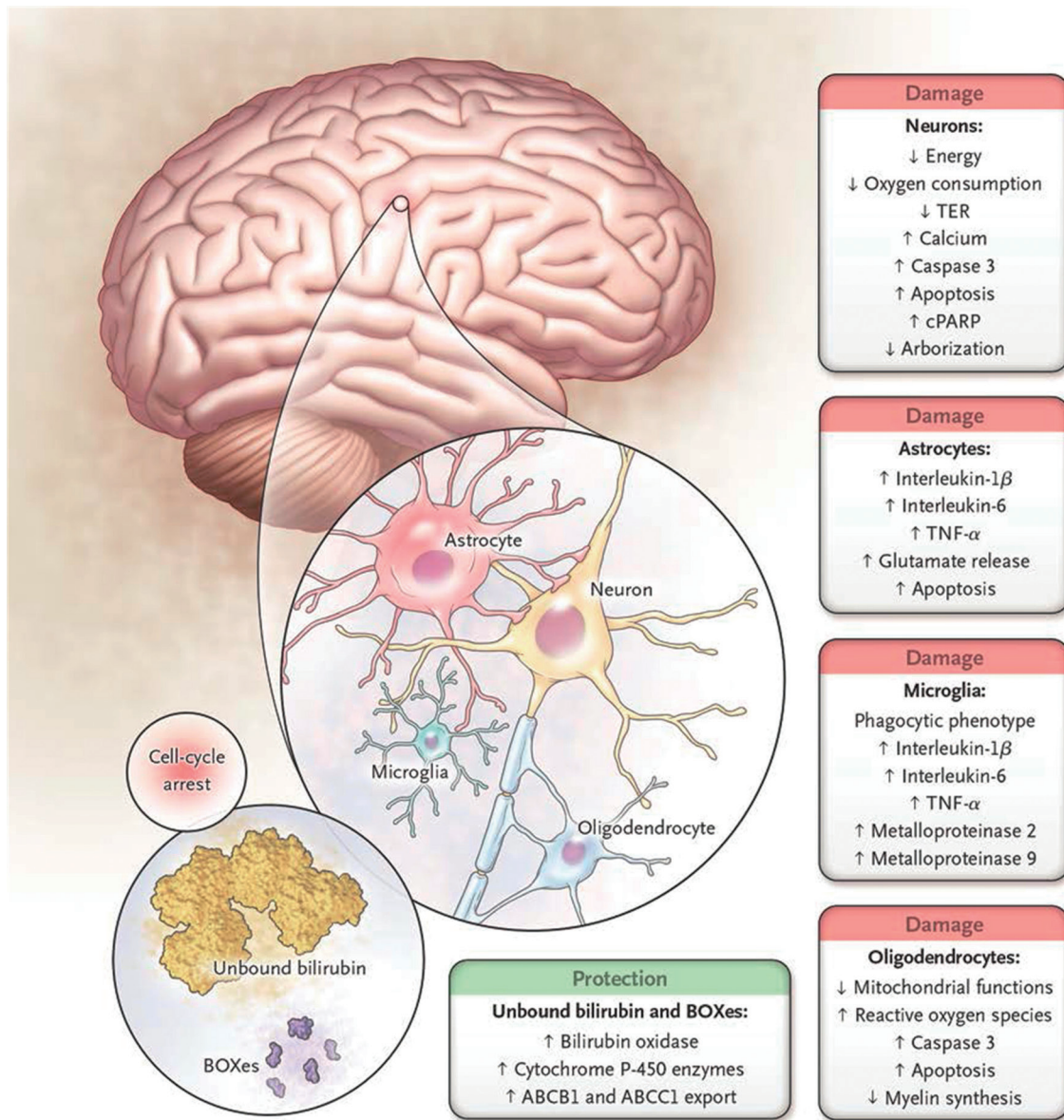


Fig. 4. BAMR in patient 2 after admission.



**Fig. 5. Cell types and metabolic processes affected by bilirubin in the central nervous system.** The main effects of bilirubin on neurons are decreased oxygen consumption and increased release of calcium and caspase 3, resulting in apoptosis. There is also decreased dendritic and axonal arborization. A similar pattern is observed in oligodendrocytes with increased apoptosis, impairment of the redox state (oxidative stress), and reduced synthesis of myelin. Microglia react to toxic injury associated with bilirubin by increased release of proinflammatory cytokines and metalloproteinase activity as cells manifest a phagocytic phenotype. A similar proinflammatory pattern is observed in astrocytes, with enhanced release of glutamate and apoptosis. At the same time, cells may reduce the intracellular concentration of bilirubin either by extruding the pigment through the ATP-binding cassette transporters or by increasing the formation of the less toxic products through bilirubin oxidation products (BOXes) and/or cytochrome P-450 enzymes (1a1 and 1a2, in particular). These responses are protective, whereas all others result in cell damage; this suggests that once the intracellular concentration of bilirubin exceeds a toxic threshold (still to be defined), the polymorphic metabolic cascade leading to neurotoxicity ensues. (From Watchko JF, Tiribelli C. Bilirubin-induced neurologic damage-mechanism and management approaches. *N Engl J Med* 2013; 369: 2025). Abbreviations: cPARP, cleaved poly (adenosine diphosphate-ribose) polymerase; TER, transcellular resistance.

cidated but the main reason is excessive bilirubin production (i.e. hemolysis) and/or insufficient liver glucuronidation, leading to higher levels of free unbound bilirubin. The potential mechanism of UCB neurotoxicity is shown in Fig. 5.<sup>18</sup> In our two patients, CNS2 reduced bilirubin glucuronidation. Infection, fever and liver injury cause a decrease in serum albumin levels. Therefore, free unbound bilirubin increased. In infants, a bilirubin-albumin molar ratio (referred to as BAMR) value >0.8 is considered dangerous because bilirubin/albumin binding is unpredictable at these levels.<sup>17</sup>

However, for adults, the BAMR value predicting kernicterus is still unclear. In our two patients, bilirubin concentrations increased to 616  $\mu\text{mol/L}$  and 547  $\mu\text{mol/L}$ , respectively, with BAMR value >0.8 in both. Then, kernicterus occurred. Therefore, for patients with CNS2, it is important to avoid particularly high bilirubin levels and maintain normal serum albumin levels.

Infection, liver damage, and hemolytic disease should also be avoided. It should be noted that CNS2 patients respond to phenobarbital. To prevent severe hyperbilirubine-

mia and kernicterus, phenobarbital therapy should be adhered to. If the patient develops kernicterus, treatments that eliminate the cause, or those such as albumin supplementation and artificial liver support treatment, are effective. Due to severe necrosis and insufficient regeneration of hepatocytes in patient 1, the bilirubin level still slightly fluctuated in the case of artificial liver support treatment. At the same time, although the patient recovered consciousness after albumin supplementation and artificial liver support treatment, increased bilirubin due to CNS2 may lead to recurrence of kernicterus. At present, liver transplantation is the only treatment option that completely replaces UGT1A1 function and normalizes serum bilirubin levels.

In conclusion, although very rare, adults with CNS2 are at risk of kernicterus. Phenobarbital administration helps maintain bilirubin levels and prevent kernicterus.

## Funding

This study was supported by Beijing Municipal Science and Technology Project (No. Z171100002217070), National Key R&D Program of China (No. 2017YFA0103000), National Science and Technology Key Project on "Major Infectious Diseases such as HIV/AIDS, Viral Hepatitis Prevention and Treatment" (Nos. 2012ZX10002004-006, 2017ZX10203201-005, 2017ZX10201201, 2017ZX10202203-006-001 and 2017ZX10302201-004-002), "Beijing Municipal Administration of Hospitals" Ascent Plan (No. DFL20151601), Beijing Municipal Administration of Hospitals Clinical Medicine Development of Special Funding Support (Nos. ZYLX201806 and ZYLX202125), Digestive Medical Coordinated Development Center of Beijing Municipal Administration of Hospitals (No. XXZ0503), You An Fund for Liver Diseases and AIDS (No. YNKTT201801189), Beijing Municipal Natural Science Foundation (No. 7202068).

## Conflict of interest

The authors have no conflict of interests related to this publication.

## Author contributions

Conception and design (JB, LL, SZ, ZD), patient recruitment (JB, LL), data collection (HL, SL, LB, WS), data analysis (JB, LL, HL, WS), writing the draft (JB, LL), revising and polishing the manuscript (JB, LL, YC, SZ, ZD). All authors read and approved the final manuscript.

## References

- [1] Olusanya BO, Kaplan M, Hansen TWR. Neonatal hyperbilirubinaemia: a global perspective. *Lancet Child Adolesc Health* 2018;2:610–620. doi:10.1016/S2352-4642(18)30139-1.
- [2] Olusanya BO, Ogunlesi TA, Slusher TM. Why is kernicterus still a major cause of death and disability in low-income and middle-income countries? *Arch Dis Child* 2014;99:1117–1121. doi:10.1136/archdischild-2013-305506.
- [3] Muchowski KE. Evaluation and treatment of neonatal hyperbilirubinemia. *Am Fam Physician* 2014;89:873–878.
- [4] Okolie F, South-Paul JE, Watchko JF. Combating the hidden health disparity of kernicterus in black infants: A review. *JAMA Pediatr* 2020;174(12):1199–1205. doi:10.1001/jamapediatrics.2020.1767.
- [5] Lin JP, Cupples LA, Wilson PW, Heard-Costa N, O'Donnell CJ. Evidence for a gene influencing serum bilirubin on chromosome 2q telomere: a genome-wide scan in the Framingham study. *Am J Hum Genet* 2003;72:1029–1034. doi:10.1086/373964.

- [6] Strassburg CP. Hyperbilirubinemia syndromes (Gilbert-Meulengracht, Crigler-Najjar, Dubin-Johnson, and Rotor syndrome). *Best Pract Res Clin Gastroenterol* 2010;24:555–571. doi:10.1016/j.bpg.2010.07.007.
- [7] Ebrahimi A, Rahim F. Crigler-Najjar syndrome: Current perspectives and the application of clinical genetics. *Endocr Metab Immune Disord Drug Targets* 2018;18:201–211. doi:10.2174/1871530318666171213153130.
- [8] Crigler JF Jr, Najjar VA. Congenital familial nonhemolytic jaundice with kernicterus. *Pediatrics* 1952;10:169–180.
- [9] Crigler JF Jr, Najjar VA. Congenital familial nonhemolytic jaundice with kernicterus; a new clinical entity. *AMA Am J Dis Child* 1952;83:259–260.
- [10] van Dijk R, Beuers U, Bosma PJ. Gene replacement therapy for genetic hepatocellular jaundice. *Clin Rev Allergy Immunol* 2015;48:243–253. doi:10.1007/s12016-014-8454-7.
- [11] Fagioli S, Daina E, D'Antiga L, Colledan M, Remuzzi G. Monogenic diseases that can be cured by liver transplantation. *J Hepatol* 2013;59:595–612. doi:10.1016/j.jhep.2013.04.004.
- [12] Wagner KH, Shiels RG, Lang CA, Seyed Khoei N, Bulmer AC. Diagnostic criteria and contributors to Gilbert's syndrome. *Crit Rev Clin Lab Sci* 2018;55:129–139. doi:10.1080/10408363.2018.1428526.
- [13] Erlinger S, Arias IM, Dhumeaux D. Inherited disorders of bilirubin transport and conjugation: new insights into molecular mechanisms and consequences. *Gastroenterology* 2014;146:1625–1638. doi:10.1053/j.gastro.2014.03.047.
- [14] Strauss KA, Robinson DL, Vreman HJ, Puffenberger EG, Hart G, Morton DH. Management of hyperbilirubinemia and prevention of kernicterus in 20 patients with Crigler-Najjar disease. *Eur J Pediatr* 2006;165:306–319. doi:10.1007/s00431-005-0055-2.
- [15] Poddar B, Bharti B, Goraya J, Parmar VR. Kernicterus in a child with Crigler-Najjar Syndrome Type II. *Trop Gastroenterol* 2002;23:33–34.
- [16] Bosma PJ, Chowdhury JR, Bakker C, Gantla S, de Boer A, Oostra BA, *et al*. The genetic basis of the reduced expression of bilirubin UDP-glucuronosyltransferase 1 in Gilbert's syndrome. *N Engl J Med* 1995;333:1171–1175. doi:10.1056/NEJM199511023331802.
- [17] Wallenstein MB, Bhutani VK. Jaundice and kernicterus in the moderately preterm infant. *Clin Perinatol* 2013;40:679–688. doi:10.1016/j.clp.2013.07.007.
- [18] Watchko JF, Tiribelli C. Bilirubin-induced neurologic damage—mechanisms and management approaches. *N Engl J Med* 2013;369:2021–2030. doi:10.1056/NEJMra1308124.
- [19] Waser M, Kleihues P, Frick P. Kernicterus in an adult. *Ann Neurol* 1986;19:595–598. doi:10.1002/ana.410190614.
- [20] Chalasani N, Chowdhury NR, Chowdhury JR, Boyer TD. Kernicterus in an adult who is heterozygous for Crigler-Najjar syndrome and homozygous for Gilbert-type genetic defect. *Gastroenterology* 1997;112:2099–2103. doi:10.1053/gast.1997.v112.pm9178703.
- [21] Clarke DJ, Moghrabi N, Monaghan G, Cassidy A, Boxer M, Hume R, *et al*. Genetic defects of the UDP-glucuronosyltransferase-1 (UGT1) gene that cause familial non-hemolytic unconjugated hyperbilirubinaemias. *Clin Chim Acta* 1997;266:63–74. doi:10.1016/S0009-8981(97)00167-8.
- [22] Kadakol A, Ghosh SS, Sappal BS, Sharma G, Chowdhury JR, Chowdhury NR. Genetic lesions of bilirubin uridine-diphosphoglucuronate glucuronosyltransferase (UGT1A1) causing Crigler-Najjar and Gilbert syndromes: correlation of genotype to phenotype. *Hum Mutat* 2000;16:297–306.
- [23] Servadio V, d'Apolito M, Maiorano N, Minuti B, Torricelli F, Ronchi F, *et al*. Spectrum of UGT1A1 mutations in Crigler-Najjar (CN) syndrome patients: identification of twelve novel alleles and genotype-phenotype correlation. *Hum Mutat* 2005;25:325. doi:10.1002/humu.9322.
- [24] Zheng B, Hu G, Yu J, Liu Z. Crigler-Najjar syndrome type II in a Chinese boy resulting from three mutations in the bilirubin uridine 5'-diphosphate-glucuronosyltransferase (UGT1A1) gene and a family genetic analysis. *BMC Pediatr* 2014;14:267. doi:10.1186/1471-2431-14-267.
- [25] Yanagi T, Nakahara S, Maruo Y. Bilirubin uridine diphosphate-glucuronosyltransferase polymorphism as a risk factor for prolonged hyperbilirubinemia in Japanese preterm infants. *J Pediatr* 2017;190:159–162.e1. doi:10.1016/j.jpeds.2017.07.014.
- [26] Maruo Y, Nakahara S, Yanagi T, Nomura A, Mimura Y, Matsui K, *et al*. Genotype of UGT1A1 and phenotype correlation between Crigler-Najjar syndrome type II and Gilbert syndrome. *J Gastroenterol Hepatol* 2016;31:403–408. doi:10.1111/jgh.13071.
- [27] Fata CR, Gillis LA, Pacheco MC. Liver fibrosis associated with crigler-najjar syndrome in a compound heterozygote: A case report. *Pediatr Dev Pathol* 2017;20:522–525. doi:10.1177/1093526617697059.
- [28] Sarin SK, Choudhury A, Sharma MK, Maiwall R, Al Mahtab M, Rahman S, *et al*. Acute-on-chronic liver failure: consensus recommendations of the Asian Pacific association for the study of the liver (APASL): an update. *Hepatol Int* 2019;13:353–390. doi:10.1007/s12072-019-09946-3.
- [29] Sneitz N, Bakker CT, de Knecht RJ, Halley DJ, Finel M, Bosma PJ. Crigler-Najjar syndrome in The Netherlands: identification of four novel UGT1A1 alleles, genotype-phenotype correlation, and functional analysis of 10 missense mutants. *Hum Mutat* 2010;31:52–59. doi:10.1002/humu.21133.
- [30] Bai J, Luo L, Liu S, Liang C, Bai L, Chen Y, *et al*. Combined effects of *UGT1A1* and *SLCO1B1* variants on Chinese adult mild unconjugated hyperbilirubinemia. *Front Genet* 2019;10:1073. doi:10.3389/fgene.2019.01073.
- [31] Richards S, Aziz N, Bale S, Bick D, Das S, Gastier-Foster J, *et al*. Standards and guidelines for the interpretation of sequence variants: a joint consensus recommendation of the American College of Medical Genetics and Genomics and the Association for Molecular Pathology. *Genet Med* 2015;17:405–424. doi:10.1038/gim.2015.30.