

# Laparoendoscopic Single-Site (LESS) Pyeloplasty for Horseshoe Ureteropelvic Junction Obstruction

Stephen Faddegon, MD, Yung K. Tan, MD, Ephrem O. Olweny, MD, Samuel K. Park, BS,  
Sara L. Best, MD, Jeffrey A. Cadeddu, MD

## ABSTRACT

**Background and Objective:** Pyeloplasty in horseshoe kidneys can be challenging due to aberrant vasculature, renal malrotation, and ectopic location. Fewer than 20 cases of minimally invasive (MIS) pyeloplasty in horseshoe kidneys have been reported in the literature to date. We herein report the first 2 cases of laparoendoscopic single-site (LESS) pyeloplasty for UPJ obstruction in horseshoe kidneys.

**Methods:** Two patients with symptomatic ureteropelvic junction obstruction in horseshoe kidneys were treated with an Anderson-Hynes LESS pyeloplasty. This was performed using three 5-mm trocars through a single umbilical incision, plus an accessory 3-mm port at the anterior axillary line to facilitate suturing and subsequent drain placement.

**Results:** Both patients had BMI <23. The operative times were 204 minutes and 171 minutes. Blood loss was negligible, and no intraoperative complications occurred. To date, 9-month renography for patient 1 demonstrates stable renal function and unobstructed drainage. After stent removal, patient 2 was asymptomatic.

**Conclusion:** In experienced hands, LESS reconstructive techniques are applicable to complex renal anomalies. LESS pyeloplasty for UPJ obstruction associated with horseshoe kidneys is feasible, safe, and effective in select patients.

**Key Words:** LESS, Ureteropelvic junction obstruction, pyeloplasty, Horseshoe kidney.

## INTRODUCTION

Since first being introduced in 1993, minimally invasive pyeloplasty has become a well-established treatment for ureteropelvic junction obstruction (UPJO).<sup>1</sup> However, to date, only a limited number of reports have been published on the application of laparoscopic pyeloplasty for the treatment of UPJO associated with horseshoe kidneys. The first dismembered laparoscopic pyeloplasty in a horseshoe kidney was reported in 1996.<sup>2</sup> Since then, fewer than 20 cases have been reported in the literature. Explanations for these low numbers might include the relative rarity of horseshoe UPJO, but also a perceived increase in surgical difficulty due to unfamiliar and variable anatomy. This renal fusion anomaly is characterized by renal malrotation, variable blood supply, and high insertion of the ureters with an incidence of ureteropelvic junction obstruction in up to one-third of cases.<sup>3,4</sup> Despite these anatomic challenges, the principles of surgery remain the same regardless of the approach. The new evolution in MIS pyeloplasty is the LESS technique with over 90 cases reported to date.<sup>5-12</sup> With appropriate preoperative imaging to delineate the anatomy, LESS techniques have been applied successfully to urologic reconstructive techniques.<sup>8</sup> To our knowledge, these are the first 2 reported cases demonstrating the feasibility of LESS pyeloplasty in horseshoe kidneys.

## CASE REPORT ONE

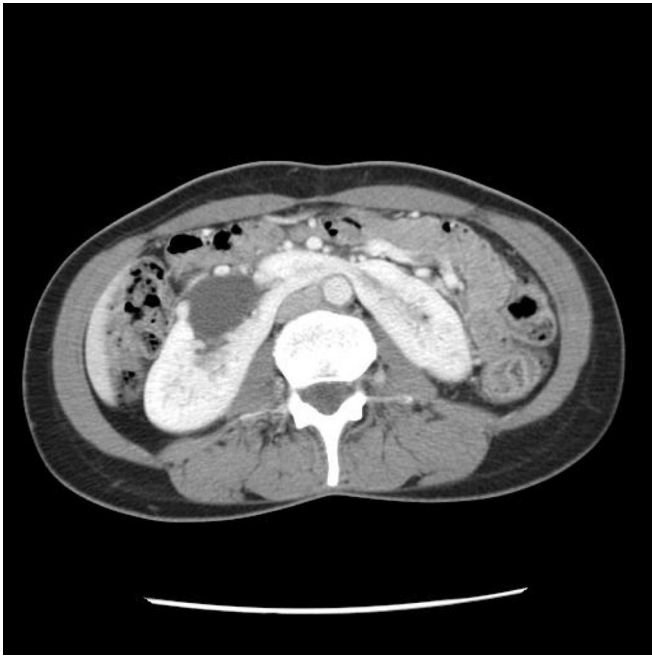A 44-year-old Caucasian female was referred for episodes of severe intermittent right flank pain and lower abdominal pain that would last several hours. There was no history of complicating stones or infections. She had no prior abdominal surgery and her BMI was 19.1. A CT scan (**Figure 1**) and IVP (**Figure 2**) demonstrated an extrarenal dilated pelvis with delayed excretion. On a MAG-3 renogram the differential function of the affected side was preserved (52%), but drainage t1/2 was 45 minutes, consistent with obstruction. Surgical options were discussed, and the patient elected single-incision laparoscopic pyeloplasty.

Department of Urology, University of Texas Southwestern Medical Center, Dallas, Texas, USA (all authors).

Address correspondence to: Jeffrey A. Cadeddu, MD, Professor of Urology and Radiology, Department of Urology, University of Texas Southwestern Medical Center, 5323 Harry Hines Blvd., J8.106, Dallas, TX 75390, USA. Telephone: (214) 648-6856, Fax: (214) 648-8786, E-mail: Jeffrey.Cadeddu@UTSouthwestern.edu

DOI: 10.4293/108680812X13291597716500

© 2012 by JSLS, *Journal of the Society of Laparoendoscopic Surgeons*. Published by the Society of Laparoendoscopic Surgeons, Inc.



**Figure 1.** CT scan of horseshoe kidney and right ureteropelvic junction obstruction (Case 1).

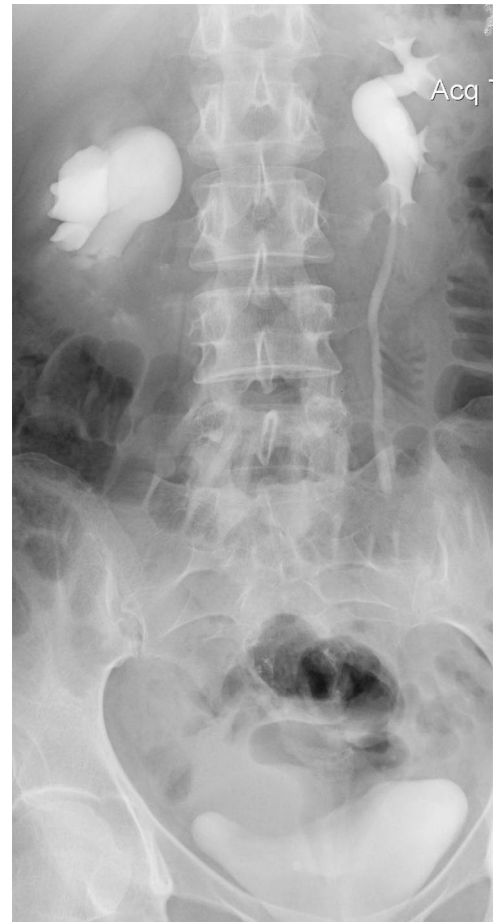## CASE REPORT TWO

A 24-year-old Hispanic female with a BMI of 22.5 presented with a 1-year history of intermittent left flank pain. A CT scan demonstrated left pelviectasis, but a renogram was not diagnostic of obstruction with a differential function of 60% for the left side. Nevertheless, persistent debilitating pain prompted placement of a nephrostomy tube which resulted in immediate symptom resolution. A subsequent nephrostogram demonstrated minimal drainage, and the patient was offered surgical treatment.

## METHODS

The patient is positioned in a modified flank fashion, and a 2.5-cm incision is made within the umbilical dimple to conceal the scar. After insufflation of the abdomen, three 5-mm trocars are placed through the anterior abdominal fascia in a triangular configuration. A 5-mm 45-degree laparoscope is used along with articulating laparoscopic instruments. The laparoscope is placed through the most medial trocar and positioned anteriorly in the abdomen so that the camera looks down onto the surgical field. The working instruments are placed through the 2 lateral trocars (**Figure 3**).

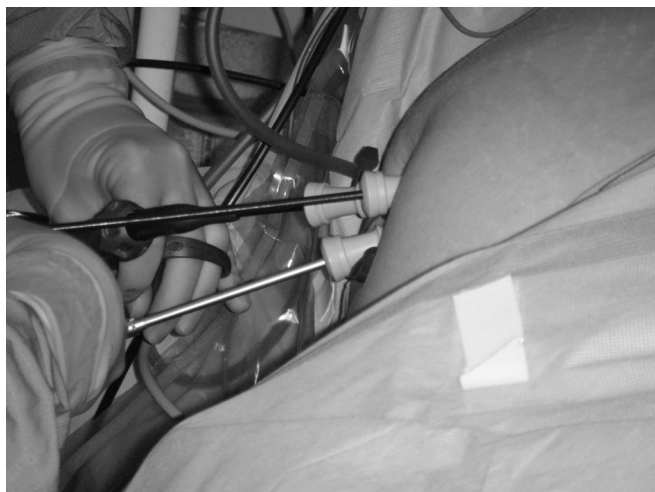
The colon is reflected medially and Gerota's fascia opened longitudinally to expose the renal pelvis and ureter in the



**Figure 2.** IVP of right ureteropelvic junction obstruction in horseshoe kidney. No contrast excretion is visualized beyond the right UPJ (Case 1).

usual fashion. In Case 1, the gonadal vessels were clearly seen crossing anterior to the ureter at the site of obstruction. A high insertion of the ureter was also noted. In Case 2, an anterior crossing vessel compressed the ureter against the isthmus. In both cases, the renal pelvis, UPJ, and ureter were fully mobilized posterior to the crossing vessels, care being taken not to grasp the crossing vessels directly.

After excision of the UPJO segment and spatulation of the ureter and renal pelvis, a PTFE-coated wire is passed down the ureter through an umbilical trocar under direct vision and exchanged for a superstiff wire via a 5-Fr angiographic catheter. A 6-Fr JJ ureteral stent is passed antegrade over the wire. The running anastomosis is completed with 3-0 vicryl by using rigid needle drivers, one through the umbilical site, and a second through a 3-mm trocar at the mid axillary line. Since a



**Figure 3.** LESS port configuration at the umbilicus for horseshoe pyeloplasty. With the patient in lateral decubitus, the 30 degree angled 5 mm camera is placed through the most medial port and looks down onto the surgical field. The REAL articulating LESS working instruments are placed through the two laterally placed ports. The working instruments cross each other within the abdomen and below the camera to maximize the working space.

retroperitoneal 10-Fr closed-suction drain is placed at the conclusion of the case, the required stab incision is utilized at this stage to facilitate suturing with the trocar later exchanged for the drain. In Case 1, a 3-mm subxyphoid instrument was required for retraction and exposure of the renal pelvis. The suture line is reinforced with fibrin glue. The 10-Fr closed-suction drain is positioned next to the anastomosis and externalized through the lateral trocar. The ureteral stent is removed after 4 weeks, and a follow-up renogram is obtained 3 months postoperatively.

## RESULTS

Both patients underwent uncomplicated horseshoe LESS pyeloplasty with operative times of 171 and 204 minutes, respectively. During each case, a crossing vessel was identified necessitating ureteral transposition. The umbilical port-site skin incisions were each 2.5cm in length. There was minimal blood loss, and both patients were discharged home on postoperative days 3 and 4, respectively, after uneventful hospitalizations. After 9 months of follow-up, Patient 1 remained asymptomatic, and renography showed a t1/2 of 11 minutes compared to a preoperative t1/2 of 45 minutes. Patient 2 was asymptomatic after stent removal but moved shortly thereafter and was lost to follow-up.

## DISCUSSION

LESS has been reported for a variety of procedures including pyeloplasty in heterotypic kidneys, nephrectomy, and adrenalectomy.<sup>9</sup> As reflected in the cases presented, optimal candidates for LESS pyeloplasty include those with a low BMI, no prior abdominal surgery, primary UPJ etiology, large extrarenal pelvis, and finally, a desire for superior cosmesis.

Although there is a learning curve between standard laparoscopic and LESS pyeloplasty,<sup>5</sup> we would expect surgeons with LESS pyeloplasty experience to be equipped to operate on horseshoe kidneys. In fact, the lower anatomical position of horseshoe kidneys brings the pelvis closer to the umbilical port site and helps facilitate LESS pyeloplasty. On the other hand, unfamiliar and variable anatomy can be intimidating. In one postmortem study of 6 horseshoe kidneys, the authors differentiated 3 groups of arteries. Besides the main renal vessels and accessory vessels entering the hilum, aberrant vessels entering directly into the poles of the kidney and isthmus were noted.<sup>13</sup> This latter group of vessels is of particular relevance to pyeloplasty cases in horseshoe kidneys. To avoid unnecessary bleeding and renal compromise, preoperative CT scan or MRI is essential for proper delineation of the renal vasculature.

The few cohort studies available comparing standard laparoscopic to LESS pyeloplasty have demonstrated similar perioperative outcomes including operative time, blood loss, perioperative complications, length of stay, and analgesic requirements.<sup>9</sup> Success rates, both clinical and radiologic, also appear to be equivalent in experienced hands.<sup>9,14</sup> The primary advantage of LESS pyeloplasty is thus aesthetic, which we have found to be most important to younger females like the 2 patients presented here.

Given the finite benefits of LESS pyeloplasty, it is imperative to avoid complications such as urine leak or excessive bleeding. In case 1, an accessory 3-mm xiphoid port was placed to facilitate renal pelvis retraction during suturing. Although usually not required, it was helpful in this case due to a large floppy pelvis that impaired visualization of the suture line. We believe that under no circumstances should patient outcomes be compromised to avoid a small accessory incision.

Robotic-LESS pyeloplasty is proving to be a valuable technique and will likely supplant conventional-LESS in the future due to a reduced learning curve for both dissection and suturing. Furthermore, robotic articulation negates the need of an accessory lateral port, because suturing can

be accomplished with relative ease through the single incision.<sup>15</sup>

## CONCLUSION

These first reported cases of LESS pyeloplasty in horseshoe kidneys demonstrate that the procedure is both safe and efficacious, though it should only be undertaken by highly experienced surgeons. A 3-mm accessory port facilitates suturing with rigid drivers. Advancements in robotic single-incision techniques may present an additional opportunity for treatment of horseshoe UPJO via advanced minimally invasive approaches.

## References:

1. Schuessler WW, Grune MT, Tecuanhuey LV, Preminger GM. Laparoscopic dismembered pyeloplasty. *J Urol*. 1993;150:1795–1799.
2. Janetschek G, Peschel R, Altarac S, Bartsch G. Laparoscopic and retroperitoneoscopic repair of ureteropelvic junction obstruction. *Urology*. 1996;47:311–316.
3. Jabbour ME, Goldfischer ER, Stravodimos KG, Klima WJ, Smith AD. Endopyelotomy for horseshoe and ectopic kidneys. *J Urol*. 1998;160:694–697.
4. Lallas CD, Pak RW, Pagnani C, et al. The minimally invasive management of ureteropelvic junction obstruction in horseshoe kidneys. *World J Urol*. 2011;29:91–95.
5. Best SL, Donnally C, Mir SA, Tracy CR, Raman JD, Cadeddu JA. Complications during the initial experience with laparoendoscopic single-site pyeloplasty. *BJU Int*. 2011;108:1326–1329.
6. Caione P, Lais A, Nappo SG. One-port retroperitoneoscopic assisted pyeloplasty versus open dismembered pyeloplasty in young children: preliminary experience. *J Urol*. 2010;184:2109–2115.
7. Choi KH, Ham WS, Rha KH, et al. Laparoendoscopic single-site surgeries: A single-center experience of 171 consecutive cases. *Korean J Urol*. 2011;52:31–38.
8. Kaouk JH, Autorino R, Kim FJ, et al. Laparoendoscopic single-site surgery in urology: worldwide multi-institutional analysis of 1076 cases. *Eur Urol*. 2011;60:998–1005.
9. Stein RJ, Berger AK, Brandina R, et al. Laparoendoscopic single-site pyeloplasty: A comparison with the standard laparoscopic technique. *BJU Int*. 2011;107:811–815.
10. Tugcu V, Ilbey YO, Polat H, Tasci AI. Early experience with laparoendoscopic single-site pyeloplasty in children. *J Pediatr Urol*. 2011;7:187–191.
11. Tugcu V, Sonmezay E, Ilbey YO, Polat H, Tasci AI. Transperitoneal laparoendoscopic single-site pyeloplasty: Initial experiences. *J Endourol*. 2010;24:2023–2027.
12. White WM, Haber GP, Goel RK, Crouzet S, Stein RJ, Kaouk JH. Single-port urological surgery: Single-center experience with the first 100 cases. *Urology*. 2009;74:801–804.
13. Janetschek G, Kunzel KH. Percutaneous nephrolithotomy in horseshoe kidneys. Applied anatomy and clinical experience. *Br J Urol*. 1988;62:117–122.
14. Tracy CR, Raman JD, Bagrodia A, Cadeddu JA. Perioperative outcomes in patients undergoing conventional laparoscopic versus laparoendoscopic single-site pyeloplasty. *Urology*. 2009;74:1029–1034.
15. Olweny EO, Park SK, Tan YK, Gurbuz C, Cadeddu JA, Best SL. Perioperative comparison of robotic assisted laparoendoscopic single-site (less) pyeloplasty versus conventional less pyeloplasty. *Eur Urol*. 2011;61:410–414.