

# Utility of Intraoperative Fetal Heart Rate Monitoring for Cerebral Arteriovenous Malformation Surgery during Pregnancy

Kenji FUKUDA,<sup>1,2</sup> Jun MASUOKA,<sup>1</sup> Shigeki TAKADA,<sup>1</sup> Shinji KATSURAGI,<sup>3</sup>  
Tomoaki IKEDA,<sup>3</sup> and Koji IIHARA<sup>1</sup>

*Departments of <sup>1</sup>Neurosurgery and <sup>3</sup>Perinatology and Gynecology,  
National Cerebral and Cardiovascular Center, Suita, Osaka;*

*<sup>2</sup>Department of Neurosurgery, Faculty of Medicine, Fukuoka University, Fukuoka, Fukuoka*

## Abstract

We report two methods of intraoperative fetal heart rate (FHR) monitoring in cases of cerebral arteriovenous malformation surgery during pregnancy. In one case in her third trimester, cardiotocography was used. In another case in her second trimester, ultrasound sonography was used, with a transesophageal echo probe attached to her lower abdomen. Especially, the transesophageal echo probe was useful because of the advantages of being flexible and easy to attach to the mother's lower abdomen comparing with the usual doppler ultrasound probe. In both cases, the surgery was successfully performed and FHR was monitored safely and stably. The use of intraoperative FHR monitoring provides information about the influence of induced maternal hypotension and unexpected bleeding on fetus during surgery. These monitoring techniques would be especially emphasized in cerebrovascular surgery for the safe management of both mother and fetus.

Key words: arteriovenous malformation, pregnancy, fetal heart rate monitoring

## Introduction

Intracranial hemorrhage due to rupture of a cerebral arteriovenous malformation (AVM) during pregnancy, although rare, is associated with significant maternal and fetal mortality and morbidity.<sup>1)</sup> Several studies have reported an increased rebleeding rate during the course of pregnancy and it is considered desirable to remove the AVM, if possible.<sup>2,3)</sup> While performing surgery for AVM during pregnancy, monitoring the fetal heart rate (FHR) is important to avoid uterine and placental hypoperfusion and fetal asphyxia. Although many cases of neurosurgery during pregnancy have been reported, the reference of intraoperative FHR monitoring was in few reports of brain tumor.<sup>4,5)</sup> So, we describe the role of intraoperative FHR monitoring in two cases of maternal AVM surgery at different stages of pregnancy, and additionally in cerebrovascular surgery.

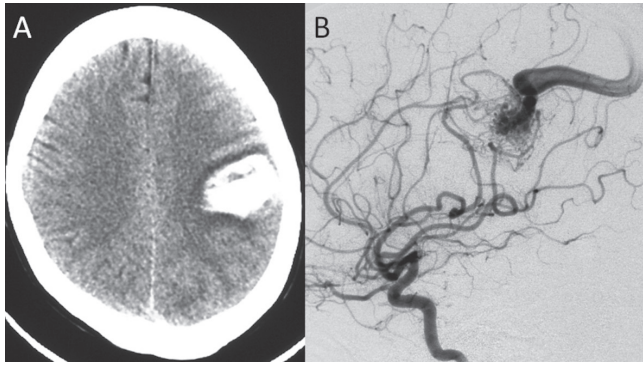
## Illustrative Cases

### I. Case 1

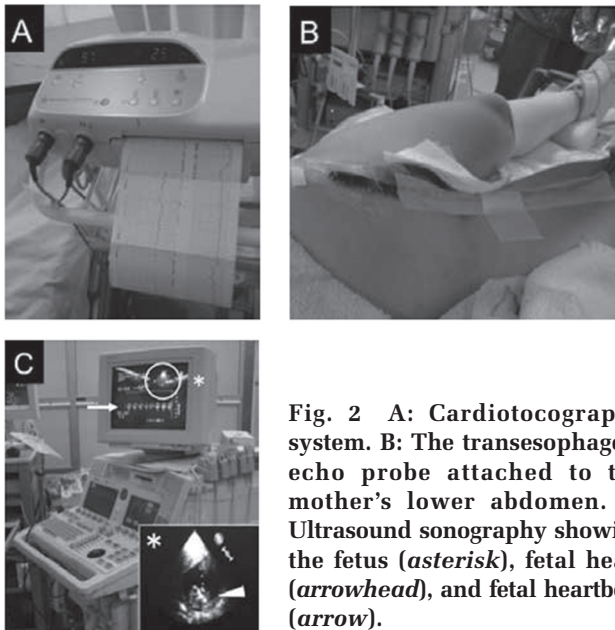
A healthy 27-year-old woman (gravida 1, para 1)

presented with sudden right hemiparesis and sensory aphasia at 25th week of gestation. Computed tomography (CT) and magnetic resonance imaging (MRI) revealed an intracerebral hemorrhage in the left parietal lobe (Fig. 1A). Given the mild neurological symptoms, emergency removal of the hematoma was not indicated. Obstetrically, there was no indication for pregnancy termination. At 27th week of gestation, cerebral angiography revealed a left parietal AVM of Spetzler and Martin grade 2 (Fig. 1B). AVM removal was judged necessary on a neurosurgical indication to avoid the risk of rebleeding during pregnancy. As the fetus was not mature enough for extra-uterine life, we performed AVM removal at 30 weeks of gestation with the patient's consent. The patient was operated on under general anesthesia in the supine position with her abdomen slightly turned to left for the prevention of supine hypotensive syndrome. Anesthesia was induced with rocuronium 50 mg i.v., propofol 100 mg i.v., fentanyl 0.2 mg i.v., and maintained with propofol 1–4 mg/kg/h, remifentanyl 0.15–0.30  $\mu$ g/kg/min, and 0.5–1.2% sevoflurane in oxygen. During the operation, the fetal status was monitored using cardiotocography (CTG) (Fig. 2A). The obstetrics team was prepared for an emergency cesarean section

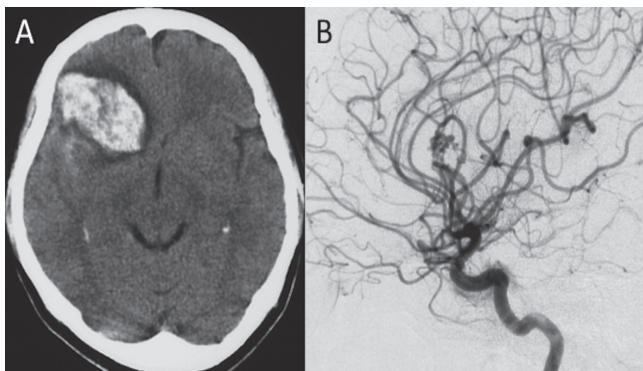
Received November 27, 2013; Accepted January 13, 2014



**Fig. 1** Case 1: A: Computed tomography scan showing a left parietal intraparenchymal hematoma. B: Digital subtraction angiogram showing a grade 2 left parietal arteriovenous malformation.



**Fig. 2** A: Cardiotocography system. B: The transesophageal echo probe attached to the mother's lower abdomen. C: Ultrasound sonography showing the fetus (asterisk), fetal heart (arrowhead), and fetal heartbeat (arrow).



**Fig. 3** Case 2: A: Computed tomography scan showing a right frontal intraparenchymal hematoma. B: Digital subtraction angiogram showing a grade 1 right frontal arteriovenous malformation.

in the same operating room. The patient's systolic blood pressure (SBP) was maintained between 90 and 100 mmHg during surgery, and the lowest SBP was 82 mmHg during the resection of the nidus by deliberate depression of maternal blood pressure. Her uterine contraction was restrained by anesthetic agents. The FHR remained between 130 and 140 beat per minute (bpm) and FHR variability decreased less than 6 bpm throughout the operation. The FHR decreased between 5 and 10 bpm under general anesthesia compared to pre-operative value. The surgery was completed without any problems. The amount of blood loss was 560 ml. The patient showed a slight right sensory disturbance, but the symptom improved rapidly. The remaining course of the pregnancy was favorable, and the patient successfully delivered via spontaneous vaginal delivery with epidural anesthesia in the 40th week of gestation.

## II. Case 2

A 34-year-old woman (gravida 1, para 1) was admitted to our hospital in the 16th week of gestation because of sudden left hemiparesis. CT and MRI revealed an intracerebral hemorrhage in the right frontal lobe. Cerebral angiography showed a right frontal AVM of Spetzler and Martin grade 1 on the same day (Fig. 3A, B). The mother wished to continue the pregnancy and consented to the AVM resection. The surgery was performed in the 18th week of gestation. General anesthesia was induced with rocuronium 50 mg i.v., thiopental 250 mg i.v., fentanyl 0.2 mg i.v., and maintained with remifentanyl 0.20–0.25  $\mu\text{g}/\text{kg}/\text{min}$ , and 1.0–1.5% sevoflurane in oxygen. During the procedure, FHR was directly monitored using ultrasonography, with a transesophageal echo probe attached to the mother's lower abdomen (Fig. 2B, C). The patient's SBP was maintained between 90 to 100 mmHg during surgery, and the lowest SBP was 84 mmHg during the resection of the nidus. Her oxygenation level was good and no fetal bradycardia occurred during surgery. The FHR remained between 150 and 160 bpm throughout the perioperative period. The surgery was completed without any problems. The amount of blood loss was only 200 ml. The mother complained of no new abnormal neurological symptom. The remaining course of the pregnancy was favorable, and a cesarean section was performed in the 40th week of pregnancy because of macrosomia and a history of cesarean section.

## Discussion

The prevalence of AVM is estimated at 0.01–0.50%

of the population.<sup>6,7)</sup> AVM is generally present in patients aged between 20 years and 40 years, and especially in those over 30 years, which is a childbearing age for women. AVM rupture during pregnancy is associated with maternal mortality of 28% and fetal mortality of 14%.<sup>1)</sup> The implication of pregnancy in AVM rupture is controversial, but the bleeding rate appears to increase up to three-fold.<sup>1-3,8)</sup> Although the rebleeding rate during the first year in the natural course of a ruptured AVM varied from 6% to 15.8%, the frequency of rebleeding during the same pregnancy could be as high as 27%.<sup>3,9)</sup> Moreover, in a recent report by Gross and Du, the annual hemorrhage rate during pregnancy was 10.8%, the hemorrhage rate per pregnancy was 8.1%, and the hazard ratio for intracerebral hemorrhage during pregnancy was 7.91.<sup>10)</sup> In view of these very high rates, cases of AVM in pregnant women should be treated with great care.

Here, we described the role of intraoperative FHR monitoring in two cases of elective surgery for AVM presenting with intracerebral hemorrhage at different stages of pregnancy. Although radical treatment for ruptured AVM tended to be performed after delivery in many case reports and case series, early surgical intervention for patients with an immature fetus before delivery would lead to improved maternal and fetal prognosis if the surgical risk is low.<sup>3,11-13)</sup> The indication of surgery for AVM is determined primarily by the Spetzler-Martin grading scale.<sup>14,15)</sup> The removal of AVM was supposed to be completed safely in our cases because the AVM grade was low. However, one of the anxieties for neurosurgeon is about fetal well-being during perioperative period. Although many cases of neurosurgery during pregnancy have been reported, the reference of intraoperative FHR monitoring was in few reports of brain tumor.<sup>4,5)</sup> FHR monitoring is important for the assessment of reassuring fetal status in the antepartum as well as intrapartum stage.<sup>16-18)</sup> Several reports have recommended continuous intraoperative FHR monitoring if non-obstetric surgery is performed after the 16th week of pregnancy.<sup>19-22)</sup> Prolonged deceleration or bradycardia caused by maternal hypoperfusion, maternal hypoxia, compression of the umbilical cord, or the depression of the fetal cardiovascular system by anesthetic agents reflects a decreased uterine and placental circulation that can result in fetal asphyxia, acidosis, and death.<sup>4,19)</sup> Loss of FHR variability does not always indicate fetal distress under general anesthesia because it may occur by the effect of anesthetic agents on the fetal autonomic nervous system.<sup>19,23)</sup> Unexpected intraoperative bleeding or induced maternal hypotension would lead to the risk of mother and fetus

during cerebrovascular surgery, especially in the timing as resection of AVM or clipping of cerebral aneurysm.<sup>24,25)</sup> A mean arterial pressure of < 70 mmHg or a reduction in systolic arterial pressure of 25-30% is sufficient to reduce utero-placental blood flow.<sup>23)</sup> We can adjust the maternal blood pressure, maternal oxygenation, and anesthetic agents as soon as possible if FHR abnormality occurs. Nevertheless, cesarean section is required unless the fetal distress improves. Our indication for emergency cesarean section is the incidence of prolonged deceleration or bradycardia with < 80 bpm for 2 minutes, based on the framework by Parer and Ikeda.<sup>16)</sup> This value is correlated with the lower limit thresholds of pH 7.1 and base excess of -12 mEq/L in umbilical arterial blood, which indicates the fetal hypoxic damage. In these circumstances, FHR monitoring can be especially valuable for cerebrovascular surgery.

In the third trimester, CTG is widely used to monitor the FHR for fetal well-being. Being safe, easy, and quick, CTG has become very popular. In our case, the patient was in the supine position and her abdomen was left unobstructed so that emergent cesarean section could be performed if fetal asphyxia was suspected. In the second trimester, the transesophageal echo probe was useful because of the advantages of being flexible and easy to attach to the mother's lower abdomen comparing with the usual doppler ultrasound probe. Both these approaches allowed easy, stable, and successful FHR monitoring. The problem associated with FHR monitoring in the late stage of pregnancy is the movement of the fetus. The CTG sensor would have to be repositioned when the fetus moves. However, fetal movement tends to be reduced under general anesthesia as our first case.<sup>26)</sup> The problem with FHR monitoring in the early stage of pregnancy is that the fetus cannot be rescued directly when non-reassuring fetal status is suspected. In addition, the usefulness of intraoperative FHR monitoring during pregnancy is controversial, because no large systematic study has been conducted. Maternal anesthesia may decrease the baseline FHR and variability.<sup>19,23)</sup> Misinterpretation of FHR data could result in interventions that endanger the fetus, such as an unnecessary cesarean section.<sup>27)</sup> So, a trained obstetrician team is needed to read it and prepare for an urgent cesarean delivery during surgery.<sup>28)</sup> Horrigan et al. reviewed that no fetal hypoxic condition has been documented without the occurrence of a maternal hypoxic complication, whether FHR monitoring is used or not.<sup>29)</sup> Balki and Manninen reported a successful craniotomy for suprasellar meningioma in a 28-week pregnant woman who suffered from rapidly deteriorating

vision, without FHR monitoring.<sup>5)</sup> They did not use FHR monitoring because there was no preparation for emergency cesarean delivery with the mother's consent. The American College of Obstetrics and Gynecology Committee opinion on "Non-Obstetric surgery in Pregnancy" stated that "although there are no data to support specific recommendations regarding non-obstetric surgery and anesthesia in pregnancy, it is important for non-obstetric physicians to obtain obstetric consultation before performing non-obstetric surgery, and the decision to use fetal monitoring should be individualized and each case warrants a team approach for optimal safety of the woman and her baby."<sup>28)</sup> FHR monitoring facilitates the best possible care for the fetus, especially when the mother wishes to continue the pregnancy or deliver the fetus if fetal asphyxia is suspected. In this line, we were able to operate safely, stably, and successfully for both mother and fetus under monitoring of FHR with the cooperation of obstetrician and anesthesiologist.

## Conclusion

FHR monitoring is useful for AVM surgery during pregnancy. CTG is an appropriate method in the third trimester, whereas ultrasonography, using a transesophageal echo probe, can be used in the second trimester. These methods could have a wider application for cerebrovascular surgery during pregnancy.

## Conflicts of Interest Disclosure

The authors declare no conflict of interest concerning the materials or methods used in this study or the findings specified in this article.

## References

- 1) Dias MS, Sekhar LN: Intracranial hemorrhage from aneurysms and arteriovenous malformations during pregnancy and the puerperium. *Neurosurgery* 27: 855–865; discussion 865–866, 1990
- 2) Graf CJ, Perret GE, Torner JC: Bleeding from cerebral arteriovenous malformations as part of their natural history. *J Neurosurg* 58: 331–337, 1983
- 3) Robinson JL, Hall CS, Sedzimir CB: Arteriovenous malformations, aneurysms, and pregnancy. *J Neurosurg* 41: 63–70, 1974
- 4) Tuncali B, Aksun M, Katircioglu K, Akkol I, Savaci S: Intraoperative fetal heart rate monitoring during emergency neurosurgery in a parturient. *J Anesth* 20: 40–43, 2006
- 5) Balki M, Manninen PH: Craniotomy for suprasellar meningioma in a 28-week pregnant woman without

- fetal heart rate monitoring. *Can J Anaesth* 51: 573–576, 2004
- 6) Berman MF, Sciacca RR, Pile-Spellman J, Stapf C, Connolly ES, Jr, Mohr JP, Young WL: The epidemiology of brain arteriovenous malformations. *Neurosurgery* 47: 389–396; discussion 397, 2000
- 7) Fleetwood IG, Steinberg GK: Arteriovenous malformations. *Lancet* 359: 863–873, 2002
- 8) Horton JC, Chambers WA, Lyons SL, Adams RD, Kjellberg RN: Pregnancy and the risk of hemorrhage from cerebral arteriovenous malformations. *Neurosurgery* 27: 867–871; discussion 871–872, 1990
- 9) Gross BA, Du R: Rate of re-bleeding of arteriovenous malformations in the first year after rupture. *J Clin Neurosci* 19: 1087–1088, 2012
- 10) Gross BA, Du R: Hemorrhage from arteriovenous malformations during pregnancy. *Neurosurgery* 71: 349–355; discussion 355–356, 2012
- 11) Trivedi RA, Kirkpatrick PJ: Arteriovenous malformations of the cerebral circulation that rupture in pregnancy. *J Obstet Gynaecol* 23: 484–489, 2003
- 12) Salvati A, Ferrari C, Chiumarulo L, Medicamento N, Dicuonzo F, De Blasi R: Endovascular treatment of brain arteriovenous malformations ruptured during pregnancy—a report of two cases. *J Neurol Sci* 308: 158–161, 2011
- 13) Fukuda K, Hamano E, Nakajima N, Katsuragi S, Ikeda T, Takahashi JC, Miyamoto S, Iihara K: Pregnancy and delivery management in patients with cerebral arteriovenous malformation: a single-center experience. *Neurol Med Chir (Tokyo)* 53: 565–570, 2013
- 14) Spetzler RF, Martin NA: A proposed grading system for arteriovenous malformations. *J Neurosurg* 65: 476–483, 1986
- 15) Gross BA, Du R: Surgical and radiosurgical results of the treatment of cerebral arteriovenous malformations. *J Clin Neurosci* 19: 1001–1004, 2012
- 16) Parer JT, Ikeda T: A framework for standardized management of intrapartum fetal heart rate patterns. *Am J Obstet Gynecol* 197: 26.e1–6, 2007
- 17) Parer JT, King T, Flanders S, Fox M, Kilpatrick SJ: Fetal acidemia and electronic fetal heart rate patterns: is there evidence of an association? *J Matern Fetal Neonatol* 19: 289–294, 2006
- 18) Zuspan FP, Quilligan EJ, Iams JD, van Geijn HP: Predictors of intrapartum fetal distress: the role of electronic fetal monitoring. Report of the National Institute of Child Health and Human Development Consensus Development Task Force. *Am J Obstet Gynecol* 135: 287–291, 1979
- 19) Rosen MA: Management of anesthesia for the pregnant surgical patient. *Anesthesiology* 91: 1159–1163, 1999
- 20) Goodman S: Anesthesia for nonobstetric surgery in the pregnant patient. *Semin Perinatol* 26: 136–145, 2002
- 21) Gianopoulos JG: Establishing the criteria for anesthesia and other precautions for surgery during pregnancy. *Surg Clin North Am* 75: 33–45, 1995

- 22) Macarthur A: Craniotomy for suprasellar meningioma during pregnancy: role of fetal monitoring. *Can J Anaesth* 51: 535–538, 2004
- 23) Reitman E, Flood P: Anaesthetic considerations for non-obstetric surgery during pregnancy. *Br J Anaesth* 107(Suppl 1): i72–78, 2011
- 24) Minielly R, Yuzpe AA, Drake CG: Subarachnoid hemorrhage secondary to ruptured cerebral aneurysm in pregnancy. *Obstet Gynecol* 53: 64–70, 1979
- 25) Newman B, Lam AM: Induced hypotension for clipping of a cerebral aneurysm during pregnancy: a case report and brief review. *Anesth Analg* 65: 675–678, 1986
- 26) Ito T, Toyoshima N, Takahashi H, Ozasa A, Nakajima K, Tatsumura M, Teragawa N, Nobuhara H, Iwanaga M: [Study by fetal movement meter of effects of general anesthesia on fetal movement and fetal cardiac rate]. *Obstetrical and Gynecological Practice* 39: 1115–1118, 1990 (Japanese)
- 27) Immer-Bansi A, Immer FF, Henle S, Spörri S, Petersen-Felix S: Unnecessary emergency caesarean section due to silent CTG during anaesthesia? *Br J Anaesth* 87: 791–793, 2001
- 28) ACOG Committee on Obstetric Practice: ACOG Committee Opinion Number 284, August 2003: Nonobstetric surgery in pregnancy. *Obstet Gynecol* 102: 431, 2003
- 29) Horrigan TJ, Villarreal R, Weinstein L: Are obstetrical personnel required for intraoperative fetal monitoring during nonobstetric surgery? *J Perinatol* 19: 124–126, 1999

---

*Address reprint requests to:* Kenji Fukuda, MD, Department of Neurosurgery, Faculty of Medicine, Fukuoka University, 7-45-1 Nanakuma, Jonan-ku, Fukuoka, Fukuoka 814-0180, Japan.  
*e-mail:* kefukuda@fukuoka-u.ac.jp