

Received: 2017.08.28

Accepted: 2017.09.21

Published: 2018.03.06

Amniotic Membrane Transplantation in Reconstructive and Regenerative Ophthalmology

Authors' Contribution:
Study Design A
Data Collection B
Statistical Analysis C
Data Interpretation D
Manuscript Preparation E
Literature Search F
Funds Collection G

ABCDEF 1 **Tobias Röck**
CDEF 1 **Karl Ulrich Bartz-Schmidt**
ABCEF 1 **Johanna Landenberger**
ABCDEF 2 **Matthias Bramkamp**
ABCDEF 1 **Daniel Röck**

1 Centre for Ophthalmology, University of Tübingen, Tübingen, Germany
2 Department of General Medicine, Ruhr-University Bochum, Bochum, Germany

Corresponding Author: Tobias Röck, e-mail: Tobias.Roeck@med.uni-tuebingen.de
Source of support: Departmental sources

Background: The goal of this study was to investigate numbers, indications, surgical techniques, and experiences of amniotic membrane transplantation at the University Eye Hospital Tübingen over the last 16 years.


Material/Methods: Data from all amniotic membrane transplantations from January 2001 to December 2016 were retrospectively analyzed. Data was accessed from the electronic database and the annual reports of the Eye Bank at the University Eye Hospital Tübingen.

Results: A total of 771 amniotic membrane transplantations were performed between 2001 and 2016 at the University Eye Hospital Tübingen. The mean number of amniotic membrane transplantations was 48 per year (range: 7–81). Overall, the mean number of amniotic membrane transplantations more than doubled, from 31 amniotic membrane transplantations per year during the first 8-year period to 66 amniotic membrane transplantations per year during the second 8-year period ($p < 0.0001$). The most common surgical indications for amniotic membrane transplantation were corneal ulcers and persistent corneal epithelial defects. The inlay, overlay, and sandwich technique became the favored surgical methods for various disorders of the ocular surface.

Conclusions: Our study showed a significant increase of amniotic membrane transplantations from 2001 to 2016. This increase is likely influenced by the introduction of different surgical amniotic membrane transplantation techniques, the rising knowledge about containing growth factors, neurotrophins and cytokines, and the demographic change with aging of the population.

MeSH Keywords: **Amnion • Biological Dressings • Cornea • Corneal Diseases • Guided Tissue Regeneration • Reconstructive Surgical Procedures**

Full-text PDF: <https://www.annalsoftransplantation.com/abstract/index/idArt/906856>

 1730

 —

 2

 41



Background

John Staige Davis performed the first therapeutically human amniotic membrane transplantation (AMT) as skin substitutes for treating open wounds in 1910 [1]. Thirty years later de Rotth described the first clinically use of amniotic membrane (AM) in ophthalmology. He used fresh AM as a biological bandage material for management of conjunctival defects [2].

AM, the inner layer of the placenta, is a thin, semitransparent, resilient, and avascular tissue, which consists histologically of a single epithelial layer, a thick basement membrane, and an avascular stroma. AM contains abundant growth factors, mitogenic factors, anti-angiogenic factors, anti-inflammatory proteins, and natural protease inhibitors and anti-scarring properties [3].

In recent years, many studies have shown clinical efficacy of AMT in stimulating wound healing by promoting epithelialization while suppressing inflammation, angiogenesis and scarring [3,4]. AM may not only facilitate healing but also support regeneration [5].

In recent two decades, AMT has been used increasingly and successfully to treat various types of ophthalmic indications, which include chemical or thermal burns, persistent corneal epithelial defects, corneal ulcers, reconstruction of conjunctival and ocular surfaces, ocular pemphigoid or Stevens-Johnson syndrome, and bullous keratopathy [6–10].

This increasing popularity of AMT is likely influenced by the method of cryopreservation, which was introduced by Lee et al. in 1997 [11].

Confronted with the increasing use of AMT, we decided to conduct the current study to investigate the numbers, indications, surgical techniques, and experiences of AMT at the University Eye Hospital Tübingen from January 2001 to December 2016.

To the best of our knowledge, this is the first study over such a long interval.

Material and Methods

Data from all AMTs at the University Eye Hospital Tübingen from January 2001 to December 2016 were retrospectively analyzed from the electronic database and the annual reports of the Eye Bank at the University Eye Hospital Tübingen. The indications for AMT were categorized and the yearly numbers of performed AMTs were evaluated. The mean number of AMTs was calculated and compared. This study was approved by the Institutional Review Board of the University of Tübingen and adhered to the tenets of the Declaration of Helsinki.

Statistical analysis

Statistical analysis of the data was conducted using the Statistical Packages for the Social Science (SPSS 18.0). Quantitative variables were expressed as mean \pm standard deviation (SD). A value of $p < 0.05$ was considered to be statistically significant. Yearly numbers of AMTs were compared using a Student *t*-test.

Results

Between 2001 and 2016, a total of 771 AMTs were performed at the University Eye Hospital Tübingen. Mean patient age was 67 ± 12 years (range, 13–97 years), and 70% of patient were older than 59 years. The male: female ratio was 57: 43%. The mean number of AMTs was 48 per year (range: 7–81). Figure 1 shows the number of AMTs performed per year. Overall, the mean number of AMTs more than doubled, from 31 AMTs per year during the first 8-year period to 66 AMTs per year during the second 8-year period ($p < 0.0001$).

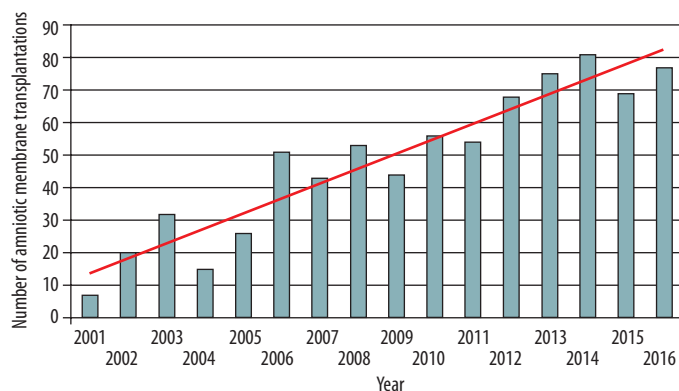


Figure 1. This figure shows the number of amniotic membrane transplantations (AMTs) performed per year. The mean number of AMTs more than doubled, from 31 AMTs per year during the first 8-year period to 66 AMTs per year during the second 8-year period ($p < 0.0001$).

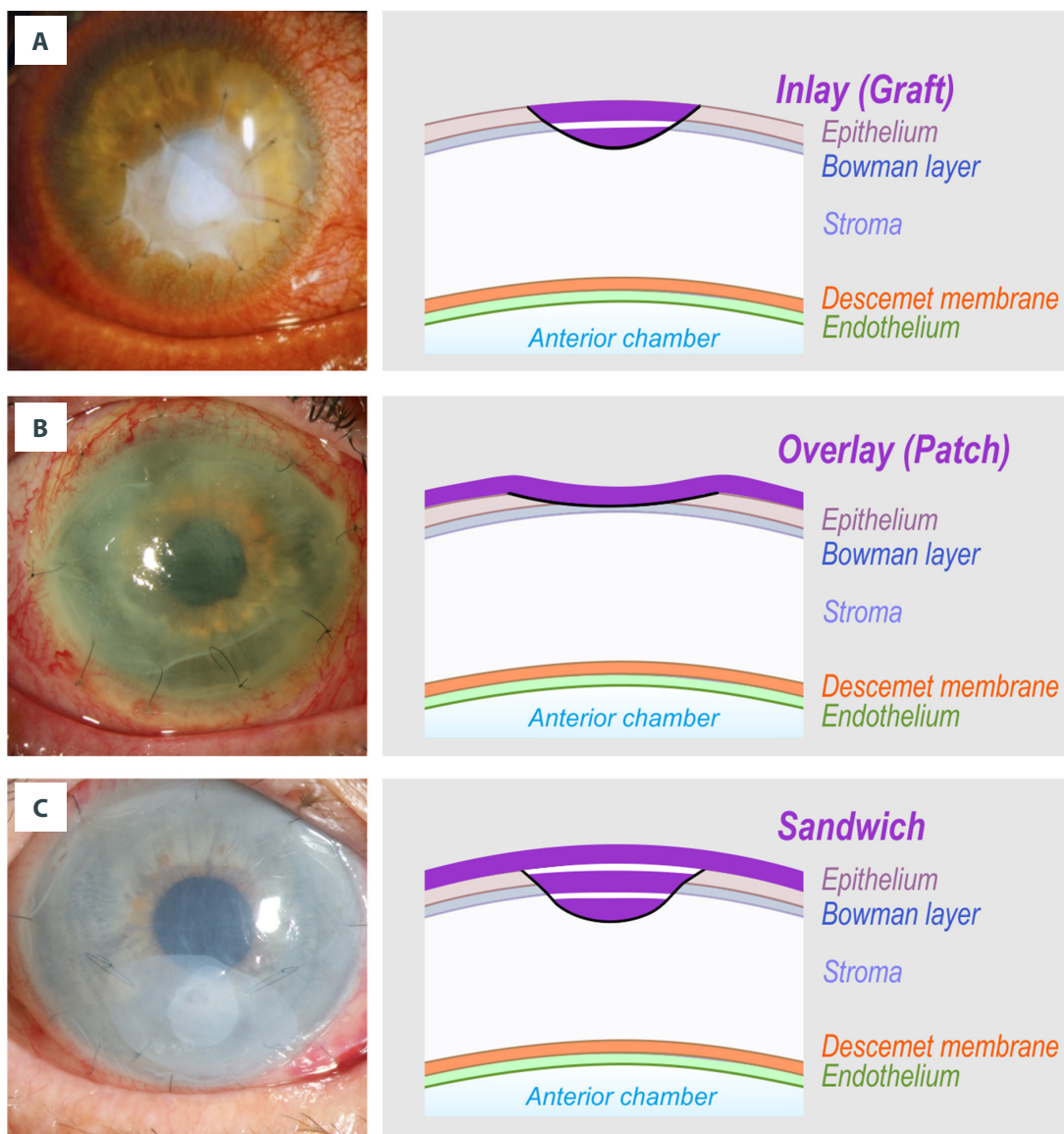


Figure 2. Slit-lamp color photography with schematic overview displaying the main techniques of amniotic membrane transplantation (AMT). The amniotic membrane (AM) is used in each instance epithelial side up. (A) The inlay or graft technique is used for stromal defects. The graft is fixed in the stromal defect with single button 10-0 nylon sutures in the periphery of the corneal ulcer. Before transplantation, a small rim of de-epithelialization around the stromal defect is prepared to ensure that no epithelium remains under the graft. The epithelium is expected to grow over the AM, which provides a new basement membrane. (B) The overlay or patch technique is used for corneal diseases with nonhealing epithelial defects having no or only shallow stromal defects, for example after chemical or thermal burn or recurrent corneal erosions. The AM is sutured over the peripheral epithelial remnants and the centrally denuded stroma. (C) The sandwich technique is used for deep stromal defects with large nonhealing epithelial defects. It's a combination of the two described methods above. A single-layer or multilayer inlay is combined with an overlay as described, respectively. The corneal epithelium is expected to grow under the patch but over the uppermost graft.

The most common surgical indications for AMT were corneal ulcers (47%) and persistent corneal epithelial defects (18%). The most common surgical methods were the inlay, overlay, and sandwich technique. Figure 2 shows a slit-lamp color photography with schematic overview displaying the main techniques of AMT.

Discussion

Our study investigated numbers, indications, surgical methods, and experiences of AMT at the University Eye Hospital Tübingen over the last 16 years from 2001 to 2016.

AMT has been found to be a great method for corneal and conjunctival reconstruction and regeneration in many clinical situations, including burns, persistent epithelial defects of the cornea, corneal ulcers and diseases of the conjunctiva when conservative methods of treatment fail [12]. AMT can even be used to reconstruct and restore conjunctival surfaces after resection of large ocular surface neoplasm [13]. AMT also helps to maintain a normal conjunctival phenotype and has a cosmetic benefit over buccal or mucosal grafts, which result in a nonconjunctival epithelial morphology [14–16].

AM provides a rich source of stem cells and has unique features: it supports, facilitates and promotes conjunctival and corneal epithelialization and healing, inhibits and allows a reduction of inflammation, immune rejection, vascularization, scarring and pain.

AMT has brought about major advances in the reconstructive surgery of the ocular surface. It can be used as a permanent graft in the tissue defect, so that epithelium cells will grow over the AM and the membrane will subsequently be integrated into the host tissue (e.g., the corneal stroma), which helps improve the structural quality of the tissue. The main target of this technique is to provide stability for regenerating epithelium and to restore tissue integrity and function. In this mode, the inlay or graft can be used as single or multilayers and fixed with single button 10-0 nylon sutures in the periphery of the corneal ulcer. When AM is used as a temporary biological patch or overly the main target is to suppress inflammation, reduce scarring, decrease vascularization, and promote healing. AM is sutured to the ocular surface using a patch larger than the defect. The AM acts as a biological bandage. Furthermore, the AM overlay relieves pain, which was clinically proven effective in management of chemical burns [17,18], severe bacterial keratitis [19], Steven-Johnson syndrome [20,21], and painful bullous keratopathy [22–25]. Sometimes, both an inlay and an overlay are used together as a sandwich technique, in which case the overlay is used as a protective shield to ensure epithelialization of the AM used as an inlay [26–28]. In such cases, the epithelium is expected to grow between the uppermost inlay and the patch.

In 2017 Tabatabaei et al. reported in a randomized clinical trial, that an enormous advantage of early use of AMT in treatment of patients with bacterial keratitis was associated with better outcomes compared to antibiotic therapy alone [26]. AM exerts antimicrobial effects and does not impede the penetration of topical antibiotics. It has been shown that AM becomes soaked with antibiotics and prolongs the effect [30,31].

Furthermore, in cases of severe ulcerative keratitis AM can be used to seal small corneal perforations and can soothe inflammation. Under conditions when corneal transplantations cannot be performed due to a shortage of corneal tissue [32–36], AMT is an effective alternative. AMT might also provide sufficient time to obtain a donor cornea and provide a good condition for future successful keratoplasty as an elective investigation with a better outcome for the patient's vision.

If corneal ulceration is due to bacterial infection, it is beneficial to delay penetrating keratoplasty until aggressive topical fortified antibiotics has been started two to three days prior. AMT may help to avoid an emergency corneal transplantation, create a better basis for and improve the prognosis of the elective keratoplasty.

AM has become a therapeutic option not only in ophthalmology but also in various other fields within medicine and has been applied to a wide variety of clinical scenarios including burns, chronic ulcers, dural defects, intra-abdominal adhesions, peritoneal reconstruction, genital reconstruction, hip arthroplasty, tendon repair, nerve repair, microvascular reconstruction, intra-oral reconstruction and reconstruction of the nasal lining and tympanic membrane [37,38]. Additionally, AM is widely available, economical, and is easy to manipulate, process and store. The great spread of AMT is likely influenced by the method of cryopreservation, which was introduced 20 years ago [11]. It has been shown that preservation even after storage at -80°C [34] does not influence growth factors [39].

Overall, our study demonstrated that the mean number of AMTs more than doubled, from 31 AMTs per year during the first 8-year period to 66 AMTs per year during the second 8-year period ($p < 0.0001$). This increasing popularity of AMT and doubling of the numbers of AMT is mainly due to rising knowledge about essential healing growth factors of AM and the demographic change with aging of the population. In all, 70% of our patients who needed AMT were older than 59 years of age.

Despite increasing use of AM in various fields within medicine and its miraculous biological activities, some limitations in reconstructive and regenerative ophthalmology must be considered. The use of AMT for severe eye burns is limited, because these burns frequently cause a wide loss of epithelial stem cells. A wider limbal epithelial stem cells deficiency requires

additional transplantation of autologous or heterologous stem cells. Almost 30 years ago, tenonplasty was described as a surgical treatment approach for eyes with severe burns [40,41]. In 1989 a conjunctiva-Tenon flap and a Tenon plasty were introduced to cover and to cure corneoscleral ulceration after eye burns. These strategies should not be forgotten in such cases and could be combined with AMT.

The use of AMT for large corneal perforations is also a limitation. In these selected cases, a full thickness (penetrating) keratoplasty is required, because AM is not sufficient. Most often a keratoplasty à chaud is inevitably required to secure the open eye with its risk of endophthalmitis. Preservation of the globe is the main objective in this very urgent procedure used for performing penetrating keratoplasty.

In addition, a further solution for management of large central corneal perforations should not be forgotten. For these eyes, a corneal patch graft can be used temporarily. Ideally, all necrotic tissues and epithelium are removed from the bed of the ulcer or margins of the corneal perforation until a viable tissue corneal patch graft is sutured in place with interrupted 10.0 nylon sutures.

Partial or total conjunctival flaps are reserved for chronic, indolent, non healing ulcers in eyes that have poor visual potential. Conjunctival flaps help to promote healing and decrease the need for frequent medication. Additionally, a temporary

tarsorrhaphy can decrease the ocular surface area and reduce corneal exposure and evaporation of the tear film while minimizing friction between the eyelid and ocular surface during blinking. In summary, knowledge and experience are necessary in considering multiple possibilities to achieve the desired goals, while considering the patient's situation. AMT should be considered as a secure and easy option in reconstructive and regenerative ophthalmology.

Conclusions

Our study showed a significant increase of amniotic membrane transplantations (ATM) from 2001 to 2016. This increase was likely influenced by the introduction of different surgical AMT techniques, the rising knowledge about containing growth factors, neurotrophins and cytokines, and the demographic change with the aging population.

Conflict of interests

None.

Statement

This research received no specific grant from any funding agency in the public, commercial or not-for-profit sectors.

References:

- Davis JS: Skin transplantation. *Johns Hopkins Hosp Rep.* 1910; 15: 307–96
- De Roth A: Plastic repair of conjunctival defects with fetal membrane. *Arch Ophthalmol*, 1940; 23: 522–25
- McQuilling JP, Vines JB, Mowry KC: *In vitro* assessment of a novel, hypothermically stored amniotic membrane for use in a chronic wound environment. *Int Wound J*, 2017 [Epub ahead of print]
- Tseng SCG, Espana EM, Kawakita T et al: How does amniotic membrane work? *Ocul Surf*, 2004; 2(3): 177–87
- Adzick NS, Lorenz HP: Cells, matrix, growth factors, and the surgeon. The biology of scarless fetal wound repair. *Ann Surg*, 1994; 220(1): 10–18
- Liu J, Sheha H, Fu Y et al: Update on amniotic membrane transplantation. *Expert Rev Ophthalmol*, 2010; 5(5): 645–61
- Sippel KC, Ma JJK, Foster CS: Amniotic membrane surgery. *Curr Opin Ophthalmol*, 2001; 12: 269–81
- Bouchard CS, John T: Amniotic membrane transplantation in the management of severe ocular surface disease: Indications and outcomes. *Ocul Surf*, 2004; 2(3): 201–11
- Tseng SCG: Amniotic membrane transplantation for ocular surface reconstruction. *Bioscience Rep*, 2002; 21: 481–89
- Dua HS, Gomes JA, King AJ et al: The amniotic membrane in ophthalmology. *Surv Ophthalmol*, 2004; 49(1): 51–77
- Lee S-H, Tseng SCG: Amniotic membrane transplantation for persistent epithelial defects with ulceration. *Am J Ophthalmol*, 1997; 123: 303–12
- Meller D, Pauklin M, Thomasen H et al: Amniotic membrane transplantation in the human eye. *Dtsch Arztebl Int*, 2011; 108(14): 243–48
- Paridaens D, Beekhuis H, van Den Bosch W et al: Amniotic membrane transplantation in the management of conjunctival malignant melanoma and primary acquired melanosis with atypia. *Br J Ophthalmol*, 2001; 85: 658–61
- Ahmad MS, Frank GS, Hink EM et al: Amniotic membrane transplants in the pediatric population. *J AAPOS*, 2017; 21(3): 215–18
- Prabhasawat P, Tesavibul N: Preserved amniotic membrane transplantation for conjunctival surface reconstruction. *Cell Tissue Bank*, 2001; 2(1): 31–39
- Asoklis RS, Damijonaityte A, Butkiene L et al: Ocular surface reconstruction using amniotic membrane following excision of conjunctival and limbal tumors. *Eur J Ophthalmol*, 2011; 21(5): 552–58
- Kheirkhah A, Johnson DA, Paranjpe DR et al: Temporary sutureless amniotic membrane patch for acute alkaline burns. *Arch Ophthalmol*, 2008; 126(8): 1059–66
- Westekemper H, Figueiredo FC, Siah WF et al: Clinical outcomes of amniotic membrane transplantation in the management of acute ocular chemical injury. *Br J Ophthalmol*, 2017; 101(2): 103–7
- Sheha H, Liang L, Li J et al: Sutureless amniotic membrane transplantation for severe bacterial keratitis. *Cornea*, 2009; 28(10): 1118–23
- John T, Foulks GN, John ME et al: Amniotic membrane in the surgical management of acute toxic epidermal necrolysis. *Ophthalmology*, 2002; 109(2): 351–60
- Kobayashi A, Yoshita T, Sugiyama K et al: Amniotic membrane transplantation in acute phase of toxic epidermal necrolysis with severe corneal involvement. *Ophthalmology*, 2006; 113(1): 126–32
- Sonmez B, Kim BT, Aldave AJ: Amniotic membrane transplantation with anterior stromal micropuncture for treatment of painful bullous keratopathy in eyes with poor visual potential. *Cornea*, 2007; 26(2): 227–29
- Pires RTF, Tseng SCG, Prabhasawat P et al: Amniotic membrane transplantation for symptomatic bullous keratopathy. *Arch Ophthalmol*, 1999; 117: 1291–97

24. Mejia LF, Santamaria JP, Acosta C: Symptomatic management of postoperative bullous keratopathy with nonpreserved human amniotic membrane. *Cornea*, 2002; 21(4): 342–45
25. Espana EM, Grueterich M, Sandoval H et al: Amniotic membrane transplantation for bullous keratopathy in eyes with poor visual potential. *J Cat Refract Surg*, 2003; 29: 279–84
26. Seitz B, Grüterich M, Cursiefen C et al: Conservative and surgical treatment of neurotrophic keratopathy. *Ophthalmologe*, 2005; 102(1): 15–26
27. Seitz B, Das S, Sauer R et al: Amniotic membrane transplantation for persistent corneal epithelial defects in eyes after penetrating keratoplasty. *Eye*, 2009; 23(4): 840–48
28. Hoffmann S, Szentmáry N, Seitz B: Amniotic membrane transplantation for the treatment of infectious ulcerative keratitis before elective penetrating keratoplasty. *Cornea*, 2013; 32(10): 1321–25
29. Tabatabaei SA, Soleimani M, Behrouz MJ et al: A randomized clinical trial to evaluate the usefulness of amniotic membrane transplantation in bacterial keratitis healing. *Ocul Surf*, 2017; 15(2): 218–26
30. Kim JS, Kim JC, Hahn TW et al: Amniotic membrane transplantation in infectious corneal ulcer. *Cornea*, 2001; 20(7): 720–26
31. Mencucci R, Menchini U, Dei R: Antimicrobial activity of antibiotic-treated amniotic membrane: An *in vitro* study. *Cornea*, 2006; 25(4): 428–31
32. Röck D, Wude J, Yoeruek E et al: Evaluation of factors limiting corneal donation. *Ann Transplant*, 2016; 21: 701–7
33. Röck D, Bartz-Schmidt KU, Röck T: Rates of and experiences with corneal donation at the University Hospital Tübingen from 2002 to 2015. *Ann Transplant*, 2016; 21: 433–38
34. Röck T, Hofmann J, Thaler S et al: Factors that influence the suitability of human organocultured corneas. *Graefes Arch Clin Exp Ophthalmol*, 2016; 254(1): 135–41
35. Röck D, Petersen P, Yoeruek E et al: Effect of organ scandal on corneal donation rate and organ donors at a German University Hospital. *Ann Transplant*, 2018; 23: 425–30
36. Röck T, Bramkamp M, Bartz-Schmidt KU et al: Organ transplantation scandal influencing corneal donation rate. *Int J Ophthalmol*, 2017; 10(6): 1001–3
37. Jirsova K, Jones GLA: Amniotic membrane in ophthalmology: Properties, preparation, storage and indications for grafting-a review. *Cell Tissue Bank*, 2017; 18(2): 193–204
38. Fairbairn NG, Randolph MA, Redmond RW: The clinical applications of human amnion in plastic surgery. *J Plast Reconstr Aesthet Surg*, 2014; 67(5): 662–75
39. Koizumi NJ, Inatomi TJ, Sotozono CJ et al: Growth factor mRNA and protein in preserved human amniotic membrane. *Curr Eye Res*, 2000; 20(3): 173–77
40. Reim M, Teping C: Surgical procedures in the treatment of most severe eye burns. Revival of the artificial epithelium. *Acta Ophthalmol Suppl*, 1989; 192: 47–54
41. Kuckelkorn R, Schrage N, Reim M: Treatment of severe eye burns by tenoplasty. *Lancet*, 1995; 345(8950): 657–58