

Case report

An unusual case of intraabdominal abscess and acute abdomen caused by axial torsion of a Meckel's diverticulum



İhsan Yıldız*, Yavuz Savaş Koca, İbrahim Barut

Suleyman Demirel University Medical School, Department of General Surgery, Isparta, Turkey

HIGHLIGHTS

- Axial torsion of MD is very a rare and serious complication.
- Although MD is known as a pediatric disease, it is likely to occur in adults as well.
- Axial torsion of Meckel's diverticulum should be kept in mind the adults presenting with symptoms of acute abdomen.

ARTICLE INFO

Article history:

Received 10 December 2015

Received in revised form

25 January 2016

Accepted 25 January 2016

Keywords:

Meckel's diverticulum

Omphalomesenteric duct cyst

ABSTRACT

Background: Meckel's diverticulum (MD), the most common congenital anomaly of the gastrointestinal tract, is a true diverticulum. MD is mostly seen in pediatric age groups but may be seen in adults as well. Is twice common in men than women. Surgical treatment is required in symptomatic MD patients. We present a 21-year-old female patient who was admitted with acute abdomen and underwent diverticulectomy with diagnosis of Meckel's diverticulum.

Presentation of case: The 21-year-old female patient was admitted to emergency service with abdominal pain, nausea and vomiting. Physical examination revealed abdominal distention, rebound tenderness and defense. Abdominal radiography revealed air-fluid levels. White blood cell count was high. In the exploration, torsion of MD was observed and diverticulectomy was performed. Histopathologic analysis indicated the presence of MD. The patient recovered without complication, and was uneventfully discharged.

Discussion: MD is found in 2% of the general population. Common complications of MD include gastrointestinal bleeding, intestinal obstruction, perforation and diverticulitis. However, axial torsion of MD is a rare complication. Simple diverticulectomy is sufficient in the treatment of most MD cases; however, ileal resection may be required in some cases. Diagnosis of MD is established by histopathologic analysis.

Conclusion: Although MD is known as a pediatric disease, it is likely to occur in adults as well. Axial torsion of Meckel's diverticulum should be kept in mind the adults presenting with symptoms of acute abdomen.

© 2016 The Authors. Published by Elsevier Ltd on behalf of IJS Publishing Group Limited. This is an open access article under the CC BY-NC-ND license (<http://creativecommons.org/licenses/by-nc-nd/4.0/>).

1. Introduction

Meckel's diverticulum (MD), the remnant of the omphalomesenteric duct and the most common congenital anomaly of the gastrointestinal tract, is a true diverticulum containing all the layers of the small bowel wall and located in the antimesenteric border of the ileum. The mucosa of MD may contain pancreatic, duodenal,

ileal, colonic, and heterotopic gastric mucosa. MD was first described by Meckel in 1809 and is often described by the "rule of 2", which indicates that MD is usually located 2 feet proximal to the ileocecal valve, mostly presents before the age of 2, is seen twice as commonly in men as in women, and is found in 2% of the general population [1,2].

MD is mostly seen in pediatric age groups but may occur in adults as well. MD is mostly asymptomatic and it is symptomatic in only 3.7%–6.42% of the patients throughout their lives. Common complications of MD include bleeding in the sub-gastrointestinal tract, intestinal obstruction, perforation, diverticulitis, and cecal

* Corresponding author. Suleyman Demirel University, School of Medicine, Department of General Surgery, 32260 Isparta, Turkey.

E-mail address: drihsanyildiz@gmail.com (İ. Yıldız).

volvulus [3,4]. Surgical treatment is required in patients with symptomatic and complicated MD.

In this report, we present a case of MD localized in the subumbilical region that presented with abscess formation associated with axial torsion and caused acute abdomen.

2. Presentation of case

The 21-year-old female patient had no history of abdominal surgery and presented to our emergency service with a two-day history of worsening abdominal pain, nausea, vomiting, anorexia, fever, and failure to eliminate feces or pass gas. Patient history revealed that the patient had no such complaints before.

Physical examination revealed a temperature of 38 °C, a blood pressure of 120/80 mmHg, a pulse rate of 76/min, mild abdominal distention, hyperactive bowel sounds on auscultation, abdominal tenderness on palpation, and muscular defense and rebound in the subumbilical region.

Biochemical analysis revealed that the white blood cell (WBC) count was 19,000/ml (4000–8000) and the other parameters were in normal range. In the radiological examination, the direct abdominal radiography revealed several air-fluid levels and the other examinations were normal. Ultrasonography (USG) detected fluid in the subumbilical region that suggested the presence of abscess formation. Abdominal computed tomography (CT) revealed air-fluid levels and wall thickening in the ileum, a 41 × 38 mm lesion in the subumbilical region presence of abscess formation and free fluid in the pelvis (Fig. 1).

Preoperatively, cephalosporin (intravenous sefazol 1 gr) and intravenous fluid therapy was administered. During the diagnostic laparoscopy, which was performed with the prediagnosis of acute abdomen, a thorough exploration was not performed since the small bowel was markedly distended; therefore, the procedure was converted to open surgery. Surgical exploration revealed a small amount of inflamed fluid in the abdomen, axial torsion of MD associated with the ileum in the subumbilical region, and a 4 × 4 cm abscess (Fig. 2).

The abscess was drained. The diverticulum measured 3 cm in thickness and 12 cm in length and was located 45 cm proximal to the ileocecal valve, adjacent to the ileum (Fig. 3). Presence of MD was confirmed, the cecum was very mobile and the appendix was normal. The junction between the diverticulum and the ileum was resected using a gastrointestinal anastomosis (GIA) stapler. The surgery was completed by placing a drain in the abdomen. No complication was observed in the postoperative period. Oral intake was resumed on postoperative day 3, and the drain was removed on postoperative day 5. On postoperative day 6, the patient recovered without complication, the symptoms were improved, the laboratory parameters were normal, and thus the patient was uneventfully discharged. The sutures were removed on postoperative day 10.

Histopathologic analysis of the specimen confirmed the presence of MD with ischemic and necrotic ileum mucosa.

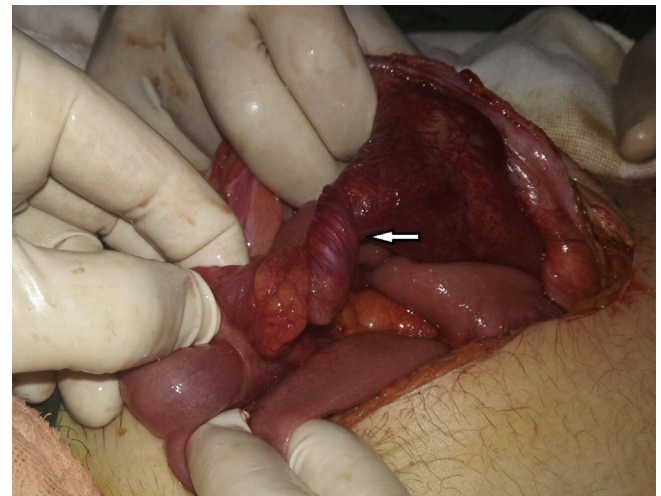


Fig. 2. Axial torsion of MD associated with the ileum in the subumbilical region.

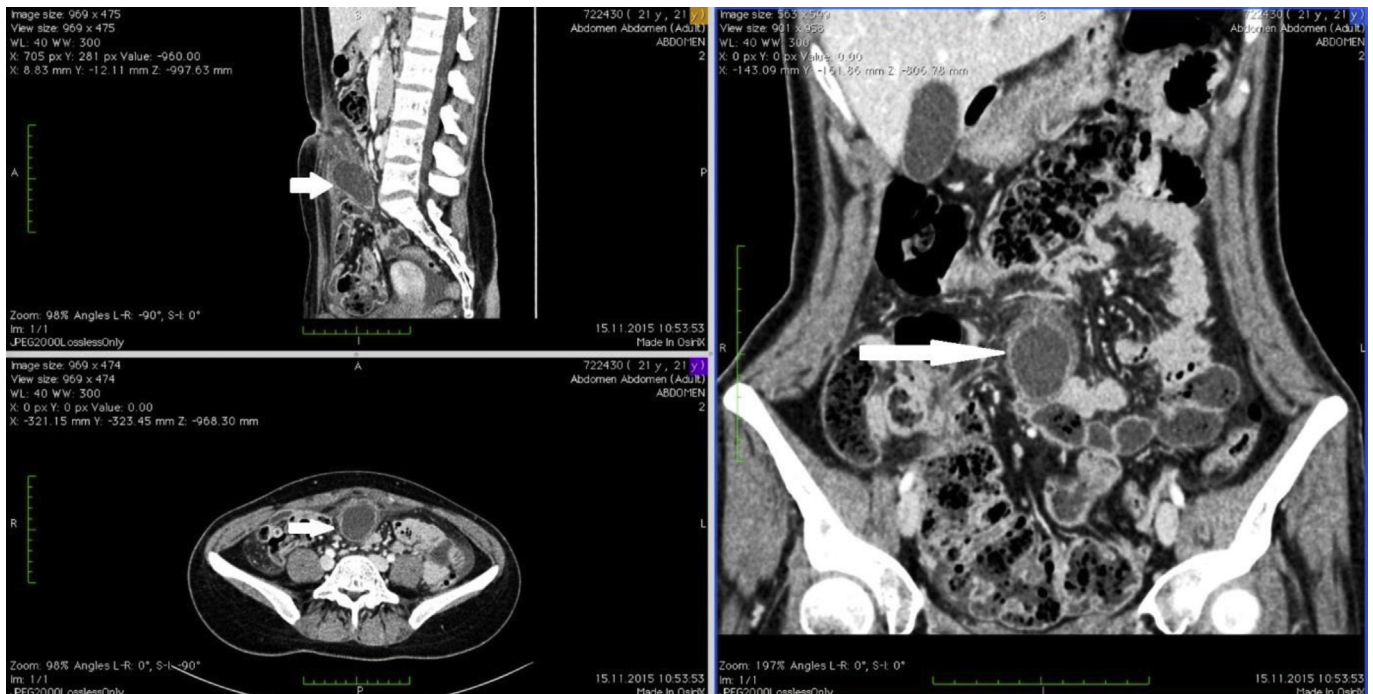

Fig. 1. CT imagine: subumbilical region presence of abscess formation.

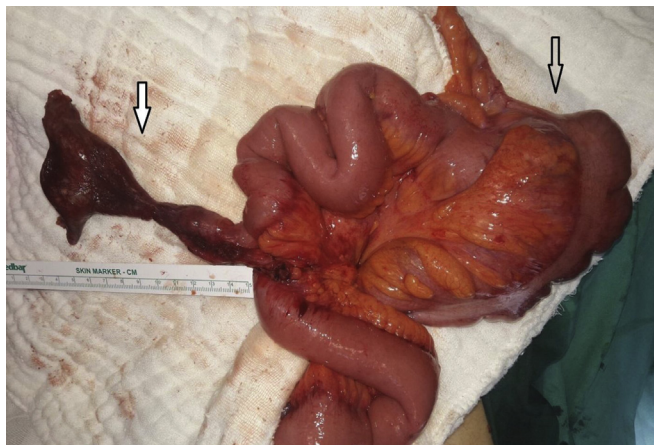

Fig. 3. MD, 12 cm length and located 45 cm proximal to the ileocecal valve.

3. Discussion

MD, the remnant of the omphalomesenteric duct located in the antimesenteric border of the ileum, is a true diverticulum containing all the layers of the small bowel wall. MD is found in 2% (range, 0.14–4.50%) of the general population, which has the highest incidence in pediatric age groups and is less commonly seen in adults and old-age individuals. The patients with an MD length greater than 2 cm are often symptomatic. MD is twice as commonly in men as in women [1,3,4]. The decision to perform surgery for MD remains a controversial issue; although some authors recommend surgery for the patients with asymptomatic incidental finding of MD, some others suggest that the decision to perform surgery should be given based on the age of the patient [5,6]. The diagnosis of the patients with symptomatic complicated MD includes patient history, physical examination, radiological examination (direct abdominal radiography at standing position), computed abdominal tomography, and laboratory tests (WBC count), respectively [1,4]. This paragraph was removed due to the reviewer recommendation.

In the prediagnosis of our patient, CT was performed during the physical examination since the direct abdominal radiography indicated air-fluid levels, the USG revealed intraabdominal fluid and an abscess formation in the subumbilical region and the WBC count was 19000/ml.

The most common complication of MD is obstruction in pediatric age groups, whereas the most common complication in adults is gastrointestinal bleeding, followed by twisting of the colon (volvulus), intestinal obstruction caused by adhesions, diverticulitis, and localized or generalized peritonitis associated with diverticulitis [2]. However, axial torsion of MD is a rare complication and has been reported only in 11 studies in the literature [5–7]. Our patient was an adult and presented with acute abdomen due to the torsion of MD caused by the abscess formation that occurred prior to perforation.

Simple diverticulectomy is sufficient in the treatment of patients with uncomplicated MD; however, large resections may be required in complicated patients (1). Common postoperative complications of MD include early surgical complications (12%), surgical site infection (3%), ileus (3%), anastomotic leak (2%), and mortality (1.5%) [5,7]. In our patient, no postoperative complication was observed and the patient was uneventfully discharged on postoperative day 6.

The mucosa of MD may contain pancreatic, duodenal, ileal, colonic, and heterotopic gastric mucosa and thus may lead to bleeding and mass formations [3,4]. Therefore, care should be taken

to avoid leaving behind any remnant tissues. The tissues left behind require segmental ileal resection rather than simple diverticulectomy [1,2]. In our patient, however, surgery was inevitable since the patient presented with an MD associated with the small bowel as well as an impression of a mass formation in the subumbilical region and the signs of acute abdomen. Simple diverticulectomy was sufficient for the treatment of the patient and no complication was observed in the postoperative period.

Definitive diagnosis of MD is established by histopathologic analysis. Similarly, in our patient, the histopathologic analysis confirmed the presence of MD with ileum mucosa.

4. Conclusion

MD is the most frequent clinical condition known in pediatric disease; however, MD may be seen in adults. Surgical treatment is required in symptomatic and complicated MD cases. Axial torsion of Meckel's diverticulum should be kept in mind in the adults presenting with symptoms of acute abdomen.

Ethical approval

No.

Sources of funding

No funding.

Author contribution

Ihsan yıldız: writing the paper and design.
Yavuz savař koca: study concept data collection.
İbrahim barut: data analysis.

Conflicts of interest

We declared that: no conflicts of interest.

Consent

A signed consent was obtained (to publish a case report) from the patient.

Guarantor

Ihsan yıldız.

References

- [1] V. Erol, T. Yoldař, S. Cin, C. Çalıřkan, E. Akgün, M. Korkut, Complicated Meckel's diverticulum and therapeutic management, *Ulus. Cerrahi Derg.* 29 (2013) 63–66.
- [2] S. Akbulut, Y. Yagmur, Giant Meckel's diverticulum: an exceptional cause of intestinal obstruction, *World J. Gastrointest. Surg.* 6 (3) (2014 March 27) 47–50.
- [3] S. Annaberdyev, T. Capizzani, T. Plesec, M. Moorman, A rare case presentation of a symptomatic omphalomesenteric Cyst in an adult, 24-year-old patient, treated with laparoscopic resection, *J. Gastrointest. Surg.* 17 (2013) 1503–1506.
- [4] N. Tenreiro, H. Moreira, S. Silva, L. Madeira, J. Gaspar, A. Oliveira, Unusual presentation of a Meckel's diverticulum: a case report, *Int. J. Surg. Case Rep.* 16 (2015) 48–51.
- [5] S.H. Kim, 14 cm long Meckel's Diverticulum associated with acute torsion, *Korean J. Gastroenterol.* 52 (2008) 131–133.
- [6] D. Tassinari, A.G. Cimatti, G. Tani, M. Lima, A common case of gastroenteritis in a child followed by an axial torsion of Meckel diverticulum: a rare and unusual complication. *BMJ Case Rep.* 22 (2013) 2013, <http://dx.doi.org/10.1136/bcr-2012-006656>.
- [7] C. Cartanese, T. Petitti, E. Marinelli, et al., Intestinal obstruction caused by torsed gangrenous Meckel's diverticulum encircling terminal ileum, *World J. Gastrointest. Surg.* 3 (2011) 106–109.