

Traction method using slim biopsy forceps for prevention of stent migration during multiple biliary stent placement

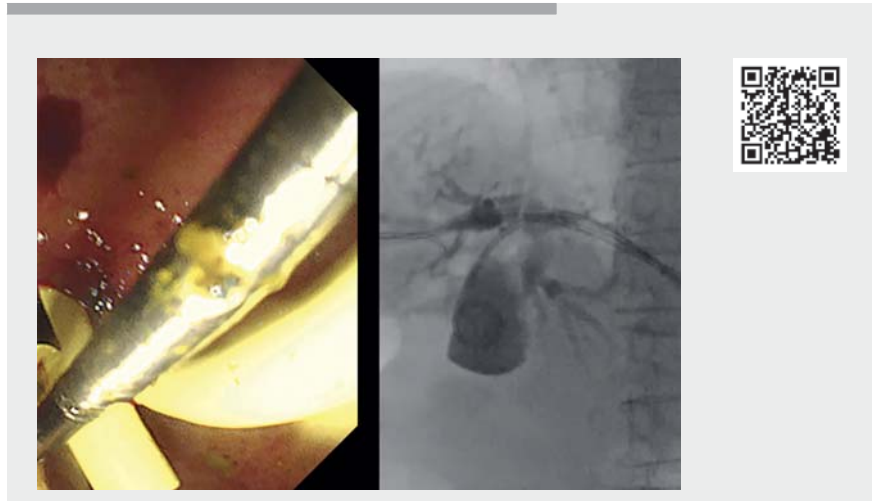

Stent migration is a possible complication encountered during placement of multiple biliary stents [1]. The SpyBite Max Biopsy Forceps (Boston Scientific Endoscopy, Natick, Massachusetts, United States), which are very slim biopsy forceps, have been developed for biopsy during peroral cholangioscopy. The forceps are introduced simultaneously from the same working channel of the duodenoscope during placement of the 7-Fr or 8.5-Fr biliary stent. Herein, we present a novel traction technique using SpyBite to prevent stent migration during placement of multiple stents.

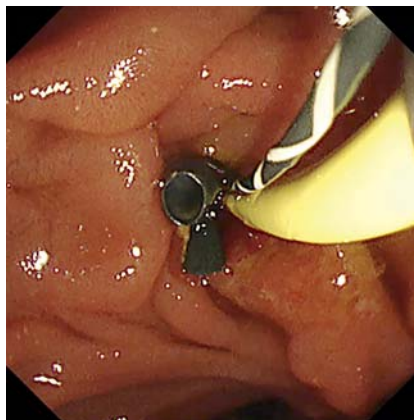
Case 1: In an 85-year-old man with obstructive jaundice owing to lymph metastasis of lung cancer, computed tomography revealed a biliary stricture extending beyond the bifurcation of the common hepatic duct, requiring multiple biliary drainages. After stent placement into B6, we attempted to add a plastic stent to B8; however, the first stent almost migrated into the bile duct. By grasping the flap of the first stent using the SpyBite, we successfully placed the second stent without migration of the first (▶ **Fig. 1**, ▶ **Fig. 2**; ▶ **Video 1**).

Case 2: An 84-year-old woman was admitted to the hospital for obstructive jaundice owing to a serous cystic neoplasm and underwent endoscopic ultrasonography-guided hepaticogastrostomy (EUS-HGS). One month thereafter, reintervention was required because of obstructive cholangitis. We attempted to place three plastic stents. During the placement of the third stent, the first stent almost migrated into the abdominal cavity. The third stent was successfully placed when the flap of the first stent was grasped using SpyBite (▶ **Fig. 3**, ▶ **Fig. 4**, ▶ **Fig. 5**; ▶ **Video 1**).

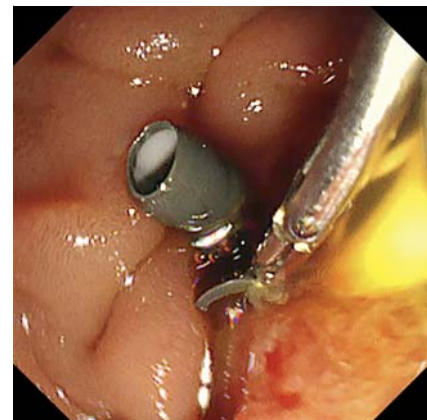
Despite reports of troubleshooting for retrieval of a migrated stent [2–4], retrieval of the stent can be challenging once migration occurs; therefore, prevention



▶ **Video 1** Successful prevention of stent migration during placement of multiple stents in two cases.



▶ **Fig. 1** Case 1. Endoscopic view during multiple biliary stent placement. The first stent almost migrates into the bile duct.



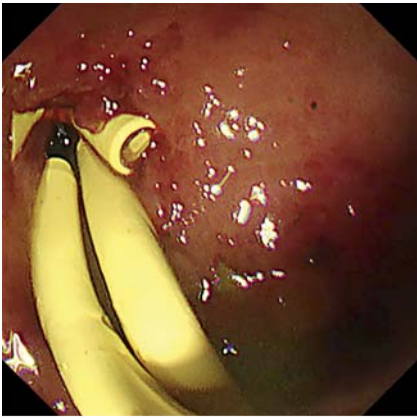▶ **Fig. 2** Case 1. Endoscopic view during traction method using the SpyBite Max Biopsy Forceps. By grasping the flap of the first stent using the SpyBite forceps, the second stent is successfully placed without migration of the first stent.

is important. Endoscopists should be aware of the characteristics of the scopes and devices used routinely, such as the diameter of the working channel and devices, which may be helpful in troubleshooting.

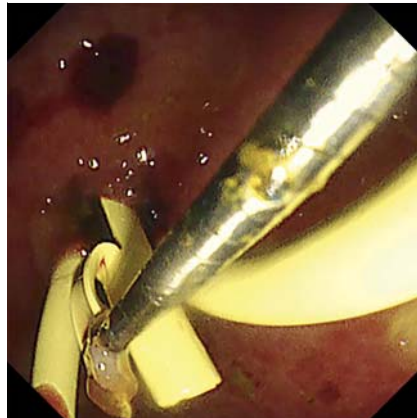
Endoscopy_UCTN_Code_TTT_1AR_2AZ

Acknowledgment

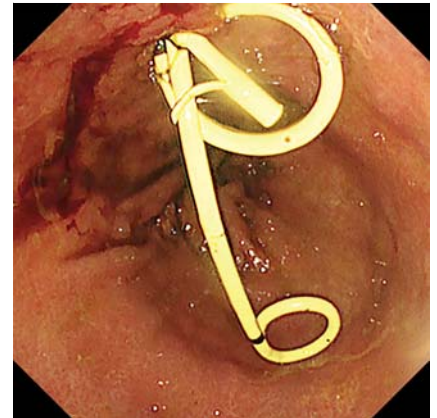
We would like to thank Editage for English language editing.



► **Fig. 3** Case 2. Endoscopic view during multiple biliary stent placement via the endoscopic ultrasonography-guided hepaticogastrostomy route. The first stent almost migrates into the abdominal cavity.



► **Fig. 4** Case 2. Endoscopic view during traction method using the SpyBite forceps.



► **Fig. 5** Case 2. Endoscopic view after successful placement of multiple stents.

Competing interests

Akio Katanuma, as a guest lecturer, received honoraria from Olympus Co., Tokyo, Japan. Kosuke Iwano, Tsuyoshi Hayashi, Tatsuya Ishi, and Kuniyuki Takahashi declare that they have no conflict of interest.

The authors

Kosuke Iwano, Tsuyoshi Hayashi, Tatsuya Ishii, Kuniyuki Takahashi, Akio Katanuma
Center for Gastroenterology, Teine-Keijinkai Hospital, Sapporo, Hokkaido, Japan

Corresponding author

Kosuke Iwano, MD
Center for Gastroenterology, Teine-Keijinkai Hospital, 1-40, 12-chome, 1-jou, Maeda, Teine-ku, Sapporo 006-0811, Hokkaido, Japan
ksk.own@gmail.com

References

- [1] Tarnasky PR, Cotton PB, Baillie J et al. Proximal migration of biliary stents: attempted endoscopic retrieval in forty-one patients. *Gastrointest Endosc* 1995; 42: 513–520doi:10.1016/s0016-5107(95)70003-x
- [2] Abdelgelil A, Kumbhari V, Tieu AH et al. Snare-over-scope technique for retrieval of a proximally migrated biliary stent. *Endoscopy* 2014; 46: E650–E651doi:10.1055/s-0034-1390847
- [3] Mangiavillano B, Masci E. An obstructive, proximally migrated plastic biliary stent extracted with a “modified” Seldinger technique and a polypectomy snare. *Endoscopy* 2007; 39: E256doi:10.1055/s-2007-966478
- [4] Bas-Cutrina F, Garcia-Sumalla A, Velasquez J et al. Removal of a migrated biliary stent using new digital cholangioscopy retrieval devices in a transplant patient. *Endoscopy* 2019; 51: E323–E324doi:10.1055/a-0916-8490

Bibliography

Endoscopy 2022; 54: E1074–E1075
DOI 10.1055/a-1915-4738
ISSN 0013-726X
published online 1.9.2022
© 2022. The Author(s).

This is an open access article published by Thieme under the terms of the Creative Commons Attribution-NonDerivative-NonCommercial License, permitting copying and reproduction so long as the original work is given appropriate credit. Contents may not be used for commercial purposes, or adapted, remixed, transformed or built upon. (<https://creativecommons.org/licenses/by-nc-nd/4.0/>)
Georg Thieme Verlag KG, Rüdigerstraße 14, 70469 Stuttgart, Germany



ENDOSCOPY E-VIDEOS
<https://eref.thieme.de/e-videos>



Endoscopy E-Videos is an open access online section, reporting on interesting cases and new techniques in gastroenterological endoscopy. All papers include a high quality video and all contributions are freely accessible online. Processing charges apply (currently EUR 375), discounts and waivers acc. to HINARI are available.

This section has its own submission website at
<https://mc.manuscriptcentral.com/e-videos>