

Diagnosis and Management of Multiple Endocrine Neoplasia Type 1 (MEN1)

Koen M.A. Dreijerink, Cees J.M. Lips

Department of Endocrinology, University Medical Centre, Utrecht, the Netherlands

Key words: multiple endocrine neoplasia type 1, MEN1, mutation analysis, periodical monitoring, menin

Corresponding author: Cees J.M. Lips; University Medical Centre Utrecht, Department of Endocrinology, PO Box 85.500, 3508 GA, Utrecht, the Netherlands, phone: +31 30 250 91 11, e-mail: c.j.m.lips@azu.nl

This article has originally been published in Dutch in the Dutch Journal of Oncology (Nederlands Tijdschrift voor Oncologie; Ned Tijdschr Oncol 2004; 1 (5): 171-177) and is reprinted with the permission of Ariez Medical Publishing, Amsterdam, the Netherlands.

Koen Dreijerink is supported by the Netherlands Organisation for Health Research and Development (ZonMw; AGIKO-stipendium).

Submitted: 31 January 2005

Accepted: 10 February 2005

Abstract

Multiple endocrine neoplasia type 1 (MEN1) is an autosomal dominantly inherited disorder, characterised by the occurrence of tumours of the parathyroid glands, the pancreatic islets, the pituitary gland, the adrenal glands and neuroendocrine carcinoid tumours. Carcinoid tumours of the thymus and pancreatic-duodenal gastrinomas are the most harmful tumour types, since these tumours have malignant potential and curative treatment is difficult to achieve.

MEN1 is caused by germline mutations of the MEN1 tumour suppressor gene. Mutation analysis enables mutation carriers to be identified. MEN1 patients and their family members, family members of mutation carriers and patients who are clinically suspected to be carriers of a MEN1 gene mutation are eligible for mutation analysis. MEN1-associated tumours can be detected and treated at an early stage through periodical clinical monitoring of mutation carriers.

Introduction

Multiple endocrine neoplasia type 1 (MEN1) is an autosomal dominantly inherited syndrome. MEN1 is characterised by the occurrence of tumours of the parathyroid glands, the pancreatic islets, the anterior pituitary gland and the adrenal glands, as well as neuroendocrine carcinoid tumours, often at a young age. Non-endocrine manifestations of MEN1 include angiofibromas, collagenomas, lipomas and leiomyomas (Table 1). The prevalence of MEN1 is 2-3 per 100,000, and is equal among males and females.

MEN1 and multiple endocrine neoplasia type 2 (MEN2) are two distinct syndromes. In MEN2, patients frequently develop medullary thyroid carcinoma and pheochromocytoma.

MEN1 is caused by germline mutations of the MEN1 gene [1, 2]. Since the discovery of the gene in 1997, mutation analysis has become available. Carriers of a MEN1 gene germline mutation can be monitored periodically to identify MEN1-associated lesions at a presymptomatic stage.

In this report, we give an overview of the recent developments concerning the aetiology of MEN1 as

Table 1. The variable expression of MEN1. Percentages of MEN1 germline mutation carriers that develop a MEN1-associated tumour. ACTH: adrenocorticotropic hormone

Parathyroid adenomas	75-95%
Pancreatic islet cell tumours	70%
Gastrinomas	45%
Insulinomas	10%
Non-functioning (including pancreatic polypeptide producing tumours)	10%
Other	2%
Pituitary adenomas	47%
Prolactinomas	30%
Non-functioning (i.e. not producing hormone)	10%
ACTH producing	1%
GH producing	3-6%
Adrenal adenomas	20%
Carcinoid tumours	18%
Thymus	8%
Bronchial	8%
Stomach	5%
Skin lesions	80%
Angiofibromas	75%
Collagenomas	5%
Lipomas	30%
Leiomyomas	5%

well as the current diagnostic and therapeutic options. Furthermore, we provide guidelines for MEN1 mutation analysis and periodical clinical monitoring.

Clinical manifestations, diagnosis and treatment

The clinical definition of a MEN1 patient we use is a patient with three or more of the five major MEN1-associated lesions (i.e. tumours of the parathyroid glands, the endocrine pancreas, the pituitary gland, the adrenal glands, and neuroendocrine carcinoid tumours).

A suspected MEN1 patient is defined as having two major MEN1-associated lesions, multiple lesions within one organ, and/or a lesion at a young age (<35 years) [3].

Below, for each tumour type the clinical presentation and the diagnostic and therapeutic options are listed. In Figure 1, flow charts are shown for diagnosis and therapy of MEN1-associated parathyroid adenoma, tumours of the pancreatic islets and pituitary adenoma.

Parathyroid adenoma

Parathyroid adenomas (Fig. 1A) are often the first manifestation of MEN1. 75-95% of MEN1 patients develop parathyroid adenomas [4, 5]. The increased production of parathyroid hormone causes hypercalcaemia. Fatigue, depression, constipation, nausea, symptoms caused by nephrolithiasis or nephrocalcinosis, bone pain, myalgia and arthralgia as well as hypertension may all be signs and symptoms of hypercalcaemia.

Laboratory investigation consists of measurement of ionised calcium, chloride, phosphate and parathyroid hormone. In addition to this, the 24-hour calcium excretion in the urine is measured. Bone densitometry can be used to detect bone mass reduction.

Van Dalen et al showed that parathyroid adenomas can be effectively localised by ultrasound, supplemented with computed tomography (CT) [6]. Alternatively, a scan can be made with Tc-99m sestamibi that is retained selectively by parathyroid adenomas.

Usually, parathyroid adenomas in MEN1 are benign. When a tumour causes hypercalcaemia, it is surgically removed, preferably in a minimally invasive procedure. If this is not possible, a conventional neck exploration can be performed [7].

Tumours of the endocrine pancreas

Tumours of the endocrine pancreas (Fig. 1B) develop in about 70% of MEN1 patients [8]. Gastrinomas are the most common pancreatic tumour in MEN1. The elevated levels of gastrin cause excessive gastric acid production. If untreated, this can lead to the Zollinger-Ellison syndrome: ulcerations of the digestive tract, diarrhoea, and mucosal hypertrophy. Before treatment with proton pump inhibitors became available, the Zollinger-Ellison syndrome was a frequent cause of death of MEN1 patients. Gastrinomas are still an important threat to MEN1 patients, because they are often multicentric and are able to metastasise to the lymph nodes and the liver [9].

Insulinomas and glucagonomas affect blood glucose levels. Besides, glucagonomas can cause skin lesions. Tumours producing vasoactive intestinal peptide (VIP), VIPomas, can cause the Verner-Morrison syndrome, or watery-diarrhoea-hypokalemia-achlorhydria (WDHA)

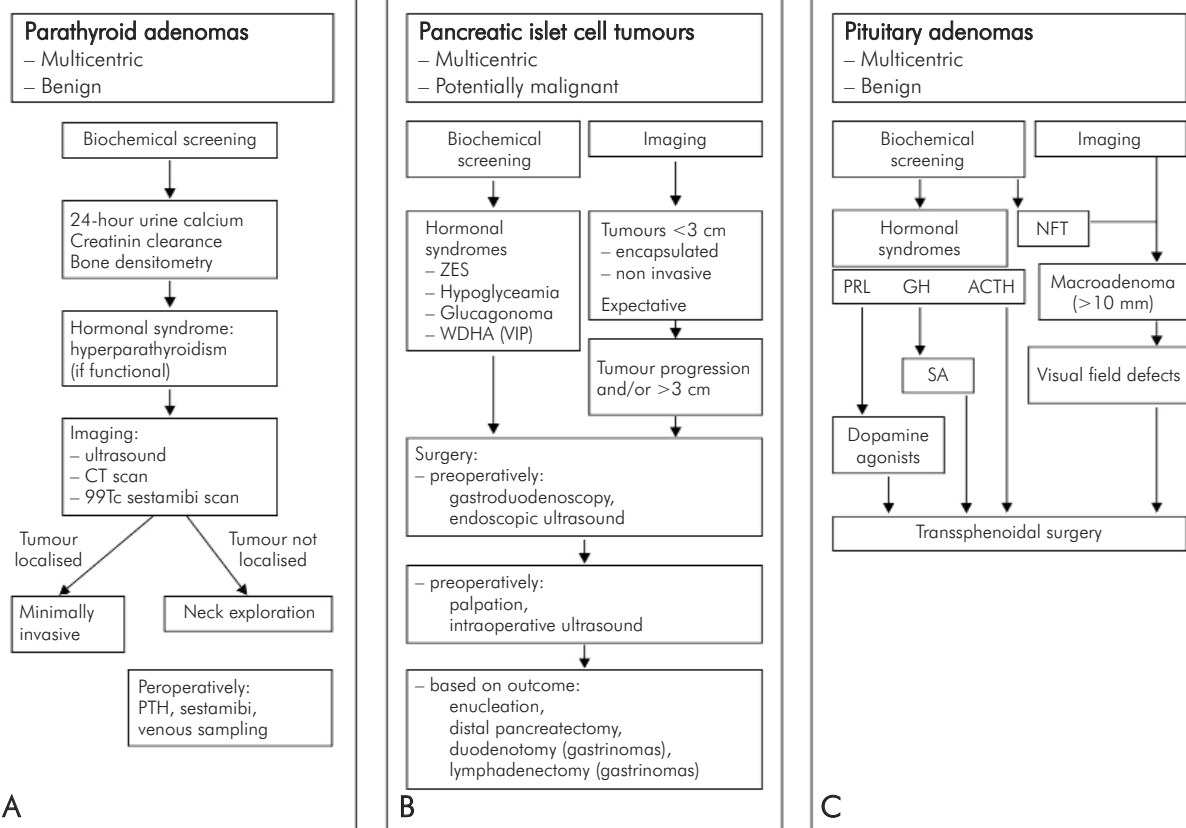


Fig. 1. Recommendations for diagnosis and management of parathyroid adenomas (A), pancreatic islet cell tumours (B), and pituitary adenomas (C) in MEN1 patients.

PTH: parathyroid hormone; CT: computed tomography; ZES: Zollinger-Ellison syndrome; WDHA: watery diarrhoea, hypokalemia, achlorhydria; VIP: vasoactive intestinal peptide; NFT: non-functioning tumour; PRL: prolactin; GH: growth hormone; ACTH: adrenocorticotropic hormone; SA: somatostatin analogues

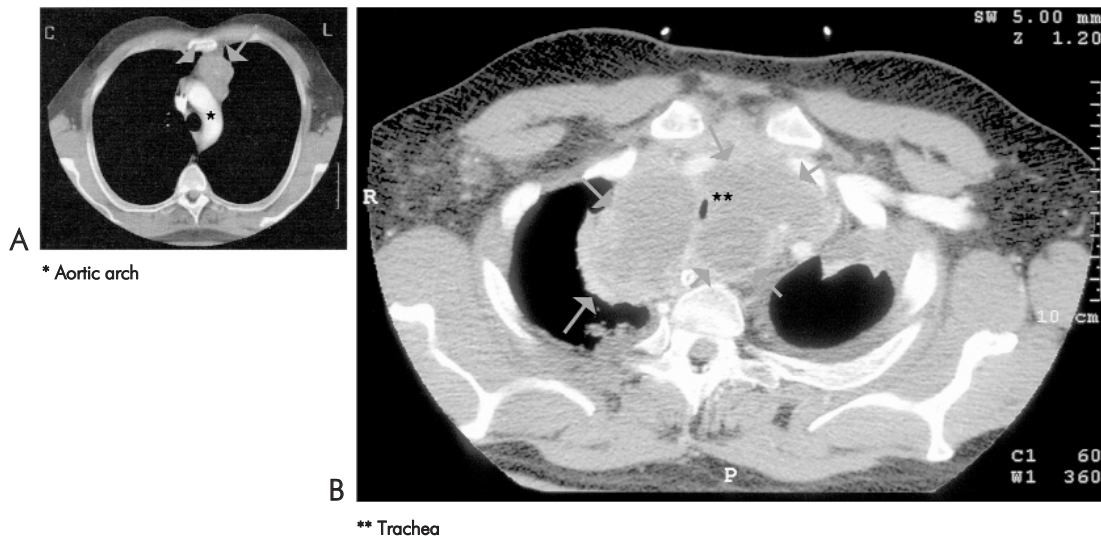


Fig. 2. (A) CT imaging of a 42-year-old MEN1 patient. A lesion is present in the mediastinum (indicated with green arrows). The lesion turned out to be a carcinoid tumour of the thymus. Due to invasive growth into the pleura the tumour could not be completely removed. (B) Chest CT of the same patient, five years later. The tumour in the upper mediastinum has expanded; there is compression of the trachea. The patient died from respiratory failure

syndrome. Laboratory investigation includes glucose, insulin, c-peptide, glucagon, gastrin, and pancreatic polypeptide. Pancreatic islet cell tumours can be visualised by magnetic resonance imaging (MRI), somatostatin receptor scintigraphy (SRS), or CT. Surgery is required when the tumour is causing a functional syndrome. If a gastrinoma is larger than 3 cm in diameter and/or is progressively expanding, the tumour and the peripancreatic lymph nodes should be resected and a duodenotomy should be carried out to assess the presence of duodenal tumours [8]. Surgical excision of glucagonomas, insulinomas and VIPomas is usually curative. Tumours producing pancreatic polypeptide are common, but only rarely cause symptoms and therefore do normally not require treatment.

Pituitary adenomas

The most frequently occurring pituitary tumours in MEN1 are prolactinomas (Fig. 1C). Non-functioning tumours, growth hormone, or adrenocorticotrophic hormone (ACTH) producing tumours and mixed tumours are seen less frequently. Symptoms such as visual field defects, headache, or a decrease of other pituitary functions may develop because of compression by the expanding tumour. Elevated levels of prolactin may cause amenorrhoea, galactorrhoea, and lack of libido in females and hypogonadism in males. Acromegaly, caused by a growth hormone producing tumour, is observed in 3-6% of MEN1 patients. Patients present with enlarged hands or feet, coarse facial features or soft-tissue growth. Patients with acromegaly have an increased risk of developing cardiovascular disease and malignancy. The diagnosis is confirmed by determining insulin like growth factor I (IGF-I) levels and by an oral glucose tolerance test. Pituitary adenomas can be detected by MR imaging with gadolinium contrast. If the adenoma has a diameter larger than 10 mm, or if there is visual field loss, a patient is eligible for transsphenoidal surgery. Dopamine suppresses prolactin secretion. Hence, the primary treatment of prolactinomas consists of dopamine receptor agonists such as bromocriptine, quinagolide or cabergoline. GH producing cells express the somatostatin receptor. Somatostatin is a repressor of GH secretion, so somatostatin analogues are the first choice of treatment of acromegaly. If the results are insufficient, surgery should be considered. ACTH producing adenomas are removed operatively.

Adrenal tumours

About 20% of MEN1 patients develop adrenal tumours. These tumours are often detected during

screening of the upper abdomen. Like sporadic incidentalomas of the adrenals, these tumours usually do not produce hormones and are mostly benign. However, when a tumour is larger than 4 cm in diameter, there is an increased risk of malignancy and the tumour should be resected [8, 10].

Neuroendocrine carcinoid tumours

Carcinoid tumours are tumours of neuroendocrine origin. In MEN1, carcinoid tumours arise from cells that are derived from the embryonic foregut. Carcinoid tumours in MEN1 can develop in the thymus (mostly in males), in the lungs (mostly in females), and in the stomach or the pancreas.

Carcinoid tumours in MEN1 usually do not cause symptoms until at an advanced stage. As these tumours are capable of infiltrating surrounding tissues and metastasising, and treatment is very difficult, early detection of these tumours is important (Fig. 2) [9, 11].

Carcinoid tumours produce a vast spectrum of amines, peptides and prostaglandins. Carcinoid tumours in MEN1 do not release serotonin (5HT), but do produce 5-hydroxytryptophan (5-HTP), the precursor of serotonin. The 5-HTP is partially converted into serotonin in the kidneys. Levels of platelet serotonin and chromogranin A are useful markers. The level of 5-hydroxyindoleacetic acid (5-HIAA) in the 24-hour urine of MEN1 patients with carcinoid tumours usually is not elevated. Tumours can be detected using MRI, SRS or CT. Carcinoid tumours in MEN1 are always treated surgically. For prevention, when parathyroid adenomas are removed during a neck dissection, the thymus could be removed at the same time.

Aetiology of MEN1

MEN1 is caused by inactivating germline mutations of the MEN1 gene, which is located on chromosome 11q13 [1, 2]. The MEN1 gene is a tumour suppressor gene. In accordance with Knudson's "two-hit theory", biallelic inactivation of the MEN1 gene is required for the development of a tumour cell [12]. Loss of the wild type allele (loss of heterozygosity) is observed frequently in MEN1-associated tumours in MEN1 patients.

Since the discovery of the gene, more than 400 different germline mutations have been identified in MEN1 families. These mutations are found scattered throughout the gene. Also in sporadic MEN1-associated tumours mutations of the MEN1 gene have been found, which suggests that inactivation of the MEN1 gene contributes to the development of these tumours.

No clear genotype-phenotype correlation has been established. The expression of the disease is variable,

Table 2. Criteria for MEN1 mutation analysis and guidelines for periodical clinical monitoring

Criteria for mutation analysis
<p>MEN1 mutation analysis is offered to:</p> <ul style="list-style-type: none"> – MEN1 patients: patients with three of the five major MEN1-associated lesions: parathyroid adenomas, pancreatic islet cell tumours, pituitary adenomas, adrenal adenomas, neuroendocrine carcinoid tumours; – First degree family members (parents, brothers, sisters, children) of MEN1 patients with a confirmed MEN1 germline mutation, family members of clinical MEN1 patients without an identified germline mutation or who declined mutation analysis; – First degree family members of asymptomatic MEN1 germline mutation carriers; – Suspected MEN1 patients: patients with two of the five major lesions, two MEN1-associated tumours within one organ and/or a MEN1-associated lesion at a young age (<35 years).
Periodical clinical monitoring
<p>MEN1 patients, MEN1 gene germline mutation carriers and suspected MEN1 patients without a confirmed mutation are eligible for periodical clinical monitoring.</p>
<p>This includes:</p> <p>From the age of five: biannual clinical examination, laboratory investigation including measurement of ionised calcium, chloride, phosphate, parathyroid hormone, glucose, insulin, c-peptide, glucagon, gastrin, pancreatic polypeptide, prolactin, insulin like growth factor 1 (IGF-I), platelet serotonin and chromogranin A.</p>
<p>From the age of 15: once every two years:</p> <ul style="list-style-type: none"> Magnetic resonance imaging (MRI) of the upper abdomen MRI of the pituitary with gadolinium contrast MRI of the mediastinum in males

even within families. However, some MEN1 gene mutations seem to be causing familial isolated hyperparathyroidism or a variant MEN1 that is characterised by the frequent occurrence of prolactinoma [13, 14]. Thus, additional genetic events may play a role in MEN1-associated tumorigenesis.

The MEN1 gene encodes the menin protein. Menin is expressed ubiquitously, predominantly in the nucleus. Menin is a regulator of gene transcription. It has been reported to interact with several transcription factors such as JunD and NF-kappaB [15, 16]. Modifications of histones, the proteins to which DNA is bound, are important for the function of menin [17, 18]. Recently, the telomerase (hTERT) gene was identified as a menin target gene [19]. The ends of chromosomes in a cell, the telomeres shorten after DNA replication. Eventually, after several cell divisions, the DNA loses its stability and the cell is subjected to apoptosis. Telomerase is an enzyme that maintains the length of the telomeres. Telomerase is not expressed in normal cells, but it is active in stem cells and tumour cells. Menin is a suppressor of the expression of telomerase. Possibly, inactivation of menin could lead to cell immortalisation, which could allow a cell to develop into a tumour cell.

Further insight into the mechanisms that underlie MEN1-associated tumorigenesis may provide opportunities for new therapeutic strategies.

MEN1 mutation analysis

Roijers et al found germline mutations in the MEN1 gene in 100% of clinical MEN1 patients by sequence analysis [3]. Besides MEN1 patients, first degree family members (parents, brothers, sisters, children) of MEN1 patients, and family members of MEN1 mutation carriers are eligible for mutation analysis.

A small percentage of patients with apparently sporadic MEN1-associated lesions turn out to be carriers of MEN1 germline mutation. To be able to identify these patients, without screening the entire group of patients with apparently sporadic tumours, the above-mentioned criteria for suspected MEN1 patients were created. In 60% of suspected MEN1 patients a germline mutation of the MEN1 gene has been found [3].

The earliest manifestation of MEN1 reported is a pituitary adenoma in a five-year-old boy. Therefore, in principle, mutation analysis could be performed from the age of five [20].

Periodical clinical monitoring

MEN1 patients and their family members can be monitored periodically. The investigation is aimed at identification of MEN1-associated lesions and includes, besides the patient's history and physical examination, biochemical screening and imaging. The protocol for periodical clinical monitoring is shown in Table 2.

Conclusion

MEN1 is an inherited disorder with a variable presentation, often at a young age. The initial symptoms of MEN1-associated lesions may be very general. By using stringent criteria MEN1 patients can be identified efficiently. Mutation analysis enables MEN1 gene mutation carriers to be identified. Gastrinomas and carcinoid tumours have malignant potential. Periodical clinical monitoring makes presymptomatic detection and treatment of MEN1-associated tumours possible. This will be beneficial for both life expectancy and quality of life of MEN1 patients.

References

- Chandrasekharappa SC, Guru SC, Manickam P, Olufemi SE, Collins FS, Emmert-Buck MR, Debelenko LV, Zhuang Z, Lubensky IA, Liotta LA, Crabtree JS, Wang Y, Roe BA, Weisemann J, Boguski MS, Agarwal SK, Kester MB, Kim YS, Heppner C, Dong Q, Spiegel AM, Burns AL and Marx SJ. Positional cloning of the gene for multiple endocrine neoplasia-type 1. *Science* 1997; 276 (5311): 404-407.
- Lemmens I, Van de Ven WJ, Kas K, Zhang CX, Giraud S, Wautot V, Buisson N, De Witte K, Salandre J, Lenoir G, Pugeat M, Calender A, Parente F, Quincey D, Gaudray P, De Wit MJ, Lips CJ, Hoppener JW, Khodaei S, Grant AL, Weber G, Kytola S, Teh BT, Farnebo F, Thakker RV, et al. Identification of the multiple endocrine neoplasia type 1 (MEN1) gene. The European Consortium on MEN1. *Hum Mol Genet* 1997; 6 (7): 1177-1183.
- Roijers JF, de Wit MJ, van der Luijt RB, Ploos van Amstel HK, Hoppener JW and Lips CJ. Criteria for mutation analysis in MEN 1-suspected patients: MEN 1 case-finding. *Eur J Clin Invest* 2000; 30 (6): 487-492.
- Trump D, Farren B, Wooding C, Pang JT, Besser GM, Buchanan KD, Edwards CR, Heath DA, Jackson CE, Jansen S, Lips K, Monson JP, O'Halloran D, Sampson J, Shalet SM, Wheeler MH, Zink A and Thakker RV. Clinical studies of multiple endocrine neoplasia type 1 (MEN1). *QJM* 1996; 89 (9): 653-669.
- Carty SE, Helm AK, Amico JA, Clarke MR, Foley TP, Watson CG and Mulvihill JJ. The variable penetrance and spectrum of manifestations of multiple endocrine neoplasia type 1. *Surgery* 1998; 124 (6): 1106-1113; discussion 1113-1114.
- Van Dalen A, Smit CP, van Vroonhoven TJ, Burger H and de Lange EE. Minimally invasive surgery for solitary parathyroid adenomas in patients with primary hyperparathyroidism: role of US with supplemental CT. *Radiology* 2001; 220 (3): 631-639.
- Van Vroonhoven TJ. [Surgical treatment of primary hyperparathyroidism: minimally invasive if possible, conventional neck exploration if necessary]. *Ned Tijdschr Geneesk* 2002; 146 (37): 1735-1739.
- Thompson NW. Current concepts in the surgical management of multiple endocrine neoplasia type 1 pancreatic-duodenal disease. Results in the treatment of 40 patients with Zollinger-Ellison syndrome, hypoglycaemia or both. *J Intern Med* 1998; 243 (6): 495-500.
- Geerdink EA, Van der Luijt RB and Lips CJ. Do patients with multiple endocrine neoplasia syndrome type 1 benefit from periodical screening? *Eur J Endocrinol* 2003; 149 (6): 577-582.
- Grumbach MM, Biller BM, Braunstein GD, Campbell KK, Carney JA, Godley PA, Harris EL, Lee JK, Oertel YC, Posner MC, Schlechte JA and Wieand HS. Management of the clinically inapparent adrenal mass ('incidentaloma'). *Ann Intern Med* 2003; 138 (5): 424-429.
- Gibril F, Chen YJ, Schrupp DS, Vortmeyer A, Zhuang Z, Lubensky IA, Reynolds JC, Louie A, Entsuah LK, Huang K, Asgharian B and Jensen RT. Prospective study of thymic carcinoids in patients with multiple endocrine neoplasia type 1. *J Clin Endocrinol Metab* 2003; 88 (3): 1066-1081.
- Knudson AG, Jr. Mutation and cancer: statistical study of retinoblastoma. *Proc Natl Acad Sci USA* 1971; 68 (4): 820-823.
- Panneff AA, Kennedy AM, Turner JJ, Forbes SA, Cavaco BM, Bassett JH, Cianferotti L, Harding B, Shine B, Flinter F, Maidment CG, Trembath R and Thakker RV. Multiple endocrine neoplasia type 1 (MEN1) germline mutations in familial isolated primary hyperparathyroidism. *Clin Endocrinol (Oxf)* 2003; 58 (5): 639-646.
- Olufemi SE, Green JS, Manickam P, Guru SC, Agarwal SK, Kester MB, Dong Q, Burns AL, Spiegel AM, Marx SJ, Collins FS and Chandrasekharappa SC. Common ancestral mutation in the MEN1 gene is likely responsible for the prolactinoma variant of MEN1 (MEN1Burin) in four kindreds from Newfoundland. *Hum Mutat* 1998; 11 (4): 264-269.
- Agarwal SK, Guru SC, Heppner C, Erdos MR, Collins RM, Park SY, Saggari S, Chandrasekharappa SC, Collins FS, Spiegel AM, Marx SJ and Burns AL. Menin interacts with the AP1 transcription factor JunD and represses JunD-activated transcription. *Cell* 1999; 96 (1): 143-152.
- Heppner C, Bilimoria KY, Agarwal SK, Kester M, Whitty LJ, Guru SC, Chandrasekharappa SC, Collins FS, Spiegel AM, Marx SJ and Burns AL. The tumor suppressor protein menin interacts with NF-kappaB proteins and inhibits NF-kappaB-mediated transactivation. *Oncogene* 2001; 20 (36): 4917-4925.
- Gobl AE, Berg M, Lopez-Egido JR, Oberg K, Skogseid B and Westin G. Menin represses JunD-activated transcription by a histone deacetylase-dependent mechanism. *Biochim Biophys Acta* 1999; 1447 (1): 51-56.
- Hughes CM, Rozenblatt-Rosen O, Milne TA, Copeland TD, Levine SS, Lee JC, Hayes DN, Shanmugam KS, Bhattacharjee A, Biondi CA, Kay GF, Hayward NK, Hess JL and Meyerson M. Menin associates with a trithorax family histone methyltransferase complex and with the *hoxc8* locus. *Mol Cell* 2004; 13 (4): 587-597.
- Lin SY and Elledge SJ. Multiple tumor suppressor pathways negatively regulate telomerase. *Cell* 2003; 113 (7): 881-889.
- Stratakis CA, Schussheim DH, Freedman SM, Keil MF, Pack SD, Agarwal SK, Skarulis MC, Weil RJ, Lubensky IA, Zhuang Z, Oldfield EH and Marx SJ. Pituitary macroadenoma in a 5-year-old: an early expression of multiple endocrine neoplasia type 1. *J Clin Endocrinol Metab* 2000; 85 (12): 4776-4780.