

SYSTEMATIC REVIEW

Open Access



Chondral injuries in patients with recurrent patellar dislocation: a systematic review

Filippo Migliorini^{1*}, Emanuela Marsilio², Francesco Oliva², Jörg Eschweiler¹, Frank Hildebrand¹ and Nicola Maffulli^{2,3,4}

Abstract

Background: Patellar dislocations in patients presenting with recurrent patellofemoral instability can damage the surrounding structures, limiting patient's participation to recreational activities and quality of life. This study evaluated frequency, location, and extent of associated injuries in patients with recurrent patellar dislocation.

Methods: This systematic review was conducted according to the PRISMA checklist. PubMed, Google scholar, Embase, and Web of Science databases were accessed in July 2021. All the published clinical studies reporting frequency, location, and extent of soft tissue lesions in patients with recurrent patellar dislocations were accessed.

Results: Data from 9 articles (232 patients) were retrieved. The mean age of the included patients was 21.2 ± 5.6 years. 84.8% of patients suffering from recurrent patellar dislocations demonstrated patellar chondral defects: medial facet (34.9%), while patellar crest (34.8%) and lateral facet (17%). 27.8% of patients demonstrated trochlear chondral injuries.

Conclusion: Chondral defects of the medial facet and the crest of the patella are the most common in patients with recurrent patellofemoral instability.

Keywords: Patellar dislocation, Chondral damage, Soft tissues

Introduction

Recurrent patellofemoral instability is common, especially among the active and young population [1, 2]. Its aetiology is multifactorial [3, 4]. Several pathoanatomical factors which predispose to instability have been described, such as patella alta, dysplasia, mal-alignment syndromes, and leg axis deformities [5–9]. Irrespective of the aetiopathogenesis, most of patients experience recurrent episodes of patellar dislocation [10, 11]. Recurrent patellar dislocations may damage the articular surface, generating chondral or osteochondral defects [12]. Chondral injuries may cause persistent pain, limiting knee function and impairing the patients' quality of life

[13–15]. Controversies regarding the frequency, extent, and location of chondral lesions exist [16–18]. Previous studies reported that many patients with recurrent patellofemoral instability evidenced chondral defects and osteochondral fractures on the medial facet of the patella and on the lateral trochlea [19–21]. However, the evidence with regard of frequency, location, and extent chondral damages in patients with recurrent patellofemoral instability are limited and no previous systematic review has been published [22–30]. This systematic review evaluated the frequency, location, and extent chondral damages in patients with recurrent patellofemoral instability.

Material and methods

Search strategy

This systematic review was conducted according to the Preferred Reporting Items for Systematic Reviews and

*Correspondence: migliorini.md@gmail.com

¹ Department of Orthopedic, Trauma, and Reconstructive Surgery, RWTH Aachen University Hospital, Pauwelsstraße 30, 52074 Aachen, Germany
Full list of author information is available at the end of the article



© The Author(s) 2022. **Open Access** This article is licensed under a Creative Commons Attribution 4.0 International License, which permits use, sharing, adaptation, distribution and reproduction in any medium or format, as long as you give appropriate credit to the original author(s) and the source, provide a link to the Creative Commons licence, and indicate if changes were made. The images or other third party material in this article are included in the article's Creative Commons licence, unless indicated otherwise in a credit line to the material. If material is not included in the article's Creative Commons licence and your intended use is not permitted by statutory regulation or exceeds the permitted use, you will need to obtain permission directly from the copyright holder. To view a copy of this licence, visit <http://creativecommons.org/licenses/by/4.0/>. The Creative Commons Public Domain Dedication waiver (<http://creativecommons.org/publicdomain/zero/1.0/>) applies to the data made available in this article, unless otherwise stated in a credit line to the data.

Meta-Analyses: the PRISMA guidelines [31]. The literature search was guided by the following points:

- Problem: recurrent patellar dislocation;
- Outcome: soft tissue injuries.

Literature search

Two independent authors (**,**) performed the literature search in July 2021. PubMed, Google Scholar, Embase, and Web of Science were accessed to identify suitable articles. The database search was performed without filters and time constraints, using the Boolean operators AND/OR. The following keywords were used in combination: *patella, dislocation, recurrent, instability, soft tissue, chondral, articular, cartilage, lesion, osteochondral, injury, arthroscopy, medial patellofemoral ligament, MPFL, damage, insertion, rupture, Outerbridge, and International Cartilage Repair Society, ICRS*. The same authors performed the initial screening of the resulting titles from the search in a separate fashion and accessed the full text of the articles of interest. The bibliographies of the full-text articles were screened by hand for identify further eligible articles. Any disagreements were discussed and settled by consensus.

Eligibility criteria

All the published clinical studies which reported quantitative data on frequency, location, and extent of chondral injuries in patients with recurrent patellar dislocations were considered. Given the authors language capabilities, articles in English, German, Italian, French, and Spanish were eligible. Level I–IV of evidence, according to Oxford Centre of Evidence-Based Medicine [32], was considered. Reviews, technical notes, comments, letters, editorials, protocols, and guidelines were not eligible, nor were biomechanical, animal, and cadaveric studies. Studies reporting data on habitual, congenital, and/or acute patellofemoral instability were excluded. Studies involving patients who underwent previous patellofemoral surgical procedures were also not eligible. Missing information on the endpoints of interest warranted the exclusion from this study.

Outcomes of interest

Data extraction was performed by two authors (**,**). Studies generalities were collected: author, year, journal, study design, number of patients, and mean age. Arthroscopy findings were also collected: type, location, and extent of trochlear and patellar chondral injuries. The International Cartilage Repair Society (ICRS) [33] was used to classify the arthroscopic findings.

Methodology quality assessment

Two authors (**,**) independently assessed the methodological quality using the Newcastle–Ottawa Scale (NOS) [34]. NOS was used to assess methodological quality of the included studies. A 'star system' was applied, in which a study is judged on three broad perspectives: the selection of the study groups; the comparability of the groups; and the observation of either the exposure or outcome of interest for case–control or cohort studies respectively. Mean values of 2 stars in selection, 1 or 2 stars in comparability, and 2 or 3 stars in outcomes were considered satisfactory.

Results

Search result

The literature search resulted in 915 articles. Of these, 310 were excluded being duplicates. Another 380 were not eligible: not matching the topic ($N=220$), study design ($N=90$), acute patellofemoral instability ($N=45$), language limitation ($N=10$), and uncertain results ($N=15$). This left 225 articles for inclusion. A further 216 articles were excluded because lack of data under the outcomes of interest. Finally, 9 articles were considered for the analysis (Fig. 1).

Methodological quality assessment

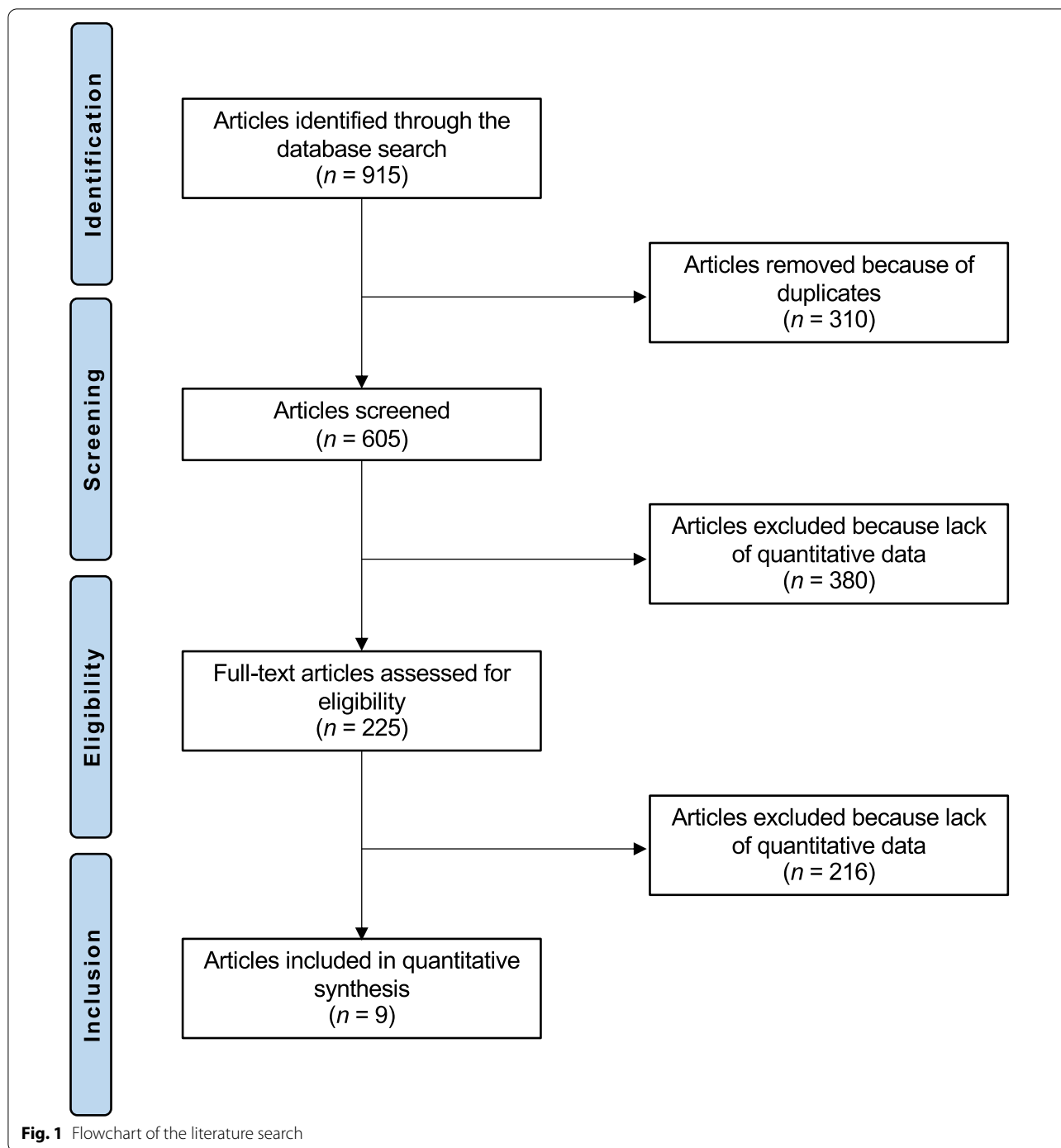
The satisfactory size of the included studies, their baseline comparability, and adequate length of the follow-up are the most important strengths of this analysis. The most important limitations evidenced by the NOS are the lack of randomization and blinding, along with high the high risk of bias during allocation concealment. Concluding, the NOS resulted in 3 or 4 stars in selection, 1 or 2 stars in comparability, and 2 or 3 stars in outcomes in all of the selected articles, attesting to this study good quality of the methodological assessment (Table 1).

Patient demographics

A total of 232 patients were identified, with a mean age of 21.2 ± 5.6 . Study generalities and patient demographics of the included studies are shown in Table 2.

Main findings

84.8% of patients demonstrated patellar chondral defects: 34.9% in the medial facet, 17.0% in the lateral facet, and 34.8% in the patellar crest. Concerning the medial facet, defects were ICRS grade I in 11.1%, grade II in 14.8%, grade III in 9.3%, and grade IV in 9.3%. Concerning the lateral facet, defects were ICRS grade I in 9.3%, grade II in 11.1%, grade III in 3.7%, and grade IV in 4.3%. Concerning the patellar crest, defects were ICRS grade I in 9.7%, grade II in 25.8%, grade III in 6.5%, and grade IV in 19.0%. 27.8%



of patients demonstrated trochlear chondral defects. These defects were ICRS grade I in 19.2%, grade II in 16.7%, grade III in 5.1%, and grade IV in 7.0%. Table 3 resumes the main findings of the included studies.

Discussion

According to the main findings of the present systematic review, 84.8% of patients suffering from recurrent patellar dislocation demonstrated chondral defects of the patella. Defects are more frequently located on the medial facet (34.9%), while patellar crest (34.8%) and lateral facet

Table 1 Methodological quality assessment

References	Selection	Comparability	Outcome
Boddula et al. [22]	****	**	***
Chan et al. [23]	****	*	**
Franzone et al. [24]	****	**	**
Gaweda et al. [25]	****	**	***
Kita et al. [26]	****	**	***
Lee et al. [27]	****	**	***
Luhmann et al. [28]	****	*	**
Maffulli et al. [29]	****	**	***
Nha et al. [30]	****	**	***

(17%) are less injured. Trochlear chondral injuries were evidenced in 27.8% of patients.

In patients with recurrent patellar instability, arthroscopy may be performed as diagnostic and therapeutic tool [35]. Franzone et al. [24] investigated the association between recurrent patellar instability and the location,

frequency, and grade of chondral lesions. 57.9% (22/38) of the patients suffering from recurrent dislocations presented advanced chondral lesions in the patella, mostly located on the medial patellar facet [24]. Boddula et al. [22] reported that 45% (9/20) of patients with recurrent patellar instability had chondral lesions. Moreover, concomitant chondral lesions were also associated with lower values in patients reported outcome measures (PROMs) and early onset osteoarthritis [22].

Several surgical strategies are available to manage chondral defects. Microfractures (Mxs) are indicated for smaller defects [36, 37]. Autologous chondrocyte implantation (ACI) has been also widely used for larger chondral defects [38, 39]. However, ACI requires a chondrocyte harvest site, two surgical sessions, and cells expansion in a dedicated laboratory [40, 41]. These features lead to longer recovery, increasing morbidity and the health care burden [42, 43]. To overcome these limitations, autologous matrix-induced chondrogenesis (AMIC) has been introduced [44, 45]. AMIC exploits the regenerative potential of autologous bone marrow derived

Table 2 Study generalities and patient demographics of the included studies

References	Journal name	Design	Knees	Mean age
Boddula et al. [22]	Am J Sports Med	Retrospective	20	28.0
Chan et al. [23]	Knee Surg Sports Traumatol	Retrospective	1	12.0
Franzone et al. [24]	J Knee Surg	Retrospective	38	21.0
Gawada et al. [25]	Int Orthop	Prospective	19	25.5
Kita et al. [26]	J Orthop Sci	Retrospective	31	20.0
Lee et al. [27]	Knee Surg Sports Traumatol	Retrospective	28	20.0
Luhmann et al. [28]	J Pediatr Orthop	Retrospective	38	14.9
Maffulli et al. [29]	Injury	Prospective	34	25.6
Nha et al. [30]	Am J Sports Med	Retrospective	23	26.0

Table 3 Main findings of the included studies

References	Main findings
Boddula et al. [22]	Seven patients showed chondral lesions, located at medial and lateral patellar facet, while one patient reported an associated lateral trochlea chondral lesion
Chan et al. [23]	Chondral fracture and a lateral trochlea chondral lesion were found in one patient
Franzone et al. [24]	Twenty patients had patellar chondral lesions, while five patients reported lateral trochlea defects
Gaweda et al. [25]	Nineteen patients had severe and extensive patellar chondral defects
Kita et al. [26]	Twenty-seven patients reported patellar lesions, while eight showed lateral trochlea chondral defects, after MPFL rupture
Lee et al. [27]	After MPFL reconstruction, 26 patients presented patellar chondral lesions, while 16 patients had lateral trochlea lesions
Luhmann et al. [28]	Patellar osteochondral lesions were present in 30 knees, femoral lesions were documented in 11 knees, and loose bodies were present in 6 knees
Maffulli et al. [29]	At arthroscopy, there was an osteochondral lesion less than 15 mm in diameter in 13 of 34 patients. The osteochondral defects were in the medial patellar facet ($n=6$), on the lateral femoral trochlea ($n=4$), and on both the medial patellar facet and the lateral femoral trochlea in 3 patients
Nha et al. [30]	All patients reported patellar lesions, while 14 showed lateral trochlea chondral defects, after MPFL rupture

mesenchymal stem cells, and could be performed in a minimally invasive fashion [46, 47]. For chondral defect of the patella, isolated AMIC performed better compared to isolated MFx [14]. AMIC demonstrated greater International Knee Document Committee (IKDC) and Lysholm Knee Scoring Scale, along with a considerable reduction of the visual analogue scale (VAS), and an earlier return to sport. Furthermore, AMIC demonstrated a lower rate of failure compared to MFx [14].

Patients suffering from recurrent patellofemoral instability present underlying pathoanatomical abnormalities which predispose to dislocation: trochlear or patellar dysplasia, lower limb mal-alignment syndromes such as tibial extra-rotation or femoral anteversion, and soft tissue abnormalities such as patella alta [2, 6, 48–50]. Moreover, most patients present a combination of two or more concomitant pathoanatomical risk factors which synergistically predispose to instability [51, 52]. Thus, the management of recurrent patellofemoral instability can be challenging [53–55]. An adequate evaluation of pathoanatomical risk factors is mandatory to select the proper treatment [56]. The current literature accounts more than thousand articles concerning the management of the patellofemoral instability, but the optimal treatment is still controversial [4, 35]. Conservative strategies are usually preferred as first line management for patellar dislocation [57–60]. However, following conservative management, between 15 and 48% of patients experienced a further patellar dislocation [61]. Surgery is deserved for patients with unstable osteochondral defects or free bodies in the joint cavity, or for patients with recurrent dislocations who have failed conservative management [61].

The present investigation has several limitations. Most of the studies were retrospective, and blinding was seldom performed. The cohort size was limited by most of studies. Most of the included studies did not primarily investigate the rate of chondral injuries, which could represent an important source of bias. Furthermore, relevant patient biometrics characteristics which may influence the patellofemoral biomechanics, such as patella alta, dysplasia, mal-alignment syndromes, and leg axis deformities, were seldom reported. The relatively short length of the mean follow-up by most of studies may jeopardize the efficacy to detect further chondral lesions in the long term. Given these limitations, results of the present systematic review should be interpreted with caution. Future high-quality investigations should validate these findings on a larger scale.

Conclusion

Chondral defects of the medial facet and the crest of the patella are the most common in patients with recurrent patellofemoral instability.

Abbreviations

PRISMA: Preferred reporting items for systematic reviews and meta-analyses; ICRS: International Cartilage Repair Society; NOS: Newcastle–Ottawa Scale; Mx: Microfractures; ACI: Autologous chondrocyte implantation; AMIC: Autologous matrix-induced chondrogenesis; IKDC: International Knee Document Committee; VAS: Visual analogue scale.

Authors' contributions

FM performed literature search, data extraction, methodological quality assessment, statistical analyses, and writing; NM contributed to supervision, revision, and final approval; EM performed literature search, data extraction, and methodological quality assessment; JE, FH, and FO performed supervision. All listed author approved the final version of the manuscript. All authors read and approved the final manuscript.

Funding

Open Access funding enabled and organized by Projekt DEAL. No external source of funding was used.

Availability of data and materials

No new data were generated or analyzed in support of this review.

Declarations

Ethics approval and consent to participate

This article does not contain any studies with human participants or animals performed by any of the authors.

Consent for publication

Not applicable.

Competing interests

Prof. Nicola Maffulli is the Editor in Chief of the *Journal of Orthopaedic Surgery and Research*. The authors declare that they have any competing interests for this article.

Author details

¹Department of Orthopedic, Trauma, and Reconstructive Surgery, RWTH Aachen University Hospital, Pauwelsstraße 30, 52074 Aachen, Germany. ²Department of Musculoskeletal Disorders, Faculty of Medicine and Surgery, University of Salerno, Via S. Allende, SA 84081 Baronissi, Italy. ³School of Pharmacy and Bioengineering, Faculty of Medicine, Keele University, Thornburrow Drive, Stoke on Trent, England. ⁴Barts and the London School of Medicine and Dentistry, Centre for Sports and Exercise Medicine, Mile End Hospital, Queen Mary University of London, 275 Bancroft Road, London E1 4DG, England.

Received: 28 November 2021 Accepted: 3 January 2022

Published online: 31 January 2022

References

- Nomura E, Inoue M. Second-look arthroscopy of cartilage changes of the patellofemoral joint, especially the patella, following acute and recurrent patellar dislocation. *Osteoarthritis Cartilage*. 2005;13:1029–36.
- Insall J, Goldberg V, Salvati E. Recurrent dislocation and the high-riding patella. *Clin Orthop Relat Res*. 1972;88:67–9.
- Migliorini F, Rath B, Tingart M, et al. Surgical management for recurrent patellar dislocations in skeletally immature patients. *Eur J Orthop Surg Traumatol*. 2019;29:1815–22.

4. Arnbjornsson A, Egund N, Rydning O, et al. The natural history of recurrent dislocation of the patella. Long-term results of conservative and operative treatment. *J Bone Joint Surg Br.* 1992;74:140–2.
5. Atkin DM, Fithian DC, Marangi KS, et al. Characteristics of patients with primary acute lateral patellar dislocation and their recovery within the first 6 months of injury. *Am J Sports Med.* 2000;28:472–9.
6. Dejour H, Walch G, Nove-Josserand L, et al. Factors of patellar instability: an anatomic radiographic study. *Knee Surg Sports Traumatol Arthrosc.* 1994;2:19–26.
7. Runow A. The dislocating patella. Etiology and prognosis in relation to generalized joint laxity and anatomy of the patellar articulation. *Acta Orthop Scand Suppl.* 1983;201:1–53.
8. Cooke TD, Price N, Fisher B, et al. The inwardly pointing knee: an unrecognized problem of external rotational malalignment. *Clin Orthop Relat Res.* 1990;260:56–60.
9. Huberti HH, Hayes WC. Patellofemoral contact pressures. The influence of q-angle and tendofemoral contact. *J Bone Joint Surg Am.* 1984;66:715–24.
10. Cash JD, Hughston JC. Treatment of acute patellar dislocation. *Am J Sports Med.* 1988;16:244–9.
11. Hawkins RJ, Bell RH, Anisette G. Acute patellar dislocations. The natural history. *Am J Sports Med.* 1986;14:117–20.
12. Vollnberg B, Koehlietz T, Jung T, et al. Prevalence of cartilage lesions and early osteoarthritis in patients with patellar dislocation. *Eur Radiol.* 2012;22:2347–56.
13. Migliorini F, Berton A, Salvatore G, et al. Autologous chondrocyte implantation and mesenchymal stem cells for the treatments of chondral defects of the knee—a systematic review. *Curr Stem Cell Res Ther.* 2020;15(6):547–56.
14. Migliorini F, Eschweiler J, Maffulli N, et al. Management of patellar chondral defects with autologous matrix induced chondrogenesis (AMIC) compared to microfractures: a four years follow-up clinical trial. *Life (Basel).* 2021;11:141.
15. Migliorini F, Eschweiler J, Maffulli N, et al. Autologous matrix-induced chondrogenesis (AMIC) and microfractures for focal chondral defects of the knee: a medium-term comparative study. *Life Basel.* 2021;11:183.
16. Sanders TG, Paruchuri NB, Zlatkin MB. MRI of osteochondral defects of the lateral femoral condyle: incidence and pattern of injury after transient lateral dislocation of the patella. *AJR Am J Roentgenol.* 2006;187:1332–7.
17. von Engelhardt LV, Raddatz M, Bouillon B, et al. How reliable is MRI in diagnosing cartilaginous lesions in patients with first and recurrent lateral patellar dislocations? *BMC Musculoskelet Disord.* 2010;11:149.
18. Guerrero P, Li X, Patel K, et al. Medial patellofemoral ligament injury patterns and associated pathology in lateral patella dislocation: an MRI study. *Sports Med Arthrosc Rehabil Ther Technol.* 2009;1:17.
19. Elias DA, White LM, Fithian DC. Acute lateral patellar dislocation at MR imaging: injury patterns of medial patellar soft-tissue restraints and osteochondral injuries of the inferomedial patella. *Radiology.* 2002;225:736–43.
20. Freiburger RH, Kotzen LM. Fracture of the medial margin of the patella, a finding diagnostic of lateral dislocation. *Radiology.* 1967;88:902–4.
21. Jerabek SA, Asnis PD, Bredella MA, et al. Medial patellar ossification after patellar instability: a radiographic finding indicative of prior patella subluxation/dislocation. *Skeletal Radiol.* 2009;38:785–90.
22. Boddula MR, Adamson GJ, Pink MM. Medial reefing without lateral release for recurrent patellar instability: midterm and long-term outcomes. *Am J Sports Med.* 2014;42:216–24.
23. Chan CM, King JJ 3rd, Farmer KW. Fixation of chondral fracture of the weight-bearing area of the lateral femoral condyle in an adolescent. *Knee Surg Sports Traumatol Arthrosc.* 2014;22:1284–7.
24. Franzone JM, Vitale MA, Shubin Stein BE, et al. Is there an association between chronicity of patellar instability and patellofemoral cartilage lesions? An arthroscopic assessment of chondral injury. *J Knee Surg.* 2012;25:411–6.
25. Gaweda K, Walawski J, Weglowski R, et al. Early results of one-stage knee extensor realignment and autologous osteochondral grafting. *Int Orthop.* 2006;30:39–42.
26. Kita K, Tanaka Y, Toritsuka Y, et al. Patellofemoral chondral status after medial patellofemoral ligament reconstruction using second-look arthroscopy in patients with recurrent patellar dislocation. *J Orthop Sci.* 2014;19:925–32.
27. Lee DK, Wang JH, Kang SH, et al. The clinical and radiological results of individualized surgical treatment depending on pathologic abnormalities in recurrent patellar dislocation: low recurrence rate, but unintended patella baja. *Knee Surg Sports Traumatol Arthrosc.* 2018;26:2558–67.
28. Luhmann SJ, Schoenecker PL, Dobbs MB, et al. Arthroscopic findings at the time of patellar realignment surgery in adolescents. *J Pediatr Orthop.* 2007;27:493–8.
29. Maffulli N, Aicale R, D'Addona A, et al. Combined medial patellofemoral and patellotibial reconstruction with soft tissue fixation in recurrent patellar dislocation. *Injury.* 2020;51:1867–73.
30. Nha KW, Ha Y, Oh S, et al. Surgical treatment with closing-wedge distal femoral osteotomy for recurrent patellar dislocation with Genu Valgum. *Am J Sports Med.* 2018;46:1632–40.
31. Moher D, Liberati A, Tetzlaff J, et al. Preferred reporting items for systematic reviews and meta-analyses: the PRISMA statement. *BMJ.* 2009;339:b2535.
32. Howick J CI, Glasziou P, Greenhalgh T, Carl Heneghan, Liberati A, Moschetti I, Phillips B, Thornton H, Goddard O, Hodgkinson M. The 2011 Oxford CEBM levels of evidence. Oxford Centre for Evidence-Based Medicine. 2011.
33. Paatela T, Vasara A, Nurmi H, et al. Assessment of cartilage repair quality with the international cartilage repair society score and the Oswestry Arthroscopy Score. *J Orthop Res.* 2020;38:555–62.
34. Wells GA, Shea B, O'Connell Da, et al. The Newcastle-Ottawa Scale (NOS) for assessing the quality of nonrandomised studies in meta-analyses. Oxford. 2000.
35. Nam EK, Karzel RP. Mini-open medial reefing and arthroscopic lateral release for the treatment of recurrent patellar dislocation: a medium-term follow-up. *Am J Sports Med.* 2005;33:220–30.
36. Aae TF, Randsborg PH, Luras H, et al. Microfracture is more cost-effective than autologous chondrocyte implantation: a review of level 1 and level 2 studies with 5 year follow-up. *Knee Surg Sports Traumatol Arthrosc.* 2018;26:1044–52.
37. Basad E, Ishaque B, Bachmann G, et al. Matrix-induced autologous chondrocyte implantation versus microfracture in the treatment of cartilage defects of the knee: a 2-year randomised study. *Knee Surg Sports Traumatol Arthrosc.* 2010;18:519–27.
38. Filardo G, Kon E, Berruto M, et al. Arthroscopic second generation autologous chondrocytes implantation associated with bone grafting for the treatment of knee osteochondritis dissecans: results at 6 years. *Knee.* 2012;19:658–63.
39. Bertho P, Pauvert A, Pouderoux T, et al. Treatment of large deep osteochondritis lesions of the knee by autologous matrix-induced chondrogenesis (AMIC): preliminary results in 13 patients. *Orthop Traumatol Surg Res.* 2018;104:695–700.
40. Siebold R, Suezzer F, Schmitt B, et al. Good clinical and MRI outcome after arthroscopic autologous chondrocyte implantation for cartilage repair in the knee. *Knee Surg Sports Traumatol Arthrosc.* 2018;26:831–9.
41. Niemeyer P, Laute V, Zinser W, et al. A prospective, randomized, open-label, multicenter, phase III noninferiority trial to compare the clinical efficacy of matrix-associated autologous chondrocyte implantation with spheroid technology versus arthroscopic microfracture for cartilage defects of the knee. *Orthop J Sports Med.* 2019;7:2325967119854442.
42. Van Assche D, Staes F, Van Caspel D, et al. Autologous chondrocyte implantation versus microfracture for knee cartilage injury: a prospective randomized trial, with 2-year follow-up. *Knee Surg Sports Traumatol Arthrosc.* 2010;18:486–95.
43. Saris DB, Vanlauwe J, Victor J, et al. Treatment of symptomatic cartilage defects of the knee: characterized chondrocyte implantation results in better clinical outcome at 36 months in a randomized trial compared to microfracture. *Am J Sports Med.* 2009;37(Suppl 1):105–195.
44. Bartlett W, Skinner JA, Gooding CR, et al. Autologous chondrocyte implantation versus matrix-induced autologous chondrocyte implantation for osteochondral defects of the knee: a prospective, randomised study. *J Bone Joint Surg Br.* 2005;87:640–5.
45. Migliorini F, Berton A, Salvatore G, et al. Autologous chondrocyte implantation and mesenchymal stem cells for the treatments of chondral defects of the knee—a systematic review. *Curr Stem Cell Res Ther.* 2020;15:547–56.
46. Schagemann J, Behrens P, Paech A, et al. Mid-term outcome of arthroscopic AMIC for the treatment of articular cartilage defects in the knee

- joint is equivalent to mini-open procedures. *Arch Orthop Trauma Surg.* 2018;138:819–25.
47. Volz M, Schaumburger J, Frick H, et al. A randomized controlled trial demonstrating sustained benefit of Autologous Matrix-Induced Chondrogenesis over microfracture at five years. *Int Orthop.* 2017;41:797–804.
 48. Dejour H, Walch G, Neyret P, et al. Dysplasia of the femoral trochlea. *Rev Chir Orthop Reparatrice Appar Mot.* 1990;76:45–54.
 49. Migliorini F, Trivellas A, Colarossi G, et al. Single- versus double-bundle patellar graft insertion for isolated MPFL reconstruction in patients with patellofemoral instability: a systematic review of the literature. *Arch Orthop Trauma Surg.* 2020;140(6):769–76.
 50. Migliorini F, Rath B, Tingart M, et al. Surgical management for recurrent patellar dislocations in skeletally immature patients. *Eur J Orthop Surg Traumatol.* 2019;29(8):1815–22.
 51. Steensen RN, Bentley JC, Trinh TQ, et al. The prevalence and combined prevalences of anatomic factors associated with recurrent patellar dislocation: a magnetic resonance imaging study. *Am J Sports Med.* 2015;43:921–7.
 52. Longo UG, Berton A, Salvatore G, et al. Medial patellofemoral ligament reconstruction combined with bony procedures for patellar instability: current indications, outcomes, and complications. *Arthroscopy.* 2016;32:1421–7.
 53. Fithian DC, Paxton EW, Stone ML, et al. Epidemiology and natural history of acute patellar dislocation. *Am J Sports Med.* 2004;32:1114–21.
 54. Migliorini F, Trivellas A, Driessen A, et al. Graft choice for isolated MPFL reconstruction: gracilis versus semitendinosus. *Eur J Orthop Surg Traumatol.* 2020;30(5):763–70.
 55. Felli L, Alessio-Mazzola M, Lovisolo S, et al. Anatomy and biomechanics of the medial patellotibial ligament: a systematic review. *Surgeon.* 2020;19(5):168–74.
 56. Panni AS, Alam M, Cerciello S, et al. Medial patellofemoral ligament reconstruction with a divergent patellar transverse 2-tunnel technique. *Am J Sports Med.* 2011;39:2647–55.
 57. Hoetzel J, Preiss A, Heitmann MA, et al. Knee injuries in children and adolescents. *Eur J Trauma Emerg Surg.* 2014;40:23–36.
 58. Palmu S, Kallio PE, Donell ST, et al. Acute patellar dislocation in children and adolescents: a randomized clinical trial. *J Bone Joint Surg Am.* 2008;90:463–70.
 59. Buchner M, Baudendistel B, Sabo D, et al. Acute traumatic primary patellar dislocation: long-term results comparing conservative and surgical treatment. *Clin J Sport Med.* 2005;15:62–6.
 60. Stefancin JJ, Parker RD. First-time traumatic patellar dislocation: a systematic review. *Clin Orthop Relat Res.* 2007;455:93–101.
 61. Frosch S, Balcarek P, Walde TA, et al. The treatment of patellar dislocation: a systematic review. *Z Orthop Unfall.* 2011;149:630–45.

Publisher's Note

Springer Nature remains neutral with regard to jurisdictional claims in published maps and institutional affiliations.

Ready to submit your research? Choose BMC and benefit from:

- fast, convenient online submission
- thorough peer review by experienced researchers in your field
- rapid publication on acceptance
- support for research data, including large and complex data types
- gold Open Access which fosters wider collaboration and increased citations
- maximum visibility for your research: over 100M website views per year

At BMC, research is always in progress.

Learn more biomedcentral.com/submissions

