



## Case report

## A rare case of cutaneous mucormycosis in the forearm: A case report

Rouzbeh Shadidi-Asil<sup>a</sup>, Mehrnoosh Kialashaki<sup>b,\*</sup>, Armin Fateh<sup>a</sup>, Amirreza Ramezani<sup>c</sup>, Amir Zamani<sup>a</sup>, Manoochehr Ebrahimi<sup>a</sup>

<sup>a</sup> Department of General Surgery, Lohman Hakim Hospital, Shahid Beheshti University of Medical Sciences, Tehran, Iran

<sup>b</sup> Department of General Surgery, Shafa Hospital, Qazvin University of Medical Sciences, Qazvin, Iran

<sup>c</sup> School of Medicine, Shahid Beheshti University of Medical Sciences, Tehran, Iran

## ARTICLE INFO

## Keywords:

Mucormycosis  
Skin  
Debridement  
Antifungal agents  
Amphotericin B  
Case report

## ABSTRACT

**Introduction and importance:** Cutaneous Mucormycosis (CM) is a less frequent type of fungal infection that can present with different skin lesions. Although these lesions appear to be benign and silent, CM rapidly progresses into the deeper layers. Given that no specific laboratory or imaging finding is described for the disease, the diagnosis is mainly based on history and physical examination. In addition, immediate debridement and antifungal agents must be commenced.

**Case presentation:** We present a 43-year-old septic man who was hospitalized for his forefoot infection. During his admission, he developed a necrotic-like ulcer in his antecubital fossa. After initial debridement, pathology examination revealed the infection with mucormycosis. We administered intravenous liposomal Amphotericin B, and also multiple surgeries were performed. Unfortunately, the sepsis progressed to multiorgan failure, and the patient passed away.

**Conclusion:** CM requires emergent diagnosis and treatment. Early surgical interventions like extensive debridement and repetitive wound irrigation alongside systemic antifungal therapy are the key steps to preventing the progression of the disease.

## 1. Introduction

Mucormycosis (aka phycomycosis, zygomycosis) is a rare opportunistic infection that progresses rapidly, caused by fungi belonging to the mucoromycotina subphylum. The infection usually affects immunocompromised patients, especially those with phagocyte bactericidal dysfunctions, leukemia, uncontrolled diabetes, and also the population of organ transplant patients [1]. Although rhino-orbito-cerebral and pulmonary mucormycosis are the most common forms of the disease, CM also can be found rarely in immunosuppressed patients, mainly induced after a trauma or breach of skin [2]. The infection can immediately invade the arteries, and form thrombosis; causing soft and hard tissues necrosis. Finally, the undiagnosed or uncontrolled disease may lead to devastating septicemia and death.

For this reason, early diagnosis and effective treatment of the disease are the main steps to reducing mortality and morbidity rates. This requires high index suspicion in clinicians [3].

We present a patient with uncontrolled diabetes mellitus and a history of chronic kidney disease who was under treatment for an infected

post-amputation surgical wound on his right foot. During treatment, the patient developed a necrotic ulcer on his arm which pathologic evaluation revealed CM. This article is reported in line with SCARE criteria [4].

## 2. Case presentation

A 43-year-old man was presented to our hospital with uncontrolled sepsis due to an infected surgical wound on his right foot. He had a history of uncontrolled diabetes mellitus (DM) and chronic kidney disease (CKD) and didn't mention any history of medication consumption. He mentioned that an infected wound was developed on his right forefoot due to an intangible trauma two weeks previously. Following that, the patient was referred to a hospital, and became a candidate for Ray's amputation on his first two phalanges. Three days after the first operation, he noticed pus coming out of his wound and came to our emergency department.

Primary physical examination revealed an infected surgical wound on the right forefoot with purulent discharge and cellulitis in the

\* Corresponding author.

E-mail address: [m.kialashaky@gmail.com](mailto:m.kialashaky@gmail.com) (M. Kialashaki).

<https://doi.org/10.1016/j.ijscr.2022.107048>

Received 12 February 2022; Received in revised form 3 April 2022; Accepted 5 April 2022

Available online 6 April 2022

2210-2612/© 2022 Published by Elsevier Ltd on behalf of IJS Publishing Group Ltd. This is an open access article under the CC BY-NC-ND license (<http://creativecommons.org/licenses/by-nc-nd/4.0/>).

surrounding tissue. There were no signs of necrosis around there. Although the patient was a known case of CKD, his urination was decreased significantly. For this reason, we inserted a Foley catheter to measure the urine output more precisely. Plain X-rays did not show any neglected fracture or opaque foreign bodies.

The blood analysis on admission day is depicted in Table 1. We sent three consecutive blood samples for culture, but all of them were negative. According to Sequential [Sepsis-related] Organ Failure Assessment (SOFA) criteria, ongoing sepsis was occurring [5].

Concerning the patient's general condition, he was admitted to the intensive care unit (ICU) and treated with broad-spectrum intravenous (IV) antibiotics such as Vancomycin (1 g/bid), Piperacillin/Tazobactam (3.376 g/QID), and Imipenem (500 mg/BID). Wound irrigation with a saline solution twice a day was performed regularly.

After one week, the patient was still septic, and also developed fever (OT = 38.5 °C), systolic hypotension, and confusion. Laboratory data showed deteriorated levels of leukocytes ( $12.7 \times 10^3$ ), hemoglobin (6.9 g/dL), thrombocytes (39,000/ $\mu$ L), and high creatinine levels. Due to the patient's condition, he was transferred to the operating room, and a Guillotine Ankle Amputation in the right foot was performed to control the possible source of sepsis.

Ten days after the amputation, sepsis was under control, and no purulent discharge was detected at the surgery site. On the other hand, a new-onset necrotic ulcer at the site of IV injections in the right antecubital fossa was found on whole-body examination (Fig. 1).

The patient was transferred to the operating theatre with a suspicion of drug extravasation, and extensive debridement of necrotic tissue was performed. Also, removed necrotic tissue was sent for a pathological evaluation (Fig. 2).

Pathology analysis of soft tissue revealed skin and underlying fat with extensive necrosis, multiple non-septate broad fungal hyphae invading dermis and, hypodermal fat, consistent with CM (Fig. 3) Therefore, an anti-fungal drug (liposomal amphotericin B, 300 mg daily) was added to the antibiotic regimen.

Two days after the Second surgery, daily examinations showed pulseless radial and ulnar arteries in the right hand. We performed a Color-Doppler ultrasound which demonstrated a lack of flow in radial, ulnar, and distal brachial arteries suggesting occlusive clot formation in the proximal brachial artery and acute deep vein thrombosis (DVT) in the axillary vein. A successful urgent surgical embolectomy was immediately performed.

Unfortunately, after several debridement attempts and medical therapy, the patient died from severe sepsis and multi-organ failure.

### 3. Discussion

Mucormycosis is an opportunistic, invasive infection caused by fungi belonging to the Mucoromycotina subphylum [1]. This infection is more

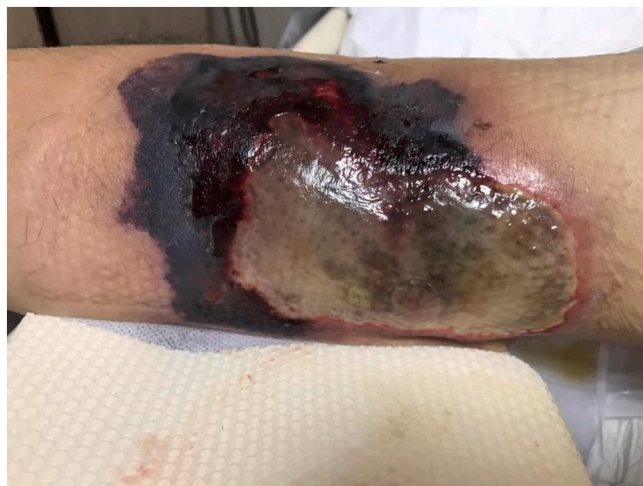

Fig. 1. A large necrotic ulcer I antecubital fossa.

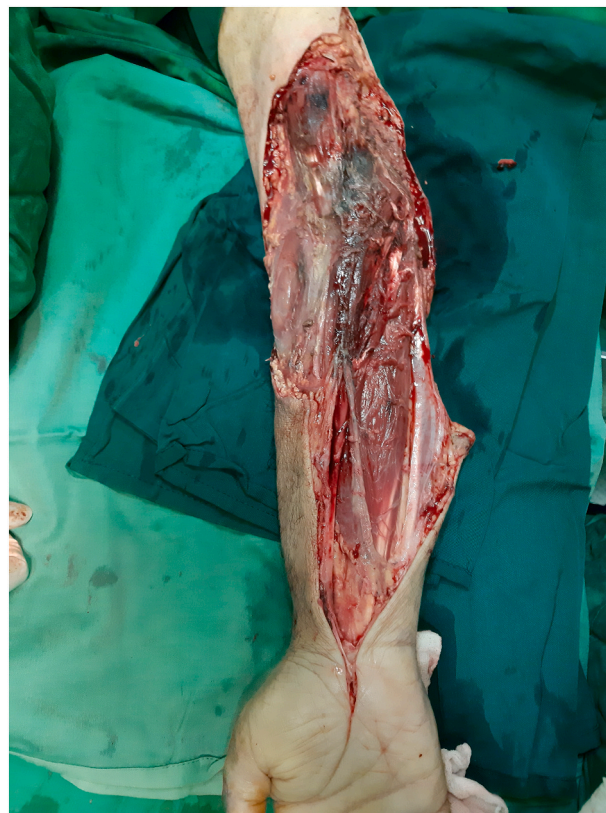


Fig. 2. The upper limb after extensive necrosis. Please note the remained tissues still have dark colors suggesting a profound invasion of the infection.

Table 1

Laboratory tests on admission day.

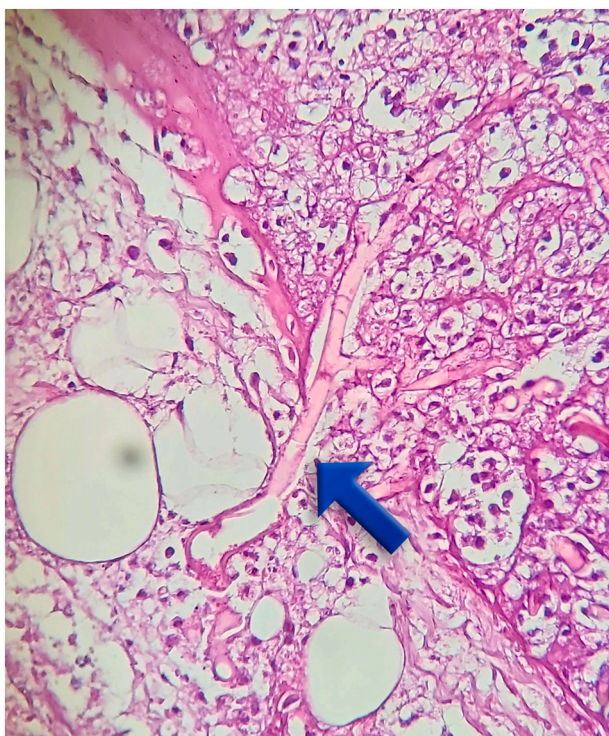
Test	Value	Unit
White blood cells	17.1	thousands/ $\mu$ L
Neutrophils	15.5	thousands/ $\mu$ L
Lymphocytes	1.1	thousands/ $\mu$ L
Hemoglobin	7.9	g/dL
Hematocrit	26.9	%
Platelets	100	units/ $\mu$ L
Fasting blood sugar	175	mg/dL
Creatinine	3.5	mg/dL
Blood urea nitrogen	189	mg/dL
C-reactive protein	96.1	mg/L
Bilirubin, total	3.7	mg/dL
Venous blood gas		
pH	7.34	
PCO <sub>2</sub>	30.2	mmHg
HCO <sub>3</sub>	16.6	Mmol/L

frequent in the upper parts of the skull and lung. The fungi may disseminate through inhalation of spores into the upper respiratory tract, consuming contaminated foods, and also colonization in damaged or wounded skin [3].

There are several notable species of fungi that cause mucormycosis. In Iran, the *Rhizopus* species is the most common cause of the disease accounting for up to 52% of cases [6]. Also, there is no reliable information about the exact incidence of CM.

Although genetic studies disclosed the role of several potential genes in the pathogenesis of the disease, impaired phagocytic activities in immunocompromised patients are the most important predisposing





**Fig. 3.** Pathology examination shows a non-septate broad fungal hyphae inside the dermis.

factor [1]. Therefore, the incidence is more common in patients with hematologic malignancies, uncontrolled hyperglycemia, ketoacidosis, etc.

Cutaneous mucormycosis is an unusual form of the disease, which can cause skin and subdermal infection after disruption of the intact skin barrier [7]. The typical presentation of the disease is a necrotic scar with an erythematous and indurated surrounding skin. Also, it can present as other skin lesions (including tinea-corporis-like lesions and erythema multiform) [8]. In immunocompromised cases, such lesions should be a caveat for clinicians. Especially when a necrotic lesion develops in these patients, mucormycosis must be on the top of the diagnosis list [9].

Although imaging studies such as computed tomography and magnetic resonance imaging, are very useful in diagnosing rhinocerebral mucormycosis, they cannot be used in the cutaneous form [10]. On the other hand, color-doppler ultrasonography (US), in some cases, can guide the clinician to the diagnosis. Given that the disease finally involves the microcirculation system and may cause aggressive angioinvasion, color-doppler US will show low blood flow and clot formation in the adjacent vessels [1].

It seems that with the explanations given, perhaps the only way to definitively diagnose the disease is histopathologic examination [11].

Management of mucormycosis has three essential elements: reversing underlying immunosuppression, immediate initiation of systemic anti-fungal agents, and aggressive surgical debridement [9]. Amphotericin B is the drug of choice for systemic treatment, but using liposomal Amphotericin B allows clinicians to administer higher doses of the drug with fewer nephrotoxic effects [12]. On the other hand, emergent surgical debridement has two main advantages. The first one is controlling the source of infection, and the second is preventing the spread of the fungi into deeper layers such as fasciae, muscles, and bones. The second reason has a paramount importance; because this infection may lead to necrotizing fasciitis, which has a mortality rate of nearly 80% [13].

In our case, we immediately put the patient on liposomal Amphotericin B and IV insulin to control the hyperglycemic state.

Unfortunately, despite hemodialysis, the underlying acidosis did not handle properly, and after several extensive surgical debridements, the underlying necrosis of soft tissue progressed rapidly.

#### 4. Conclusion

The case is reported to highlight the high index of clinical suspicion in diagnosing cutaneous mucormycosis and the importance of immediate systemic and surgical treatment. Surgeons and intensivists should be alarmed, especially if the patient is hospitalized for an extended period of time and is treated with broad-spectrum antibiotics. Regular fungal cultures in such patients can be performed when signs of sepsis and wound infection are seen. However, reasonable control of diabetes and a healthy immune system and phagocyte function can prevent the disease.

#### Sources of funding

The authors didn't receive any financial support for this report.

#### Ethical approval

This article does not contain any studies with human participants or animals performed by any of the authors.

#### Consent

Written informed consent was obtained from the patient for publication of this case report and accompanying images. A copy of the written consent is available for review by the Editor-in-Chief of this journal on request.

#### Authors' contributions

RS: Conceptualization.  
MK: Writing - Review & Editing.  
AF: Resources.  
AR: Writing - Original Draft.  
AZ: Supervision.  
ME: Project administration.

#### Registration of research studies

Not applicable.

#### Provenance and peer review

Not commissioned, externally peer-reviewed.

#### Guarantor

Dr. Manoochehr Ebrahimian.

#### Declaration of competing interest

The authors declared no potential conflict of interests with respect to the research, authorship, and/or publication of this article.

#### Acknowledgments

None.

#### References

- [1] A.S. Ibrahim, D.P. Kontoyiannis, Update on mucormycosis pathogenesis, *Curr. Opin. Infect. Dis.* 26 (6) (2013) 508.
- [2] H. Prakash, A. Chakrabarti, Epidemiology of mucormycosis in India, *Microorganisms* 9 (3) (2021) 523.

- [3] A.S. Ibrahim, B. Spellberg, T.J. Walsh, D.P. Kontoyiannis, Pathogenesis of mucormycosis, *Clin. Infect. Dis.* 54 (suppl\_1) (2012) S16–S22.
- [4] R.A. Agha, T. Franchi, C. Sohrabi, G. Mathew, A. Kerwan, A. Thoma, et al., The SCARE 2020 guideline: updating consensus surgical CAse REport (SCARE) guidelines, *Int. J. Surg.* 84 (2020) 226–230.
- [5] E.P. Raith, A.A. Udy, M. Bailey, S. McGloughlin, C. MacIsaac, R. Bellomo, et al., Prognostic accuracy of the SOFA score, SIRS criteria, and qSOFA score for in-hospital mortality among adults with suspected infection admitted to the intensive care unit, *JAMA* 317 (3) (2017) 290–300.
- [6] A. Vaezi, M. Moazeni, M.T. Rahimi, S. de Hoog, H. Badali, Mucormycosis in Iran: a systematic review, *Mycoses* 59 (7) (2016) 402–415.
- [7] E. Herrero, M. Sánchez, A. Agrifoglio, L. Cachafeiro, M. Asensio, B. Galván, et al., Cutaneous mucormycosis in the ICU, *Crit. Care* 19 (1) (2015) 1–201.
- [8] S.N. Afroz, R. Korlepara, G.V. Rao, J. Madala, Mucormycosis in a diabetic patient: a case report with an insight into its pathophysiology, *Contemp. Clin. Dent.* 8 (4) (2017) 662.
- [9] V. Pathania, R. Kothari, A. Kashif, K.B. Anand, P. Guleria, R. Venugopal, A Sinister Call for the Dermatologist From Intensive Care Unit: Mucormycosis Revisited, 2022.
- [10] D.A. Herrera, A.B. Dublin, E.L. Ormsby, S. Aminpour, L.P. Howell, Imaging findings of rhinocerebral mucormycosis, *Skull Base* 19 (02) (2009) 117–125.
- [11] C. Zirak, J.P. Brutus, A. De Mey, Atypical cause of forearm skin ulceration in a leukaemic child: mucormycosis. A case report, *Acta Chir. Belg.* 105 (5) (2005) 551–553.
- [12] Z. Ahmadinejad, H. Khazraiyani, F. Ghanbari, B. Ahmadi, M. Gerami Shoar, Cutaneous mucormycosis in a diabetic patient following traditional dressing, in: *Case Reports in Dermatological Medicine* 2013, 2013.
- [13] B. Spellberg, J. Edwards Jr., A. Ibrahim, Novel perspectives on mucormycosis: pathophysiology, presentation, and management, *Clin. Microbiol. Rev.* 18 (3) (2005) 556–569.