

## Central nervous system demyelination associated with etanercept in a 51 years old woman

Wanis H Ibrahim<sup>1</sup>, Mohammed Hammoudah<sup>2</sup>, Naveed Akhtar<sup>3</sup>,  
Hassan Al-Hail<sup>3</sup> and Dirk Deleu<sup>3</sup>

(1) Department of Medicine, (2) Department of Rheumatology and (3) Department of Neurology  
Hamad General Hospital & Weill-Cornell medical college, Doha, Qatar

**Abstract:** There are few case reports documenting a new onset of demyelinating processes in patients receiving anti-tumour necrosis factor alpha therapy (anti-TNF alpha) for chronic inflammatory arthropathies. Whether anti-TNF alpha therapy induces new onset demyelination or just exacerbates pre-existing latent multiple sclerosis is not fully understood. We are reporting a 51-year-old woman without a prior history of multiple sclerosis, who developed demyelinating brain lesions three months after starting Etanercept. Her symptoms partially resolved on cessation of the drug. Our case was unusual compared to some previous case reports, as the patient's age at presentation was beyond that for idiopathic multiple sclerosis. This may strengthen the hypothesis of a causal relationship between new onset demyelination and Etanercept; however, exacerbation of pre-existing demyelinating process by Etanercept in this patient still cannot be totally excluded. We recommend doing magnetic resonance imaging (MRI) of the brain before starting patients on anti-TNF alpha therapy to exclude latent demyelination. In addition, new onset demyelination following anti-TNF alpha therapy should be reported and studied thoroughly as this may yield a significant advancement in our understanding of the pathogenesis of multiple sclerosis. Long-term follow-up of these cases is also important to determine the long-term prognosis and the rate of relapse of demyelinating process in this group of patients.

### Introduction

Many rheumatic diseases including Rheumatoid arthritis (RA), Psoriatic arthritis (PsA) and Ankylosing spondylitis (AS) are autoimmune conditions, characterized by dysregulation and chronic activation of T-cell responses [1,2]. The ultimate outcome is overproduction of pro-inflammatory cytokines, including tumor necrosis factor (TNF) alpha and interleukin 1, which have been postulated to mediate the joint destruction seen in RA [3,4]. Of note, B-cells seem also to play an important role in the pathogenesis of these diseases. They can act as antigen-presenting cells (APC) to T-cells and activate them, which in turn result in secretion of pro-inflammatory cytokines including TNF alpha [5]. Biological agents such as anti-tumor necrosis factor alpha (Anti-TNF alpha) have been approved for the treatment of certain diseases like inflammatory arthropathies, Psoriasis, and Crohn's disease. In fact, these agents have revolutionized the treatment of these diseases, with demonstrated efficacy and safety [4,6]. However, several potential risks such as predisposition to some infections (especially tuberculosis), heart failure or development of lymphomas have been uncovered in post-marketing reports. In addition, rare cases of new onset or exacerbations of central nervous system demyelination have been reported in the literature [7]. Etanercept is a fully human, soluble, TNF alpha receptor-IgG1 fusion protein that binds to both soluble and membrane bound TNF alpha, thereby inhibiting its interaction with cell surface receptors and preventing TNF mediated cellular responses. Etanercept has been approved by the Federal Drug Administration (FDA) for the treatment of subjects with moderately to severely

active RA, Polyarticular juvenile RA (JRA), AS, PsA and psoriasis [8].

We report a case of new onset demyelinating disease that developed in a temporal association with the use of Etanercept in a patient whose age is beyond that for idiopathic multiple sclerosis.

### Case report

A 51-year old woman with a 2-year history of rheumatoid arthritis presented with three weeks history of vertigo and vomiting. Her symptoms worsened progressively and she became unsteady on walking. She also felt episodes of tingling and numbness on the right side of the face. There was no prior history of neurological disease and no family history of multiple sclerosis.

She was maintained on Methotrexate 20 mg weekly for the arthritis, however due to inadequate response, subcutaneous Etanercept 50 mg weekly was begun three months prior to her admission with marked improvement in her joint symptoms. She had received the last dose of Etanercept four days prior to hospital admission. Past medical history was also significant for 1-year history of diabetes on Metformin, and hypercholesterolemia on Simvastatin 10 mg. The physical examination revealed a horizontal nystagmus with fast component towards left side and broad-based, ataxic gait with tendency to fall to the left side. Rest of examination was unremarkable and there were no signs of active joint disease.

Complete blood count, urea, electrolytes, and blood sugar were normal and Electrocardiography revealed occasional ventricular ectopic beats. Autoimmune tests including ANA, Anti-ds DNA and Anti-CCP were negative. Rheumatoid factor also was negative at admission.

MRI of the brain (Figure 1) revealed multiple rounded foci with iso-intense T1 and hyper-intense FLAIR and T2 signals involving the left side of the medulla, the right middle cerebral peduncle, the body of the corpus callosum and the sub-cortical white matter of both cerebral hemispheres, which were suggestive of demyelinating foci. The patient refused lumbar puncture.

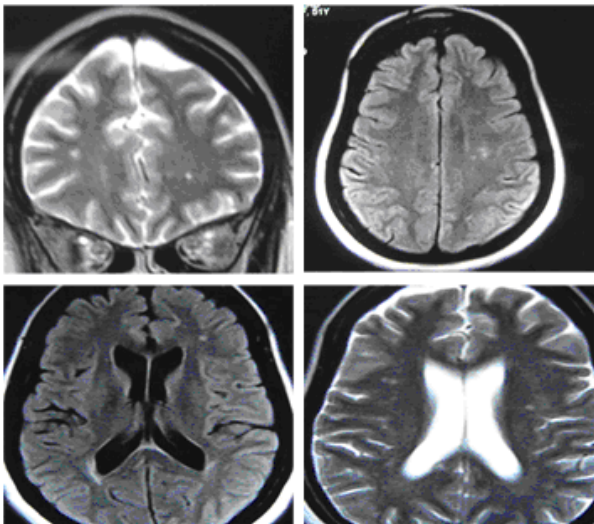


Figure 1: MRI brain showing demyelinating lesions.

Etanercept was discontinued immediately. Three days later she felt better, with reduction in intensity of vertigo and disappearance of nystagmus, however her gait remained ataxic.

Intravenous methylprednisolone pulse therapy was then started and three days later, she made a good recovery and was able to walk unsupported. She was discharged on oral prednisolone 60 mg daily to be tapered gradually and then maintained on Methylprednisolone 4 mg daily. Three months later, she presented with new onset ataxia, double vision and vertigo. Neurological examination revealed ataxic gait, nystagmus with fast component to left side. Repeated MRI of the brain (Figure 2) revealed a newly developed rounded, about 1 cm in size, demyelinating lesion in the right posterior parietal area, with scattered small demyelinating lesions. The patient requested discharge to seek a second opinion abroad.

### Discussion

Anti-TNF alpha therapy was initially considered for the treatment of multiple sclerosis based on studies of experimental autoimmune encephalomyelitis (EAE), which is considered a model for human multiple sclerosis [9-11]. Blocking TNF alpha with antibodies decreased EAE severity in rodents [12]. In humans high levels of TNF alpha have been found in multiple

sclerosis plaques and cerebrospinal fluid [13]. But despite these findings, anti-TNF alpha treatment for multiple sclerosis worsens the disease. In a trial of anti-TNF alpha therapy using Lenercept for patients with multiple sclerosis, treated patients had significantly more exacerbations than placebo-treated patients [14]. In addition, treatment with anti-TNF alpha antibody in two patients with rapidly progressing multiple sclerosis led to a transient increase in gadolinium-enhancing lesions and no improvement in disease severity [15]. Based on these studies, anti-TNF alpha agents were abandoned as candidate drugs for the treatment of multiple sclerosis [9].

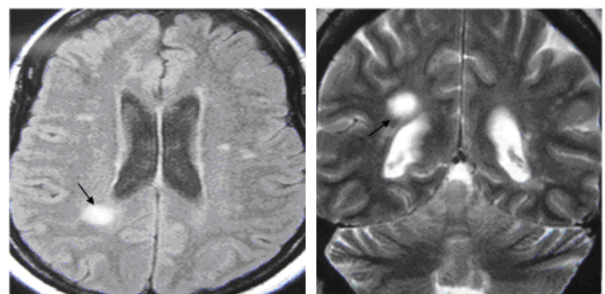


Figure 2: MRI brain 3 months later

Nonetheless the recent approval of these agents for the treatment of certain chronic inflammatory arthropathies, Crohn's disease and Psoriasis, has had a major impact on the outcome of these diseases. These agents have led to significant improvement in most patients with inflammatory arthropathies, which were resistant to conventional forms of treatment. In fact, these agents revolutionized the treatment of chronic inflammatory arthropathies. However, since the approval of anti-TNF alpha agents, rare cases of new onset or exacerbations of demyelinating diseases have been reported. This includes multiple sclerosis-like disease, optic neuritis, myelitis or chronic inflammatory demyelinating polyneuropathy [7]. Central nervous system demyelination following anti TNF alpha therapy has been reported with different agents like Infliximab, Etanercept and Adalimumab that were indicated for diseases like Crohn's disease, Inflammatory arthropathies and Psoriasis [7,16-19].

In 2001, Mohan et al [9] queried the Adverse Events Reporting system of the Food and Drug Administration for neurological events suggestive of demyelination following anti-TNF alpha therapy. Nineteen patients with demyelinating-like neurological events were identified, 17 who had been receiving Etanercept and two who had been receiving infliximab. The most common presenting clinical symptoms were parasthesias (13 patients),

optic neuritis (eight patients), confusion (five patients), gait disturbance, apraxia, and facial palsy and Guillain-Barre syndrome. The average time between the beginning of therapy and the onset of symptoms was five months. Cessation of anti-TNF alpha therapy resulted in complete or partial improvement of symptoms in all patients. One patient noted return of symptoms when therapy was tried again. The duration of therapy before development of neurological symptoms ranged from one week to 15 months, with a mean duration of five months.

Table 1 Characteristics of some cases reported in literature

	Year (20**)	Age (yrs)	sex	Onset after anti-TNF (months)	Anti-TNF	Indication	History of MS	Relapse after anti-TNF stop
Sicott <sup>20</sup>	01	21	F	9	E	JRA	N	Y
Titlebaum <sup>23</sup>	05	33	F	18	E	RA	N	Y
Al saieg <sup>24</sup>	06	58	F	12	E	RA	N	N
Ruiz-Jimeno <sup>25</sup>	06	47	F	6	I	PsA	N	Y
Sukai <sup>16</sup>	06	18	F	12	E	Pe	N	N
Mejico <sup>17</sup>	04	50	F	1	I	C	N	N
Tanno <sup>26</sup>	06	56	M	1	I	RA	N	N
Ibrahim (current case)	06	51	F	3	E	RA	N	Y

E: Etanercept, I: Infliximab, RA: rheumatoid arthritis, JRA: juvenile rheumatoid arthritis, PsA: psoriatic arthritis, Pe: psoriatic erythroderma, C: Crohn's disease N: No, Y: Yes

The overall number of individuals with new onset demyelinating events on anti-TNF alpha therapy appears to be small, but these episodes can be clinically silent, making it difficult to assess the actual number of affected individuals [20]. In addition the condition may be under-reported due to the unawareness and the non-specific presentation. Parasthesia, which is the most common symptom [9] may be easily attributed to the rheumatologic disease itself or associated illness. In a recent meta-analysis of 22 trials done on rheumatoid arthritis, psoriatic arthritis, and ankylosing spondylitis patients, Fleischmann et al [21] assessed the long-term safety of Etanercept in elderly subjects with rheumatic diseases. Out of the 4322 subjects studied, only eight cases of demyelinating disorders were diagnosed in subjects aged less than 65 and no cases of demyelinating disease in subjects aged  $\geq$  65. In the recent German Etanercept registry for the

treatment of juvenile idiopathic arthritis, out of the 324 subjects studied, only one had central nervous system demyelination [22].

## CONCLUSION

Our patient did not have past history of multiple sclerosis. In addition, her age at presentation was beyond that for multiple sclerosis. Her symptoms partially resolved on cessation of Etanercept. This may suggest a causal relationship between new onset demyelination and Etanercept. Nevertheless, exacerbation of pre-existing occult (asymptomatic) demyelinating disease can't be totally excluded as the cause of this patient's clinical presentation. Therefore, we recommend doing MRI of the brain before starting patients on anti-TNF alpha therapy. This will definitely determine whether a demyelination process is a new onset, anti-TNF alpha related or merely due to latent multiple sclerosis exacerbation. In addition, we recommend that all cases of new onset demyelination should be reported and studied thoroughly as this will not only help to avoid a serious adverse event but may also yield a significant advancement in our understanding of the pathogenesis of multiple sclerosis. Furthermore, follow-up of these cases should be encouraged in order to determine the long-term prognosis and relapse rate of demyelinating process in these patients.

## References

1. Goronzy JJ and Weyand CM. T-cell regulation in rheumatoid arthritis. *Curr Opin Rheumatol.* 2004; 16:212-17.
2. Aringer M. T lymphocyte activation- an inside overview. *Acta Med Austriaca.* 2002; 29:7-12.
3. Bingham CO III. The pathogenesis of rheumatoid arthritis: pivotal cytokines involved in bone degradation and inflammation. *J Rheumatol suppl.* 2002; 65:3-9.
4. Suryaprasad AG and Prindiville T. The biology of TNF blockade. *Autoimmun Rev.* 2003; 2:346-57.
5. Panayi GS. B cells: a fundamental role in the pathogenesis of rheumatoid arthritis?. *Rheumatology.* 2005; 44(suppl.2): ii3-ii7.
6. Moreland LW. Drugs that block tumor necrosis factor: experience in patients with rheumatoid arthritis. *Pharmacoeconomics.* 2004; 39-53.
7. Desai SB, Furst DE. Problems encountered during anti-tumor necrosis factor therapy. *Best practice & Research Rheumatology.* 2006; 20(4):757-790.

8. Enbrel® (etanercept). Prescribing information. Amgen Inc. 2004.
9. Mohan N, Edwards ET, Cupps TR, et al. Demyelination occurring during anti-tumor necrosis factor alpha therapy for inflammatory arthritides. *Arthritis Rheum.* 2001 Dec; 44(12):2862-9.
10. Owens T and Sriram S. The immunology of multiple sclerosis and its animal model Experimental allergic encephalomyelitis. *Neurol Clin.* 1995; 13:51-73.
11. Kuroda Y and Shimamoto Y. Human tumor necrosis factor-alpha augments experimental allergic encephalomyelitis in rats. *J Neuroimmunol.* 1991; 34:159-64.
12. Baker D, Butler D, Scallon BJ, et al. Control of established experimental allergic encephalomyelitis by inhibition of tumor necrosis factor (TNF) activity within the central nervous system using monoclonal antibodies and TNF receptor immunoglobulin fusion proteins. *Eur J Immunol.* 1994; 24:2040-8.
13. Selmaj K, Raine CS, Cannella B, et al. Identification of lymphotoxin and tumor necrosis factor in multiple sclerosis lesions. *J Clin Invest* 1991; 87:949-954.
14. The Lenercept Multiple Sclerosis Study Group. TNF neutralization in multiple sclerosis: results of a randomized, placebo-controlled multicenter study. The Lenercept Multiple Sclerosis Study Group and the University of British Columbia MS/MRI Analysis Group. *Neurology.* 1999; 53:457-465.
15. van Oosten BW, Barkhof F, Truyen L, et al. Increased MRI activity and immune activation in two multiple sclerosis patients treated with monoclonal anti-tumor necrosis factor antibody Ca2. *Neurology.* 1996; 47:1531-1534.
16. Sukal SA, Nadiminti L and Granstein R. Etanercept and demyelinating disease in a patient with psoriasis. *J Am Acad Dermatol.* 2006; 54(1):160-164.
17. Mejico LS. Infliximab associated with retrobulbar optic neuritis. *Arch Ophthalmol.* 2004; 122: 793-794.
18. Freeman HJ and Flak B. Demyelination – like syndrome in Crohn's disease after infliximab therapy. *Canadian J Gastroenterology.* 2005; 19:313-316.
19. Thomas Jr, CW, Weinschenker BG and Sandborn WJ. Demyelination during anti-TNF alpha therapy with infliximab for Crohn's disease. *Inflammatory Bowel dis.* 2004; 10:28-31.
20. Sicotte NL and Voskuhl R. Onset of multiple sclerosis associated with anti-tumor necrosis factor therapy. *Neurology.* 2001; 57:1885-1888.
21. Fleischmann R, Baumgartner SW, Weisman MH, et al. Long-term safety of etanercept in elderly subjects with rheumatic diseases. *Ann Rheum Dis.* 2006; 65:379-384.
22. Horneff G, Schmeling H, Beidermann T, et al. The German etanercept registry for treatment of juvenile idiopathic arthritis. *Ann Rheum Dis.* 2004; 63:1638-1644.
23. Titelbaum DS, Degenhardt A and Kinkel RP. Anti-Tumor Necrosis Factor Alpha-Associated multiple sclerosis. *Am J Neuroradiol.* 2005; 26:1548-1550.
24. AL Saieg N and Luzar M. Etanercept induced multiple sclerosis and transverse myelitis. *J Rheumatology.* June 2006.
25. Ruiz-Jimeno T, Carvajal A, Mata C, et al. Demyelinating disease in a patient with psoriatic arthritis and family history of multiple sclerosis. *J Rheumatology.* July 2006.
26. Tanno M, Nakamura I, Kobayashi S, et al. New onset demyelination induced by Infliximab therapy in two rheumatoid arthritis patients. *Clin Rheumatol.* 2006; 25:929-933.