

Case Report

Ashley K. Clift, Henk Giele, Srikanth Reddy, Rubens Macedo, Adil Al-Nahas, Harpreet S. Wasan, Gabriel E. Gondolesi, Rodrigo M. Vianna, Peter Friend, Anil Vaidya and Andrea Frilling*

Neoadjuvant peptide receptor radionuclide therapy and modified multivisceral transplantation for an advanced small intestinal neuroendocrine neoplasm: an updated case report

<https://doi.org/10.1515/iss-2017-0025>

Received April 9, 2017; accepted August 2, 2017; previously published online August 25, 2017

Keywords: multivisceral; neoplasm; neuroendocrine; sentinel flap; transplantation.

Abstract: Small intestinal neuroendocrine neoplasms (SI-NEN) frequently metastasise to regional lymph nodes, and surgery is the mainstay of therapy for such patients. However, despite the possible use of advanced surgical techniques, the resection of both primary and locoregional diseases is not always attainable. Intestinal and multivisceral transplantation has been performed in a small number of patients with conventionally nonresectable, slow-growing tumours threatening the mesenteric root but has remained controversial. The use of donor skin in “sentinel flaps” in transplantation theoretically offers advantages in tailoring immunosuppression and monitoring for rejection. We represent (with extended follow-up) the first case of a patient with inoperable extensive mesenteric metastases from SI-NEN, who underwent neoadjuvant peptide receptor radionuclide therapy before a modified multivisceral transplant with a concomitant vascularised sentinel forearm flap. At 48 months after transplantation, our patient remained at full physical activity with no evidence of disease recurrence on either tumour biochemistry or radiological imaging.

Introduction

Neuroendocrine neoplasms (NEN) represent the commonest type of small intestinal (SI) tumours [1, 2]. Despite their relative indolence in terms of survival time compared to SI adenocarcinomas, SI-NEN display a strong predilection for nodal and distant metastasis, namely to the mesentery and the liver, respectively. Indeed, although the majority of SI-NEN are low-grade, well-differentiated entities, institutional case series have demonstrated that the identification of regional lymph node metastases at initial presentation may approach 90% [3]. Accordingly, the surgical intervention for disease control often encompasses the extirpation of locoregional disease and also the resection of hepatic deposits if present and surgery is recognised as the cornerstone in therapeutic strategy in patients with resectable disease [4, 5].

The aggressive surgical management of regional deposits is mandated in patients with extensive mesenteric spread, given the risks of intestinal obstruction and encasement of superior mesenteric vessels causing intestinal ischaemia. Although several complex methods have been developed to render previously unresectable tumours (i.e. those in apposition to the coeliac and superior mesenteric vessels or with retroperitoneal extension) amenable to surgery, such as ultrasound-guided superior mesenteric vein stenting [6], free dissection of the superior mesenteric artery and vein at the inferior pancreatic border [7] and multivisceral *ex vivo* autotransplantation [8, 9], many patients still suffer from unresectable disease.

The relatively newly embraced concept of “transplantation oncology” has occupied a small albeit highly controversial role in intra-abdominal tumours, including NEN. Orthotopic liver transplantation is an increasingly accepted option in highly selected patients with NEN

*Corresponding author: **Andrea Frilling**, Department of Surgery and Cancer, Imperial College London, Hammersmith Hospital, Du Cane Road, London, W12 0HS, UK, Phone: +44 203 133 210, Fax: +44 203 132 037, E-mail: a.frilling@imperial.ac.uk

Ashley K. Clift and Harpreet S. Wasan: Department of Surgery and Cancer, Imperial College London, London, UK

Henk Giele and Anil Vaidya: Department of Plastic and Reconstructive Surgery, Oxford University NHS Trust, Oxford, UK

Srikanth Reddy, Rubens Macedo and Peter Friend: Oxford Transplant Centre, Oxford University NHS Trust, Oxford, UK

Adil Al-Nahas: Department of Nuclear Medicine, Imperial College London, London, UK

Gabriel E. Gondolesi: Instituto de Trasplante Multiorganos, Fundacion Favaloro, Buenos Aires, Argentina

Rodrigo M. Vianna: Miami Transplant Institute, University of Miami/Jackson Memorial Hospital, Miami, FL, USA

metastatic to the liver [10], with recent reports inferring outcomes similar to those observed in hepatocellular carcinoma [11, 12]. Experience with SI and multivisceral transplantation (MVT; with or without the liver) for slow-growing intra-abdominal tumours such as NEN threatening the mesenteric root is limited, although outcomes associated with allografts containing the SI in general appear to be improving [13, 14]. A number of small case series including patients with NEN have been reported, predominantly from Scandinavian centres (Table 1) [11, 15–18]. Lastly, a relatively new approach in transplantation surgery is the vascularised sentinel forearm flap (VSFF) notably used in facial transplantation. A VSFF comprises a skin allograft obtained from the same donor as another composite tissue graft and enables the monitoring for immune rejection via monitoring the transplanted area on the recipient's forearm [19, 20]. Briefly, the theoretical basis of using a VSFF is that the appearance of a rash on the graft may indicate a rejection reaction suggestive of concomitant rejection of the “primary” graft, in this case, the intra-abdominal allograft. The careful monitoring of this sentinel site has obvious ramifications on immunosuppression and may accordingly permit the tailoring of immunosuppressive regimens.

Here, we present the extended follow-up data for a patient with SI-NEN with unresectable bulky mesenteric metastases managed with peptide receptor radionuclide therapy (PRRT) before undergoing combined modified liver-free MVT (MMVT) and a VSFF from the same donor. The initial report on this patient was published by our group in 2015 [21]. This is the first case of its type to demonstrate the use of PRRT as a neoadjuvant concept in MMVT and also to implement the use of a VSFF as a tool

for proactive monitoring of immunosuppression in MMVT for a NEN.

The case – initial investigations

Our male patient presented at age 44 with haematuria and intermittent abdominal pain in 2009. There were no other symptoms or any significant previous medical or family history. A standard computed tomography (CT) scan of the abdomen was performed, which demonstrated a complex and partially calcified left-sided renal cyst, and also identified within the mesentery a suspicious 10×9×6 cm heterogeneously enhancing mass. The latter was subjected to ultrasound-guided biopsy, in which histopathology confirmed to be a well-differentiated grade 1 (Ki-67 <1%) NEN with clear expression of the archetypal neuroendocrine markers synaptophysin and chromogranin A (CgA) evident on immunohistochemical analysis. Subsequent routine NEN-specific biochemistry included serum CgA and chromogranin B (CgB) and urinary 5-hydroxyindoleacetic acid (5-HIAA) in 24 h urine – all were markedly elevated relative to reference ranges: 395 pmol/L (0–60 pmol/L), 349 pmol/L (0–150 pmol/L) and 643 μmol/L (0–40 μmol/L), respectively.

The patient subsequently underwent imaging with ⁶⁸Ga-DOTATATE positron emission tomography (PET)/CT, which demonstrated marked radiotracer uptake in the aforementioned mesenteric mass [standard uptake value (SUV) = 27] and in a lymph node in the aortocaval groove (SUV = 10). Thereafter, after multidisciplinary and patient discussion, it was decided that the patient would undergo

Table 1: Overview of previously published experience with multivisceral transplantation for neuroendocrine tumours.

Author (year)	Cohort size (NEN)	Percentage with liver metastases	Primary tumour location/type	Recurrence data	Survival data
Tzakis et al. (2012) [8]	2	N/S	‘Carcinoid’, VIPoma	24-months post-transplant in 1 patient	Death of recurrent disease at 24-months in 1 patient
Olausson et al. (2007) [15]	5	100%	Pancreas	25-months and 48-months post-transplant in 1 patient each, respectively	2 deaths within 4-months post-transplant; 1 death at 27 months post-transplant
Gedaly et al. (2011) [11]	13	100%	N/S	23% at 1-year, 50% at 3-years, and 68% at 5-years, post-transplant	80% overall survival at 1-year, 64% at 3-years, 48% at 5-years
Mangus et al. (2013) [16]	4	100%	Insulinoma, gastrinoma, ‘carcinoid’, VIPoma	10-months and 23-months post-transplant in 1 patient each, respectively	1 death at 10 months post-transplant
Varkey et al. (2013) [17]	6	100%	Pancreas	100%	67% at 2 years

NEN, neuroendocrine neoplasms; N/S, not specified; VIPoma, vasoactive intestinal peptide-oma.

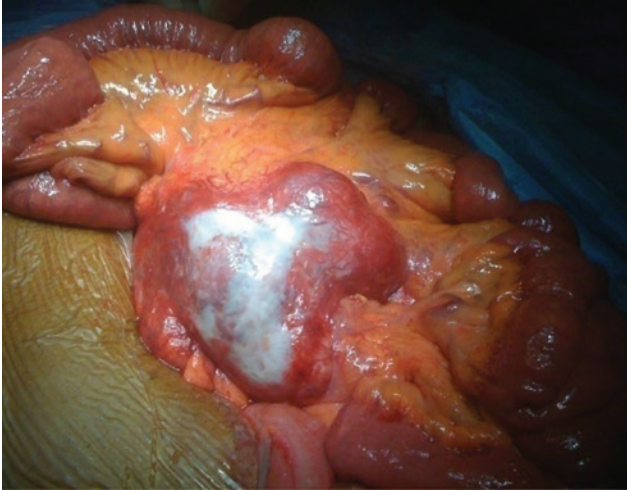


Figure 1: Bulky mesenteric lymph node metastases as observed at laparotomy.

an exploratory laparotomy in April 2010. This identified a stage IV (i.e. extending retroperitoneally) tumour bulk, which was circumferentially encasing the mesenteric vessels (Figure 1). Meticulous intraoperative exploration and ultrasound elucidated several additional, mostly sub-centimetre, lymph nodes scattered through the mesentery close to the ileum but no evidence of hepatic metastases.

On a multicentre, multidisciplinary team discussion of therapeutic strategy in this conventionally unresectable tumour, the option of MMVT was raised and the patient was referred to the Oxford Transplant Centre for formal review with regard to possible intestinal transplantation.

Clinical management

Given the setting of unresectable, metastatic disease from a low-grade NEN, the patient received four cycles of PRRT with ^{177}Lu -DOTATATE. Each cycle was administered after 12-week intervals with a cumulative radiation dose of 28 GBq, with no adverse effects associated with treatment. Standard nephroprotective amino acid infusions were administered. Post-PRRT ^{68}Ga -DOTATATE PET/CT in February 2013 did not identify any additional sites of disease or progression in size of the previously identified lesions, but the SUV had increased in both the mesenteric bulk and the aortocaval node (Figure 2). Tumour biochemistry values had also increased throughout PRRT, with post-PRRT CgA and CgB results of 2200 pmol/L (initially 395 pmol/L) and 450 pmol/L (initially 349 pmol/L), respectively.

The patient underwent MMVT with VSFF at the Oxford Transplant Centre in March 2013. During operation, the

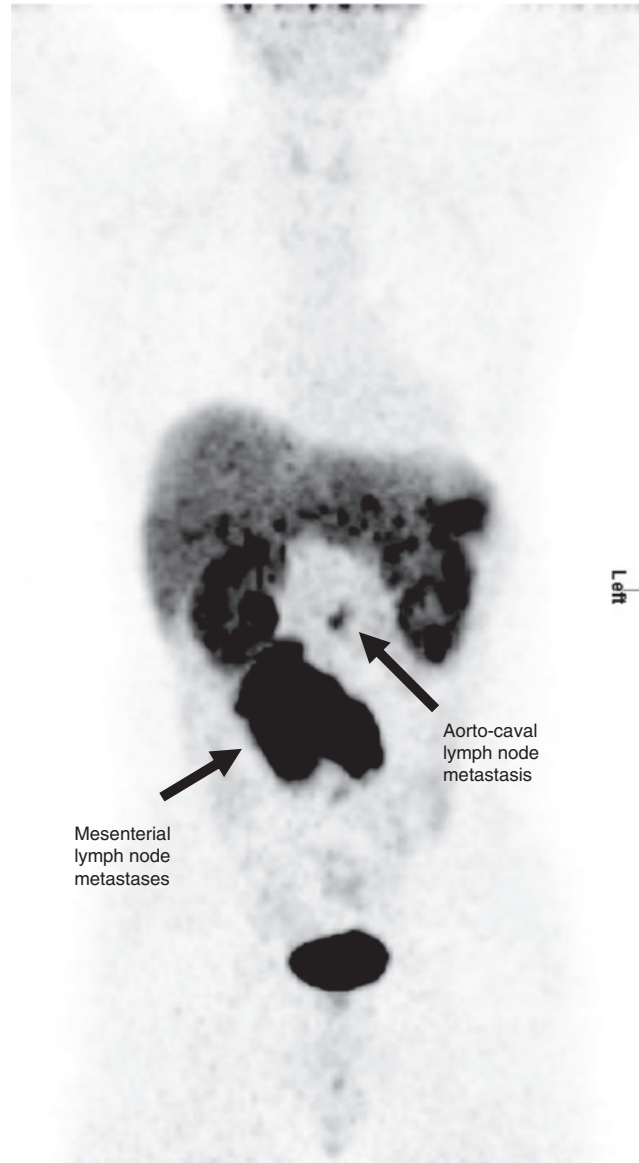


Figure 2: Pretreatment ^{68}Ga -DOTATATE PET imaging clearly demonstrating pathological radiotracer uptake corresponding to mesenteric metastases and also a lymph node metastasis in the aortocaval groove.

mesenteric mass was noted to now involve both the duodenum and the pancreas, but there was still no evidence of liver metastases. As part of the MMVT, the stomach, pancreas, spleen, SI and right and transverse colon were exenterated, and the aortocaval lymph node was resected. The donor thoracic aorta was used to construct a “jump” graft from the recipient thoracic aorta to act as an arterial supply to the multivisceral graft. The venous return for the graft was constructed by means of a portal-portal anastomosis. A temporary ileostomy was formed.

The VSFF was retrieved from the same donor and comprised a 10×5 cm elliptoid composite skin island flap

derived from the territory overlying the radial artery, with subcutaneous tissues, fascia, cephalic vein, lateral cutaneous nerve and the radial artery with venae comitantes. In the recipient, an incision under a tourniquet was made over the ulnar artery territory of the left arm (nondominant) and deepened to the artery and its venae comitantes. The VSFF was flushed with a cold preservative solution immediately after retrieval, transported without freezing and ultimately revascularised with an anastomosis between the donor's radial artery and the recipient's ulnar artery on the left arm. The venous outflow for the VSFF was established by the connection of donor and recipient venae comitantes and anastomosis between the donor's cephalic vein and the recipient's basilic vein. Lastly, the donated lateral cutaneous nerve was coapted to a branch of the recipient's medical cutaneous nerve.

Regarding immunosuppression, the reperfusion of transplanted organs was covered with 500 mg methylprednisolone, and induction immunosuppression included 30 mg intravenous alemtuzumab (Campath) within 6 h of reperfusion, with a second dose 24 h later. Initial maintenance immunosuppression used tacrolimus with target trough levels between 8 and 12 ng/mL. The immediate postoperative course was uneventful.

The histopathological analysis of the resected tumour confirmed a well-differentiated, grade 1, multifocal SI NEN (7 tumours up to 11 mm in size) with attendant large mesenteric lymph node metastases up to 120 mm in size encasing the mesenteric vessels. Disease stage was confirmed as $pT_3N_1M_0L_1V_0R_0$ using the ENETS/WHO criteria [22]. Immunohistochemical analyses again demonstrated strong expression of chromogranin and synaptophysin, focal expression of CK19 and no expression of glucagon, insulin, gastrin, and somatostatin.

Two months after transplantation, the patient underwent a biopsy of his VSFF due to a maculopapular rash suggestive of rejection. The diagnosis of acute rejection was made in accordance with the Banff 2007 Working Classification of Skin-Containing Composite Tissue Allograft Pathology classification [23]. Endoscopy with intestinal biopsy was performed, which demonstrated no evidence of rejection in the abdominal organ graft. Therefore, the patient was treated with three 500 mg doses of methylprednisolone and topical tacrolimus cream, with which the rash resolved completely. A daily dose of 10 mg oral prednisolone was added to the patient's maintenance immunosuppression regimen.

The patient successfully underwent an uncomplicated reversal of his ileostomy in January 2014, and on his last follow-up 48 months after transplantation, he remained on full enteral nutrition with a stable weight

and at full physical activity. His NEN-related serum (CgA and CgB) and urine (5-HIAA) biochemical markers normalised after transplantation and have remained within reference ranges throughout follow-up. Furthermore, routine follow-up imaging with magnetic resonance imaging (MRI) or CT every 6 months and ^{68}Ga -DOTATATE PET/CT annually have yet to identify any evidence of disease recurrence.

Discussion

Contrary to the increasingly accepted role within the armamentarium for liver transplantation in metastatic gastrointestinal NEN, the use of multivisceral allografts attracts considerably more controversy. Although initial results with the former were disappointing, the development of strict patient selection criteria and advances in immunosuppression have resulted in favourable outcomes that are not significantly inferior to those observed in hepatocellular carcinoma [10, 24]. Five-year overall survival after orthotopic liver transplantation for metastatic NEN may reach 90% in recent case series, justifying its use as a well-timed (i.e. not a "last resort") intervention in carefully selected patients with nonresectable liver metastases [4]. Furthermore, recent evidence has suggested a significant benefit to liver transplantation over nontransplant techniques [25]. Nevertheless, 5-year recurrence rates may range between 50% and 90% [12, 26–28], which highlights the known difficulties with the insidiously progressive behaviour of low-grade NEN and also the necessity of novel strategies facilitating long-term control both neoadjuvant and adjuvant in nature.

Experience with intestinal transplantation and MVT in general is steadily growing, with reported indications including abdominal catastrophes and slow-growing intra-abdominal tumours, such as NEN. As aforementioned, this arena within the realm of transplant oncology is highly debated due to disparities in outcomes from different centres. The report by Gedaly et al. [11] described the use of MVT in 13 patients with NEN (primary tumour origin not clearly stated) associated with 1-, 3- and 5-year survival of 80%, 64% and 48%, respectively, whereas in a series of 10 NEN patients with liver metastases treated at Indiana University over 8 years, an overall survival rate of 80% was attained (personal communication [16]). A more cautious outlook has been advocated by Varkey et al. [17] in their report of 6 patients with metastatic pancreatic NEN, demonstrating a 67% overall survival at 2 years. With small sample sizes, variation in the quality

of documentation in case reports/series, and different primary tumour sites, the evidence regarding MVT/MMVT for NEN is far from conclusive. Of the approximately 30 cases of intestinal transplantation/MVT for NEN reported, to our knowledge, none have clearly detailed the procedures and outcomes specifically in SB NEN.

Our strategy in this patient centred on four facets:

1. Use of PRRT as a neoadjuvant modality,
2. Radical removal of a classically nonresectable tumour,
3. Restoration of abdominal anatomy and physiology with a multivisceral graft, and
4. Use of a second soft-tissue graft from the donor to aid posttransplant management.

The use of PRRT in metastatic, unresectable, low-to-intermediate grade NEN that exhibit high expression of somatostatin receptors may attain tumour response rates of approximately 33% [29–31]. There have also been a small number of reports in which PRRT has been used as a neoadjuvant therapy in NEN, specifically to attempt to downsize tumours and render them resectable [32–35]. To our knowledge, our report is the first to report the use of PRRT as a neoadjuvant therapy specifically in transplantation. A major concern in our patient was that, despite the lack of evidence of hepatic disease on morphological and functional imaging, micrometastases not detectable with these methods may have existed and could have subsequently manifested throughout a period of immunosuppression. Indeed, currently available gold-standard imaging methods significantly underestimate true disease burden by up to 50% [36]. Given the strong avidity of this patient's disease for somatostatin receptor-targeted imaging tracers, the patient was offered PRRT with ¹⁷⁷Lu-DOTATATE before radical treatment with an aim to treat/stabilise the main tumour bulk and eradicate microdisease. An “all-in-one” approach to transplantation avoided the risks of managing an ultra-short gut with a high output stoma, plus deterioration in liver function with total parenteral nutrition that would have presented if we had proceeded with intestinal exenteration with transplantation on a later date.

The theoretical benefits of a sentinel marker in solid-organ transplantation include the noninvasive monitoring of immunosuppression with possible ramifications on preventing rejection and avoiding the morbidity associated with excessive immunosuppression. Our rationale for concomitant transplantation of a VSFF was to aid the clinical team in distinguishing between possible causes of posttransplant bowel dysfunction should they arise, specifically infective causes or an immunological rejection, which would be characterised by the lack of and

presence of a rash, respectively. Although the histopathological appearances of both phenomena may be similar, the treatments for each are obviously different. The use of a VSFF has been documented in facial transplantation [37]. The usefulness of skin more generally as an immunological tool has also been reported in abdominal wall transplantation, where it may serve as an immune modulator resulting in improved graft survival, lower rejection rates, and lower rates of incorrectly diagnosed rejection in patients receiving solid-organ transplants and abdominal wall transplants [38].

In conclusion, this case represents a truly novel approach to the treatment of metastatic SI NEN due to its unique integration of several treatment concepts. Given the favourable outcome documented so far, specifically a lack of both biochemical and radiological disease recurrence and that the patient remains at full physical activity at 4 years of follow-up, we believe that this approach could be used in other, strictly selected patients in the future.

Acknowledgments: The authors would like to thank the patient for their consent to present their case in this report.

Author Statement

Research funding: Authors state no funding involved. Conflict of interest: Authors state no conflict of interest. Informed consent: Informed consent has been obtained from the individual included in this study. Ethical approval: The research related to human use complied with all the relevant national regulations and institutional policies and was performed in accordance with the tenets of the Helsinki Declaration, and has been approved by the authors' institutional review board.

Author Contributions

Ashley Kieran Clift: Data curation; Formal analysis; Investigation; Project administration; Writing – original draft; Writing – review and editing. Henk Giele: Conceptualization; Formal analysis; Methodology; Clinician involved in patient care. Srikanth Reddy: Conceptualization; Formal analysis; Methodology; Writing – original draft; Clinician involved in patient care. Rubens Macedo: Conceptualization; Formal analysis; Methodology; Writing – original draft; Clinician involved in patient care. Adil Al-Nahhas: Conceptualization; Formal analysis; Methodology; Writing – original draft; Clinician involved in patient care. Harpreet Wasan: Conceptualization; Formal analysis; Methodology; Writing – original draft; Clinician involved in patient care. Gabriel Gondolesi: Formal

analysis; Methodology; Supervision; Writing – original draft. Rodrigo Vianna: Data curation; Formal analysis; Supervision; Writing – original draft. Peter Friend: Conceptualization; Formal analysis; Investigation; Writing – original draft; Writing – review and editing; Clinician involved in patient care. Anil Vaidya: Conceptualization; Formal analysis; Methodology; Writing – original draft; Writing – review and editing; Clinician involved in patient care. Andrea Frilling: Conceptualization; Formal analysis; Methodology; Supervision; Writing – original draft; Writing – review and editing; Clinician involved in patient care.

References

- [1] Pan SY, Morrison H. Epidemiology of cancer of the small intestine. *World J Gastrointest Oncol* 2011;3:33–42.
- [2] Bilimoria KY, Bentrem DJ, Wayne JD, Ko CY, Bennett CL, Talamonti MS. Small bowel cancer in the United States: changes in epidemiology, treatment, and survival over the last 20 years. *Ann Surg* 2009;249:63–71.
- [3] Miller HC, Drymoussis P, Flora R, Goldin R, Spalding D, Frilling A. Role of Ki-67 proliferation index in the assessment of patients with neuroendocrine neoplasias regarding the stage of disease. *World J Surg* 2014;38:1353–61.
- [4] Frilling A, Clift AK. Therapeutic strategies for neuroendocrine liver metastases. *Cancer* 2015;121:1172–86.
- [5] Norlén O, Ståhlberg P, Öberg K, et al. Long-term results of surgery for small intestinal neuroendocrine tumors at a tertiary referral center. *World J Surg* 2012;36:1419–31.
- [6] Hellman P, Hessman O, Akerström G, et al. Stenting of the superior mesenteric vein in midgut carcinoid disease with large mesenteric masses. *World J Surg* 2010;34:1373–9.
- [7] Ohrvall U, Eriksson B, Juhlin C, et al. Method for dissection of mesenteric metastases in mid-gut carcinoid tumors. *World J Surg* 2000;24:1402–8.
- [8] Tzakis AG, Pararas NB, Tekin A, et al. Intestinal and multivisceral autotransplantation for tumors of the root of the mesentery: long-term follow-up. *Surgery* 2012;152:82–9.
- [9] Kato T, Lobritto SJ, Tzakis A, et al. Multivisceral ex vivo surgery for tumors involving celiac and superior mesenteric arteries. *Am J Transplant* 2012;12:1323–8.
- [10] Vilchez V, Gedaly R. Liver transplantation for the treatment of neuroendocrine liver metastases. *Best Pract Res Clin Endocrinol Metab* 2016;30:141–7.
- [11] Gedaly R, Daily MF, Davenport D, et al. Liver transplantation for the treatment of liver metastases from neuroendocrine tumors: an analysis of the UNOS database. *Arch Surg* 2011;146:953–8.
- [12] Le Treut YP, Grégoire E, Klempnauer J, et al. Liver transplantation for neuroendocrine tumors in Europe—results and trends in patient selection: a 213-case European liver transplant registry study. *Ann Surg* 2013;257:807–15.
- [13] Grant D, Abu-Elmagd K, Reyes J, et al. 2003 report of the intestine transplant registry: a new era has dawned. *Ann Surg* 2005;241:607–13.
- [14] Sudan D. The current state of intestine transplantation: indications, techniques, outcomes and challenges. *Am J Transplant* 2014;14:1976–84.
- [15] Olausson M, Friman S, Herlenius G, et al. Orthotopic liver or multivisceral transplantation as treatment of metastatic neuroendocrine tumors. *Liver Transpl* 2007;13:327–33.
- [16] Mangus RS, Tector AJ, Kubal CA, Fridell JA, Vianna RM. Multivisceral transplantation: expanding indications and improving outcomes. *J Gastrointest Surg* 2013;17:179–87.
- [17] Varkey J, Simrén M, Bosaeus I, Krantz M, Gäbel M, Herlenius G. Survival of patients evaluated for intestinal and multivisceral transplantation – the Scandinavian experience. *Scand J Gastroenterol* 2013;48:702–11.
- [18] Tzakis AG, Kato T, Levi DM, et al. 100 multivisceral transplants at a single center. *Ann Surg* 2005;242:480–93.
- [19] Zamfirescu DG, Owen E, Lascar I, et al. Sentinel skin allograft – a reliable marker for monitoring of composite tissue transplant rejection. *Transplant Proc* 2009;41:503–8.
- [20] Pomahac B, Pribaz J, Eriksson E, et al. Three patients with full facial transplantation. *N Engl J Med* 2012;366:715–22.
- [21] Frilling A, Giele H, Vrakas G, et al. Modified liver-free multivisceral transplantation for a metastatic small bowel neuroendocrine tumor: a case report. *Transplant Proc* 2015;47:858–62.
- [22] Rindi G, Klöppel G, Couvelard A, et al. TNM staging of midgut and hindgut (neuro) endocrine tumors: a consensus proposal including a grading system. *Virchows Arch* 2007;451:757–62.
- [23] Cendales LC, Kanitakis J, Schneeberger S, et al. The Banff 2007 working classification of skin-containing composite tissue allograft pathology. *Am J Transplant* 2008;8:1396–400.
- [24] Nguyen NT, Harring TR, Goss JA, O’Mahony CA. Neuroendocrine liver metastases and orthotopic liver transplantation: the US experience. *Int J Hepatol* 2011;2011:742890.
- [25] Mazzaferro V, Sposito C, Coppa J, et al. The long-term benefit of liver transplantation for hepatic metastases from neuroendocrine tumors. *Am J Transplant* 2016;16:2892–902.
- [26] Florman S, Toure B, Kim L, et al. Liver transplantation for neuroendocrine tumors. *J Gastrointest Surg* 2004;8:208–12.
- [27] Frilling A, Malago M, Weber F, et al. Liver transplantation for patients with metastatic endocrine tumors: single-center experience with 15 patients. *Liver Transpl* 2006;12:1089–96.
- [28] van Vilsteren FG, Baskin-Bey ES, Nagorney DM, et al. Liver transplantation for gastroenteropancreatic neuroendocrine cancers: defining selection criteria to improve survival. *Liver Transpl* 2006;12:448–56.
- [29] Campana D, Capurso G, Partelli S, et al. Radiolabelled somatostatin analogue treatment in gastroenteropancreatic neuroendocrine tumours: factors associated with response and suggestions for therapeutic sequence. *Eur J Nucl Med Mol Imaging* 2013;40:1197–205.
- [30] Villard L, Romer A, Marincek N, et al. Cohort study of somatostatin-based radiopeptide therapy with [(90)Y-DOTA]-TOC versus [(90)Y-DOTA]-TOC plus [(177)Lu-DOTA]-TOC in neuroendocrine cancers. *J Clin Oncol* 2012;30:1100–6.
- [31] Imhof A, Brunner P, Marincek N, et al. Response, survival, and long-term toxicity after therapy with the radiolabeled somatostatin analogue [90Y-DOTA]-TOC in metastasized neuroendocrine cancers. *J Clin Oncol* 2011;29:2416–23.

- [32] Sowa-Staszczak A, Pach D, Chrzan R, et al. Peptide receptor radionuclide therapy as a potential tool for neoadjuvant therapy in patients with inoperable neuroendocrine tumours (NETs). *Eur J Nucl Med Mol Imaging* 2011;38:1669–74.
- [33] Kaemmerer D, Prasad V, Daffner W, et al. Neoadjuvant peptide receptor radionuclide therapy for an inoperable neuroendocrine pancreatic tumor. *World J Gastroenterol* 2009;15:5867–70.
- [34] Stoeltzing O, Loss M, Huber E, et al. Staged surgery with neoadjuvant 90Y-DOTATOC therapy for down-sizing synchronous bilobular hepatic metastases from a neuroendocrine pancreatic tumor. *Langenbecks Arch Surg* 2010;395:185–92.
- [35] van Vliet EI, van Eijck CH, de Krijger RR, et al. Neoadjuvant treatment of nonfunctioning pancreatic neuroendocrine tumors with [¹⁷⁷Lu-DOTA0,Tyr3]octreotate. *J Nucl Med* 2015;56:1647–53.
- [36] Elias D, Lefevre JH, Duvillard P, et al. Hepatic metastases from neuroendocrine tumors with a “thin slice” pathological examination: they are many more than you think. *Ann Surg* 2010;251:307–10.
- [37] Kueckelhaus M, Imanzadeh A, Fischer S, et al. Noninvasive monitoring of immune rejection in face transplant recipients. *Plast Reconstr Surg* 2015;136:1082–9.
- [38] Gerlach UA, Vrakas G, Sawitzki B, et al. Abdominal wall transplantation: skin as a sentinel marker for rejection. *Am J Transplant* 2016;16:1892–900.

Supplemental Material: The article (<https://doi.org/10.1515/iss-2017-0025>) offers reviewer assessments as supplementary material.



Reviewer Assessment

Ashley K. Clift, Henk Giele, Srikanth Reddy, Rubens Macedo, Adil Al-Nahas, Harpreet S. Wasan, Gabriel E. Gondolesi, Rodrigo M. Vianna, Peter Friend, Anil Vaidya and Andrea Frilling*

Neoadjuvant peptide receptor radionuclide therapy and modified multivisceral transplantation for an advanced small intestinal neuroendocrine neoplasm: an updated case report

<https://doi.org/10.1515/iss-2017-0025>

Received April 9, 2017; accepted August 2, 2017

*Corresponding author: **Andrea Frilling**, Department of Surgery and Cancer, Imperial College London, Hammersmith Hospital, Du Cane Road, London, W12 0HS, UK, Phone: +44 203 133 210, Fax: +44 203 132 037, E-mail: a.frilling@imperial.ac.uk

Reviewers' Comments to Original Submission

Reviewer 1: anonymous

May 02, 2017

Reviewer Recommendation Term:	Revise with Major Modification
Overall Reviewer Manuscript Rating:	N/A
Custom Review Questions	Response
Is the subject area appropriate for you?	3
Does the title clearly reflect the paper's content?	4
Does the abstract clearly reflect the paper's content?	4
Do the keywords clearly reflect the paper's content?	2
Does the introduction present the problem clearly?	4
Are the results/conclusions justified?	3
How comprehensive and up-to-date is the subject matter presented?	3
How adequate is the data presentation?	2
Are units and terminology used correctly?	3
Is the number of cases adequate?	3
Are the experimental methods/clinical studies adequate?	3
Is the length appropriate in relation to the content?	4
Does the reader get new insights from the article?	4
Please rate the practical significance.	2
Please rate the accuracy of methods.	3
Please rate the statistical evaluation and quality control.	3
Please rate the appropriateness of the figures and tables.	1 - Low/No
Please rate the appropriateness of the references.	4
Please evaluate the writing style and use of language.	3
Please judge the overall scientific quality of the manuscript.	3
Are you willing to review the revision of this manuscript?	Yes

Comments to Authors:

This manuscript represents an update of a case-report previously published in 2015. The manuscript depicts some interesting Points (i.e. the follow-up after two years without evidence of relapse) and describes an infrequent clinical course and therefore is potentially publishable.

However, the figures are exactly the same as used in the first publication of this case-report and are redundant. More interesting would be to show intraoperative photos or ones of the VSFF!!!

Minor points:

What is the reason for the delay between diagnosis (2009) and initial laparotomy (April 2010)

The language and style needs revision

Reviewer 2: anonymous

Apr 16, 2017

Reviewer Recommendation Term:	Reject
Overall Reviewer Manuscript Rating:	10

Custom Review Questions**Response**

Is the subject area appropriate for you?	5 - High/Yes
Does the title clearly reflect the paper's content?	3
Does the abstract clearly reflect the paper's content?	3
Do the keywords clearly reflect the paper's content?	3
Does the introduction present the problem clearly?	3
Are the results/conclusions justified?	3
How comprehensive and up-to-date is the subject matter presented?	3
How adequate is the data presentation?	3
Are units and terminology used correctly?	3
Is the number of cases adequate?	N/A
Are the experimental methods/clinical studies adequate?	N/A
Is the length appropriate in relation to the content?	3
Does the reader get new insights from the article?	1 - Low/No
Please rate the practical significance.	2
Please rate the accuracy of methods.	N/A
Please rate the statistical evaluation and quality control.	N/A
Please rate the appropriateness of the figures and tables.	2
Please rate the appropriateness of the references.	3
Please evaluate the writing style and use of language.	3
Please judge the overall scientific quality of the manuscript.	1 - Low/No
Are you willing to review the revision of this manuscript?	Yes

Comments to Authors:

There are no new informations compared to the article from 2015 (Modified Liver-free Multivisceral Transplantation for a Metastatic Small Bowel Neuroendocrine Tumor: A Case Report), even the images are completely the same. I cannot see the necessity to publish the case report again.

Reviewer 3: Klaus-Martin Schulte

Jun 20, 2017

Reviewer Recommendation Term:	Accept with Minor Revision
Overall Reviewer Manuscript Rating:	80

Custom Review Questions**Response**

Is the subject area appropriate for you?	3
--	---

Does the title clearly reflect the paper's content?	5 - High/Yes
Does the abstract clearly reflect the paper's content?	5 - High/Yes
Do the keywords clearly reflect the paper's content?	5 - High/Yes
Does the introduction present the problem clearly?	5 - High/Yes
Are the results/conclusions justified?	5 - High/Yes
How comprehensive and up-to-date is the subject matter presented?	5 - High/Yes
How adequate is the data presentation?	4
Are units and terminology used correctly?	5 - High/Yes
Is the number of cases adequate?	2
Are the experimental methods/clinical studies adequate?	N/A
Is the length appropriate in relation to the content?	4
Does the reader get new insights from the article?	5 - High/Yes
Please rate the practical significance.	4
Please rate the accuracy of methods.	N/A
Please rate the statistical evaluation and quality control.	N/A
Please rate the appropriateness of the figures and tables.	4
Please rate the appropriateness of the references.	5 - High/Yes
Please evaluate the writing style and use of language.	4
Please judge the overall scientific quality of the manuscript.	4
Are you willing to review the revision of this manuscript?	Yes

Comments to Authors:

Thank you for this interesting contribution which can be published as it stands - following some minor corrections only: see attached document.

Authors' Response to Reviewer Comments

Jul 23, 2017

Reviewer comments:

Reviewer #1:

This manuscript represents an update of a case-report previously published in 2015. The manuscript depicts some interesting Points (i.e. the follow-up after two years without evidence of relapse) and describes an infrequent clinical course and therefore is potentially publishable.

However, the figures are exactly the same as used in the first publication of this case-report and are redundant. More interesting would be to show intraoperative photos or ones of the VSFF!!!

Reply: We thank this reviewer for their kind appraisal and finding that our manuscript is potentially publishable. The submitted manuscript included the intra-operative image of the bulky mesenteric metastases as visualised at laparotomy, and further images (intra-operative or of the VSFF) would surely add to the revised manuscript. However, we regret that these are not available. We also realise that the figures of the functional imaging are the same as those in a previous publication. However, we believe that these have a valuable role in this updated case report as: 1) Innovative Surgical Sciences undoubtedly has wider target readership than the journal that the original case report was published in, and many readers may not have read the first article; and 2) the images clearly demonstrate the challenging presentation of this case.

Minor points:

What is the reason for the delay between diagnosis (2009) and initial laparotomy (April 2010)

The language and style needs revision

Reply: The reviewer is indeed correct in identifying this seemingly relatively protracted delay between diagnosis and initial laparotomy. This is due to a combination of patient factors (deciding whether or not to pursue the option of aggressive treatment) and multidisciplinary discussion regarding the scope for curative management. We have added a short sentence to the revised manuscript to detail this to future readers.

We do wish to be able to comply with all reviewer comments. However, we humbly believe that the remark to revise language and style is somewhat vague and we are unable to identify the specific aspects of the article that the reviewer would like us to restructure or amend. We have however, made some language edits as suggested by another reviewer (please see below).

Reviewer #2:

There are no new informations compared to the article from 2015 (Modified Liver-free Multivisceral Transplantation for a Metastatic Small Bowel Neuroendocrine Tumor: A Case Report), even the images are completely the same. I cannot see the necessity to publish the case report again.

Reply: We wish to express our gratitude to this reviewer for their careful consideration of our manuscript. However, we respectfully disagree with this reviewer comment as our updated case report has not only prolonged follow-up (which is absolutely essential in any study of neuroendocrine tumour disease given their relative indolence as compared to adenocarcinomas), but further evidence of disease control (i.e. the patient is still biochemically and radiologically tumour free in a hitherto unresectable and thus incurable tumour). It also has a broader discussion of the indications and rationale for this approach. We find that this reviewer comment contrasts with those of the other reviewers, which were more favourable.

Reviewer #3:

Thank you for this interesting contribution which can be published as it stands - following some minor corrections only: see attached document.

Reply: We wish to thank this reviewer for their very kind appraisal. Accordingly, we are glad to revise the manuscript according to their suggestions – these have been clearly marked in red in the revised manuscript

Editor comments: more and better documentation regarding the use of the flaps, this could include a picture; information on the function of the transplant (like BMI); an overview of the actually used immunosuppression and how this compared to patients without flaps looks like; a table on the cases of duodenal or composite transplants in NET or other primary tumors of the duodenum.

Reply: We thank the Editor for their contributions to reviewing our paper, and for their constructive suggestions. Accordingly, we have added a short explanation of the function of the transplant (see the Introduction, end of paragraph 3, marked in red), as well as a table summarising cases of other small intestinal/composite transplants in NET (now Table 1). Unfortunately, the documentation of immunosuppressive regimens used in multivisceral transplantation in NET is not of a high standard across the case reports/series (a contributory factor may be the typically 'mixed' nature of the study cohorts) and therefore including this data in a meaningful way would be challenging.

Reviewers' Comments to Revision

Reviewer 1: anonymous

Jul 24, 2017

Reviewer Recommendation Term:	Accept
Overall Reviewer Manuscript Rating:	40
Custom Review Questions	Response
Is the subject area appropriate for you?	3
Does the title clearly reflect the paper's content?	3
Does the abstract clearly reflect the paper's content?	3
Do the keywords clearly reflect the paper's content?	3
Does the introduction present the problem clearly?	4
Are the results/conclusions justified?	3
How comprehensive and up-to-date is the subject matter presented?	2
How adequate is the data presentation?	3

Are units and terminology used correctly?	3
Is the number of cases adequate?	N/A
Are the experimental methods/clinical studies adequate?	N/A
Is the length appropriate in relation to the content?	4
Does the reader get new insights from the article?	3
Please rate the practical significance.	2
Please rate the accuracy of methods.	3
Please rate the statistical evaluation and quality control.	N/A
Please rate the appropriateness of the figures and tables.	1 - Low/No
Please rate the appropriateness of the references.	4
Please evaluate the writing style and use of language.	3
Please judge the overall scientific quality of the manuscript.	2
Are you willing to review the revision of this manuscript?	Yes

Comments to Authors:

After major revision I can accept the paper in the current form

Reviewer 2: anonymous

Aug 01, 2017

Reviewer Recommendation Term:	Reject
Overall Reviewer Manuscript Rating:	50

Custom Review Questions

Custom Review Questions	Response
Is the subject area appropriate for you?	5 - High/Yes
Does the title clearly reflect the paper's content?	3
Does the abstract clearly reflect the paper's content?	4
Do the keywords clearly reflect the paper's content?	3
Does the introduction present the problem clearly?	4
Are the results/conclusions justified?	4
How comprehensive and up-to-date is the subject matter presented?	1 - Low/No
How adequate is the data presentation?	N/A
Are units and terminology used correctly?	N/A
Is the number of cases adequate?	N/A
Are the experimental methods/clinical studies adequate?	N/A
Is the length appropriate in relation to the content?	4
Does the reader get new insights from the article?	1 - Low/No
Please rate the practical significance.	1 - Low/No
Please rate the accuracy of methods.	N/A
Please rate the statistical evaluation and quality control.	N/A
Please rate the appropriateness of the figures and tables.	1 - Low/No
Please rate the appropriateness of the references.	4
Please evaluate the writing style and use of language.	3
Please judge the overall scientific quality of the manuscript.	1 - Low/No
Are you willing to review the revision of this manuscript?	No: I have written in my first review that there is no need to publish AGAIN a previously published case report with no further information beside an extended follow-up. I am still this opinion. Even with the next and the next revision, there can't be any substantial changes and I don't think another review would help.

Comments to Authors:

I really appreciate the work of the group but there are still the same the images and tables as in the case report in 2015. I still don't see the necessity for publishing this report even if the follow-up is extended and the result is impressive.

Reviewer 2: Klaus-Martin Schulte

Jul 30, 2017

Reviewer Recommendation Term:	Accept
Overall Reviewer Manuscript Rating:	75
Custom Review Questions	Response
Is the subject area appropriate for you?	3
Does the title clearly reflect the paper's content?	4
Does the abstract clearly reflect the paper's content?	5 - High/Yes
Do the keywords clearly reflect the paper's content?	4
Does the introduction present the problem clearly?	4
Are the results/conclusions justified?	5 - High/Yes
How comprehensive and up-to-date is the subject matter presented?	5 - High/Yes
How adequate is the data presentation?	3
Are units and terminology used correctly?	4
Is the number of cases adequate?	3
Are the experimental methods/clinical studies adequate?	N/A
Is the length appropriate in relation to the content?	4
Does the reader get new insights from the article?	4
Please rate the practical significance.	3
Please rate the accuracy of methods.	4
Please rate the statistical evaluation and quality control.	N/A
Please rate the appropriateness of the figures and tables.	4
Please rate the appropriateness of the references.	5 - High/Yes
Please evaluate the writing style and use of language.	4
Please judge the overall scientific quality of the manuscript.	4
Are you willing to review the revision of this manuscript?	Yes

Comments to Authors:

Dear Authors,

thank you for taking the manuscript through the effort of review and making changes.

I believe that the manuscript is well-written and clearly confers important long-term follow-up data in a rare but significant clinical scenario.

Thank you

Editor-in-Chief's Comments to Decision

Aug 02, 2017

Dear Reader,

the manuscript "Neoadjuvant peptide receptor radionuclide therapy and modified multivisceral transplantation for an advanced small intestinal neuroendocrine neoplasm: an updated case report" by Ashley Kieran Clift was originally reviewed by two reviewers who recommended "revise with major modification" and "reject" respectively. According to the journal's review policy we asked for a third reviewer who recommended "accept with minor revision". The revised manuscript was then sent to all three reviewers again, and one reviewer still argued for rejection. The main argument is, that in the revised manuscript "[...] there are still the same images and tables as in the case report in 2015. I still don't see the necessity for publishing this report even if the follow-up is extended and the result is impressive". Because the authors entitled the manuscript "[...] an updated case report", the Editor-in-Chief decided to accept the manuscript for publication. We feel that the transparency of the peer-review process justifies this decision.

With best regards

Joachim Jaehne