

CORRESPONDENCE

Open Access



# Hidden Harlequin syndrome in neonatal and pediatric VA-ECMO

Yael Levy<sup>1,2,3\*</sup>, Julie Starck<sup>1</sup>, Anne-Lise Mary<sup>1</sup>, Yohan Soreze<sup>1</sup>, Sandrine Jean<sup>1</sup>, Bernard Kreitmann<sup>4</sup>, Pierre-Louis Léger<sup>1,2,3</sup> and Jerome Rambaud<sup>1,2,3</sup>

Extracorporeal membrane oxygenation (ECMO) is frequently used in critically ill children and, even if the reported results are good, it remains a challenge encompassing numerous risks. There are two types of ECMO: veno-arterial ECMO (VA-ECMO) which can be used for heart and lung support, while veno-venous (VV-ECMO) is used for lung support only. Indications for VA-ECMO, even if they must be carefully considered, peculiarly if respiratory failure is predominant, remain frequent in infants because there are several specific problems with the use of VV-ECMO. Various types of perforations have been reported with the use of a dual-lumen cannula in VV-ECMO [1]. In a survey of U.K ECMO centers, these complications have been cited as the main reason to favor VA-ECMO over VV-ECMO in infants with respiratory failure only [2]. Jugulo-femoral VV-ECMO should be avoided due to small femoral veins in infants and adequate ECMO flows cannot be achieved [3].

On bifemoral VA-ECMO in the adult population, when left ventricle (LV) recovery coexists with respiratory failure, an antegrade ejection by the LV of relatively deoxygenated blood hinders the retrograde oxygenated blood flow of the VA-ECMO in the aortic arch resulting in cerebral hypoxemia. This has been described as Harlequin syndrome (HS) [4]. In adults, this syndrome is detected by arterial blood gas and pulsatile saturation (SpO<sub>2</sub>) which decrease in the right arm but stay normal in the lower limb. In infants, the neck access for peripheral cannulation is commonly used. The drainage and infusion

cannulas are introduced through the right internal jugular vein and the right carotid artery, respectively. In the literature, the HS has not been previously described in infants to our knowledge. However, in all infants on VA-ECMO, the LV continues to eject more or less “native” blood flow through the aortic valve. This is in opposition to the VA-ECMO blood flow in a point called “mixing-point,” located somewhere between the aortic valve and the brachiocephalic trunk [4]. If the cardiac native flow is insufficient (e.g., severe to moderate LV dysfunction or a very high afterload) and coexists with respiratory failure, the “mixing-point” will be localized into the ascending aorta, the detection of desaturated blood ejection from the LV may be hidden and the coronaries arteries will be the only arterial vessels perfused by this deoxygenated blood flow causing an “invisible” HS (Fig. 1A and B). This “invisible” HS could evolve to a secondary LV dysfunction explained by the desaturated coronary blood flow and the VA-ECMO afterload. Moreover, the reduction in the left ventricular preload by a large interatrial communication or the presence of LV dysfunction may be so important that the aortic valve remains closed, VA-ECMO then provides full circulatory support, no HS exists and the coronaries arteries are well oxygenated (Fig. 1C). In infants, the HS becomes “visible” if the LV function is mildly impaired or subnormal so that the “mixing-point” is close to the brachiocephalic trunk. Thus, the blood flows coming from VA-ECMO and the LV are mixed: SpO<sub>2</sub> decreases in the descending aorta and allows easier detection of the HS (Fig. 1D, E and Additional file 1: Table S1 and Additional file 2: Table S2).

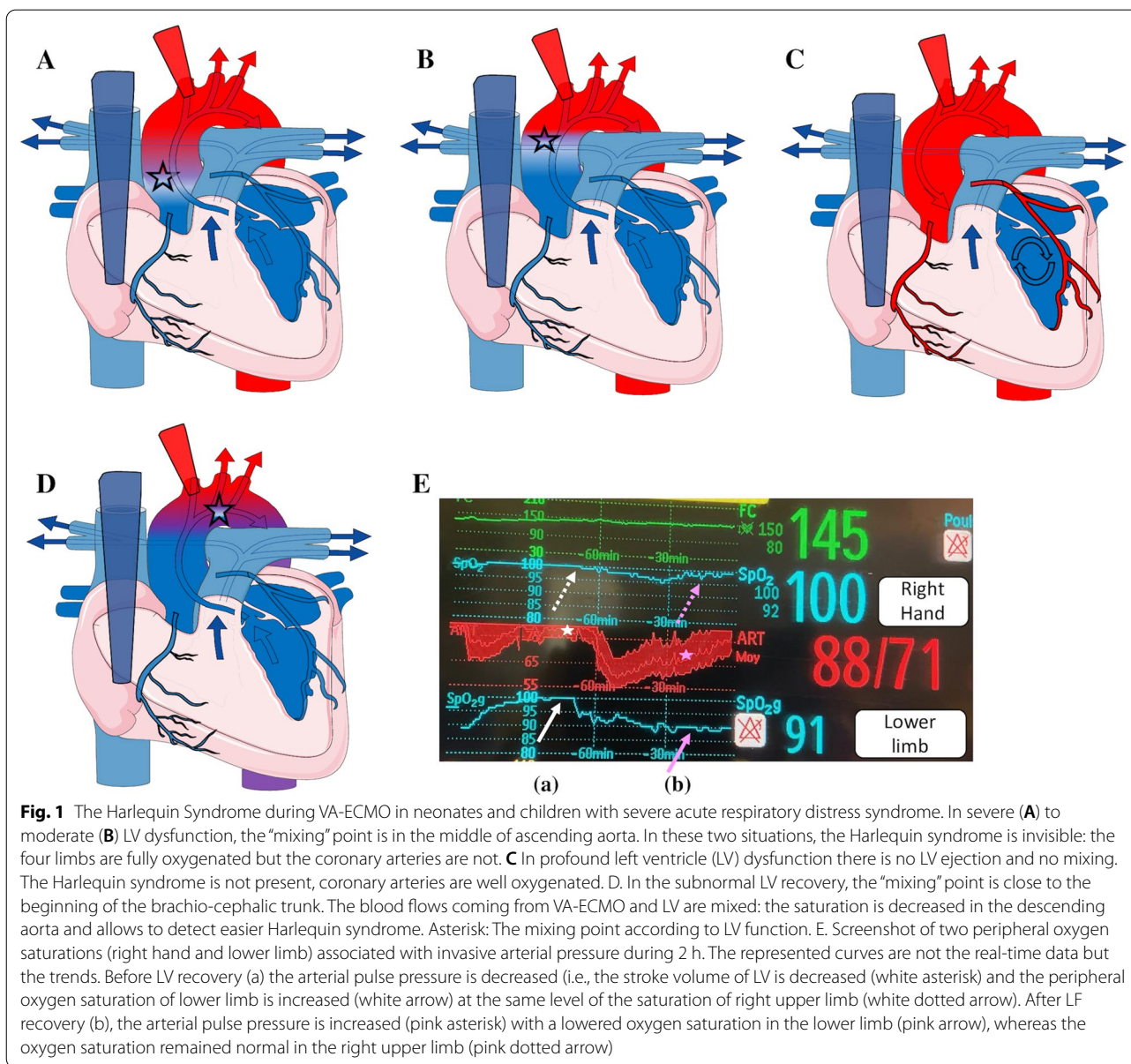
\*Correspondence: yael.levy@aphp.fr

<sup>2</sup> Sorbonne University, Paris, France

Full list of author information is available at the end of the article



© The Author(s) 2022. **Open Access** This article is licensed under a Creative Commons Attribution 4.0 International License, which permits use, sharing, adaptation, distribution and reproduction in any medium or format, as long as you give appropriate credit to the original author(s) and the source, provide a link to the Creative Commons licence, and indicate if changes were made. The images or other third party material in this article are included in the article's Creative Commons licence, unless indicated otherwise in a credit line to the material. If material is not included in the article's Creative Commons licence and your intended use is not permitted by statutory regulation or exceeds the permitted use, you will need to obtain permission directly from the copyright holder. To view a copy of this licence, visit <http://creativecommons.org/licenses/by/4.0/>. The Creative Commons Public Domain Dedication waiver (<http://creativecommons.org/publicdomain/zero/1.0/>) applies to the data made available in this article, unless otherwise stated in a credit line to the data.



The diagnosis of this HS must be suspected (and therefore prevented) with clinical, biological, blood gas and echocardiographic signs (Additional file 1: Table S1). To decrease the risk of severe cardiac failure, the HS should be evoked in all VA-ECMO patients. Unexpected EKG changes or recurrent signs of myocardial injury must be considered as very significant of it.

The best prevention of HS is to carefully consider VA-ECMO indications. Moreover, to prevent and/or treat a HS, several options can be proposed in function of LV function (Additional file 1: Table S1). First, improving the pulmonary function by optimizing respiratory pressures, inspired fraction of oxygen and using prone positioning.

These strategies could improve the oxygen content of the blood flow ejected by LV. According to guidelines, this ventilation must remain protective with a limited driving pressure in order to avoid volo-barotrauma to the lung. Secondly, if the LV function is sufficient, the withdrawal of the VA-ECMO should be discussed with a conversion to VV-ECMO. Thirdly, if the patient is not weanable, the increase in VA-ECMO blood flow could be a possibility: the arterialized blood flow from VA-ECMO could improve the oxygenation in the coronary arteries but this strategy could impair the LV function by increasing LV afterload, risk of acute pulmonary edema and at the end could also impair the coronary perfusion pressure.

Fourthly, hypothermia could be a strategy to decrease the cardiac outflow and the myocardial oxygen consumption. Finally, adding a re-injection cannula in the femoral vein to offer a hybrid veno-arterio-venous ECMO will help to ensure coronary oxygenation by potentially increasing transpulmonary blood flow and oxygen content of pulmonary blood at the cost of recirculation [5].

In conclusion, HS must be suspected and prevented in all VA-ECMO patients in order to avoid a prolonged or a secondary/recurrent cardiac dysfunction.

## Supplementary Information

The online version contains supplementary material available at <https://doi.org/10.1186/s13054-022-04017-w>.

**Additional file 1.** Diagnosis elements during the successive stages in the Harlequin syndrome and elements of discussion for ECMO management.

**Additional file 2.** Blood gas according to sample site.

## Acknowledgements

Not applicable

## Author contributions

YL, JS, PLL, BK and JR participated in the conception and design of the study. YL, PLL, BK and JR drafted the manuscript and all authors contributed substantially to its revision. All authors have read and approved the final manuscript.

## Funding

Not applicable.

## Availability of data and materials

The datasets used and/or analyzed during the current study are available from the corresponding author on reasonable request.

## Declarations

### Ethics approval and consent to participate

Not applicable.

### Consent for publication

Not applicable.

### Competing interests

No competing interests.

## Author details

<sup>1</sup>Pediatric and Neonatal Intensive Care Unit, Armand-Trousseau Hospital, APHP, 26 avenue du Dr Arnold Netter, 75012 Paris, France. <sup>2</sup>Sorbonne University, Paris, France. <sup>3</sup>INSERM, IMRB, Univ Paris Est Créteil, 94010 Créteil, France. <sup>4</sup>Cardiac Surgery, Bordeaux University, Bordeaux, France.

Received: 18 March 2022 Accepted: 5 May 2022

Published online: 20 May 2022

## References

- Johnson SM, Itoga N, Garnett GM, Kilcommons M, Puapong DP, Woo RK. Increased risk of cardiovascular perforation during ECMO with a bicaval, wire-reinforced cannula. *J Pediatr Surg*. 2014;49:46–9.
- Lillie J, Boot L, Speggorin S, Nyman AG. Factors behind decline of venovenous extracorporeal membrane oxygenation to support neonatal respiratory failure. *Pediatr. Crit. Care Med. J. Soc. Crit. Care Med. World Fed. Pediatr. Intensive Crit. Care Soc.* 2020;21:e502-4.
- Brogan TV, Lequier L, Lorusso R, et al: Extracorporeal life support: the ELSO red book. Red Book Fifth Edition. Ann Arbor, MI, Extracorporeal Life Support Organization, 2017.
- Hoepfer MM, Tudorache I, Kühn C, Marsch G, Hartung D, Wiesner O, et al. Extracorporeal membrane oxygenation watershed. *Circulation*. 2014;130:864–5.
- Ius F, Sommer W, Tudorache I, Avsar M, Siemeni T, Salman J, et al. Venovenous-arterial extracorporeal membrane oxygenation for respiratory failure with severe haemodynamic impairment: technique and early outcomes. *Interact Cardiovasc Thorac Surg*. 2015;20:761–7.

## Publisher's Note

Springer Nature remains neutral with regard to jurisdictional claims in published maps and institutional affiliations.

### Ready to submit your research? Choose BMC and benefit from:

- fast, convenient online submission
- thorough peer review by experienced researchers in your field
- rapid publication on acceptance
- support for research data, including large and complex data types
- gold Open Access which fosters wider collaboration and increased citations
- maximum visibility for your research: over 100M website views per year

At BMC, research is always in progress.

Learn more [biomedcentral.com/submissions](https://biomedcentral.com/submissions)

