

# Isolated Complete Rupture of the Biceps Femoris Insertion: A Surgical Repair Technique Manuscript



Benjamin Todd Raines, M.D., M.A., A.T.C., Ryan J. Pomajzl, M.D., M.P.T., A.T.C., Taylor E. Ray, B.S., Jordan A. Bley, M.P.H., and Seth L. Sherman, M.D.

**Abstract:** Isolated rupture of the distal biceps femoris insertion is rare. Current literature offers limited case reports and outcome measures after surgical management. We describe a knotless suture anchor fixation technique for this tear pattern. At surgery, the retracted biceps tendon and insertion site is debrided to healthy tissue, FiberTape suture (Arthrex) is passed in a Kracków fashion through the tendon, and the 2 ends of the suture are brought down to a SwiveLock anchor (Arthrex) at the anatomic insertion. FiberWire sutures (Arthrex) from the anchor are brought over the remnant stump, completing the repair.

Isolated rupture of the distal biceps femoris is rare, and current literature offers little with respect to case reports and outcomes after management. The biceps femoris is the most powerful flexor of the knee joint, and traumatic injuries at the insertion site are often associated with concomitant capsular or ligamentous injury.<sup>1-5</sup> For isolated injuries, current literature describes various treatment options ranging from bracing and immobilization to surgical intervention.<sup>1</sup> The purpose of our article is to present a technique

for operative fixation of isolated biceps femoris tendon tears.

## Anatomy

The biceps femoris muscle runs the length of the posterolateral thigh and comprises 2 heads: 1 short and 1 long. The long head originates from the ischial tuberosity and inserts on the fibular head and Gerdy's tubercle. The short head originates at the distal one-third of the femoral diaphysis, arising from the linea aspera, joining fibers of the long head as it traverses distally.<sup>1,3,6</sup> The biceps femoris is a major flexor of the lower leg, generating between 30% and 85% of strength during knee flexion, and aids in performing external rotation and extension of the hip.<sup>1,3,7-9</sup> Because the biceps femoris is part of the capsular-ligamentous complex—in concert with the popliteal muscle, posterolateral articular capsule, and the lateral collateral ligament (LCL)—it also functions as a dynamic and static knee stabilizer.<sup>1,3,7</sup> This capsular-ligamentous complex, with the inclusion of the popliteofibular ligament, comprises the posterolateral corner (PLC) of the knee, which resists external rotation of the lateral aspect of the tibia on the femur. Injury to the biceps femoris is therefore often associated with injury to the capsular-ligamentous structures that maintain knee stability.<sup>10</sup>

## Injury Etiology and Mechanisms

Etiologies of distal biceps femoris rupture fall into 2 categories, acute and subacute/acute on chronic, and the injury pattern is often suggestive of the etiology. Eccentric contraction of the biceps femoris and hyperextension

From the Department of Orthopaedic Surgery, University of Missouri (B.T.R., T.E.R., S.L.S.), Columbia, Missouri, U.S.A.; SSM Health Medical Group (R.J.P.), Bridgeton, Missouri, U.S.A.; and Columbia Orthopaedic Group (J.A.B.), Columbia, Missouri, U.S.A.

The authors report the following potential conflicts of interest or sources of funding: S.L.S. is a board or committee member for ACL Study Group, American Orthopaedic Society for Sports Medicine, Arthroscopy Association of North America, International Cartilage Restoration & Joint Preservation Society, and the International Society of Arthroscopy, Knee Surgery, and Orthopaedic Sports Medicine, and is on the editorial or governing board of The American Journal of Orthopedics and Arthroscopy; he is a paid consultant, receiving personal fees from Ceterix Orthopaedics, CONMED Linvatec, Moximed, and Vericel; receives personal fees and research support from Arthrex; and receives research support from Zimmer, outside the submitted work. Full ICMJE author disclosure forms are available for this article online, as [supplementary material](#).

Received August 17, 2018; accepted November 29, 2018.

Address correspondence to Seth L. Sherman, M.D., University of Missouri, Columbia, Missouri Orthopaedic Institute, 1100 Virginia Avenue, Columbia, Missouri 65212, U.S.A.. E-mail: [shermanse@health.missouri.edu](mailto:shermanse@health.missouri.edu)

© 2019 Published by Elsevier on behalf of the Arthroscopy Association of North America. This is an open access article under the CC BY-NC-ND license (<http://creativecommons.org/licenses/by-nc-nd/4.0/>).

2212-6287/181029

<https://doi.org/10.1016/j.eats.2018.11.020>

**Table 1.** Pearls and Pitfalls Isolated Rupture of the Distal Biceps Femoris Insertion

Pearls	Pitfalls
It is important to identify and protect the peroneal nerve throughout the procedure.	Be prepared for peroneal nerve scarring and the possible need for neurolysis.
Use the stump of the bicep origin, biceps bursa, and origin of lateral collateral ligament on the fibula to guide anatomic positioning.	Ensure that concomitant posterolateral capsular or ligamentous injuries are not present or require surgical management.
Fixate the bicep in full extension to ensure tension-free repair throughout the range of motion arc.	Use criteria rehabilitation protocol to mitigate risk of early failure and persistent dysfunction.

with concomitant varus or valgus stress are both noted mechanisms associated with acute traumatic tears and avulsion.<sup>1-3,11</sup> Subacute or acute on chronic etiologies are related to a smoldering inflammatory processes, which contributes to degeneration and subsequent failure under stresses below the native failure point.<sup>1</sup> The myotendinous junction is the most common location of failure, although failure may also occur in the midsubstance of the tendon or by avulsion at the fibular head.<sup>7</sup>

## Technique

### Physical Examination

Given that distal biceps femoris rupture rarely occurs in isolation, it is paramount that a thorough ligamentous examination be performed both in the clinical setting as well as under anesthesia before operative intervention. Further, a thorough neurologic examination should also be performed and documented, because up to 44% of multiligamentous knee injuries with associated distal biceps femoris tendon rupture or avulsion may have a concomitant common peroneal nerve injury (Table 1).<sup>10</sup>

The surgeon should assess alignment in bilateral lower extremities as well as gait, quadriceps tone, and straight leg raise and assess extensor lag, effusion, patellar mobility, and knee range of motion (ROM), strength, and velocity. Tenderness to palpation over the fibular head, ecchymosis or other skin changes, ligamentous stability to anterior and posterior drawer, Lachman's, pivot-shift, varus and valgus stress at 0° and 30° of knee flexion, prone dial test at 30° and 90° of knee flexion, and a thorough neurovascular assessment throughout the lower extremity should be performed.

### Imaging

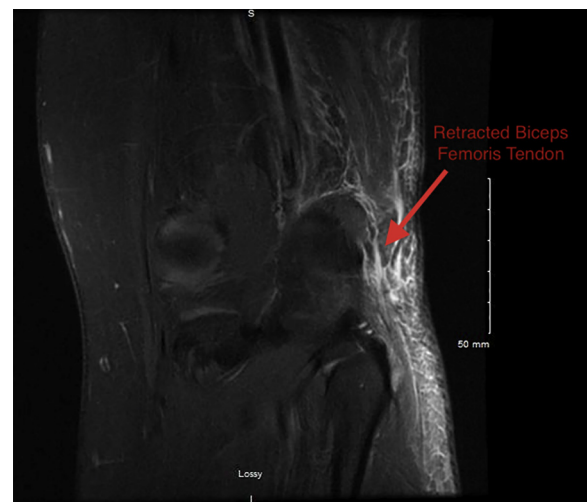
Imaging should be reviewed and correlated to the patient's clinical examination. Review with a musculoskeletal radiologist may be beneficial. Magnetic resonance imaging (MRI) of the injured knee in this case demonstrated no significant intra-articular effusion, but did show mild early chondral changes and rupture of the distal biceps femoris tendon from the fibular head (Fig 1, Video 1). Increased signal can be appreciated within the distal aspect of the LCL (Fig 2) and popliteofibular ligament (Fig 3), despite being asymptomatic without laxity on specific examination of these structures clinically.

### Intraoperative Examination

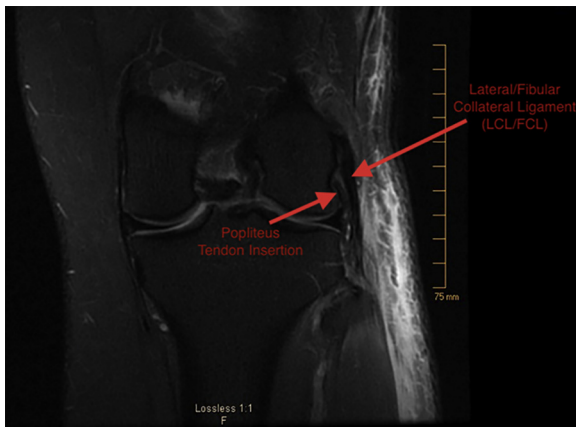
The patient is taken to the operative suite, positioned supine on the operative table, and an examination under anesthesia is performed. The operative limb demonstrates no effusion, good patellar mobility, full range of motion, and stable ligaments throughout (Video 1). Focused examination of the LCL is found to be symmetric to the contralateral side as is the supine dial test at both 30° and 90°.

### Tendon Identification and Debridement

After the examination under anesthesia, the patient is prepped and draped in the usual sterile fashion and a curvilinear incision is made from the level of the fibular head, extending proximally 10 cm. The incision should be carried through the skin and subcutaneous tissue. Fascia overlying the biceps femoris is identified and split longitudinally. The stump of the biceps femoris is identified and may be found completely retracted (Fig 4). The stump is then mobilized with an Allis clamp and inspected. Tendon quality should be assessed and should be under no undue tension when reapproximated to its insertion site on the fibular head. The peroneal nerve should be identified and neurolysis performed to the level of the fibular head. The LCL is identified and assessed and should be found to be completely intact (Fig 5). Residual stump of the biceps



**Fig 1.** Coronal magnetic resonance imaging scan showing rupture of the left leg's distal biceps femoris tendon from the fibular head with retraction.



**Fig 2.** Magnetic resonance imaging scan showing distal aspect of the left leg's lateral collateral ligament.

tendon at the insertion site on the fibular head will be found adjacent and posterior to the LCL. This remnant should be preserved and debrided to healthy tissue.

### Tendon Suturing and Repair

A FiberTape suture (Arthrex, Naples, FL) is passed in a Kracków fashion, yielding control of the torn tendon (Fig 6). To reapproximate the anatomic origin of the biceps, a 2.4-mm guide pin is placed into the biceps remnant, adjacent to the LCL on the fibula. This is visualized by both direct palpation and fluoroscopic guidance. The guidepin is over-drilled with a 4.0-mm reamer to a depth of 20 mm. A tap is then used before bringing the 2 ends of the FiberTape suture down to a 4.75-mm SwiveLock anchor (Arthrex) with the knee held in full extension (Fig 7). The #2 FiberWire sutures (Arthrex) from the SwiveLock anchor are then brought over the remnant stump and secured using a horizontal mattress configuration to complete the distal biceps repair. The leg should be taken through a range of motion from 0° to 90° and the repair should produce no undue tension on the biceps or peroneal nerve. The wound should be thoroughly irrigated and fascia and subcutaneous tissue closed in a standard fashion. Skin is closed with absorbable suture and patient should be placed into a hinge knee brace. Postoperative deep vein thrombosis prophylaxis and a home exercise program should be provided.

### Rehabilitation

Postoperatively, patients are placed in a hinged knee brace, and they are given transcutaneous electrical nerve stimulation and ice/compression device. Patients are instructed to maintain toe-touch weight bearing with crutches and have the brace locked in extension until week 6. Patients will also perform passive ROM exercises during this time. After, they are allowed progressive weight bearing as tolerated with discontinuation of the brace and crutches once adequate quadriceps control is established. The patient should progress toward active

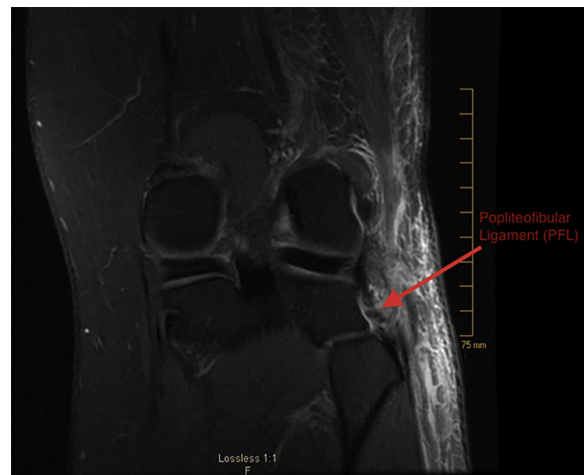
ROM and gentle strengthening at this time. Patients are allowed to resume normal activities as tolerated at 3 months postoperatively.

### Discussion

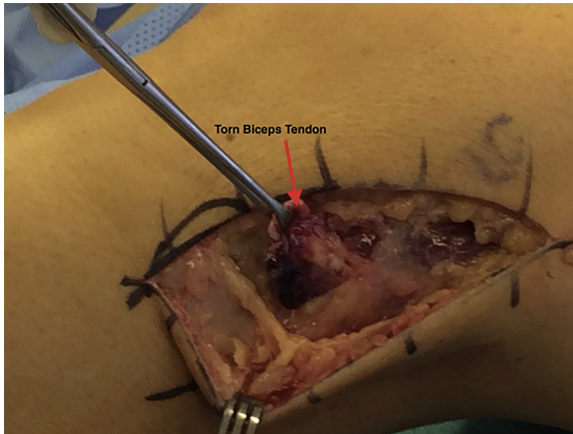
The majority of distal biceps ruptures are associated with a combined hyperextension and external rotation injury mechanism.<sup>12</sup> The LCL and PLC complex usually share loading during combined hyperextension external rotation forces, whereas an isolated, low-energy rotational mechanism may preferentially load the biceps tendon, sparing the LCL and the remainder of the PLC complex.

Treatment options range from nonoperative to surgical intervention with various methods of repair. Nonoperative management is characterized by a period of immobilization of the knee in a flexed position with subsequent therapy to restore normal ROM.<sup>11,13</sup> Some studies recommend a trial of nonoperative management for incomplete tears, whereas other studies suggest that partial thickness injuries initially treated nonoperatively usually require surgical intervention after failure to improve.<sup>1,7,11,13,14</sup> A trial of nonoperative management may therefore be attempted, but clinicians should educate patients that surgical intervention may be recommended if they fail to improve.

Operative intervention is based on the location of failure, chronicity of the tear, and retraction/excursion of the proximal tendon in situ. Selection of the appropriate repair type should be based on the anatomic point of failure as well as excursion of the retracted proximal biceps femoris tendon in situ at the time of surgery. Transosseous attachment with anchors should be considered in the face of avulsion from the fibular head, whereas absorbable suture may be used to perform end-to-end tenorrhaphy when there are adequate remaining tendon stumps. Both of these surgical options are



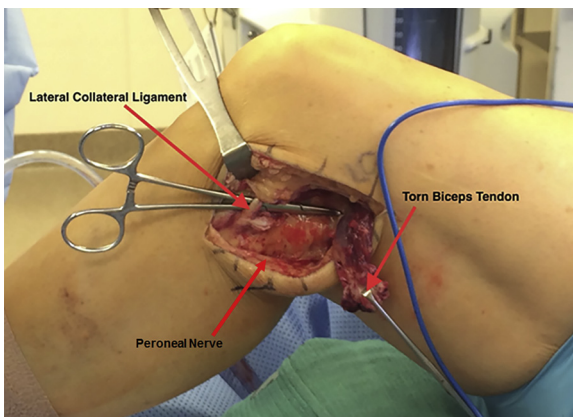
**Fig 3.** Magnetic resonance imaging scan showing the distal aspect of the left leg's popliteofibular ligament.



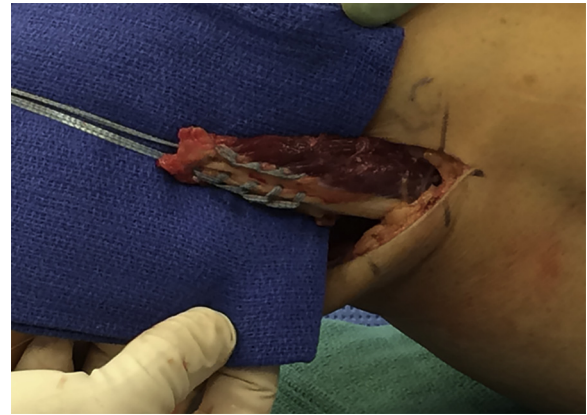
**Fig 4.** A curvilinear incision is made from the level of the left leg's fibular head, extending proximally 10 cm. The incision is carried through the skin and subcutaneous tissue. Fascia overlying the biceps femoris is identified and split longitudinally. The stump of the biceps femoris is identified and found to be completely retracted.

followed by a period of immobilization in flexion and subsequent physical therapy to help restore normal ROM.<sup>1</sup> In the event of chronic biceps rupture, hamstring allograft tendon reconstruction has been described.<sup>15</sup>

The use of suture anchors in general has been reported in distal biceps tendon avulsion repair. To our knowledge, no other case reports describe the use of a knotless repair construct (FiberTape and SwiveLock) for isolated distal biceps femoris repair. Studies have investigated biomechanical strength and failure loads comparing anchor fixation systems using tape suture versus wire suture. De Carli et al.<sup>16</sup> found that tape suture was biomechanically stronger than wire suture, with a significantly higher ultimate failure load. Deranlot et al.<sup>17</sup> found that the tape form of a suture was less abrasive than wire form in creating tendon tears, although this was not statistically significant. To



**Fig 5.** The peroneal nerve is identified and neurolysis is performed to the level of the left leg's fibular head. The lateral collateral ligament is identified and is completely intact.

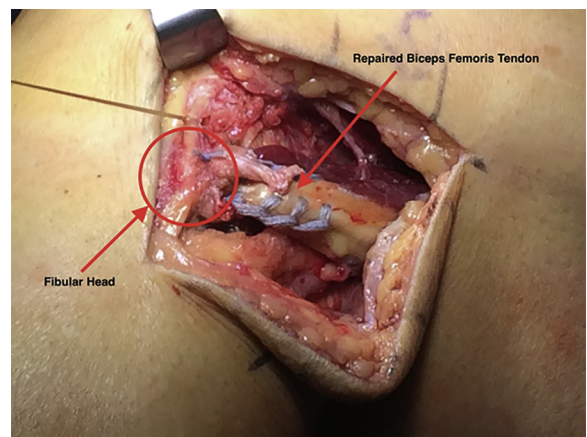


**Fig 6.** FiberTape suture (Arthrex) is passed in a Kraków fashion, yielding control of the left leg's torn tendon.

date, no studies exist comparing the biomechanical strength or clinical outcomes of tenorrhaphy versus tenodesis in distal biceps tendon repair. This is likely because the indications for use differ and the results are not directly comparable (midsubstance tendon rupture versus insertional avulsion, respectively).

Whether nonoperative or surgical management is selected, patients should undergo physical therapy following immobilization to help restore knee range of motion. Return to play decisions for competitive athletes should be based on isokinetic testing in conjunction with a physical examination.

Few reports of outcome measures are present in the literature. In a case report 6 months following an end-to-end tenorrhaphy, Valente et al.<sup>1</sup> noted no pain with full ROM and strength of knee flexion and external rotation comparable to the patient's contralateral side on exam. Also, at the 6-month mark, MRI revealed appropriate anatomic position of both biceps femoris heads, and isokinetic testing demonstrated a deficit of 15.8% at low velocity (90°/s), and only 4.8% at medium velocity



**Fig 7.** The FiberTape suture is brought to a SwiveLock anchor (Arthrex) and placed at the anatomic insertion of the left leg's biceps femoris, adjacent to the lateral collateral ligament.

(180°/s). Valente et al. reported a full return to professional level football at 1 year following end-to-end suture tenorrhaphy. Aldebeyan et al.<sup>18</sup> report full return to play at 1 year postoperatively for a National Football League athlete who underwent suture anchor repair with concomitant LCL and semimembranosus repair; however, the case report offers little in terms of objective data or subjective report. Mascarenhas et al.<sup>15</sup> reported a good clinic outcome with return to high-level physical activity following distal biceps tendon reconstruction for a chronic biceps rupture using hamstring allograft.

### Risks and Limitations

A major risk during surgery involves the potential for iatrogenic damage to the common peroneal nerve. The nerve should be identified and protected throughout the case to avoid inadvertent injury. Additionally, surgical dissection combined with careful physical examination is critical to confirm the integrity of the posterolateral corner structures. In severe cases of musculotendinous or muscular injury to the biceps femoris, the tissue quality may be poor and/or the tendon retracted and difficult to repair without the use of autograft/allograft augmentation.

Isolated rupture of the distal biceps femoris is rare. Treatment options differ based on severity and location of rupture, and current case reports offer little insight with regard to comparative outcomes. In this report, we describe surgical treatment with knotless repair that demonstrates successful outcome at 6 months, with significantly improved functional outcome scores maintained through 2-year follow-up.

### References

1. Valente M, Mancuso F, Alecci V. Isolated rupture of biceps femoris tendon. *Musculoskelet Surg* 2013;97:263-266.
2. Werlich T. [Isolated rupture of the biceps tendon of the knee joint]. *Unfallchirurg* 2001;104:187-190 [in German].
3. Kusma M, Seil R, Kohn D. Isolated avulsion of the biceps femoris insertion-injury patterns and treatment options: A case report and literature review. *Arch Orthop Trauma Surg* 2007;127:777-780.
4. McGoldrick F, Colville J. Spontaneous rupture of the biceps femoris. *Arch Orthop Trauma Surg* 1990;109:234.
5. Sebastianelli WJ, Hanks GA, Kalenak A. Isolated avulsion of the biceps femoris insertion. *Clin Orthop Relat Res* 1990;259:200-203.
6. Marshall JL, Girgis FG, Zelko RR. The biceps femoris tendon and its functional significance. *J Bone Joint Surg Am* 1972;54:1444-1450.
7. Lempainen L, Sarimo J, Mattila K, Heikkilä J, Orava S, Puudu G. Distal tears of the hamstring muscles: Review of the literature and our results of surgical treatment. *Br J Sports Med* 2007;41:80-83.
8. David A, Buchholz J, Muhr G. Tear of the biceps femoris tendon. *Arch Orthop Trauma Surg* 1994;113:351-352.
9. Brunet ME, Kester MA, Cook SD. Biomechanical evaluation of superficial transfer of the biceps femoris tendon. *Am J Sports Med* 1987;15:103-110.
10. Oshima T, Nakase J, Numata H, Takata Y, Tsuchiya H. Common peroneal nerve palsy with multiple-ligament knee injury and distal avulsion of the biceps femoris tendon. *Case Rep Orthop* 2015;2015:306260.
11. Fortems Y, Victor J, Dauwe D, Fabry G. Isolated complete rupture of biceps femoris tendon. *Injury* 1995;26:275-276.
12. Riemer C, Lueder A, Sattler MF, Zeichen J. [Clinically symptom-poor isolated rupture of the biceps tendon of the knee close to the attachment. Can an operative approach always be recommended?]. *Unfallchirurg* 2014;117:75-79 [in German].
13. Jensen IH, Kramhoft M. Distal rupture of the biceps femoris muscle. *Scand J Med Sci Sports* 1994;4:259-260.
14. Tsai TY, Yang YS, Yeh YK, Chuang FK, Liu CW, Pan RY. A new operative treatment for chronic biceps femoris tendon avulsion. *Knee Surg Sports Traumatol Arthrosc* 2010;18:787-789.
15. Mascarenhas R, Mcrae S, MacDonald PB. Semitendinosus allograft reconstruction of chronic biceps femoris rupture at the knee. *J Knee Surg* 2009;22:381-384.
16. De Carli A, Lanzetti RM, Monaco E, Labianca L, Mossa L, Ferretti A. The failure mode of two reabsorbable fixation systems: Swivelock with Fibertape versus Bio-Corkscrew with Fiberwire in bovine rotator cuff. *J Orthop Sci* 2012;17:789-795.
17. Deranlot J, Maurel N, Diop A, et al. Abrasive properties of braided polyblend sutures in cuff tendon repair: An in vitro biomechanical study exploring regular and tape sutures. *Arthroscopy* 2014;30:1569-1573.
18. Aldebeyan S, Boily M, Martineau PA. Complete tear of the distal hamstring tendons in a professional football player: A case report and review of the literature. *Skeletal Radiol* 2016;45:427-430.