





# Vocal Folds Leukoplakia: The Efficacy of Vitamin A in the Initial Treatment

Dayane Silvestre Botini<sup>1</sup> Sergio Augusto Rodrigues<sup>2</sup>  Gustavo Leão Castilho<sup>1</sup> Gustavo Mercuri<sup>1</sup>  
Regina Helena Garcia Martins<sup>1</sup> 

<sup>1</sup>Ophthalmology, Otorhinolaryngology, Head and Neck Surgery Department, Universidade Estadual Paulista(Unesp), Botucatu, SP, Brazil

<sup>2</sup>Biostatistical Department, Universidade Estadual Paulista (Unesp), Botucatu, SP, Brazil

Address for correspondence Regina H. G. Martins, MD, PhD, Ophthalmology, Otorhinolaryngology and Head Neck Surgery Department, Botucatu Medical School – Universidade Estadual Paulista Júlio de Mesquita Filho, Distrito de Rubião Junior s/n, 18618-970; Botucatu, SP, Brazil (e-mail: regina.g.martins@unesp.br).

Int Arch Otorhinolaryngol 2023;27(1):e97–e103.

## Abstract

**Introduction** Laryngeal leukoplakia corresponds to a white lesion in the mucosa developed by the deposit of keratin in the epithelium, potentiated by chronic smoking. It is considered a preneoplastic lesion. Surgery is the most adopted treatment; however, non-surgical treatment is advocated by some authors.

**Objective** To evaluate the effectiveness of vitamin A in the management of vocal fold leukoplakia.

**Methods** Patients with videolaryngoscopy diagnosis of vocal fold leukoplakia were selected. The endoscopic images were photographed and with the aid of the ImageJ software (National Institutes of Health, Bethesda, MD, USA), the proportion of the size of the leukoplakia was calculated. Eligible patients were prescribed 50,000U of vitamin A, twice daily for 2 months, at which point videolaryngostroboscopy was repeated for comparative analysis between pre and posttreatment. The efficacy of the treatment was classified as: outcome I – complete improvement of the lesion, outcome II – partial improvement, and outcome III – no difference or increased lesion size.

**Results** Fifteen patients (eight women, seven men) were included, six of whom had bilateral lesions. Smoking was reported in 86.8% of patients. Complete improvement of the lesion was found in 7 cases (33.4%, outcome I), partial improvement in 6 (28.6%, outcome II), and worsening of the injury in 8 (38.1%, outcome III). Of the latter, 6 underwent microsurgery; histopathology indicated absence of dysplasia in 3, and mild dysplasia in 3.

**Conclusions** In this study, the treatment with vitamin A at a dose of 100,000 IU daily for 2 months was effective in reducing the laryngeal leukoplakia size in 62% of cases.

## Keywords

- ▶ leukoplakia
- ▶ vocal folds
- ▶ larynx
- ▶ vitamin A
- ▶ treatment

received  
May 26, 2021  
accepted after revision  
December 14, 2021

DOI <https://doi.org/10.1055/s-0042-1742767>.  
ISSN 1809-9777.

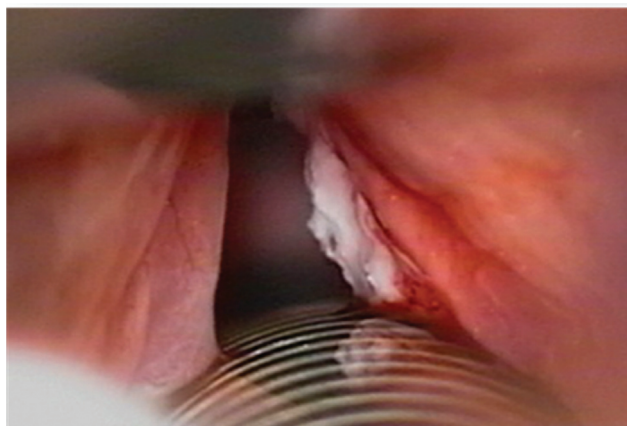
© 2023. Fundação Otorrinolaringologia. All rights reserved.  
This is an open access article published by Thieme under the terms of the Creative Commons Attribution-NonDerivative-NonCommercial-License, permitting copying and reproduction so long as the original work is given appropriate credit. Contents may not be used for commercial purposes, or adapted, remixed, transformed or built upon. (<https://creativecommons.org/licenses/by-nc-nd/4.0/>)  
Thieme Revinter Publicações Ltda., Rua do Matoso 170, Rio de Janeiro, RJ, CEP 20270-135, Brazil

## Introduction

Leukoplakia corresponds to a white lesion of the mucosa that begins with abnormal epithelial deposition of keratin.<sup>1</sup> In the larynx, there is a predilection for the vocal folds (→Fig. 1), which is considered, by some authors, a preneoplastic lesion.<sup>1,2</sup> For others, however, the rate of malignant transformation is lower than 20%, making it difficult to correlate it to a high potential for malignancy.<sup>3</sup> In a review of the histological slides of 136 patients (208 biopsies) with laryngeal leukoplakia, Isemberg et al.<sup>4</sup> showed absence of dysplasia in 110 slides (53%), moderate dysplasia in 38 (18%), and severe dysplasia in 31 (15%). After 30 months of follow-up, malignant transformation was found in 3.7% of patients without dysplasia, in 10% of patients with moderate dysplasia, and in 18% of patients with severe dysplasia. Thus, they highlighted the importance of maintaining constant surveillance in patients with vocal fold leukoplakia, even in those whose histological reports did not show dysplasia.

A smoking habit and alcoholism are the main independent risk factors, with a synergistic effect, in the etiopathogenesis of malignant and premalignant laryngeal lesions.<sup>5,6</sup> Vaezi et al.<sup>7</sup> stated that there is an increase of 23% in the risk of cancer for every 5 years of active smoking, associated with an increase of 17% when alcoholism is also present. For other authors, these rates are higher, around 67% in smokers.<sup>8</sup>

Leukoplakic lesions of the larynx can be found in one or both vocal folds. Other injuries associated with smoking may also be present, such as Reinke's edema and polyps.<sup>9</sup> In leukoplakia, complementation of the exam with laryngoscopy is mandatory, since it shows the vibratory conditions of the mucous wave, pointing toward the best treatment. Persistence of the intact mucous wave indicates superficial lesion, leading to the possibility of conservative clinical treatment, to avoid permanent dysphonia, especially in voice professionals, as well as hospital procedures under general anesthesia, in at-risk patients. On the other hand, the decrease or absence of a mucous wave indicates progression of the lesion to the deeper layers of the epithelium and is potentially related to malignancy.<sup>10,11</sup> In these cases, surgery



**Fig. 1** Leukoplakia in right vocal fold.

is the preferred treatment, to define early treatment based on the diagnosis.

Vitamin A has been used in the clinical treatment of laryngeal and oral leukoplakia. Its use is justified by its numerous and important actions in the body. Vitamin A is a micronutrient that belongs to the group of fat-soluble vitamins, acting on vision (enabling the adaptation of night vision), in the immunological system (by stimulating phagocytosis, activating cell-mediated cytotoxicity, increasing the expression of interleukin-2 receptors, stimulating the selective release of interleukin-1 by monocytes, and increasing the percentage of auxiliary T-lymphocytes and “natural killer” –NK cell markers) and being anticarcinogenic (by suppressing the malignant phenotype and inhibiting cell proliferation).<sup>12,13</sup>

Vitamin A also plays an important role in tissue differentiation, growth, and maintenance, especially in the upper airways, where retinoic acid receptors are identified in the nuclei of epithelial cells. Due to its inhibitory action over keratinization, it has been used in oral actinic keratitis and leukoplakia. In vitamin A deficiency, squamous epithelial metaplasia can be observed, as demonstrated by Tateya et al.<sup>14</sup> in an experimental study in rats with vitamin A deficiency, whose immunohistochemical study of the vocal folds revealed overexpression of keratin 10 and transglutaminase (TGase 1). In the respiratory epithelium, vitamin A induces and controls mucus differentiation.<sup>11</sup>

Several studies have tested the effectiveness of the use of retinoid, both topical and oral, in leukoplakic lesions of the mouth, with satisfactory results.<sup>15,16</sup> However, recurrence of lesions is often reported after drug withdrawal. Nevertheless, in the proposal for the treatment of leukoplakia with retinoic derivatives, we must consider the possible adverse effects of the medication, such as conjunctivitis, hypertriglyceridemia, and a possible teratogenic effect, since the dose and time of treatment vary widely between different studies.<sup>17,18</sup>

There are few studies about the treatment for laryngeal leukoplakia with vitamin A. Most of them were performed in previous decades, and the topic was incomprehensibly abandoned over the years, even with the proof of its benefits by several authors, such as laryngeal papillomatosis recurrence<sup>19,20</sup> and well-differentiated squamous cell carcinoma.<sup>20–22</sup> An interesting study performed by Issing in 1997<sup>23</sup> evaluated the efficacy and toxicity of vitamin A in the treatment of laryngeal leukoplakia. The patients were treated with 300,000 IU/day of retinyl palmitate in the 1<sup>st</sup> week, reaching up 1,500,000 IU/day in the 5<sup>th</sup> week in patients with no response to treatment. Complete lesion remission was observed in 15 of 20 patients (75% of cases), partial remission was recorded in 5 patients, while 3 of the patients relapsed. The authors found no toxicity even at high doses. With these results, the authors emphasize that retinyl palmitate has substantial activity in laryngeal leukoplakias. In contrast, using daily vitamin A doses of 90,000 IU, Okur et al.<sup>24</sup> did not succeed in eliminating laryngeal lesions.

Therefore, it is observed that the studies are scarce and present contradictory results. So, the objective of the present

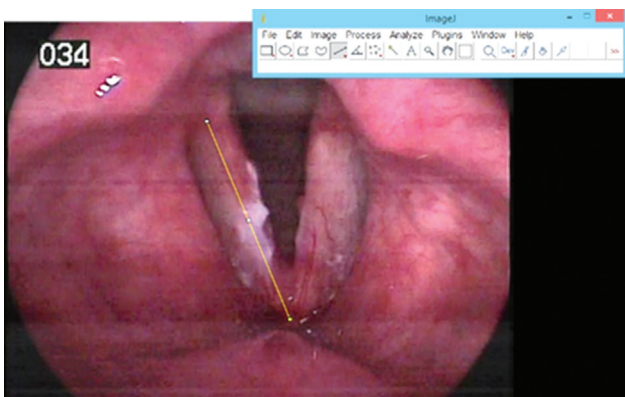
study was to evaluate the effectiveness of the initial clinical treatment with vitamin A on leukoplakia lesions of the vocal folds with a dosage of 100,000 units/day for 2 months.

## Material and Methods

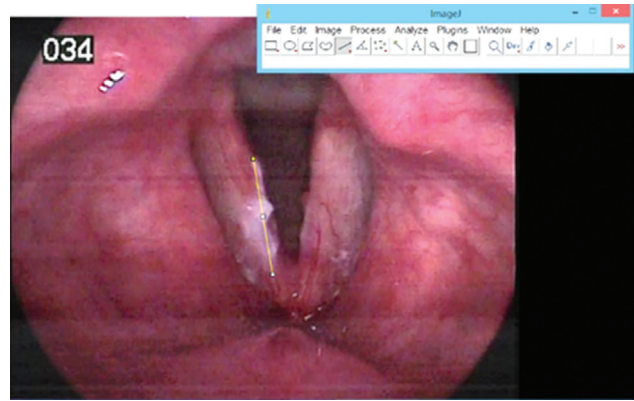
Longitudinal cohort study with patients treated at the voice disorders outpatient clinic of University Sao Paulo State University (Unesp), Botucatu Medical School, between 2018 and 2020, with a video-laryngoscopy diagnosis of vocal fold leukoplakia, who were selected after signing a free and informed consent form. All patients completed a questionnaire containing information related to vocal symptoms, systemic diseases, and demography. They subsequently underwent a videolaryngoscopy using a rigid telescope with 8 mm in diameter and 70° (Asap, Germany) or a 3.5-mm flexible nasofibroscope (Olympus, Japan), coupled to an XE-50, Eco V 50W X-TFT/USB image capture system (ILO Electronic GmbH, Carl Zeiss, Germany), Asap microcamera (Germany), lapel microphone (Leson, Brazil) and stroboscopic light source (Endo - Stroboscope, Atmos, MedizinTechnik GmbH & Co KG, Germany). The mucous wave was described as present, decreased, or absent, and symmetric or asymmetric. Patients with decreased or absent mucous wave were excluded from the study and were submitted to direct laryngoscopy for surgery.

The exams were recorded, and the vocal folds were photographed during inspiration, in complete abduction. From these images, with the aid of the ImageJ software (National Institutes of Health, Bethesda, MD, USA), the proportion of the size of the leukoplakia was calculated. Initially, the size of the affected vocal fold was calculated, tracing a longitudinal line from its insertion in the anterior glottic commissure to the corresponding vocal apophysis (→ Fig. 2). A second longitudinal line was drawn at the limits of the leukoplakia plate (→ Fig. 3), considering its longest axis. Once the size of the vocal fold and the size of the leukoplakia had been determined, the program provided us with the percentage of the lesion size (%), in the respective vocal fold.

Patients eligible for the study and diagnosed with vocal fold leukoplakia were treated with 50,000 IU of vitamin A, twice daily, for 2 months. The patients were informed about the possible adverse effects of the vitamin A and were



**Fig. 2** ImageJ software. Longitudinal measurement of the size of the right vocal fold (yellow line).



**Fig. 3** ImageJ software. Longitudinal measurement of the size of the leukoplakia in right vocal fold (yellow line).

instructed to interrupt the treatment and return to the service if any presented. Other measures included education on the need to quit smoking and drinking, avoid vocal abuse, and take proton pump inhibitors (20 mg Omeprazole twice daily for 2 months). After 2 months, all of them were submitted to a new anamnesis to assess symptoms progression, and to do a comparative videolaryngostroboscopy.

For the interpretation of treatment effectiveness, the outcomes were divided into three groups: I - complete improvement (absence of injury after treatment); II - partial improvement (decrease in the extent of the lesion); III - no difference or increased lesion size.

The endoscopic laryngeal diagnoses were analyzed blindly to treatment by two laryngology-experienced professionals.

Patients who did not have any regression in the size of the leukoplakia lesion, had increase in the lesion or who progressed to change in the mucosal wave were referred to microsurgery by direct laryngoscopy.

The exclusion criteria were patients with laryngeal moniliasis, patients with strong suspicion or confirmation of laryngeal neoplasia, and patients with hypersensitivity to retinoids and with suspected pregnancy.

The research was approved by the Human Research Ethics Committee of the Sao Paulo State University (Unesp), Botucatu Medical School under protocol number 4.572.784.

## Statistical Methodology

The paired Student-*t* test was used to verify whether there was significant difference between the proportions of the area affected by the lesion before and after treatment with vitamin A, considering a significance level of 0.05%.

## Results

During the study period (2018–2020), 45 patients with laryngeal leukoplakia were diagnosed, 24 of whom were excluded for not meeting the inclusion criteria. The study started with 21 patients with laryngeal leukoplakia who underwent treatment with vitamin A. Of these, 6 did not return probably due to the beginning of the COVID-19

**Table 1** Size of vocal folds (in pixels) and of leukoplakia, percentage of the fold involved (%) before and after treatment, and final result

Vocal Fold	Pre-Vitamin A treatment			Post-Vitamin A treatment			Outcomes
	Size of vocal fold	Size of leukoplakia	Lesion percentage %	Size of vocal fold	Size of leukoplakia	Lesion percentage %	
1	238	90	37.82	465	351	75.48	III
2	293	137	46.76	215	125	58.14	III
3	316	35	11.08	257	56	21.79	III
4	334	71	21.26	252	72	28.57	III
5	132	116	87.88	275	251	91.27	III
6	263	47	17.87	263	53	20.15	III
7	332	146	43.98	246	111	45.12	III
8	251	149	59.36	207	125	60.39	III
9	132	33	25.00	187	45	24.06	II
10	227	135	59.47	317	147	46.37	II
11	277	83	29.96	273	44	16.12	II
12	226	117	51.77	287	96	33.45	II
13	297	122	41.98	315	68	21.59	II
14	402	194	48.26	384	102	26.56	II
15	301	62	20.60	314	0	0	I
16	147	28	19.05	129	0	0	I
17	233	40	17.17	337	0	0	I
18	234	78	33.33	320	0	0	I
19	264	102	38.64	299	0	0	I
20	265	117	44.15	302	0	0	I
21	312	182	58.33	293	0	0	I

pandemic, thus bringing the sample size to 15 patients (8 women and 7 men). Of these, 6 patients had bilateral lesions, totaling 21 vocal folds. During the use of the medication, none of them reported adverse effects related to the dose of vitamin A administered.

Smoking was reported by 11 patients (73.4%), and smoking associated with alcoholism was reported by 2 patients (13.4%). Analyzing the patients who abandoned addiction, we found four in outcome I, two in outcome II, and two in outcome III.

► **Table 1** depicts the percentage of the vocal folds affected by leukoplakia (%) before and after treatment, as well as the

outcomes. Complete improvement of the lesion was seen in 7 cases (33.4%, outcome I), partial improvement in 6 cases (28.6%, outcome II), and worsening of the lesion in 8 cases (38.1%, outcome III).

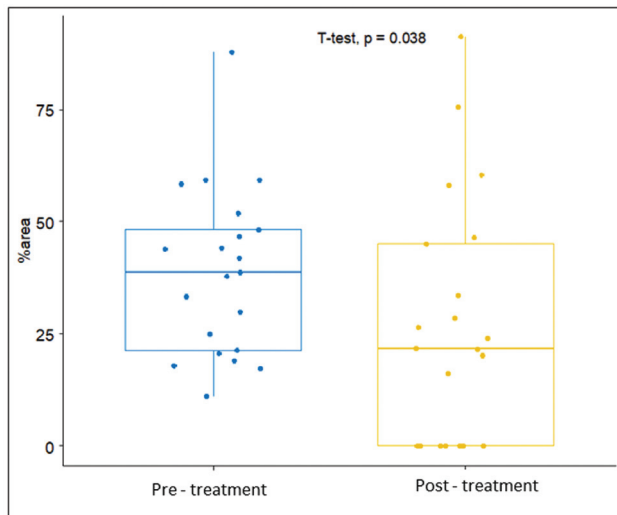
Patients who did not improve after conservative treatment using vitamin A underwent direct laryngoscopy for resection of the leukoplakia. Among the eight subjects in this situation, six had microsurgery in the period. The pathology indicated: absence of dysplasia (n-3) and mild dysplasia (n-3).

► **Table 2** shows the mean (standard deviation [SD]) of the extent of the leukoplakia pre and posttreatment with vitamin A, confirming the effectiveness of vitamin A in the

**Table 2** Mean, and median size of leukoplakia lesion pre and postvitamin A treatment

Statistics	Percentage of lesion size (%)			p-value
	Pre-vit A	Post-vit A	Difference between pre- and post-vit A	
Mean (SD)	38.75 (18.75)	27.10 (27.06)	-11.65 (21.80)	0.038*
Median (min-max)	38.64 [11.08; 87.88]	21.79 [0.00; 91.27]	-13.84 [-58.33; 37.66]	

\*paired Student-t test,  $p < 0.05$



**Fig. 4** Box plot concerning lesion size pre- and post-treatment with vitamin A.

non-surgical treatment of leukoplakia, data also illustrated in ►Fig. 4 of the box plot.

## Discussion

Most of the patients included in this study were smokers (87%), which is indicative of the relevance of this agent in the origin of leukoplakia, identified in both genders. The effects of smoking on the laryngeal mucosa have been extensively studied by several authors. Its association with alcohol, an important vasodilator, facilitates the penetration of the harmful components of cigarettes, increasing the susceptibility of the airway epithelium to its thermal effect.<sup>5,6,25,26</sup> In our study, eight smoking patients abandoned their habit after starting treatment. When reviewing the results of these patients, we noted that four of them progressed to the outcome I, with complete cure, two fell into outcome II, with partial improvement, and two others progressed to outcome III, with no improvement. The small number of patients did not allow us to evaluate the effects of abandoning addiction on the reduction of the size of the leukoplakia. The short follow-up time of 2 months was also another limiting factor, considering the long period of exposure to tobacco.

The treatment of leukoplakia is discussed by many authors, with no consensus. Among the proposed treatments, there is surgical excision by various techniques (scalpel, cryotherapy, photodynamic therapy, laser or vaporization), drug treatment, topical or systemic (antiinflammatory drugs, antifungal, retinoic, carotenoid, folic acid), abandonment of aggravating addictions (cigarette and alcohol), and monitoring.<sup>4,8,16,18,27</sup> In our study, we evaluated the non-surgical treatment of vocal fold leukoplakia with vitamin A, and we noted that 62% of the lesions disappeared completely (34%) or showed partial improvement (28%) after treatment, with statistical difference in the pre and post-treatment moments in favor of using the medication (►Table 1). However, in eight vocal folds, there was an increase in the size of the leukoplakia (38%).

The literature is scarce regarding research using vitamin A in laryngeal leukoplakia, with it being more studied for oral lesions. Stich et al.<sup>18</sup> described the effects of vitamin A in 21 patients with oral leukoplakia who received 200,000 IU of vitamin A, twice a week for 6 months, while another group received placebo. In the group treated with vitamin A, they found that 57.1% had complete remission of the lesion and none developed new leukoplakia, against 3% and 21%, respectively, in the placebo group (33 patients).

Initial studies with vitamin A in laryngeal lesions date from previous decades. Issing et al.<sup>23</sup> evaluated in 20 patients with laryngeal leukoplakia, the response to the use of 300,000 IU retinol palmitate in the 1<sup>st</sup> week, followed by 1,500,000 IU until the 5<sup>th</sup> week in patients refractory to treatment. The 18-month follow-up of patients who had total or partial response to the proposed therapy, with a maintenance dose of 150,000 IU, showed that 75% of the patients had complete remission and 25% partial remission. The authors highlight the beneficial effects of retinol palmitate in the treatment of leukoplakia, especially in patients in whom surgery is not possible or unwanted.

The recommended daily dose of vitamin A in adults, in cases of hypovitaminosis, varies between 100,000 IU and 300,000 IU, with no exact determination of the duration of use. In the treatment of leukoplakia, the authors also use many different doses, such as 90,000 to 300,000 IU per day or week, and most studies do not clarify the duration of use. We used 100,000 IU/day during 2 months, and we have not identified any cases of overdose or intoxication in our patients. Therefore, this dosage was considered safe and effective in the medical treatment of laryngeal leukoplakia. Using vitamin A in doses similar to those used in our study, however for benign lesions (nodules and polyps), Okur et al.<sup>24</sup> did not succeed in eliminating laryngeal lesions with 90,000 IU per day for 2 months.

In addition to doubts related to the dosage of vitamin A, most studies refer to oral or non-laryngeal lesions. Therefore, taking into account the similarities of such lesions, conservative treatments ended up being extrapolated also for glottic lesions. In a systematic review that included 14 studies and 909 patients, Lodi et al.<sup>16</sup> analyzed interventions in oral leukoplakia in the prevention of cancer. In this study, several types of treatments were included, such as surgical (laser and cryotherapy) and medications, including  $\beta$ -carotene, herbal extracts, non-steroidal antiinflammatory drugs, and vitamin A. Among the three works by authors who used vitamin A systemically, two demonstrated benefits, and the third did not when compared with placebo.

In oral leukoplakia, several authors describe a high recurrence of lesions in patients who have stopped using vitamin A. Hence the importance of a longer follow-up. In our study, this information cannot be obtained because the research was limited to the 2-month treatment period. Many of the patients return periodically for a longer period to the present day; however, we do not have data for all of them.

In our study, the presence of the mucosal wave, identified by laryngostroboscopy, was mandatory in recruiting patients eligible for non-surgical treatment. We consider

this evaluation extremely important as an indication of the normal conditions of the epithelium and of the superficial layers of the lamina propria. The presence of a superficial lesion on the mucosa, affecting only the epithelium, enables the persistence of the mucus-regulating wave. However, in deeper lesions, there is a decrease in its amplitude or even absence, in more severe cases, and that is a red flag for the presence of carcinoma. El-Demerdash et al.<sup>10</sup> evaluated 46 patients, with a total of 60 laryngeal leukoplakias. Patients underwent preoperative videostroboscopy, analyzing the amplitude of the mucosal wave vibration, symmetry, and wave propagation over the lesion. The sensitivity and specificity in predicting invasive disease, based on the absence or reduction of the mucosal wave, was 96.8 and 92.8%, respectively, with an accuracy of 95%. With such results, although the presence of changes in the mucosal wave is not conclusive for the diagnosis of a malignant lesion, this change must be considered important in the therapeutic decision.

In 2017, Rzepakowska et al.<sup>11</sup> evaluated 175 patients with laryngeal lesions considered to be premalignant, malignant, or with irregularities in the vocal folds. All were submitted to preoperative videolaryngostroboscopy. At the end of the study, the authors identified high sensitivity values for the detection of malignant and premalignant lesions based on stroboscopic features, which was considered a good screening method to guide the initial management of laryngeal lesions.

We highlight here some limitations of this study that deserve further discussion. We used proton pump inhibitor for all patients with laryngeal leukoplakia seeking to eliminate acid laryngitis, another important causal factor of inflammatory processes in the laryngeal mucosa. We understand that isolated gastroesophageal reflux can cause laryngeal lesions and that leukoplakia is one of them.<sup>28</sup> According to some authors, patients with gastroesophageal reflux and leukoplakia in the vocal folds may present improvement of the lesions with the treatment of proton inhibitor.<sup>29</sup> We understand that in the methodology of our research, it would have been interesting to have yet another study group, composed of patients who took only vitamin A and no pump inhibitor, to make sure of its benefits when used exclusively; however, the small number of patients made it impossible to add this group.

Other limitations of this study include the time of treatment and follow-up to detect possible relapses. The doses used could also be compared with smaller doses to determine the minimum effective dose.

From the above, it is clear that the treatment with vitamin A in leukoplakia, although it has been studied for decades, is a subject with many fronts that are still little investigated and that deserve additional studies related to the type of injury, doses, duration of use, and time of follow-up.

## Conclusion

In the present study, the treatment with vitamin A at a dose of 100,000 IU daily for 2 months was effective in reducing the laryngeal leukoplakia size in 62% of cases.

## Conflict of Interests

The authors have no conflict of interests to declare.

## References

- Fang TJ, Lin WN, Lee LY, et al. Classification of vocal fold leukoplakia by clinical scoring. *Head Neck* 2016;38(Suppl 1):E1998–E2003. Doi: 10.1002/hed.24368
- Gale N, Gnepp DR, Poljak M, et al. Laryngeal Squamous Intraepithelial Lesions: An Updated Review on Etiology, Classification, Molecular Changes, and Treatment. *Adv Anat Pathol* 2016;23(02): 84–91. Doi: 10.1097/PAP.000000000000106
- Ferlito A, Devaney KO, Woolgar JA, et al. Squamous epithelial changes of the larynx: diagnosis and therapy. *Head Neck* 2012;34 (12):1810–1816. Doi: 10.1002/hed.21862
- Isenberg JS, Crozier DL, Dailey SH. Institutional and comprehensive review of laryngeal leukoplakia. *Ann Otol Rhinol Laryngol* 2008;117(01):74–79. Doi: 10.1177/000348940811700114
- Haldorsen T, Martinsen JI, Kjørheim K, Grimsrud TK. Adjustment for tobacco smoking and alcohol consumption by simultaneous analysis of several types of cancer. *Cancer Causes Control* 2017;28 (02):155–165. Doi: 10.1007/s10552-016-0847-x
- Mello FW, Melo G, Pasetto JJ, Silva CAB, Warnakulasuriya S, Rivero ERC. The synergistic effect of tobacco and alcohol consumption on oral squamous cell carcinoma: a systematic review and meta-analysis. *Clin Oral Investig* 2019;23(07):2849–2859. Doi: 10.1007/s00784-019-02958-1
- Vaezi MF, Qadeer MA, Lopez R, Colabianchi N. Laryngeal cancer and gastroesophageal reflux disease: a case-control study. *Am J Med* 2006;119(09):768–776. Doi: 10.1016/j.amjmed.2006.01.019
- Park JC, Altman KW, Prasad VMN, Broadhurst M, Akst LM. Laryngeal leukoplakia: state of the art review. *Otolaryngol Head Neck Surg* 2021;164(06):1153–1159. Doi: 10.1177/0194599820965910
- Tavaluc R, Tan-Geller M. Reinke's Edema. *Otolaryngol Clin North Am* 2019;52(04):627–635. Doi: 10.1016/j.otc.2019.03.006
- El-Demerdash A, Fawaz SA, Sabri SM, Sweed A, Rabie H. Sensitivity and specificity of stroboscopy in preoperative differentiation of dysplasia from early invasive glottic carcinoma. *Eur Arch Otorhinolaryngol* 2015;272(05):1189–1193. Doi: 10.1007/s00405-015-3530-z
- Rzepakowska A, Sielska-Badurek E, Osuch-Wójcikiewicz E, Sobol M, Niemczyk K. The predictive value of videostroboscopy in the assessment of premalignant lesions and early glottis cancers. *Otolaryngol Pol* 2017;71(04):14–18. Doi: 10.5604/01.3001.0010.2243
- D'Ambrosio DN, Clugston RD, Blaner WS. Vitamin A metabolism: an update. *Nutrients* 2011;3(01):63–103. Doi: 10.3390/nu3010063
- Nishimoto K, Taya Y, Davis CR, Tanumihardjo SA, Welham NV. Dynamics of vitamin A uptake, storage, and utilization in vocal fold mucosa. *Mol Metab* 2020;40:101025. Doi: 10.1016/j.molmet.2020.101025
- Tateya I, Tateya T, Surles RL, Kanehira K, Tanumihardjo S, Bless DM. Vitamin A deficiency causes metaplasia in vocal fold epithelium: a rat study. *Ann Otol Rhinol Laryngol* 2008;117(02): 153–158. Doi: 10.1177/000348940811700214
- Hong WK, Endicott J, Itri LM, et al. 13-cis-retinoic acid in the treatment of oral leukoplakia. *N Engl J Med* 1986;315(24): 1501–1505. Doi: 10.1056/NEJM198612113152401
- Lodi G, Franchini R, Warnakulasuriya S, et al. Interventions for treating oral leukoplakia to prevent oral cancer. *Cochrane Database Syst Rev* 2016;7(07):CD001829. Doi: 10.1002/14651858.CD001829
- Sankaranarayanan R, Mathew B, Varghese C, et al. Chemoprevention of oral leukoplakia with vitamin A and beta carotene: an assessment. *Oral Oncol* 1997;33(04):231–236. Doi: 10.1016/s0964-1955(97)00010-9
- Stich HF, Hornby AP, Mathew B, Sankaranarayanan R, Nair MK. Response of oral leukoplakias to the administration of vitamin A. *Cancer Lett* 1988;40(01):93–101. Doi: 10.1016/0304-3835(88) 90266-2

- 19 Bell R, Hong WK, Itri LM, McDonald G, Strong MS. The use of cis-retinoic acid in recurrent respiratory papillomatosis of the larynx: a randomized pilot study. *Am J Otolaryngol* 1988;9(04):161–164. Doi: 10.1016/s0196-0709(88)80023-1
- 20 Camacho LH. Clinical applications of retinoids in cancer medicine. *J Biol Regul Homeost Agents* 2003;17(01):98–114
- 21 Meyskens FL Jr, Gilmartin E, Alberts DS, et al. Activity of isotretinoin against squamous cell cancers and preneoplastic lesions. *Cancer Treat Rep* 1982;66(06):1315–1319
- 22 Lippman SM, Garewal HS, Meyskens FL Jr. Retinoids as potential chemopreventive agents in squamous cell carcinoma of the head and neck. *ReviewPrev Med* 1989;18(05):740–748. Doi: 10.1016/0091-7435(89)90045-5
- 23 Issing WJ, Struck R, Naumann A. Long-term follow-up of larynx leukoplakia under treatment with retinyl palmitate. *Head Neck* 1996;18(06):560–565. Doi: 10.1002/(SICI)1097-0347(199611/12)18:6<560:AID-HED11>3.0.CO;2-C
- 24 Okur E, Kahveci OK, Aycicek A, Altuntaş A The effect of retinyl palmitate on healing of benign vocal fold lesions. *Eur Arch Otorhinolaryngol* 2013;270(01):239–242. Doi: 10.1007/s00405-012-2163-8
- 25 Garcia Martins RH, Marques Madeira SL, Fabro AT, Rocha NdeS, de Oliveira Semenzati G, Alves KF. Effects to exposure of tobacco smoke and alcohol on the tongue and pharynx of rats. *Inhal Toxicol* 2012;24(03):153–160. Doi: 10.3109/08958378.2011.649190
- 26 Jackler RK, VanWinkle CK, Bumanlag IM, Ramamurthi D. Alcohol-flavoured tobacco products. *Tob Control* 2018;27(03):294–300. Doi: 10.1136/tobacco
- 27 Chen M, Cheng L, Li CJ, Chen J, Shu YL, Wu HT. Nonsurgical Treatment for Vocal Fold Leukoplakia: An Analysis of 178 Cases. *BioMed Res Int* 2017;2017:6958250. Doi: 10.1155/2017/6958250
- 28 Sezen Goktas S, Dogan R, Yenigun A, Calim OF, Ozturan O, Tugrul S. A new approach to vocal cord leukoplakia and evaluation of proton pump inhibitor treatment. *Eur Arch Otorhinolaryngol* 2019;276(02):467–471. Doi: 10.1007/s00405-018-05273-9
- 29 Li X, Huang Z, Wu T, Wang L, Wu J. [Role of laryngopharyngeal reflux on the pathogenesis of vocal cord leukoplakia and early glottic cancer]. *Zhonghua Er Bi Yan Hou Tou Jing Wai Ke Za Zhi* 2014;49(05):362–367