

Collagenous Gastritis and *Helicobacter pylori* Infection: A Mere Coincidence?

Daniela G. Vinsard, MD, Lady Katherine Mejia Perez, MD, Aziza Nassar, MD, and Maria I. Vazquez Roque, MD

Department of Gastroenterology and Hepatology, Mayo Clinic, Jacksonville, FL

ABSTRACT

A 21-year-old woman presented to our clinic after 7 years of abdominal pain, diarrhea, and iron-deficiency anemia. Initial upper endoscopy revealed severe inflammation and nodularity of the gastric body and active *Helicobacter pylori* infection. After eradication therapy, esophagogastroduodenoscopy showed gastric atrophy with nodularity resolution. Histopathology revealed scattered plasma cells, eosinophils, and collagen deposition suggestive of collagenous gastritis. *H. pylori* can induce proinflammatory cytokines, resulting in fibroblast upregulation. Collagenous gastritis may be caused by an inflammatory response associated with type I, II, and III collagen. Although further research is warranted, we hypothesize that chronic inflammation from *H. pylori* may lead to collagenous gastritis.

INTRODUCTION

Collagenous gastritis (CG) is a rare disease, first described in a 15-year-old girl with subepithelial fibrosis of the gastric body.¹ Fewer than a hundred cases have been reported since then. Significant efforts have been made to determine histological patterns, but the pathogenesis remains unknown. An immune mechanism, driven by luminal antigens triggering a fibroinflammatory cascade, has been suggested.^{2,3} To date, 4 cases have been reported with coexisting *Helicobacter pylori* in patients with CG.^{4,5} Currently, there is no consensus on treatment strategies.²

CASE REPORT

A 21-year-old woman of Cuban origin presented with multiple digestive complaints. Severe watery diarrhea and poor feeding tolerance were documented shortly after birth. During her childhood she adopted several dietary restrictions, avoiding gluten, lactose, and fruits with no significant improvement. At age 14 years, intermittent abdominal pain and refractory iron-deficiency anemia were noted. Her medications included oral and intravenous iron supplements. At age 20 years, esophagogastroduodenoscopy (EGD) showed diffuse severe inflammation with edema, erythema, and nodularity in the gastric body (Figure 1). Histopathology was positive for *H. pylori* and showed normal duodenal mucosa without villous atrophy. Serology was negative for celiac disease while on a diet containing gluten. Her autoimmune panel was unremarkable. *H. pylori* was successfully eradicated with triple therapy (clarithromycin, amoxicillin, and omeprazole), but severe cramping persisted.

At age 21 years, she was referred to our clinic, with disabling abdominal pain that worsened after food ingestion. Additional symptoms included low-grade fevers, acid reflux, persistent hiccups, and postprandial diarrhea. Physical exam revealed a slim patient (body mass index 19.5 kg/m²). Laboratory studies showed hemoglobin and hematocrit on the lower-normal range. Serum immunoglobulin G (IgG), IgM, IgA, IgE, C3, and C4 were normal. Stool studies were negative for ova and parasites.

ACG Case Rep J 2017;4:e69. doi:10.14309/crj.2017.69. Published online: May 24, 2017.

Correspondence: Maria I. Vazquez Roque, Department of Gastroenterology and Hepatology, Mayo Clinic, 4500 San Pablo Rd, Jacksonville, FL 32224 (vazquezroque.maria@mayo.edu).



Copyright: © 2017 Vinsard et al. This work is licensed under a Creative Commons Attribution-NonCommercial-NoDerivatives 4.0 International License. To view a copy of this license, visit <http://creativecommons.org/licenses/by-nc-nd/4.0>.

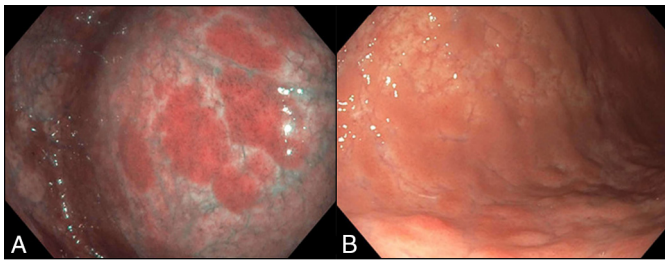


Figure 1. (A) EGD with narrow band imaging showing severe inflammation and erythema with active *H. pylori* infection. (B) EGD showing a nodular mucosa with active *H. pylori* infection.

A second EGD showed diffuse gastric atrophy and blotchy areas of erythema, with significant improvement from prior endoscopy (Figure 2). Prior gastric nodularity resolved, and both the esophagus and duodenum were normal. Histopathology revealed chronic gastritis with subepithelial collagen thickening that was confirmed with Masson trichrome stain. The collagenous band thickness measured 200 μm with a scattered infiltrate of plasma cells and eosinophils. *H. pylori* immunostaining was negative (Figure 3). Colonoscopy was normal, and random biopsies showed no evidence of collagenous colitis. Computed tomography enterography, a fructose intolerance test, and capsule endoscopy were unremarkable.

CG was diagnosed. The patient was started on oral budesonide, delayed-release capsules, at a dose of 3 mg twice a day. The capsules were opened and the granules mixed with maple syrup. Six months later, the patient showed moderate improvement of abdominal pain, anemia resolution, and persistent heartburn.

DISCUSSION

Collagenous gastritis is a rare disease, first reported in 1989 by Colleti and Trainer.¹ Histologically, it is characterized by patchy deposition of collagen in the lamina propria, and by a plasmacytic and lymphocytic infiltrate of the mucosa.¹ According to the clinical presentation, it is classified in 2 groups.⁶ The pediatric type is associated with abdominal pain, anemia, and is colon sparing, whereas the adult type is characterized by abdominal pain, watery diarrhea, colonic

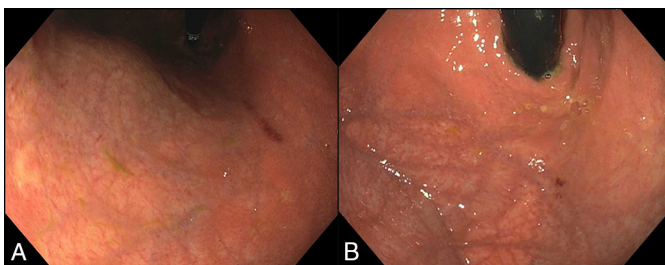


Figure 2. EGD showing an atrophic stomach one year after *H. pylori* eradication.

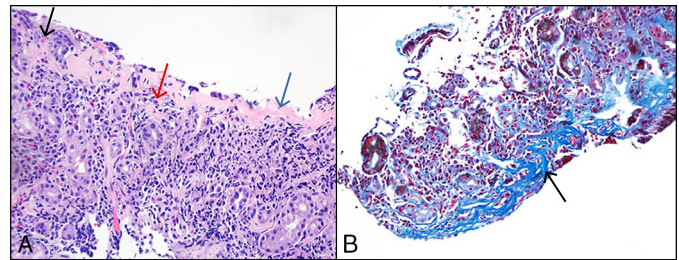


Figure 3. (A) Hematoxylin and eosin stain (40x) showing an inflammatory infiltrate consisting of eosinophils (black arrow), plasma cells (red arrow), and collagen (blue arrow). (B) Masson trichrome stain (40x) showing subepithelial collagenous band measuring up to 200 μm (arrow).

involvement, and autoimmune diseases.^{4,6} This patient fits the pediatric presentation. Current therapy focuses on symptom control. Antisecretory, antiinflammatory medications, oral iron, blood transfusions, and triple therapy for *H. pylori* have been reported.³⁻⁹ Oral steroids are usually considered after failure with these treatment modalities, given the side effects of chronic steroid therapy.⁹⁻¹¹ Additional measures include misoprostol, bismuth subsalicylate, a gluten-free diet, and parenteral nutrition, all with variable clinical response.^{3,4,7,9,10,12-14}

The pathogenesis of this disease remains unknown. Histopathology has shown that collagen type I, II, III, and tenascin are predominant, suggesting that collagen is produced in response to inflammation.^{7,15,16} When we rechecked gastric biopsies obtained on the first EGD, the histopathology did reveal concomitant CG and *H. pylori* infection. A lack of awareness of this condition might result in underdiagnosis. This is the fourth case of *H. pylori* infection reported in association with CG.^{5,17} The clinical outcomes of *H. pylori* infection are highly variable due to the diversity in microorganism virulence factors and the inflammatory response of the host.^{18,19} Although it is not invasive, it binds connective tissue proteins and induces the release of pro-inflammatory chemokines, promoting infiltration of leukocytes and inducing differentiation of fibroblasts into myofibroblasts, which in turn produce extracellular matrix-like proteins resulting in collagen deposition and fibrosis.²⁰⁻²² Interleukin (IL)-1 β is produced in the gastric mucosa in response to an insult and upregulates the expression of IL-8, promoting a proinflammatory environment characterized by recruitment and activation of neutrophils.¹⁸ IL-1 β polymorphism might induce an inappropriately upregulated inflammatory reaction in response to *H. pylori*, resulting in fibrosis and collagen deposition.¹⁸

Although we cannot demonstrate causality in this case, we point out 2 coexisting patterns of chronic gastric inflammation: the macroscopic nodular appearance in the mucosa and the long-term mucosal collagen infiltration. Under normal circumstances, eradication of *H. pylori* leads to reversal of the above mentioned cytokine abnormalities. A few cases

reporting resolution of collagenous colitis after successful *H. pylori* eradication therapy, and 3 prior cases of pediatric CG with improvement of nutritional status, support this theory.^{4,5,23} From a macroscopic standpoint, the results after eradication therapy were varied, with one case showing resolution of the nodular pattern on follow-up EGD.^{4,5}

On follow-up endoscopy of prior cases, the subepithelial collagen band remained unchanged and did not correlate with the clinical course.^{7,10,14} In our case, the erythema and nodular pattern found on first EGD were resolved after eradication therapy; however, some of the patient's symptoms and the microscopic collagen bands persisted. *H. pylori* may irreversibly modify the expression of structural genes, potentially modifying the risk of neoplasia.²⁰ Intestinal metaplasia and endocrine cell hyperplasia were described in one case after 12 years of follow-up. The risk of progression to adenocarcinoma remains unknown.¹³ The rarity of CG limits the feasibility of conducting clinical trials, and further description of cases should be encouraged to raise awareness of this disease entity and establish appropriate management strategies.

DISCLOSURES

Author contributions: All authors collected data, wrote and edited the manuscript, and provided the images. MI Vazquez Roque is the article guarantor.

Financial disclosure: None to report.

Informed consent was obtained for this case report.

Received October 17, 2016; Accepted March 15, 2017

REFERENCES

- Colletti RB, Trainer TD. Collagenous gastritis. *Gastroenterology*. 1989;97(6):1552-5.
- Nielsen OH, Riis LB, Danese S, Bojesen RD, Soendergaard C. Proximal collagenous gastroenteritides: Clinical management. A systematic review. *Ann Med*. 2014;46(5):311-7.
- Leung ST, Chandan VS, Murray JA, Wu TT. Collagenous gastritis: Histopathologic features and association with other gastrointestinal diseases. *Am J Surg Pathol*. 2009;33(5):788-98.
- Kori M, Cohen S, Levine A, et al. Collagenous gastritis: A rare cause of abdominal pain and iron-deficiency anemia. *J Pediatr Gastroenterol Nutr*. 2007;45(5):603-6.
- Dray X, Reignier S, Vahedi K, Lavergne-Slove A, Marteau P. Collagenous gastritis. *Endoscopy*. 2007;39(Suppl 1):E292-3.
- Lagorce-Pages C, Fabiani B, Bouvier R, Scoazec JY, Durand L, Flejou JF. Collagenous gastritis: A report of six cases. *Am J Surg Pathol*. 2001;25(9):1174-9.
- Brain O, Rajaguru C, Warren B, Booth J, Travis S. Collagenous gastritis: Reports and systematic review. *Eur J Gastroenterol Hepatol*. 2009;21(12):1419-24.
- Meunier S, Villard F, Bouvier R, Lachaux A, Bertrand Y. [Collagen gastritis, an unusual cause of anemia in children. Report of 2 cases]. *Arch Pediatr*. 2001;8(1):47-50.
- Suskind D, Wahbeh G, Murray K, Christie D, Kapur RP. Collagenous gastritis, a new spectrum of disease in pediatric patients: Two case reports. *Cases J*. 2009;2:7511.
- Côté JF, Hankard GF, Faure C, et al. Collagenous gastritis revealed by severe anemia in a child. *Hum Pathol*. 1998;29(8):883-6.
- Zhang HJ, Jin Z, Lin SR, et al. [A case report of collagenous gastritis in a young Chinese woman and literatures review]. *Zhonghua Nei Ke Za Zhi*. 2010;49(8):688-90.
- Billimaz K, Robles-Medrande C, Le Gall C, et al. A first report of collagenous gastritis, sprue, and colitis in a 9-month-old infant: 14 years of clinical, endoscopic, and histologic follow-up. *Endoscopy*. 2009;41(suppl 3):E233-4.
- Winslow JL, Trainer TD, Colletti RB. Collagenous gastritis: A long-term follow-up with the development of endocrine cell hyperplasia, intestinal metaplasia, and epithelial changes indeterminate for dysplasia. *Am J Clin Pathol*. 2015;116(5):753-8.
- Camarero Salces C, Enes Romero P, Redondo C, Rizo Pascual JM, Roy Arino G. Collagenous colitis and collagenous gastritis in a 9 year old girl: A case report and review of the literature. *Acta Gastroenterol Belg*. 2011;74(3):468-74.
- Jain R, Chetty R. Collagenous gastritis. *Int J Surg Pathol*. 2010;18(6):534-6.
- Jawhari A, Talbot IC. Microscopic, lymphocytic and collagenous colitis. *Histopathology*. 1996;29(2):101-10.
- Hijaz NM, Septer SS, Degaetano J, Attard TM. Clinical outcome of pediatric collagenous gastritis: Case series and review of literature. *World J Gastroenterol*. 2013;19(9):1478-84.
- El-Omar EM. The importance of interleukin 1beta in *Helicobacter pylori*-associated disease. *Gut*. 2001;48(6):743-7.
- Hussain S, Hamid S. *Helicobacter pylori* in humans: Where are we now? *Adv Biomed Res*. 2014;3(1):63.
- Krzysiek-Maczka G, Targosz A, Ptak-Belowska A, et al. Molecular alterations in fibroblasts exposed to *Helicobacter pylori*: A missing link in bacterial inflammation progressing into gastric carcinogenesis? *J Physiol Pharmacol*. 2013;64(1):77-87.
- Moran AP, Khamri W, Walker MM, Thursz MR. Role of surfactant protein D (SP-D) in innate immunity in the gastric mucosa: Evidence of interaction with *Helicobacter pylori* lipopolysaccharide. *J Endotoxin Res*. 2005;11(6):357-62.
- Trust TJ, Doig P, Emödy L, Kienle Z, Wadström T, O'Toole P. High-affinity binding of the basement membrane proteins collagen type IV and laminin to the gastric pathogen *Helicobacter pylori*. *Infect Immun*. 1991;59(12):4398-404.
- Narayani RI, Burton MP, Young GS. Resolution of collagenous colitis after treatment for *Helicobacter pylori*. *Am J Gastroenterol*. 2002;97(2):498-9.