

## Oncology

## Benign fibroepithelial polyp of the ureter: A case report

Kays Chaker<sup>a,\*</sup>, Sami Ben Rhouma<sup>a</sup>, Kheireddine Mrad Daly<sup>a</sup>, Alia Zehani<sup>b</sup>, Mokhtar Bibi<sup>a</sup>, Mohamed Ali Ben Chehida<sup>a</sup>, Ahmed Sellami<sup>a</sup>, Yassine Nouira<sup>a</sup>

<sup>a</sup> *Departement of Urology La Rabta Hospital, Tunisia*

<sup>b</sup> *Department of Anatomy and Pathological Cytology, La Rabta Hospital, Tunisia*



## Introduction

Fibroepithelial polyp of the ureter is the most common form of rare benign mesodermal tumors of urinary tract. The etiology of this tumor is still unknown. Hematuria is the most frequent of revealing signs. Imaging methods are not always contributive. The diagnosis is confirmed by histological examination. The treatment of fibro epithelial polyp of the ureter is endoscopic.

## Case report

A 37 year-old patient, without medical or surgical history, presented with a total intermittent hematuria of 3 months duration. Clinical examination was normal. Renal function test and hemogram was within normal limits. Urine culture was negative. Uro CT scan showed an obstructive intra-luminal lesion of 5 cm, localized in left pelvic and iliac regions. In delayed phase, we found a contrast-enhancing lacuna with large implantation base (Fig. 1). Endoscopic exploration showed a 7 cm-sized sessile ureteral polyp, 3 cm far from the ureteral meatus. Its implantation base was at the left iliac ureter. Histological examination concluded to fibro epithelial polyp of the ureter. The patient underwent an endoscopic excision of the polyp. The polyp stalk was coagulated and excised with claspers forceps and then the whole right ureteroscopy was assessed perfectly. Double-J stent was resided to prevent the ureteral stricture and was removed after two months. Final histological examination confirmed the diagnosis of fibro epithelial polyp (Fig. 2). After a 4 years follow up, there were no signs in uro CT scan of complications or recurrence (Fig. 3).

## Discussion

Non-epithelial tumors are derived from mesodermal tissue. They include leiomyomas, fibroids, neurofibromas, granulomas, en-

dometriomas, lymphangiomas, and fibroepithelial polyps. In fact, fibroepithelial polyps is the predominant form of rare benign mesodermal tumors of the urinary tract [1]. They most frequently concern adults, men are more affected than women.<sup>1</sup> The etiopathogenesis of these polyps is still unknown. Fibroepithelial polyps are found all along the urinary tract but their main sites of implantation are the pyeloureteric junction and the proximal lumbar ureter. They frequently have an effect on the upper urinary tract as they are potentially obstructive.<sup>1</sup> Patients are often presented with hematuria (58%), and flank pain due to obstructive hydronephrosis (79%).<sup>1</sup> The pain is generally intermittent.<sup>1</sup> Intravenous urography reveals typically a long spiral defect, with moderate dilatation of the cavities upstream.<sup>2</sup> Ultrasound can show an echogenic tissue mass, with polypoid projections in the ureteral lumen. CT scan confirms the absence of calculi, and studies the polyp's relationship with the ureteral wall.<sup>2</sup> This diagnosis remains difficult because polyps often escape imaging and the radiological appearance is limited to images of ureteral obstruction.<sup>2</sup> Ureteroscopy has an important place in the diagnosis. It allows to visualize polyps and to perform biopsies.<sup>3</sup> Currently, endoscopic surgery has become the best technique for the treatment of fibroepithelial polyps,<sup>4</sup> as it reduces morbidity and minimizes the risk of stenosis and recurrence with an early convalescence. This surgery can be performed percutaneously or using ureteroscopy. Rigorous clinical and radiological monitoring is recommended because recurrence is possible.<sup>3</sup> However, no case of malignant transformation has been reported.<sup>3</sup>

## Conclusion

Fibroepithelial polyp of the ureter is a rare benign tumor. Its etiology is still unknown. Preoperative diagnosis is often difficult. It must be suspected when filiform defects are found on imaging methods after excluding other causes of ureteral obstruction. Endoscopic conservative treatment allows early convalescence and lasting results.

\* Corresponding author.

E-mail address: [chakerkays@gmail.com](mailto:chakerkays@gmail.com) (K. Chaker).

<https://doi.org/10.1016/j.eucr.2018.10.019>

Received 28 September 2018; Received in revised form 24 October 2018; Accepted 31 October 2018

Available online 01 November 2018

2214-4420/ © 2018 Published by Elsevier Inc. This is an open access article under the CC BY-NC-ND license (<http://creativecommons.org/licenses/by-nc-nd/4.0/>).

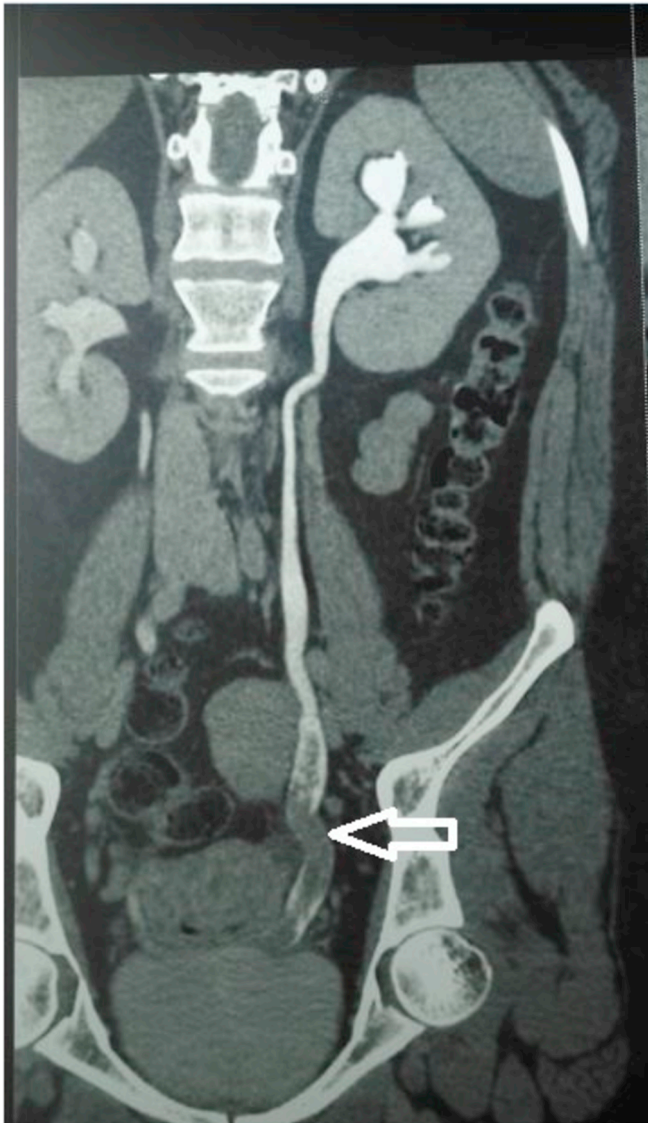

Fig. 1. Contrast-enhanced abdominal computed tomography showed a 5 cm intra-luminal ureteral lesion that is obstructive with homogenous contrast enhancement.

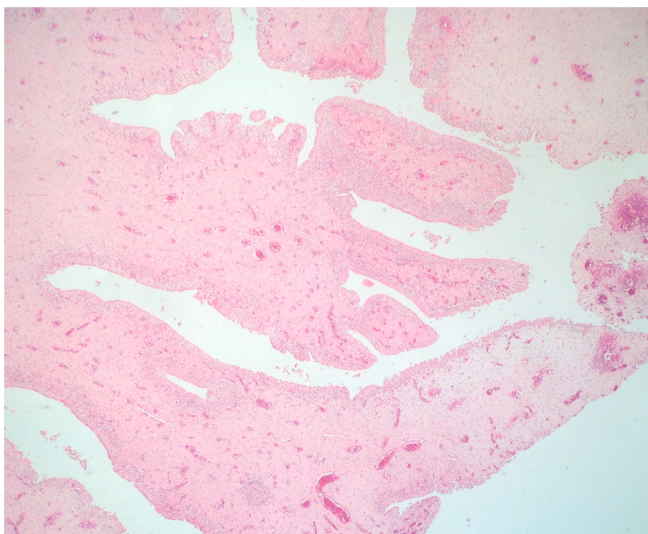


Fig. 2. Fibroepithelial polyp consisting of a fibrovascular core and a covering of normal urothelium: (Hematoxyline eosine x10).

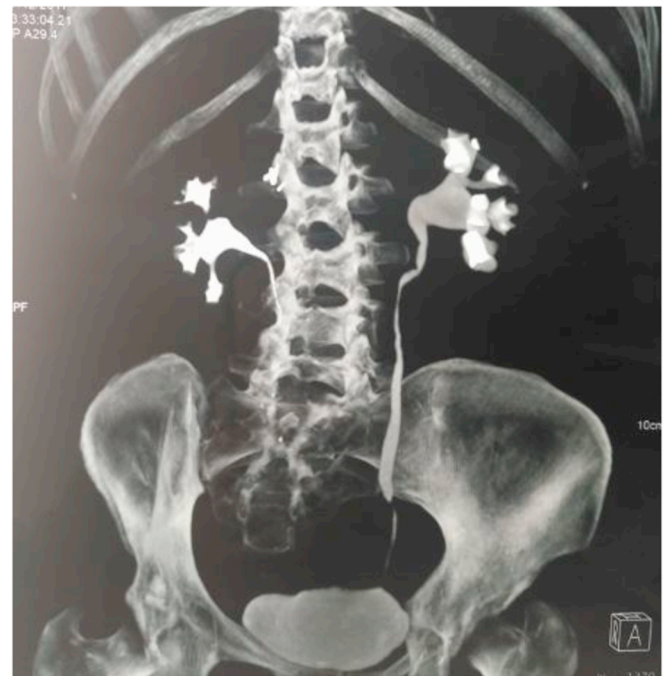


Fig. 3. Postoperative abdominal computed tomography shows the absence of local recurrence and postoperative complication except for slight dilation of the excretory cavities.

**Conflicts of interest**

None.

**References**

1. Chang HH, Ray P, Ockuly E, et al. Benign fibrous ureteral polyp. *Urology*. 1987;30 114–18.
2. Niu ZB, Yang Y, Hou Y, et al. Ureteral polyps: an etiological factor of hydronephrosis in children that should not be ignored. *Pediatr Surg Int*. 2007;23 323–6.
3. Ruiz-Lopez MJ, Ramirez-Garrido F, Nogueras-Ocana M, et al. Recurrent ureteric fibroepithelial polyp in a child. *Eur J Pediatr*. 2004;163 124–5.
4. Lam J, Bingham J, Gupta M. Endoscopic treatment of fibroepithelial polyps of the renal pelvis and ureter. *Urology*. 2003;62 810–3.