

## Mucopolysaccharidosis type I Hurler-Scheie syndrome affecting two sisters

Reena Anand, DNB; Deepak Bhatia, MD; and D.S. Yadav, DNB

Mucopolysaccharidosis I (MPS I) is a rare inherited disorder characterized by physical deformities and developmental anomalies. Part of a group of clinically progressive disorders, it is caused by the deficiency of the lysosomal enzyme,  $\alpha$ -L-iduronidase, which results in intralysosomal accumulation of dermatan sulfate and heparan sulfate and in turn causes cell dysfunction. Two sisters, one 11 years old and the other 7, both MPS type I H/S, came to our diagnostic center. Hand-wrist radiographs revealed bullet-shaped phalanges with proximal pointing of the second to fifth metacarpals. Ultrasonographic examination showed splenomegaly in the younger child. Radiography of the pelvis showed a narrow pelvis with flared iliac wings. A skull skiagram showed J-shaped sella.

### Introduction

Mucopolysaccharidosis type I (MPS I) is a progressive multisystem disorder with features ranging over a continuum from mild to severe. Clinical features usually noted within the first two years are hepatosplenomegaly, skeletal deformity, coarse facial features, corneal clouding, large tongue, prominent forehead, joint stiffness, and short stature. Progressive skeletal dysplasia (dysostosis multiplex) involving all bones occurs in all individuals with severe MPS I.

### Case report

Two sisters, one 11 years old and the other 7, both MPS type I H/S, came to our diagnostic center for a skeletal survey and abdominal sonography. On clinical examination, both children were short-statured (stunted growth) and presented coarse facial features. The elder's height was 105 cm and weight 23 kg, and the younger's height was 78 and

weight 18 kg. This was less than the 3rd percentile on the NCHS standard. Both sisters had large heads, short necks, depressed nasal bridges, large thick tongues, and joint contractures (Figs. 1A and 1B). Medical history revealed that both suffered frequent respiratory infections (chronic sinus infections), stiffness of joints, and hepatomegaly (the last more severe in the elder sister). Their family history was noncontributory. On radiological evaluation, hand-wrist radiographs revealed bullet-shaped phalanges with proximal pointing of the second to fifth metacarpals (Figs. 2A and 2B, in the older and younger one, respectively). Radiography of the spine and ribs showed anterior notching in the thoraco-lumbar vertebral bodies, with mild inferior beaking in the L2 vertebra and oar-shaped ribs (Fig. 3). Radiography of the pelvis revealed a narrow pelvis with flared iliac wings (Fig. 4).

Ultrasonographic examination showed splenomegaly in the younger child (Fig. 5). A skull skiagram showed J-shaped sella (Fig. 6). Echocardiography showed mitral-valve thickening and mild mitral regurgitation as well (Fig. 7).

Later blood and urine examination of both patients showed deficient enzyme activity of MPS-1 ( $\alpha$ -L-iduronidase). The values were 1.8 nmol/hr/ng in the elder, and 0.5 nmol/hr/mg in the younger child. Urinalysis revealed increased traces of iduronite sulphate and dermatan sulphate. The younger sister has an IQ of 50 (moderate mental retardation), and the elder has IQ of 70 (mild mental retardation). Other hematological investigations were within normal limits.

**Citation:** Anand R, Bhatia D, Yadav DS. Mucopolysaccharidosis type I Hurler-Scheie syndrome affecting two sisters. *Radiology Case Reports*. (Online) 2011;7:641.

**Copyright:** © 2012 The Authors. This is an open-access article distributed under the terms of the Creative Commons Attribution-NonCommercial-NoDerivs 2.5 License, which permits reproduction and distribution, provided the original work is properly cited. Commercial use and derivative works are not permitted.

Drs. Anand, Bhatia, and Yadav are all at the Modern Diagnostic and Research Centre, Gurgaon, India. Contact Dr. Anand at [anand.reena@yahoo.com](mailto:anand.reena@yahoo.com).

**Competing Interests:** The authors have declared that no competing interests exist.

DOI: 10.2484/rcr.v7i2.641

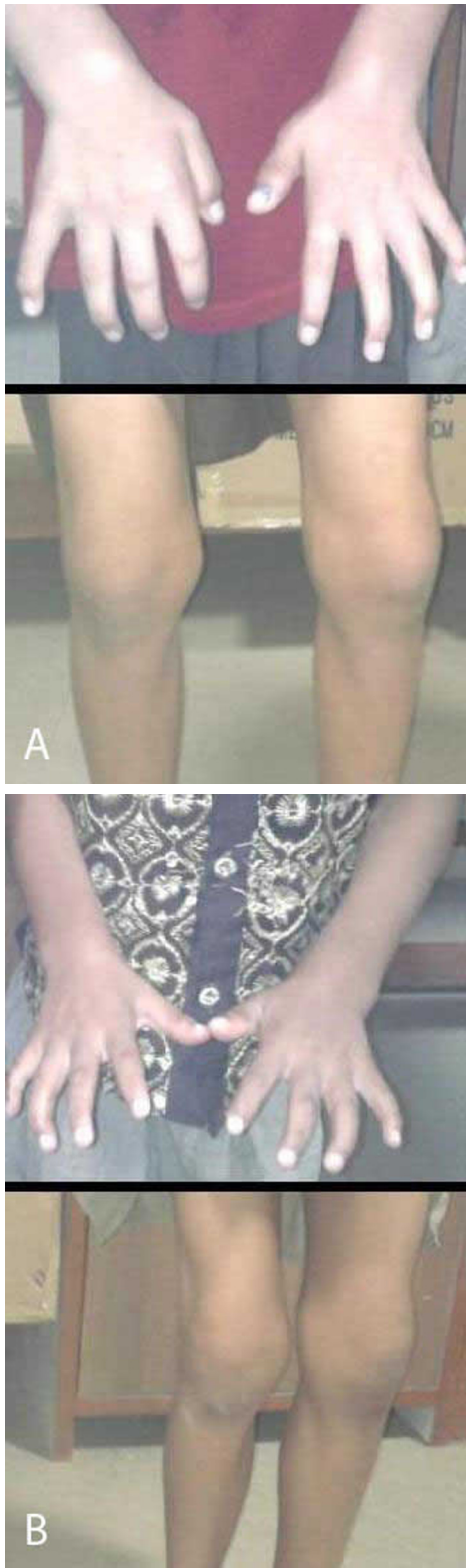

Figure 1. 7- and 11-year-old sisters with mucopolysaccharidosis I, Hurler-Scheie and Scheie syndrome. Picture of hands and knees of both children, showing contracture of joints.

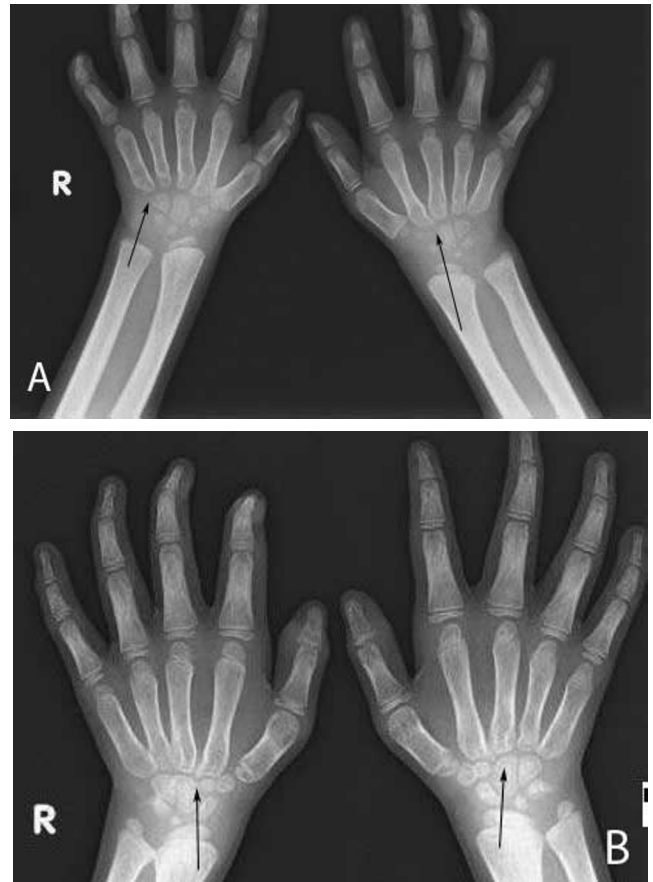


Figure 2. 7- and 11-year-old sisters with mucopolysaccharidosis I, Hurler-Scheie and Scheie syndrome. Hand-wrist skiagram. Arrows show bullet-shaped phalanges with proximal pointing of the second to fifth metacarpals. A. Older sister. B. Younger sister.

## Discussion

Mucopolysaccharidosis-I (MPS I) is a lysosomal storage disorder inherited as an autosomal-recessive condition and is caused by a deficiency of the lysosomal enzyme  $\alpha$ 1-iduronidase. This results in the progressive accumulation of glycosaminoglycans (GAG) within the lysosomes, leading to multiorgan dysfunction and damage (1). Patients affected with MPS I are unable to degrade the GAG, dermatan sulfate, and heparan sulfate, which provide structural support to the extracellular matrix and cartilaginous structures such as joints and heart valves (2).

MPS I has an estimated incidence of 1 case per 100,000 live births, and the attenuated type represents about 20% of the total MPS I population. MPS I includes separate diseases on the basis of clinical presentation: Hurler Syndrome (severe), Hurler-Scheie syndrome (intermediate), and Scheie syndrome (mild) (3). However, since MPS I has been recognized as a disease continuum due to variation in age of onset and rate of disease progression, an international panel composed of 12 experts on MPS I revised and

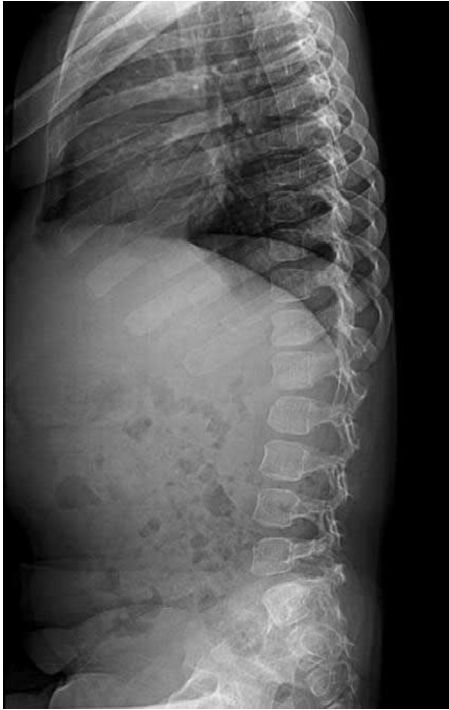

Figure 3. 7- and 11-year-old sisters with mucopolysaccharidosis I, Hurler-Scheie and Scheie syndrome. Radiograph of spine and ribs showed anterior notching in thoraco-lumbar vertebral bodies with mild inferior beaking in L2 vertebra and oar-shaped ribs.

updated the initial guidelines in 2008 on the basis of additional clinical data and therapeutic advances. Based on their recommendations, MPS I has been classified into two

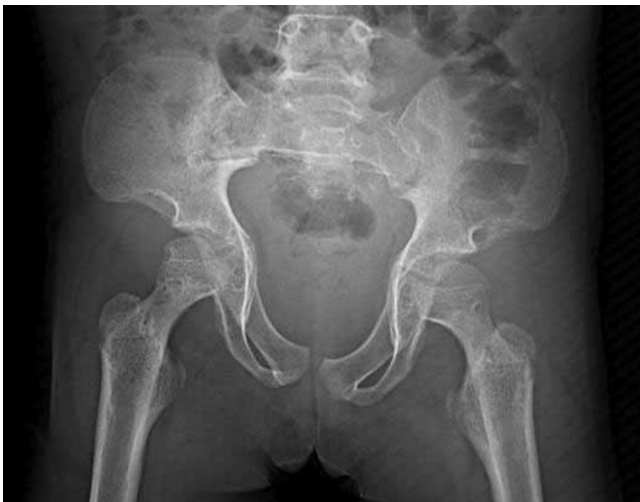

Figure 4. 7- and 11-year-old sisters with mucopolysaccharidosis I, Hurler-Scheie and Scheie syndrome. Radiograph of pelvis showed narrow pelvis with flared iliac wings.

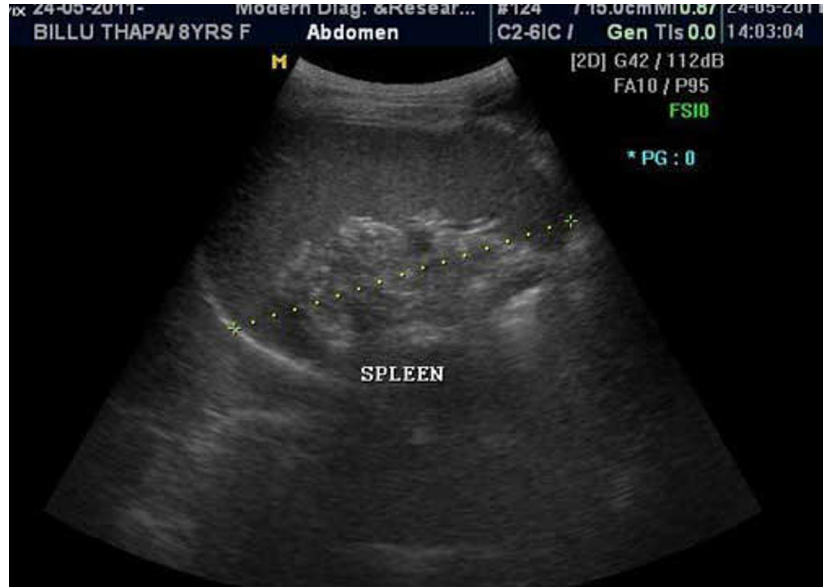

Figure 5. 7- and 11-year-old sisters with mucopolysaccharidosis I, Hurler-Scheie and Scheie syndrome. Ultrasonographic image showing splenomegaly.

broader groups, severe MPS I (Hurler Syndrome) and attenuated MPS I (Hurler-Scheie and Scheie syndromes).

Infants with severe MPS I appear normal at birth. Clinical features usually noted within the first two years are hepatosplenomegaly, skeletal deformity, coarse facial features,

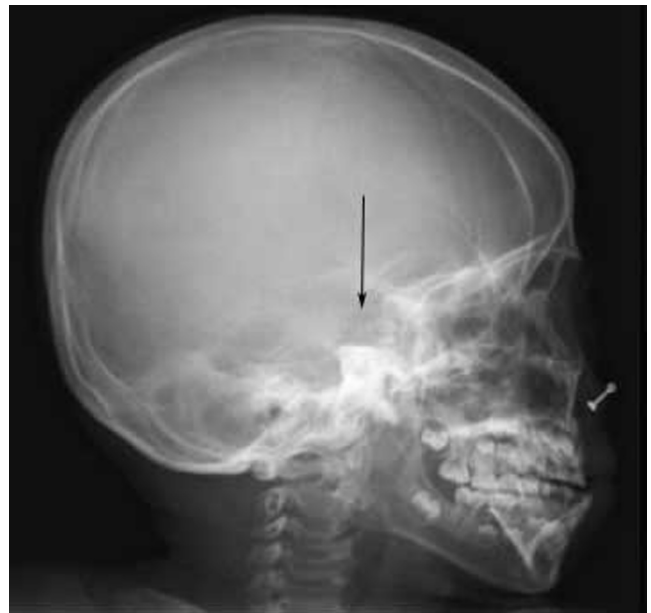

Figure 6. 7- and 11-year-old sisters with mucopolysaccharidosis I, Hurler-Scheie and Scheie syndrome. Skull radiograph with arrow showing J-shaped sella.

corneal clouding, large tongue, prominent forehead, joint stiffness, and short stature. Progressive skeletal dysplasia (dysostosis multiplex) involving all bones occurs in all individuals with severe MPS I (4). By age three, linear growth ceases. Hearing loss is common. All develop progressive and profound intellectual disability. Death, caused by cardiorespiratory failure, usually occurs within the first ten years of life.

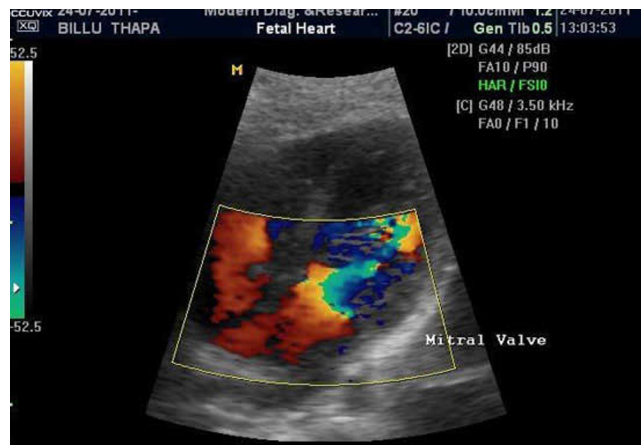


Figure 7. 7- and 11-year-old sisters with mucopolysaccharidosis I, Hurler-Scheie and Scheie syndrome. Echocardiography showed mitral valve thickening and mild mitral regurgitation in younger sister.

The greatest variability is observed in individuals with the attenuated MPS I (5). Onset is usually between ages three and ten years. Although psychomotor development may be normal in early childhood, individuals with attenuated MPS I may have learning disabilities (6). The rate of disease progression and severity can range from serious life-threatening complications (leading to death in the second to third decades) to a normal life span (with significant disability and discomfort from progressive severe restriction in the range of motion of all joints). Hearing loss and cardiac valvular disease are common (7).

The diagnosis of MPS I relies on the demonstration of deficient activity of the lysosomal enzyme  $\alpha$ -L-iduronidase in peripheral blood leukocytes, cultured fibroblasts, or plasma. Glycosaminoglycan (GAG) (heparan and dermatan sulphate) urinary excretion is a useful preliminary test. IDUA is the only gene currently known to be associated with MPS I.

## References

1. Neufeld EF, Muenzer J. The mucopolysaccharidoses. In Scriver C, Beaudet A, Sly W, et al, editors. *The metabolic and molecular bases of inherited disease*. McGraw Hill: New York, NY 2001; 3421-52.
2. Behrman RE, Kleigman RM, Jenson HB. Mucopolysaccharidosis. In Kliegman RM, Stanton BMD, St Geme J, Schor N, Behrman RE. *Nelson textbook of paediatrics*. Philadelphia: Saunders Elsevier, 2004; 482-6.
3. Belani KG, Krivit W, Carpenter BLM, Braunlin E, Buckley JJ, Liao JC, et al. Children with mucopolysaccharidoses; Perioperative care, morbidity, mortality and new findings. *J Pediatr Surg* 1993; 28:403-10. [[PubMed](#)]
4. Wraith JE: The mucopolysaccharidoses. A clinical review and guide to management. *Arch Dis Child* 1995; 72:263-7. [[PubMed](#)]
5. Meikle PJ, Hopwood JJ, Clague AE, Carey WF. Prevalence of lysosomal storage disorders. *J Am Med Assoc* 1999 ; 281:249-54. [[PubMed](#)]
6. Scott HS, Bunge S, Gal A, Clarke LA, Morris CP, Hopwood JJ. Molecular genetics of mucopolysaccharidosis type I. Diagnostic, clinical and biological implications. *Hum Mutat* 1995; 6:288-302. [[PubMed](#)]
7. Pastores G, Arn P, Beck M, Clarke JT, Guffon N, Kalpan P, et al. The MPS I registry: Design, methodology and early findings of a global disease registry for monitoring patients with mucopolysaccharidosis type I. *Mol Genet. Metab.* 2007; 91:37-47. [[PubMed](#)]