

The power of fat and its adipose-derived stromal cells: emerging concepts for fibrotic scar treatment

Maroesjka Spiekman¹, Joris A. van Dongen^{1,2}, Joep C. Willemsen^{1,2}, Delia L. Hoppe³, Berend van der Lei² and Martin C. Harmsen^{1*}

¹Department of Pathology and Medical Biology, University of Groningen, University Medical Center Groningen, Groningen, the Netherlands

²Department of Plastic Surgery, University Medical Center Groningen, University of Groningen, Groningen, the Netherlands

³Department of Plastic and Reconstructive Microsurgery/Hand surgery, Charité University Medicine, Ernst Von Bergmann Clinic, Potsdam, Germany

Abstract

Lipofilling or lipografting is a novel and promising treatment method for reduction or prevention of dermal scars after injury. Ample anecdotal evidence from case reports supports the scar-reducing properties of adipose tissue grafts. However, only a few properly controlled and designed clinical trials have been conducted thus far on this topic. Also, the underlying mechanism by which lipofilling improves scar aspect and reduces neuropathic scar pain remains largely undiscovered. Adipose-derived stromal or stem cells (ADSC) are often described to be responsible for this therapeutic effect of lipofilling. We review the recent literature and discuss anticipated mechanisms that govern anti-scarring capacity of adipose tissue and its ADSC. Both clinical and animal studies clearly demonstrated that lipofilling and ADSC influence processes associated with wound healing, including extracellular matrix remodelling, angiogenesis and modulation of inflammation in dermal scars. However, randomized clinical trials, providing sufficient level of evidence for lipofilling and/or ADSC as an anti-scarring treatment, are lacking yet warranted in the near future. © 2017 The Authors Journal of Tissue Engineering and Regenerative Medicine Published by John Wiley & Sons Ltd

Received 8 February 2016; Revised 16 March 2016; Accepted 14 April 2016

Keywords lipofilling; adipose tissue; adipose-derived stromal/stem cells; stromal vascular fraction; dermal scar; scar treatment

1. Development of lipofilling procedures

Transfer of adipose tissue, also known as fat grafting, lipografting or lipofilling, is recognized as a promising and novel technique for correction of volume deficiency, skin rejuvenation and as treatment for scars. This is strongly supported by evidence-based clinical trials as well as fundamental studies in animals and *in vitro*. The first case of lipofilling in literature dates from 1893, when Gustav Neuber described the first free fat transfer for a scar that had left a young man with a soft tissue defect of the face (Neuber, 1893).

As soon as liposuction was further developed in the mid 1980s, also interest developed of re-using the lipoaspirated subcutaneous adipose tissue. Liposuction pioneers such as Illouz and co-workers (Illouz, 1983) developed the first clinical applications and methods for lipofilling to restore or gain volume. The real breakthrough in lipofilling came with fat harvesting, subsequent processing and subcutaneous administration as described by Coleman (2002), which allowed better survival of the lipograft. Centrifugation was the first successful attempt to improve fat graft survival by removing oil,

fluid and dead cells from the harvested fat tissue. This method also inspired clinical trials to assess volumetric augmentation of the breast and buttocks (Cardenas-Camarena *et al.*, 2011; Khouri *et al.*, 2012).

Initially, introduced by Coleman in the early 1990s, the use of small liposuction and lipofilling cannulas also opened the door for lipofilling of the face and hands for both reconstructive and aesthetic purposes. Especially in these applications with rather superficial lipofilling, effects described as ‘more than volume alone’ were often observed (Coleman, 2002, 2006). This included an improved appearance and quality of the skin, and has subsequently been described in many case reports. Yet a mechanistic underpinning was still lacking. These clinical observations initiated a wide range of clinical applications for lipofilling other than just volume adjustment (Rigotti *et al.*, 2007). This novel idea to use lipofilling for treatment of (the consequences of) tissue damage has led to the use of lipofilling to treat burn scars (Klinger *et al.*, 2008) and even to alleviate scar-associated pain as occurring for example after mastectomy (Caviggioli *et al.*, 2011).

In 2001, Zuk and colleagues (Zuk *et al.*, 2001) demonstrated that adipose tissue had a source of endogenous mesenchymal stem cells (MSC), which were named adipose-derived stem or stromal cells (ADSC). This discovery significantly advanced the use of lipofilling as a regenerative therapy, as it had been shown that at least one of the components of adipose tissue had therapeutic

*Correspondence to: Martin C. Harmsen, Department of Pathology and Medical Biology, University of Groningen, University Medical Center Groningen, Hanzeplein 1 (EA11), 9713 GZ Groningen, the Netherlands. E-mail: m.c.harmsen@umcg.nl

potential. Since then, many of the beneficial effects observed after lipofilling have been attributed to ADSC.

In this review the authors, both clinicians and biologist, try to bridge the gap between both worlds, provide a review of recent literature and summarize the possible mechanism behind the anti-scarring effect of adipose tissue and its ADSC.

2. Lipofilling on a cellular level

Liposuction simply implicates the harvest of adipose tissue under negative pressure with small-bore suction cannulas. By this, the architecture of the fat tissue is disrupted and small lumps of adipose tissue are harvested and collected in a sterile environment (bag or collector), which can then be used for lipofilling subsequently. Inevitably, some degree of hypoxia occurs around the grafting of the lipospiate. In the recipient, the integration of the graft requires extensive (re)vascularization, which is primed by the occurring hypoxia as well as by the pre-existing microvasculature in the graft. Too large 'lumps' of lipograft obviously develop necrotic cores due to diffusion insufficiency, as a result of which the graft 'take' may be reduced (Dong *et al.*, 2013; Eto *et al.*, 2012; Kato *et al.*, 2014). Adipocytes are sensitive to hypoxia and as a consequence prone to apoptosis (Eto *et al.*, 2012; Kato *et al.*, 2014; Suga *et al.*, 2010). Depending on the technique and time that is required for harvesting and lipofilling (Fisher *et al.*, 2013; Pu *et al.*, 2008), 40–90% of the injected lipograft volume will remain (Hivernaud *et al.*, 2015), while the rest is resorbed within months after grafting. Oily cysts may remain in the grafted area as a consequence of this fat necrosis. To improve fat graft survival, different processing techniques are used (e.g. centrifugation, decantation, gauze-towel technique). In a systematic review, these techniques are compared for viability of the fat graft as a whole (Tuin *et al.*, 2016) in terms of number of viable cells and in terms of graft volume survival in human and animal models. For fat graft survival, the gauze-towel processing technique is found to be superior to centrifugation or decantation. However, if the focus lies on the number of ADSC in adipose grafts, centrifugation improves the number of ADSC that can be isolated, compared with a non-centrifuged fat (Ibatici *et al.*, 2014). Thus, depending on the goal of lipofilling, different fat-processing techniques need to be considered carefully.

Adipose tissue, the energy storehouse of the human body, consists of a parenchymal mass of adipocytes that is structurally supported by connective tissue and perfused by blood vessels. All non-adipocyte tissue is called stroma or stromal tissue. Adipocytes are the main volumetric component of adipose tissue, although they only comprise up to 20% of all cells (Eto *et al.*, 2009). Adipocytes consist of a thin layer of cytoplasm with an eccentric nucleus, while most of the volume is made up by the large central vacuole in which triglycerides predominantly are stored (Carmen and Victor, 2006).

During development, adipose tissue is derived from the mesodermal germ layer. The MSC that reside in the mesoderm differentiate into adipocytes to form adipose tissue. However, after the embryogenic formation of adipose tissue, some of the MSC or stromal cells remain. In the adult situation, these MSC are the previously mentioned ADSC. In the adipose tissue, ADSC reside around the vasculature (Crisan *et al.*, 2008; Lin *et al.*, 2008; Tang *et al.*, 2008; Traktuev *et al.*, 2008). Furthermore, ADSC retain the ability to differentiate into adipocytes, thus functioning as a source to regenerate adipose tissue (Cawthorn *et al.*, 2012).

3. Lipofilling as a method to treat scars

As stated above, lipofilling is beneficial for skin and scar treatment. In recent years, a limited number of retrospective and prospective studies supported previous anecdotal clinical observations (Table 1a).

3.1. Clinical studies

The clinical efficacy of lipofilling in scar areas is determined by improvement of the appearance of a scar, such as size, thickness, stiffness, discoloration of the scar. In the case of painful scars, this effect can also be measured by a decrease in pain. In the first subsection of this summary of clinical studies, the focus lies on the ability of lipografts to improve several of the above-mentioned appearances of scars, whereas in the second subsection focus lies on the ability to reduce pain.

3.1.1. Scar appearance

Macroscopically, scars are characterized by a different appearance to the surrounding skin: discoloration, stiffness and roughness are features of scarring. In clinical studies, different outcome measures are used to quantify the degree of scarring on a macroscopic level. The first methods often used to assess scar severity are patient- or observer-rated grading scales, in which several aspects of scarring (e.g. colour, stiffness, thickness, irregularity) are rated. A second method is to use measuring devices for skin elasticity or dermal pigmentation.

The efficacy of lipofilling to improve scar appearance has been investigated in 16 case reports or clinical trials (Balkin *et al.*, 2014; Bollero *et al.*, 2014; Bruno *et al.*, 2013; Coleman, 2006; Guisantes *et al.*, 2012; Klinger *et al.*, 2008; Maione *et al.*, 2014a; Mazzola *et al.*, 2013; Pallua *et al.*, 2014; Phulpin *et al.*, 2009; Ribuffo *et al.*, 2013; Sardesai and Moore, 2007; Wang *et al.*, 2013; Zellner *et al.*, 2015; Table 1a). In 10 studies of these publications, comprising of a total of 156 patients, complications were recorded: in nine of these 10 studies no complications were recorded, whereas in one study with 12 patients there was a case of cellulitis reported as a complication. Hence, it seems that risks of lipofilling in scar areas are rather low. All 14 case reports or clinical

Table 1a. Clinical studies on lipofilling to improve scar appearance

Reference	Study type	Study population	Intervention	Follow-up	Results	Complications
Balkin <i>et al.</i> (2014)	Retrospective, controlled	Patients with cleft lip repair ($n = 30$, 37 sides). Immediately treated.	Intervention: submucosal, subcutaneous, intra-muscular and periosteal lipofilling ($n = 20$). Control: no lipofilling treatment ($n = 10$). Intervention: subcutaneous lipofilling (2 interventions)	Photographic analysis by 3 independent observers using a visual 5-grade scale (mean follow-up of 24.7 months). Visual evaluation of the lower extremity.	Less cleft lip related deformity in overall facial, upper lip, nose and midface appearance in treated group.*	No complications reported
Benjamin <i>et al.</i> (2015)	Case-report	1 Patient with scarring of the lower extremity after trauma.	Intervention: subcutaneous lipofilling (2 interventions)	Visual evaluation of the lower extremity.	Patient noted improvement in mobility and appearance, less neuralgic pain.	No complications reported
Bollero <i>et al.</i> (2014)	Prospective, non-controlled, non-blinded, non-randomized	Patients with scars after trauma ($n = 19$).	Intervention: subcutaneous lipofilling (28 interventions)	Visual evaluation of photographs (pre-operative, 1 month and 3 months post-operative).	Among 28 interventions, 24 showed visual improvement in skin quality. 1 case showed improvement initially, but not after 3 months.	No complications reported
Bruno <i>et al.</i> (2013)	Prospective, controlled, non-blinded, non-randomized	Patients with burn wound scars ($n = 93$ scars). Mean scar age of 2.3 years.	Intervention: intra- and subcutaneous lipofilling ($n = 93$). Control: saline injection ($n = 93$).	Immunohistochemical analysis of scar biopsies, subjective evaluation using a questionnaire, photographic analysis by independent observers using the VSS (pre-operative, 3 months and 6 months post-operative).	After 6 months, a decrease in Langerhans cells and increase in P53 and Ki67.* No difference in P67 count. Improvements in VSS scores from 41 (pre-operative) to 15 (6 months post-operative) and questionnaire scores from 31 (pre-operative) to 95 (6 months post-operative) compared with untreated group.	Not mentioned
Byrne <i>et al.</i> (2016)	Retrospective, non-controlled	Patients with burn wounds scars of hand ($n = 13$). Mean scar age of 2.3 years.	Intervention: subdermal lipofilling	Aesthetic, functional and satisfaction scores were measured using a TAM (Goniometer), GSM (Dynamometer), DASH, MHQ and POSAS after 9.1 months (range 3 months–1.3 years).	The mobility improved*, but there was no grip strength and DASH improvement. A trend towards significant improvement in MHQ scores was noticed. A significant improvement in the POSAS scores was visible, except the scores for pain and itch.	No complications reported
Coleman (2006)	Case-report	1 patient with chronic acne scars.	Intervention: subdermal lipofilling	Visual evaluation of photographs (pre-operative, 11 months and 3 years and 7 months post-operative).	Visual improvement in skin quality.	Not mentioned
Guisantes <i>et al.</i> (2012)	Case-report	Patients with retractile and dystrophic scars ($n = 8$)	Intervention: intrascan lipofilling depending on treated area (11 interventions)	Photographic analysis by 2 independent observers using a visual 4-grade scale (mean follow-up of 18 months).	Improvement in skin quality, 5 cases obtained a score of 4, and 3 cases obtained a score of 3.	No complications reported
Klinger <i>et al.</i> (2008)	Case-report	Patients with scars as a result of hemifacial 2nd and 3rd degree burns ($n = 3$). Scar age of 2, 3 and 13 years.	Intervention: dermal-hypodermal junction lipofilling (2 interventions per patient)	Histological evaluation of scar biopsies and MRS (pre-operative, 13 months post-operative during operation, 2, 3 months post-operative).	Histological improvement: patterns of new collagen deposition and more dermal hyperplasia and neoangiogenesis. Presence of annexial structures is nearly normal. MRS revealed similar signal enhancement of soft tissue between affected and unaffected facial sides.	Not mentioned
Maione <i>et al.</i> (2014a)	Prospective, controlled, non-blinded, non-randomized	Patients with short-limb deformity syndrome presented	Intervention: subcutaneous lipofilling	A modified POSAS and durometer measurements to measure skin	Reduction of scar hardness after treatment*, while no	Not mentioned

Table 1 a. (Continued)

Reference	Study type	Study population	Intervention	Follow-up	Results	Complications
Mazzola <i>et al.</i> (2013)	Retrospective, non-controlled	retractile and painful scars (age > 1 year) caused by surgical procedures (<i>n</i> = 36).	Intervention: dermal-hypodermal junction lipofilling (<i>n</i> = 36). Control: saline injection (<i>n</i> = 36).	hardness were performed (pre-operative and 3 months post-operative).	significant reduction occurred in the control group. Reduction of all POSAS parameters, except itching in the treatment group.* No POSAS scores in control group reported.	No complications reported
Pallua <i>et al.</i> (2014)	Prospective, non-controlled, non-blinded, non-randomized	Patients who underwent tracheostomy healed by secondary intention resulting in a retracting scar (<i>n</i> = 11). Scar age of 4–10 years. Patients with facial scars of different causes (<i>n</i> = 35).	Intervention: lipofilling in the plane between skin and subcutaneous tissue. (2 interventions; interval of 6–12 months). Intervention: subcutaneous lipofilling	Evaluation of patient satisfaction (mean follow-up of 21.3 months). A POSAS, tissue oxygen saturation, haemoglobin levels and microcirculation (Doppler spectrometry) measurements performed (pre-operative, 1 month, 3 months, 6 months and 12 months follow-up).	Patients described functional and aesthetical improvement and were all satisfied. 2 cases with severe retraction needed 1 additional lipofilling procedure. Improvement in overall POSAS scores, both patient score as observer score.** Only 12 months scores mentioned. Early post-operative measurements revealed increased haemoglobin levels and reduced microcirculation, but both normalized after 7–90 days.	No complications reported No complications reported
Phulpin <i>et al.</i> (2009)	Retrospective, non-controlled	Patients with aesthetic subcutaneous or submucous head and neck reconstruction after radiotherapy (<i>n</i> = 11).	Intervention: deep and superficial subcutaneous lipofilling.	Aesthetic and functional scores were measured using a 5-grade scale (mean follow-up of 39.9 months).	Skin scoring tests revealed more softness, more pliability and improvement of skin quality of the irradiated skin. No scores mentioned.	No complications reported
Ribuffo <i>et al.</i> (2013)	Retrospective, controlled	Patients underwent MRM and IIBR + PMRT (<i>n</i> = 32). Lipofilling performed 6 weeks after PMRT.	Intervention: deep and superficial subcutaneous lipofilling (<i>n</i> = 16). Control: no lipofilling treatment (<i>n</i> = 16).	Capsular contracture was measured using Bakers' classification. Patients' satisfaction was evaluated using a 3-grade scale. (Mean follow-up of 18 months).	7 complications reported in the control group compared with none in the lipofilling group.* Higher capsular contracture rates in the control group compared with the lipofilling group. Patient satisfaction increased, but no scores were mentioned.	No complications reported
Sardesai <i>et al.</i> (2007)	Prospective, non-controlled, non-blinded, non-randomized	Patients with various scar types (<i>n</i> = 14). Scar age of > 1 year, 8.5 years on average.	Intervention: subcutaneous lipofilling	Dermal elasticity (Cutometer), vascularity and pigmentation (Derma- Spectrometer) measured. Patients' perception (POSAS) and observers' perceptions (POSAS and VSS) evaluated (pre-operative and 12–16 months post-operative).	Increase of dermal elasticity** and no difference in vascularization and pigmentation. Decrease of scar stiffness and thickness in patients' perception.** Less relief and pliability in observers' perception using a POSAS, pliability decrease was confirmed using a VSS.**No differences in vascularization and pigmentation (POSAS and VSS).	Not mentioned
Wang <i>et al.</i> (2013)	Retrospective, non-controlled	Patients with bilateral gluteal concave deformities associated with intragluteal injections (<i>n</i> = 12).	Intervention: deep, intermediate and superficial layer lipofilling of the gluteal	Effect of fat grafting on the skin was evaluated by severity of irregularity, quality of skin patterns and visual impact. Overall	9 cases scored 4–5 and 3 cases scored 3 on the satisfaction scale after treatment. Improvement in	1 case with cellulitis in the feet and calves

Table 1 a. (Continued)

Reference	Study type	Study population	Intervention	Follow-up	Results	Complications
Zellner <i>et al.</i> (2015)	Retrospective, controlled	Patients with cleft lip repair (n = 35, 44 sides). Immediately treated with lipofilling.	Intervention: submucosal, subcutaneous, intra-muscular and periosteal lipofilling (n = 19). Control: no lipofilling treatment (n = 16).	Satisfaction was evaluated using a 5-grade scale. (Follow-up of 3–44 months).	skin texture was observed in all cases. Softening of hypertrophic scars was observed, started 1 month post-operative and continued to 12 months post-operative. No pre-operative scores mentioned. Less cleft lip related deformity in overall facial, upper lip, nose and midface appearance (< 6 months) and in upper lip appearance (> 6 months). No significant improvement in cleft lip related deformity in the overall nose area (< 6 months) and overall facial and midface area (> 6 months).	Not mentioned

trials reported some degree of amelioration in scar appearance after lipofilling: in other words, scars became less different from normal skin and/or became less visible. However, the overall result of these clinical studies is not unequivocal. Firstly, not all studies use the same outcome measurements to report scar appearance: most studies used patient satisfaction or patient- and observer-rated grading scales for scar severity to report the effect of lipofilling, whereas other studies used measuring devices for skin elasticity or dermal pigmentation. Secondly, whether or not there is improvement in scar appearance varies within these studies: some studies report improvement in most patients, contrasted by no effect in a few other patients. Lastly, also, within the same study, improvement after lipofilling in one outcome measure (e.g. less stiffness of the scar) is reported, but there is no improvement in other outcome measures (e.g. no improvement in discoloration). Thus, the overall trend is that lipofilling improves scar appearance in several different outcome measures, which is confirmed by two systematic reviews (Conde-Green *et al.*, 2016; Negenborn *et al.*, 2016). However, due to lack of uniformity in intervention and follow-up, no definitive conclusions can be drawn.

Only five well-designed controlled studies had well-defined objectives and outcome parameters, and had included both non-treated (Balkin *et al.*, 2014; Ribuffo *et al.*, 2013; Zellner *et al.*, 2015) or placebo (Bruno *et al.*, 2013; Maione *et al.*, 2014a) controls. Four of these studies focused on clinical outcomes (Balkin *et al.*, 2014; Maione *et al.*, 2014a; Ribuffo *et al.*, 2013; Zellner *et al.*, 2015) and are discussed below, and one addresses histological changes (Bruno *et al.*, 2013) and is discussed in the next section.

In two studies, performed under supervision of the same senior researcher (Balkin *et al.*, 2014; Zellner *et al.*, 2015), the effect of lipofilling as adjuvant procedure to reduce formation of new scars after surgery is evaluated. During primary cleft lip repair surgery, efficacy of lipofilling is examined by comparison of pre- and post-operative pictures for residual cleft stigmata by a blinded reviewer panel. Compared with primary cleft lip repair without lipofilling, it resulted in significantly less residual cleft stigmata and thus in better scar appearance. Apparently lipofilling led to reduction of scar formation. Also, already existing scars can be treated by means of lipofilling: in prosthetic breast reconstruction in the setting of post-mastectomy radiotherapy, post-radiotherapy lipofilling can reduce the degree of capsular contracture as measured by the Baker classification (Ribuffo *et al.*, 2013). Here, lipofilling apparently is able to prevent or even (partially) revert the fibrotic process of capsular contracture. Another example is the treatment of post-surgical scars in patients with achondroplasia that require surgical limb lengthening (Maione *et al.*, 2014a). In this study, lipofilling was compared with saline injection: lipofilling significantly increased skin pliability, and all but one parameter of the patient and observer scar assessment scale improved. Thus, lipofilling apparently improves the appearance of existing scars.

3.1.2. Pain reduction

Efficacy of lipofilling as a means for pain reduction was investigated in six case reports or studies (Caviggioli *et al.*, 2011; Huang *et al.*, 2015a; Klinger *et al.*, 2013; Maione *et al.*, 2014b; Panettiere *et al.*, 2009; Rigotti *et al.*, 2007; Ulrich *et al.*, 2012; Table 1b). No complications were recorded in six of seven studies with a total of 204 patients; one study did not mention any complications. All studies reported a significant reduction of pain after treatment of painful scars: only in two of these studies there was no difference found in one (Rigotti *et al.*, 2007) and in two (Huang *et al.*, 2015a) patients out of the entire population. Three studies included control groups, where lipofilling was compared with no treatment (Caviggioli *et al.*, 2011; Maione *et al.*, 2014b; Panettiere *et al.*, 2009). Two of these studies, performed at the same institute, focused on lipofilling as treatment for neuropathic pain after total mastectomy (Caviggioli *et al.*, 2011) or breast-conserving surgery (Maione *et al.*, 2014b). In both studies, it was shown that lipofilling can reduce pain as measured on a visual analogue scale by approximately 3 points in the lipofilling group, compared with about 1 point in the control group. The third study compared results with a representative patient cohort: women who have undergone breast reconstruction and irradiation after mastectomy (Panettiere *et al.*, 2009). In the lipofilling group there was a significant improvement of all parameters of the LENT-SOMA classification (pain, telangiectasias, breast oedema, atrophy and fibrosis) after treatment. For unknown reasons, the authors did not compare and analyse the treatment group with a control group, but they still concluded that lipofilling leads to pain relief as well as amelioration of scar appearance.

3.2. Influence of lipofilling in scars at the tissue level

Microscopically, scars display a loss of rete ridges, sebaceous glands and hair follicles. Also, they are characterized by increased dermal and epidermal thickness (Beausang *et al.*, 1998; Ehrlich *et al.*, 1994). The epidermal thickening is caused by excessive proliferation of keratinocytes. In the dermis, the thickening is caused by excessive extracellular matrix (ECM) production by myofibroblasts, mainly consisting of collagen type I (van der Veer *et al.*, 2009). Not only is there an increase in the amount of collagens, but also in the collagen fibre thickness, maturation and degree of disorganization (Beausang *et al.*, 1998; Ehrlich *et al.*, 1994). Even though there is an increase in the amount of ECM in scarring, some components of normal skin (e.g. elastin, decorin) are less abundant in scars (Niessen *et al.*, 1999).

In two patient studies, skin biopsies have been acquired before and after treatment of scars with lipofilling (Bruno *et al.*, 2013; Klinger *et al.*, 2008), one study evaluating a complete series of biopsies from a single patient (Klinger *et al.*, 2008). After lipofilling, the general structure of

the skin improved, collagen was remodelled and there was an increase in vascularization.

In a large, placebo-controlled study, lipofilling in large burn scars was compared with saline injection (Bruno *et al.*, 2013). In 96 patients, half of the scar was injected with saline (placebo- or sham-treated group), the other half was injected with lipoaspirate. Skin biopsies were taken and analysed after 3 and 6 months. Overall, the histological structure of the scars returned near to that of normal skin: a better organization and alignment of collagen fibrils, better vascularization of the dermal papillae, less melanocytic activity in the epidermis and an increase of the amount of elastin fibres. On cellular level, there was an increase in cell divisions in the basal layer of the epidermis and Langerhans cells migrated downwards into this basal layer. Also, levels of pro-fibrotic factor transforming growth factor beta 1 (TGF- β 1) and pro-angiogenic factors vascular endothelial growth factor (VEGF) decreased.

In summary, histological improvement in scar appearance was noted in both studies, expressed as a plethora of changes on both histological as well as cellular level. However, why and how lipofilling results in the improvement of all these aforementioned aspects of scarring, including pain reduction, remains to be elucidated.

3.3. Animal studies

In contrast to clinical studies thus far, experimental animal models have been able to demonstrate the mechanisms and influence of lipofilling on dermal scars, scar exterior and scar pain (Table 2a).

Scar histology has been investigated in two studies using irradiation skin damage models in rodents (Garza *et al.*, 2014; Sultan *et al.*, 2011; Table 2a). Skin fibrosis after radiation in general is a clinically relevant problem, which can easily be reproduced in rodents. After radiation, dermatitis develops, which eventually gives rise to fibrotic skin characterized by epidermal thickening and irregular deposition of collagen in the dermis. Also, compared with normal skin, irradiated skin areas have an increased vessel density. In two studies in mice, it has been shown that treatment with lipofilling can reduce all these hallmark features of radiation-damaged skin (Garza *et al.*, 2014; Sultan *et al.*, 2011). A decrease in SMAD3 protein levels, a key protein in the pro-fibrotic pathway TGF- β /Smad signal transduction pathway, partly explains the mechanism of scar improvement (Sultan *et al.*, 2011). In a slightly different model in mice with full thickness burn wounds, it has been shown that lipofilling leads to better scar appearance by increasing pro-angiogenic factors VEGF and stromal cell-derived factor 1 (SDF-1) and decreasing pro-fibrotic factor TGF- β 1 (Sultan *et al.*, 2012).

Reduction of neuropathic pain has been reported in two studies of Huang and co-workers (Huang *et al.*, 2014, 2015b; Table 2b). Allodynia, painful perception of a normally non-painful stimulus, after burn wound injury

Table 1b. Clinical studies on lipofilling to reduce pain

Reference	Study type	Study population	Intervention	Follow-up	Results	Complications
Cavaggioli <i>et al.</i> (2011)	Retrospective, controlled	Patients with severe scar retraction and PMPS after mastectomy with axillary dissection and radiotherapy (<i>n</i> = 113).	Intervention: dermal-hypodermal junction lipofilling (<i>n</i> = 72). Control: no lipofilling treatment (<i>n</i> = 41).	Pain evaluation using a VAS (mean follow-up of 13 months).	Decrease of pain in treated group compared with untreated group.**	No complications reported
Huang <i>et al.</i> (2015a)	Prospective, non-controlled, non-blinded, non-randomized	Patients with painful neuropathic scars with persistent symptoms (<i>n</i> = 13); (range 3 months–13 months).	Intervention: dermal-hypodermal junction and subcutaneous lipofilling.	Pain evaluation using VAS and NPSI scores (pre-operative, 1 week, 4 weeks and 24 weeks post-operative).	Decrease of VAS and VSS scores after 1, 4 and 24 weeks compared with pre-operative scores.** No other comparisons between post-operative measurements performed. No effect in 2 cases.	No complications reported
Klinger <i>et al.</i> (2013)	Retrospective, semi-controlled non-blinded, non-randomized	Patients with retractile and painful scars compromising daily activity (<i>n</i> = 20). Scar age of > 2 years.	Intervention: dermo-hypodermic junction lipofilling. Control: saline injection.	Pain and skin quality of the scar was evaluated using the POSAS questionnaire (without control group). Scar hardness was measured using the durometer (with control group). Both after 3 months.	All POSAS scores (patient and observer scores) decreased significantly except for itching. Scars hardness decreased post-operative compared with pre-operative in the treated group.* No significant decrease of scar hardness.	No complications mentioned
Maione <i>et al.</i> (2014b)	Prospective, controlled, non-blinded, non-randomized	Patients with PMPS after lumpectomy and radiotherapy (<i>n</i> = 96). Lipofilling performed > 1 year after radiotherapy.	Intervention: dermal-hypodermal junction lipofilling (<i>n</i> = 59). Control: no lipofilling treatment (<i>n</i> = 37).	Evaluation of spontaneous pain using a VAS (pre-operative and 1 year post-operative).	A mean decrease of pain of 3.1 in the treated group and 0.9 in the control group. More decrease of pain in the treated group compared with the control group.**	No complications reported
Panetiere <i>et al.</i> (2009)	Prospective, controlled, non-blinded, non-randomized	Patients with irradiated reconstructed breasts after mastectomy for carcinomas (<i>n</i> = 61, 62 breasts).	Intervention: subscar lipofilling (serial interventions until patient was satisfied or result was stable; <i>n</i> = 20). Control: no lipofilling treatment (<i>n</i> = 41).	Functional results were evaluated using the LENT-SOMA scoring system, 3 months after the last treatment. Aesthetic results were evaluated using a 5-grade scale.	Scores for pain, telangiectasia, breast oedema, atrophy and fibrosis decreased in the intervention group after 3 months.** No significant difference for above mentioned scores compared with the control group after 3 months. Aesthetic outcome improved in the intervention group compared with the control group.*	No significant complications reported
Rigotti <i>et al.</i> (2007)	Prospective, non-controlled, non-blinded, non-randomized	Patients with side-effects of radiotherapy with severe symptoms and irreversible function damage (LENT-SOMA scale grade 3 and 4; <i>n</i> = 20). Scar age 1–30 years.	Intervention: purified lipofilling.	LENT-SOMA grading scale scores evaluation (mean follow-up of 30 months).	Reduction of LENT-SOMA grading scale scores.** Improvement observed in all patients, except 1 case.	No complications reported
Ulrich <i>et al.</i> (2012)	Prospective, non-controlled, non-blinded, non-randomized	Patients with painful episiotomy scars was 10.3 months.	Intervention: subscar lipofilling.	Perineal pain evaluation using a MGPO, a PPI and VAS. The SSSRS was used to evaluate the sexual satisfaction of the patients (pre-operative, 1, 3 and 6 months).	Reduction of pain after 1, 3 and 6 months in all pain questionnaires.* Improvement in sexual satisfaction after 1, 3 and 6 months.* No comparison performed between post-operative time points.	No major complications reported

Abbreviations: VSS = Vancouver scar scale, TAM = total active movement, GSM = grip strength measurement, DASH = the disabilities of the arm, shoulder and hand, WHQ = Michigan hand outcome questionnaire, POSAS = patient and observer scar assessment scale, MRS = magnetic resonance scan, MIRM = modified radical mastectomy, IIBR = immediate implant-based reconstruction, PMRT = post-mastectomy radiotherapy, PMPS = post-mastectomy pain syndrome, VAS = visual analogue scale, NPSI = neuropathic pain symptom inventory, MGPO = McGill pain questionnaire, PPI = present pain intensity index, SSSRS = Sabbatsberg sexual self-rating scale

*Significant difference ($P < 0.05$).

**Significant difference ($P < 0.001$).

Table 2a. Animal studies on lipofilling to improve scar appearance

Reference	Animal model	Intervention	Follow up	Results
Garza <i>et al.</i> (2014)	Mouse Radiation of scalp skin	Treatment: lipofilling (human adipose tissue) 4 weeks after irradiation. Control: no lipofilling and/or no radiation.	Histology of skin for epidermal thickness (H&E), collagen arrangement (picosirius red) and vessel density (CD31). CT for fat graft retention. Histology of fat graft. Assessments 2 and/or 8 weeks after lipofilling.	Return of dermal thickness to normal level. Decrease in collagen level to normal level. Increase of vascular density. All for irradiated skin treated with lipofilling, compared with non-treated irradiated skin. Less fat graft retention in irradiated group compared with non-irradiated group.
Sultan <i>et al.</i> (2011)	Mouse Full thickness burn wound on dorsum	Treatment: lipofilling (human adipose tissue) 2 weeks after injury. Control: saline injection	Blood flow measurement by Laser-Doppler. Photographs. Histology for collagen arrangement (picosirius red) and vessel density (CD31). Gene and protein expression analysis of skin. Assessment 4 and/or 8 weeks after lipofilling.	Improvement in colour and texture of wound area. Increased blood flow in wound area at 4 but not at 8 weeks. Increase in pro-angiogenic proteins and decrease of pro-fibrotic proteins. Increased vessel density at 4 weeks. Better collagen alignment at 8 week. All for lipofilling vs. control group.
Sultan <i>et al.</i> (2011)	Mouse Radiation of dorsum skin	Treatment: lipofilling (human adipose tissue) 4 weeks after irradiation. Control: saline injection and/or no irradiation	Photographs. Histology for epidermal thickness (H&E), collagen arrangement (picosirius red), vessel density (CD31) and pro-fibrotic marker (Smad3). All at 4 and/or 8 weeks after lipofilling.	Decrease in radiation ulcer size and less hyperpigmentation. Less epidermal thickening. Normalization of vascular density. Decrease in amount of Smad3 (activation not measured). All outcomes for lipofilling-treated irradiated animals compared with saline-treated irradiated animals.

Table 2b. Animal studies on lipofilling to reduce pain

Reference	Animal model	Intervention	Follow up	Results
Huang <i>et al.</i> (2014)	Rat Full thickness burn wound of hind paw	Treatment: lipofilling (rat adipose tissue) 4 weeks after injury. Controls: saline injection or no treatment, and/or sham burn wound.	Behavioural testing for neuropathic pain: paw withdrawal test with mechanical and heat stimuli. Histology of hind paw skin (H&E, MTC) and of spinal cord (microglial activation). All at 4 weeks after lipofilling.	Reduction of burn-induced allodynia. Improvement of skin histology in burn wound treated with lipofilling: decrease in collagen deposition, increased cellularity. Less microglial activation in spinal cord. All observations for burn wounds treated with lipofilling, compared with saline injection.
Huang <i>et al.</i> (2015b)	Rat Full thickness burn wound of hind paw	Treatment: lipofilling (rat adipose tissue) 4 weeks after injury. Controls: saline injection and/or sham burn wound	Behavioural testing for neuropathic pain: paw withdrawal tests. Assessment of inflammatory markers in hind paw skin (COX-2, iNOS, nNOS) and spinal cord (IL-1 β , TNF α , p-IkB and p-NFkB). All at 4 weeks lipofilling.	Reduction of burn-induced allodynia. Decrease of inflammatory markers in hind paw skin and in spinal cord. Decrease in inflammatory pathway activation (p-IkB and p-NFkB) and in pro-apoptotic pathway activation (p-JNK) in spinal cord. All for burn wounds treated with lipofilling, compared with saline injection.

Abbreviations: H&E = haematoxylin and eosin, MTC = Masson's trichrome, IL-1 β = interleukin 1 beta, COX-2 = cyclo-oxygenase 2, TNF α = tumour necrosis factor alpha, CD31 = cluster of differentiation 31, iNOS = inducible nitric oxide synthase, nNOS = neuronal nitric oxide synthase.

was tested in rats by means of behavioural testing. After burn injury, lipofilling reduced burn-induced allodynia. On the one hand, lipofilling reduces skin fibrosis and scarring after burn injury (Huang *et al.*, 2014, 2015b) and lowers expression of pro-inflammatory mediators in the skin (Huang *et al.*, 2015b). On the other hand, lipofilling induces changes in the spinal cord as well decreases microglial activation and lessens activation of the pro-inflammatory NFkB signal transduction pathway in spinal cord cells (Huang *et al.*, 2015b).

It can be concluded that lipofilling in rodent models for skin injury and fibrosis reduces adverse fibrotic changes. This appears to be mediated by factors from the lipograft that can inhibit activation of both fibrotic and inflammatory signal transduction pathways. All changes caused by lipofilling in a dermal scar have been drawn schematically in Figure 1.

4. Therapeutic mode of action of ADSC

4.1. ADSC: stem or stromal cells?

Because of their ability to differentiate into different cell types, ADSC are sometimes referred to as adipose stem cells. However, a true stem cell has the potential to differentiate into other cell types, while maintaining a stable population of stem cells by the process of self-renewal (Vogel *et al.*, 1968) with indefinite proliferation capability due to telomerase activity (Lansdorp, 1995). Embryonic stem cells are an example of such pluripotent stem cells: they can undergo an infinite number of cell divisions and can differentiate into all cell types of the three germ layers during embryonic development (Thomson *et al.*, 1998). ADSC, on the other hand, are a type of adult stem cell that have no telomerase activity and therefore have a limited

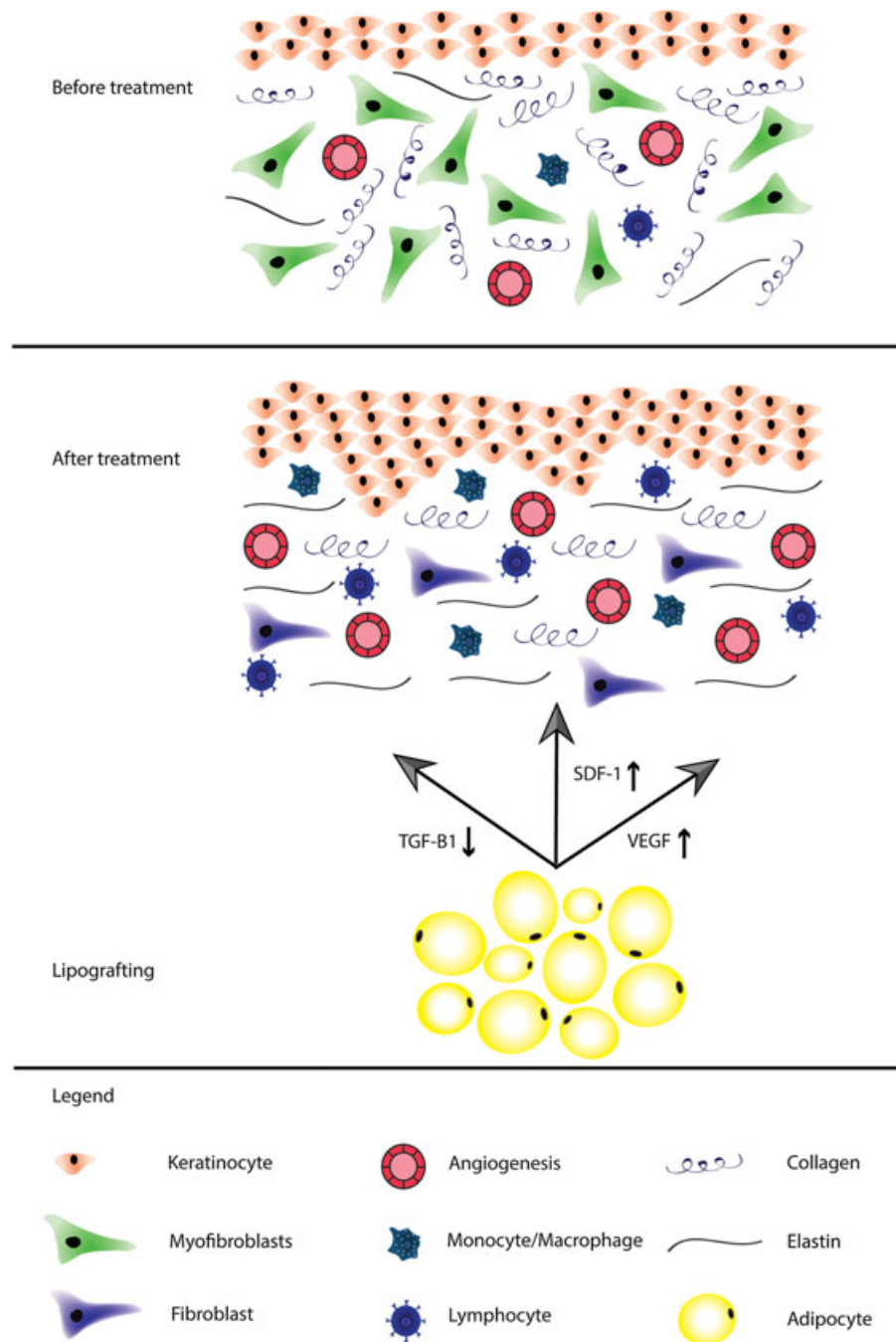


Figure 1. Schematic overview of dermal scar on tissue level, before and after treatment with lipofilling. [Colour figure can be viewed at wileyonlinelibrary.com]

capacity of proliferation (Mizuno *et al.*, 2012). ADSC can only differentiate into a limited number of cell types, which makes them multipotent progenitor cells. Hence, in the case of ADSC, the authors prefer to speak of adipose-derived stromal cells instead of adipose-derived stem cells.

4.2. Isolation

Adipose-derived stem or stromal cells can be isolated either from intact adipose tissue or from lipoaspirates. The adipose tissue or lipoaspirate is subjected to enzymatic digestion using proteases such as collagenase, dispase or

trypsin (Bourin *et al.*, 2013; Pittenger *et al.*, 1999; Yoshimura *et al.*, 2006; Zuk *et al.*, 2001). After digestion, the stromal vascular fraction (SVF) that contains ADSC as well as several other cell types is separated from the mature adipocytes by differential or density gradient centrifugation (Bourin *et al.*, 2013; Pittenger *et al.*, 1999; Yoshimura *et al.*, 2006; Zuk *et al.*, 2001). For cell culture, the SVF is then seeded into cell culture dishes. Only ADSC adhere to the tissue culture plastic, whereas other, non-adherent cell types such as erythrocytes, endothelial cells and immune cells are removed by washing (Bourin *et al.*, 2013). Then, the remaining ADSC are culture-expanded or cryopreserved until further use.

4.3. ADSC *in vivo* vs. *in vitro*

Adipose tissue contains two major components: SVF and adipocytes. SVF is a heterogeneous mix of cells of 11 main subpopulations based on CD-surface marker expression: seven adipose-derived populations (CD45⁻) and four blood-derived populations (CD45^{POS}; Yoshimura *et al.*, 2006). Three important subpopulations of CD45^{min} cells are pericytes [*in vivo*: (CD34^{POS})/CD34^{min}/CD146^{POS}/CD31^{min}], supra adventitial cells (*in vivo*: CD34^{POS}/CD146^{min}/CD31^{min}) and ADSC (*in vivo*: CD34^{POS}/CD90^{POS}/CD31^{min}/CD105^{low}) in a very low number (Corselli *et al.*, 2012, 2013; Yoshimura *et al.*, 2006; Zimmerlin *et al.*, 2010). Pericytes and supra-adventitial cells are both identified as precursor cells of ADSC, but there remains controversy (Corselli *et al.*, 2012; Lin *et al.*, 2008; Traktuev *et al.*, 2008; Zimmerlin *et al.*, 2010).

Enzymatic isolation and culture of those precursor cells or ADSC results in a large series of cells that can be used in regenerative medicine. After several days of culture, the *in vivo* phenotype of precursor cells changes into an *in vitro* specific phenotype. Most of the cells will lose their CD34 expression, and almost all of the cells gain expression of CD105 (Corselli *et al.*, 2012; Yoshimura *et al.*, 2006). The CD105 marker is also known as endoglin and is a TGF- β type III receptor, which is expressed on virtually all cells of mesenchymal origin, but also on for example endothelial cells. Ten–20% of the subpopulations remain CD34^{POS}, but their proliferation rate and adipogenic differentiation ability is significantly lower as compared with the CD34^{min} subpopulation (Yoshimura *et al.*, 2006; Zimmerlin *et al.*, 2010). This suggests that 80–90% of the so-called ADSC, characterized by their phenotype *in vitro* (CD34^{min}/CD105^{POS}), are not present *in vivo*: in other words, the majority of ADSC acquire their phenotype through culturing. Culturing of ADSC also causes dramatic shifts in secretome, as will be discussed within a few sentences below. The different components and cell types of all fractions of adipose tissue are summarized in Figure 2.

Some studies have described that regenerative potencies of ADSC are caused by secretion of trophic factors or differentiation into other cells (Yang *et al.*, 2013). *In vivo*, little is known about the secretion of trophic factors by ADSC. *In vitro*, secretion of trophic factors by ADSC in medium (called ADSC conditioned medium) is affected by many aspects: differences in culture conditions, donors, methods and medium, and cell counts results in different expression of growth factors. For instance, hypoxia culture upregulates VEGF, platelet-derived growth factor, placental growth factor and insulin-like growth factor II (Pawitan, 2014). A 3D culture structure results in thousands of genes with a significantly higher mRNA expression related to ECM, cell adhesion, wound healing and growth factors as compared with a 2D structure (Amos *et al.*, 2010). Concentrations of proteins related to angiogenesis, ECM remodelling and regeneration increase as well (Amos *et al.*, 2010).

The regenerative potency of SVF might be caused by the interaction between cells and growth factors. For

example, angiogenesis is significantly greater when pericytes and endothelial cells are combined rather than the use of pericytes or endothelial cells alone (Traktuev *et al.*, 2009). Growth factors like VEGF, hepatocyte growth factor, TGF- β and ECM stimulate angiogenesis (Rehman *et al.*, 2004). ECM influences morphogenesis, and migration speed depends on ECM density during angiogenesis (Bauer *et al.*, 2009). Furthermore, ECM functions as a scaffold for other cell types at the site of injection. The interaction of cellular integrins, i.e. matrix receptors, suppresses pro-apoptotic signalling. Thus, applications that include intact, non-enzymatic, generated SVF might favour graft survival. However, only mechanical isolation of SVF preserves ECM, while enzymatic isolation of SVF disrupts all communicative connections between cells. As compared with cultured ADSC and *in vitro* studied growth factors, freshly isolated SVF contain cells with their *in vivo* phenotype and growth factor secretion, respectively. As compared with lipofilling, the use of SVF might avoid possible complications like cyst formation or overfilling (Agostini *et al.*, 2014), because only small volumes (less than 10 ml) of SVF are injected. Thus, because injected volume is limited, there is no risk of overfilling. Because no adipocytes are injected, there is also no risk of oily cyst formation.

5. ADSC as an anti-scarring treatment

5.1. Clinical studies

To date, the use of ADSC as a cell therapy for treatment for fibrosis has not been thoroughly investigated in clinical studies. ADSC have been applied in two non-controlled, non-randomized studies investigating the effect of ADSC-enriched lipografts on healing of chronic, intractable radiation ulcers in 10 patients (Akita *et al.*, 2012) and for correction of soft tissue defects in 29 patients (Tiryaki *et al.*, 2011). It was concluded that ADSC improve wound healing (Akita *et al.*, 2012) and fat graft take (Tiryaki *et al.*, 2011), and concomitantly decrease deep tissue fibrosis and dermal scarring. However, fundamentally, there is ample evidence for these effects: ADSC increase angiogenesis, can induce mitosis in resident tissue cells and are able to remodel ECM. Based on the design of both studies, no definitive conclusions can be drawn on the effectiveness of the use of ADSC as scar treatment.

On the other hand, studies in the field of cell-assisted lipotransfer (CAL), where lipografts are combined with ADSC in order to improve fat graft survival, have been several properly designed, controlled clinical trials (Kolle *et al.*, 2013; Peltoniemi *et al.*, 2013; Tanikawa *et al.*, 2013) to demonstrate the efficacy of CAL for improvement of lipograft survival over lipofilling alone. In these studies no serious adverse events were reported after injection of autologous freshly isolated (Peltoniemi *et al.*, 2013; Tanikawa *et al.*, 2013) or culture expanded (Kolle *et al.*, 2013) ADSC. It can be concluded that use of autologous ADSC in patients is safe. These clinical trials warrant the dissection of the

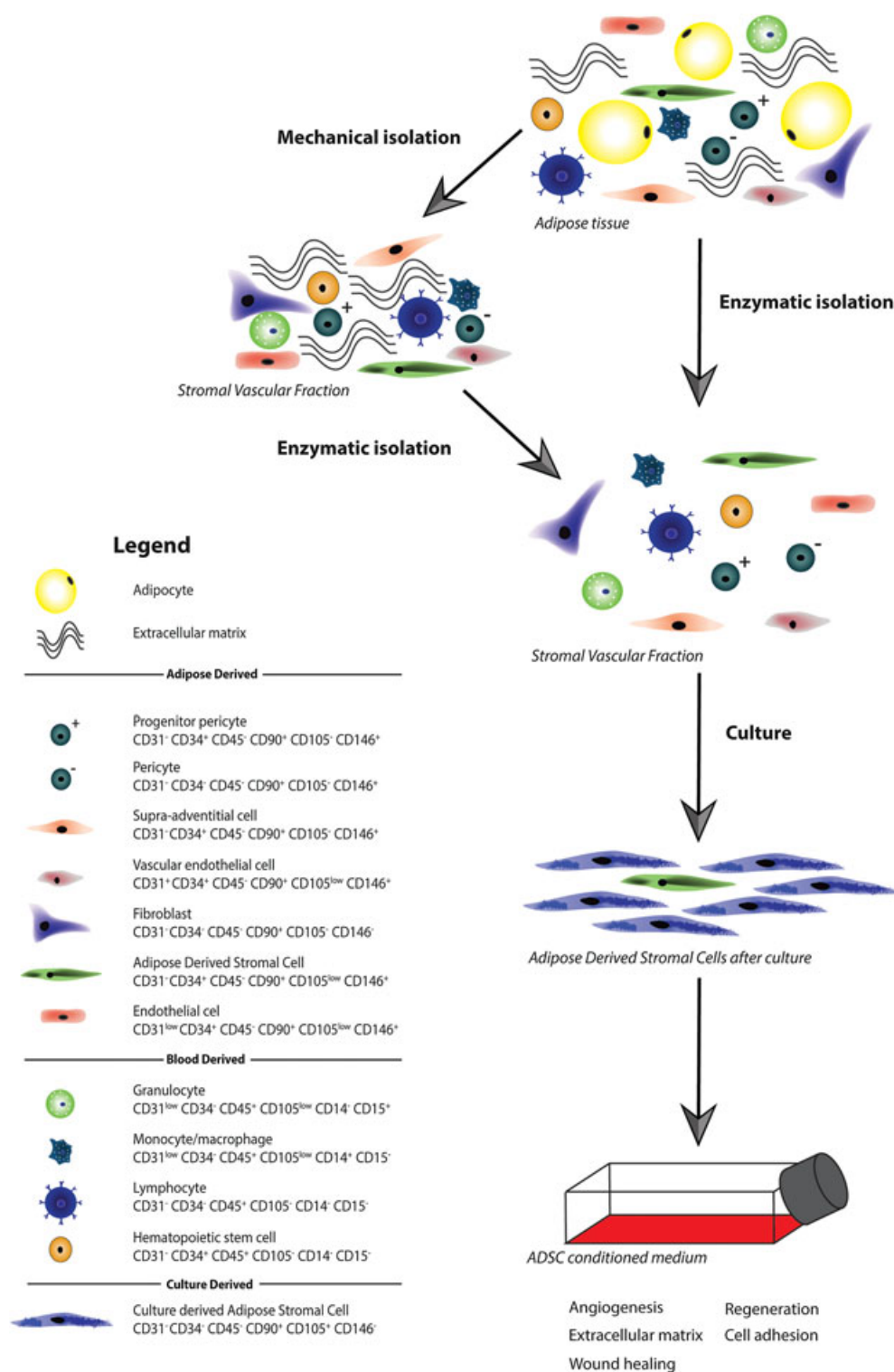


Figure 2. Summary of different fractions of adipose tissue before, during and after mechanical or enzymatic isolation of adipose-derived stem or stromal cells (ADSC). Cell types and their cell surface markers are represented for all different fractions. [Colour figure can be viewed at wileyonlinelibrary.com]

underlying mechanism via animal models and *in vitro* investigations of underlying molecular pathways.

5.2. Animal studies

In animal wound-healing models, where ADSC were used to speed up wound healing (Lam *et al.*, 2013; Lee *et al.*,

2011; Uysal *et al.*, 2014; Zonari *et al.*, 2015), it was observed that ADSC reduce severity of scarring after wound closure (Table 5). ADSC improved the wound healing rate in three out of four studies, and smaller fibrotic areas remained after wound healing (Lam *et al.*, 2013). Yet, the epidermal thickness increased (Uysal *et al.*, 2014; Zonari *et al.*, 2015), and the gene expression of the pro-fibrotic markers α -smooth muscle actin and TGF- β 1

Table 5. Animal studies on ADSC as a treatment for wound healing and scar prevention or reduction

Reference	Animal model	Biomaterial	Intervention	Follow up	Results
Castiglione <i>et al.</i> (2013)	Rat Peyronie's disease (TGF- β 1 induced)	No	1×10^6 labelled human ADSC Control: PB Local injection	Protein expression and histomorphometric analysis of the penis. Erectile function measurements 5 weeks after ADSC-treatment.	Decrease in collagen III and elastin deposition (immunofluorescence). Improved erectile function. Both in ADSC-treated vs. control group.
Lam <i>et al.</i> (2013)	MouseSplinted excisional wound healing model	Small intestinal submucosa (SIS)	1×10^6 mouse ADSC on SIS patch Control: patch alone or Topical application of ADSC	Wound healing speed, fibrosis (H&E and MTC staining) after wound healing. Measured at day 14 after wounding.	Wound healing improved slightly with ADSC on SIS. Decreased fibrotic area with topical ADSC and with ADSC on SIS Both compared ADSC on SIS with untreated or SIS alone.
Lee <i>et al.</i> (2011)	Nude mouseSplinted excisional wound healing model	Collagen gel	1×10^6 human ADSC in collagen gel Control: human dermal fibroblast in collagen gel, or collagen gel alone	Photographs of wound area size 10 days after wounding. Scar size 28 days after wounding (H&E staining).	ADSC collagen gel group had a faster wound closure rate than control, but slower than DF collagen gels. Scar size increased in ADSC and DF collagen gel groups compared with control (based on H&E staining alone).
Uysal <i>et al.</i> (2014)	RatFull excisional wound thickness	No	1×10^7 labelled rat ADSC Control: 1×10^7 rat BMSC or PBS Local injection	Wound healing speed. Histology for neovascularization, epithelial thickness (both H&E). Immunostaining for cytokeratin, α SMA, FGF, VEGF, TGF- β 1, β 2 and β 3. All at day 56 after wounding.	Increased wound healing speed, neovascularization and epithelial thickness. Lower α SMA, TGF- β 1, β 2 and β 3 and higher FGF and VEGF expression. All outcomes for ADSC and BMSC treated groups vs. control group
Yun <i>et al.</i> (2012)	PigScarring model, after full thickness wound	No	1×10^6 labelled human ADSC Control: PBS Three consecutive local injections	Area, colour and flexibility of scar. Histological assessment of collagen arrangement (MTC), number of mast cells. Gene expression analysis of scar tissue. All until 50 days after ADSC injection.	Slightly smaller scar area and slightly higher pliability. Higher amount of mature collagen. Lower mast cell count. Lower gene expression of α SMA and TIMP1, higher expression of MMP1. All outcomes for ADSC treated group vs. control group.
Zhang <i>et al.</i> (2015)	RabbitHypertrophic scar model, after full thickness wound	No	4×10^6 labelled rabbit ADSC Control: ADSC CM, culture medium, or untreated. Local injection	Histology for scar size and collagen arrangement (H&E and MTC). Gene expression analysis of scar tissue. All until 35 days after ADSC injection.	Less scar elevation. Less deposition and better alignment of collagen. Lower gene expression of α SMA and collagen I. All outcomes for ADSC or ADSC CM treated groups vs. culture medium or untreated groups.
Zonari <i>et al.</i> (2015)	RatFull excisional wound thickness	PHBV scaffold	1×10^6 labelled rat ADSC in PHBV scaffold Control: PHBV scaffold or untreated	Wound healing speed, skin thickness (H&E), vessel density, collagen arrangement (MTC) and gene expression analysis. All until 28 days after wounding.	No difference in wound-healing speed. Improved skin thickness and collagen fibre organization. Lower α SMA and TGF- β 1, higher TGF- β 3 gene expression. No difference in vessel density at 28 days. All these outcomes for ADSC in scaffold vs. scaffold alone.

Abbreviations: ADSC = adipose-derived stem/stromal cell, SIS = small intestinal submucosa, H&E = haematoxylin and eosin, MTC = Masson's trichrome, DF = dermal fibroblast, α SMA = alpha smooth muscle actin, FGF = fibroblast growth factor, VEGF = vascular endothelial growth factor, TGF- β = transforming growth factor beta, BMSC = bone marrow mesenchymal stem/stromal cell, PBS = phosphate-buffered saline, TIMP1 = tissue inhibitor of metalloproteinase, MMP = matrix metalloproteinase, ADSC CM = ADSC conditioned medium, PHBV = polyhydroxybutyrate-co-hydroxyvalerate.

decreased (Uysal *et al.*, 2014; Zonari *et al.*, 2015) while the gene expression of anti-fibrotic fibroblast growth factor and pro-angiogenic VEGF (Uysal *et al.*, 2014) increased. Together, this indicates that *in vivo* administered ADSC suppress the formation of dermal scar, through augmented wound healing. The comparison with clinical treatment of pre-existing scars is hampered, because these animal studies more prevent scar formation than revert pre-existing scars.

In animal models specifically designed to study scarring (Yun *et al.*, 2012; Zhang *et al.*, 2015) and to study the fibrotic disorder of Peyronie's disease (Castiglione *et al.*, 2013; Table 5), it was noted that deposition of ECM components, such as collagen type I and III and elastin, was decreased after treatment of scars with ADSC. Also, collagen fibre alignment improved in the treated scar areas (Yun *et al.*, 2012; Zhang *et al.*, 2015). Functionally, treatment of scars with ADSC leads to smaller scars (Yun *et al.*, 2012) and less scar

elevation (Yun *et al.*, 2012). Together, we surmise that the remodelling of the fibrotic matrix in a scar by ADSC is one of the components that governs scar reduction. Interestingly, ADSC are derived from connective tissue (SVF of fat), but appear to act as 'good guys' in contrast to the scar myofibroblasts, which are connective tissue cells too, but 'bad guys'. The ADSC are capable of tilting the balance between ECM deposition and ECM degradation in favour of degradation. Whether this depends solely on matrix influence or also on direct influence on the scar-resident myofibroblast remains to be investigated.

In conclusion, treatment of wounds or mature scars with ADSC in different animal models has shown to result in faster wound healing and reduction of scar tissue on both macroscopic and microscopic levels. Thus, the use of autologous ADSC to improve wound healing and to prevent or diminish scar tissue in patients seems to be a very exciting and promising way to go.

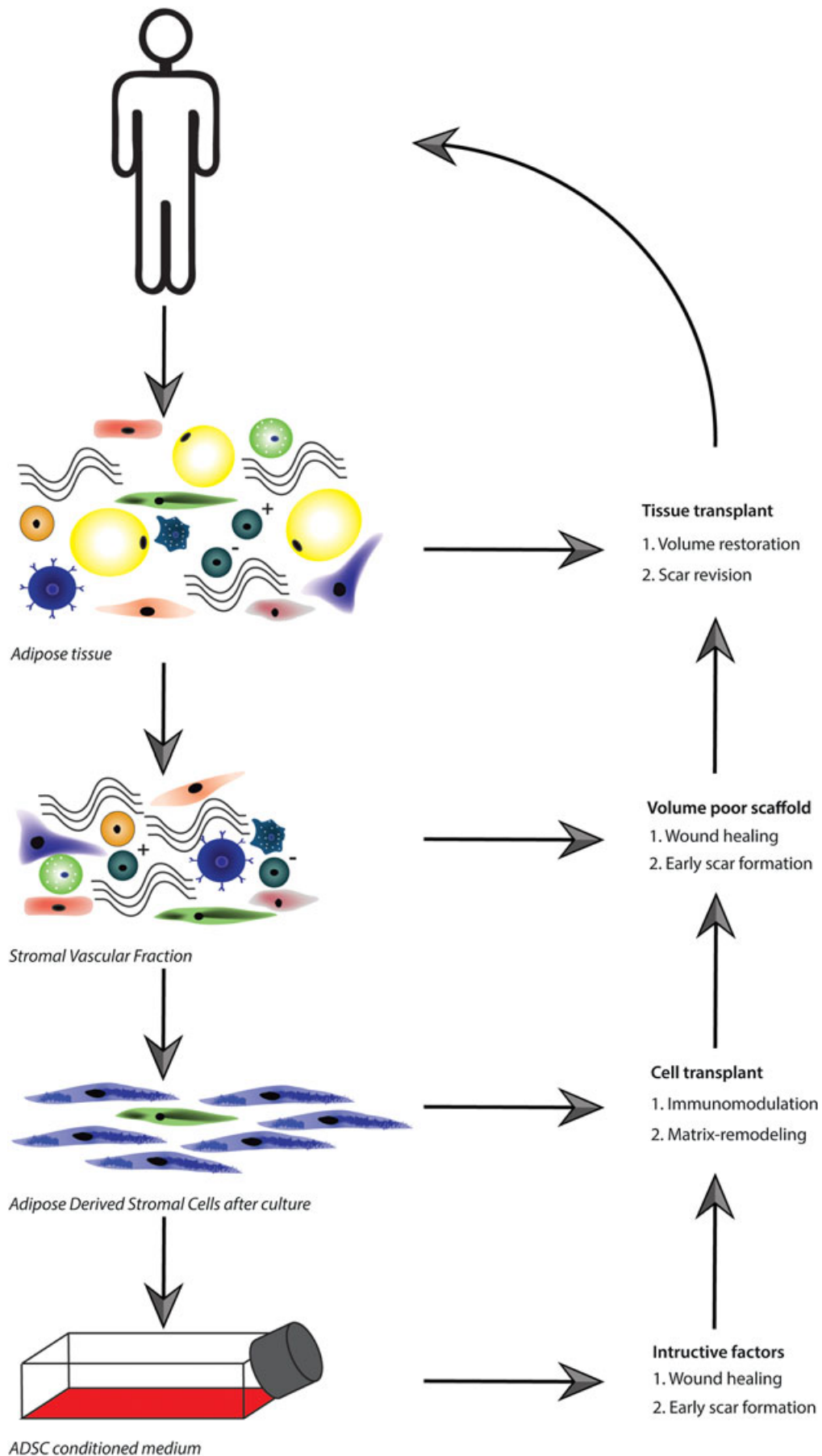


Figure 3. Harnessing the power of fat for fibrotic scar treatment: as whole adipose tissue in lipofilling, or in loose components such as stromal vascular fraction (SVF), adipose-derived stem or stromal cells (ADSC) or ADSC conditioned medium. As listed, we propose each form has its own ideal application. [Colour figure can be viewed at wileyonlinelibrary.com]

5.3. *In vitro* studies

Myofibroblasts play a major role in wound healing and scarring: activated myofibroblasts proliferate, produce ECM-like collagens and have the ability to contract. After wound healing, myofibroblasts normally are resolved via apoptosis. However, if myofibroblasts persist, scarring will be the end result (Klingberg *et al.*, 2013). In two *in vitro* studies, it has been shown that trophic factors, produced by ADSC, can inhibit the myofibroblast phenotype of dermal fibroblasts after stimulation with the pro-fibrotic cytokine TGF- β 1 (Spiekman *et al.*, 2014) and can inhibit that of fibroblasts derived from Dupuytren's nodules (Verhoekx *et al.*, 2013). Proliferation, ECM production and contraction of these fibroblasts were reduced, which indicates that growth factors and cytokines of ADSC have the ability to prevent or even to reverse dermal scarring.

6. Future perspectives

As discussed throughout, harnessing the power of fat for fibrotic scar treatment is an emerging concept in regenerative medicine. Fat can, however, be used in several fashions: as whole adipose tissue in lipofilling, or in loose components such as SVF, ADSC or even ADSC conditioned medium. In our opinion, each of these forms has its own ideal application in regenerative medicine (Figure 3). The use of whole adipose tissue in lipofilling is optimal when there is a soft tissue defect that needs filling. Besides the 'volumizing' effect, scar reduction is a beneficent side-effect of this treatment. Though, when extra volume is not a requirement or even a contraindication, the use of SVF offers an excellent alternative. In the setting of fibrotic dermal scars in areas where addition of extra volume is not aesthetically desirable, SVF is a good alternative for whole adipose tissue. Besides for use in dermal fibrotic scars, use of SVF opens the door for other clinical applications. Whole adipose tissue is not fit for use in fibrotic disorders in organs, such as cardiac or liver fibrosis. SVF, however, would be a suitable alternative to combat organ fibrosis. SVF has all the requirements to act as a scaffold for repair, as it contains ready-to-use microvasculature, ECM and ADSC to orchestrate the repair process. For example, acceleration of wound healing or

alteration of early scar formation would be exemplary candidates for use of SVF. Nonetheless, in case of pre-existing scars, a more rigorous remodelling of the mature scar tissue is necessary. Here, the microvasculature and ECM components of SVF are not a prerequisite. Thus, the application of ADSC would suffice. ADSC could orchestrate the remodelling, for example by immunomodulation or by instruction of the resident tissue cells from a synthetic to a proteolytic or a non-contractile phenotype. Last but not least, ADSC conditioned medium offers the ultimate solution when only instructive (growth) factors are required. In this way, use of allogeneic cells or xenogenic cell culture products can be circumvented, resulting in an off-the-shelf product. ADSC conditioned medium would be ideal for topical application or injection in wounds or developing scars.

7. Conclusion

Since Neuber's first report in 1893, the use of adipose tissue has gradually developed into an exciting new way to be used in the treatment and prevention of scar tissue. After lipofilling or after application of ADSC, improvement of scar appearance or reduction in scar-related pain has been reported in many case reports and clinical studies. Lipofilling and ADSC seem promising to lessen the severity of developing as well as pre-existent fibrotic scarring. A factor that complicates definitive conclusions in the efficacy of lipofilling and ADSC is the wide variety in experimental design of the studies. Each study uses different outcome measurements, at different time points in pre-existent as well as in developing scarring. Up to date, large randomized controlled clinical trials using lipofilling, ADSC, SVF or ADSC conditioned medium for fibrotic scar treatment are still lacking. For future randomized controlled clinical trials, we recommend researchers to carefully select their source of stromal cells depending on their goal.

Conflict of interest

The authors have no conflicts of interest to disclose in relation to the content of this work.

References

- Agostini T, Spinelli G, Marino G, Perello R. 2014; Esthetic restoration in progressive hemifacial atrophy (Romberg disease): structural fat grafting versus local/free flaps. *J Craniofac Surg* **25**(3): 783–787.
- Akita S, Yoshimoto H, Ohtsuru A, Hirano A, Yamashita S. 2012; Autologous adipose-derived regenerative cells are effective for chronic intractable radiation injuries. *Radiat Prot Dosimetry* **151**(4): 656–660.
- Amos PJ, Kapur SK, Stapor PC *et al.* 2010; Human adipose-derived stromal cells accelerate diabetic wound healing: impact of cell formulation and delivery. *Tissue Eng Part A* **16**(5): 1595–1606.
- Balkin DM, Samra S, Steinbacher DM. 2014; Immediate fat grafting in primary cleft lip repair. *J Plast Reconstr Aesthet Surg* **67**(12): 1644–1650.
- Bauer AL, Jackson TL, Jiang Y. 2009; Topography of extracellular matrix mediates vascular morphogenesis and migration speeds in angiogenesis. *PLoS Comput Biol* **5**(7): e1000445.
- Beausang E, Floyd H, Dunn KW, Orton CI, Ferguson MW. 1998; A new quantitative scale for clinical scar assessment. *Plast Reconstr Surg* **102**(6): 1954–1961.
- Benjamin MA, Schwarzman G, Eivazi M, Zachary L. 2015 Nov 15; Autologous staged fat tissue transfer in post-traumatic lower extremity reconstruction. *J Surg Case Rep* **2015**(11).
- Bollero D, Pozza S, Gangemi EN *et al.* 2014; Contrast-enhanced ultrasonography evaluation after autologous fat grafting in scar revision. *G Chir* **35**(11–12): 266–273.
- Bourin P, Bunnell BA, Casteilla L *et al.* 2013; Stromal cells from the adipose tissue-derived stromal vascular fraction and culture expanded adipose tissue-derived stromal/stem cells: a joint statement of the International Federation for Adipose Therapeutics and Science (IFATS) and the International Society for Cellular Therapy (ISCT). *Cytotherapy* **15**(6): 641–648.

- Bruno A, Delli Santi G, Fasciani L, Companari M, Palombo M, Palombo P. 2013; Burn scar lipofilling: immunohistochemical and clinical outcomes. *J Craniofac Surg* **24**(5): 1806–1814.
- Byrne M, O'Donnell M, Fitzgerald L, Shelley OP. 2016 Mar; Early experience with fat grafting as an adjunct for secondary burn reconstruction in the hand: Technique, hand function assessment and aesthetic outcomes. *Burns* **42**(2): 356–365.
- Cardenas-Camarena L, Arenas-Quintana R, Robles-Cervantes JA. 2011; Buttocks fat grafting: 14 years of evolution and experience. *Plast Reconstr Surg* **128**(2): 545–555.
- Carmen GY, Victor SM. 2006; Signalling mechanisms regulating lipolysis. *Cell Signal* **18**(4): 401–408.
- Castiglione F, Hedlund P, Van der Aa F *et al.* 2013; Intratunical injection of human adipose tissue-derived stem cells prevents fibrosis and is associated with improved erectile function in a rat model of Peyronie's disease. *Eur Urol* **63**(3): 551–560.
- Caviggioli F, Maione L, Forcellini D, Klinger F, Klinger M. 2011; Autologous fat graft in postmastectomy pain syndrome. *Plast Reconstr Surg* **128**(2): 349–352.
- Cawthorn WP, Scheller EL, MacDougald OA. 2012; Adipose tissue stem cells meet preadipocyte commitment: going back to the future. *J Lipid Res* **53**(2): 227–246.
- Coleman SR. 2002; Hand rejuvenation with structural fat grafting. *Plast Reconstr Surg* **110**(7): 1731–1744; discussion 1745–1747.
- Coleman SR. 2006; Structural fat grafting: more than a permanent filler. *Plast Reconstr Surg* **118**(3 Suppl): 108s–120s.
- Conde-Green A, Marano AA, Lee ES *et al.* 2016; Fat grafting and adipose-derived regenerative cells in burn wound healing and scarring: a systematic review of the literature. *Plast Reconstr Surg* **137**(1): 302–312.
- Corselli M, Chen CW, Sun B, Yap S, Rubin JP, Peault B. 2012; The tunica adventitia of human arteries and veins as a source of mesenchymal stem cells. *Stem Cells Dev* **21**(8): 1299–1308.
- Corselli M, Crisan M, Murray IR *et al.* 2013; Identification of perivascular mesenchymal stromal/stem cells by flow cytometry. *Cytometry A* **83**(8): 714–720.
- Crisan M, Yap S, Castellani L *et al.* 2008; A perivascular origin for mesenchymal stem cells in multiple human organs. *Cell Stem Cell* **3**(3): 301–313.
- Dong Z, Peng Z, Chang Q, Lu F. 2013; The survival condition and immunoregulatory function of adipose stromal vascular fraction (SVF) in the early stage of nonvascularized adipose transplantation. *PLoS One* **8**(11): e80364.
- Ehrlich HP, Desmouliere A, Diegelmann RF *et al.* 1994; Morphological and immunochemical differences between keloid and hypertrophic scar. *Am J Pathol* **145**(1): 105–113.
- Eto H, Kato H, Suga H *et al.* 2012; The fate of adipocytes after nonvascularized fat grafting: evidence of early death and replacement of adipocytes. *Plast Reconstr Surg* **129**(5): 1081–1092.
- Eto H, Suga H, Matsumoto D *et al.* 2009; Characterization of structure and cellular components of aspirated and excised adipose tissue. *Plast Reconstr Surg* **124**(4): 1087–1097.
- Fisher C, Grahovac TL, Schafer ME, Shippert RD, Marra KG, Rubin JP. 2013; Comparison of harvest and processing techniques for fat grafting and adipose stem cell isolation. *Plast Reconstr Surg* **132**(2): 351–361.
- Garza RM, Paik KJ, Chung MT *et al.* 2014; Studies in fat grafting: Part III. Fat grafting irradiated tissue – improved skin quality and decreased fat graft retention. *Plast Reconstr Surg* **134**(2): 249–257.
- Guisantes E, Fontdevila J, Rodriguez G. 2012; Autologous fat grafting for correction of unaesthetic scars. *Ann Plast Surg* **69**(5): 550–554.
- Hivernaud V, Lefourn B, Guicheux J *et al.* 2015; Autologous fat grafting in the breast: critical points and technique improvements. *Aesthetic Plast Surg* **39**(4): 547–561.
- Huang SH, Wu SH, Chang KP *et al.* 2014; Autologous fat grafting alleviates burn-induced neuropathic pain in rats. *Plast Reconstr Surg* **133**(6): 1396–1405.
- Huang SH, Wu SH, Chang KP *et al.* 2015a; Alleviation of neuropathic scar pain using autologous fat grafting. *Ann Plast Surg* **74** Suppl 2: S99–S104.
- Huang SH, Wu SH, Lee SS *et al.* 2015b; Fat grafting in burn scar alleviates neuropathic pain via anti-inflammation effect in scar and spinal cord. *PLoS One* **10**(9): e0137563.
- Ibatici A, Caviggioli F, Valeriano V *et al.* 2014; Comparison of cell number, viability, phenotypic profile, clonogenic, and proliferative potential of adipose-derived stem cell populations between centrifuged and noncentrifuged fat. *Aesthetic Plast Surg* **38**(5): 985–993.
- Illouz YG. 1983; Body contouring by lipolysis: a 5-year experience with over 3000 cases. *Plast Reconstr Surg* **72**(5): 591–597.
- Kato H, Mineda K, Eto H *et al.* 2014; Degeneration, regeneration, and cicatrization after fat grafting: dynamic total tissue remodeling during the first 3 months. *Plast Reconstr Surg* **133**(3): 303e–313e.
- Khouri RK, Eisenmann-Klein M, Cardoso E *et al.* 2012; Brava and autologous fat transfer is a safe and effective breast augmentation alternative: results of a 6-year, 81-patient, prospective multicenter study. *Plast Reconstr Surg* **129**(5): 1173–1187.
- Klingberg F, Hinz B, White ES. 2013; The myofibroblast matrix: implications for tissue repair and fibrosis. *J Pathol* **229**(2): 298–309.
- Klinger M, Caviggioli F, Klinger FM *et al.* 2013; Autologous fat graft in scar treatment. *J Craniofac Surg* **24**(5): 1610–1615.
- Klinger M, Marazzi M, Vigo D, Torre M. 2008; Fat injection for cases of severe burn outcomes: a new perspective of scar remodeling and reduction. *Aesthetic Plast Surg* **32**(3): 465–469.
- Kolle SF, Fischer-Nielsen A, Mathiasen AB *et al.* 2013; Enrichment of autologous fat grafts with ex-vivo expanded adipose tissue-derived stem cells for graft survival: a randomised placebo-controlled trial. *Lancet* **382**(9898): 1113–1120.
- Lam MT, Nauta A, Meyer NP, Wu JC, Longaker MT. 2013; Effective delivery of stem cells using an extracellular matrix patch results in increased cell survival and proliferation and reduced scarring in skin wound healing. *Tissue Eng Part A* **19**(5–6): 738–747.
- Lansdorp PM. 1995; Telomere length and proliferation potential of hematopoietic stem cells. *J Cell Sci* **108** (Pt 1): 1–6.
- Lee SH, Lee JH, Cho KH. 2011; Effects of human adipose-derived stem cells on cutaneous wound healing in nude mice. *Ann Dermatol* **23**(2): 150–155.
- Lin G, Garcia M, Ning H *et al.* 2008; Defining stem and progenitor cells within adipose tissue. *Stem Cells Dev* **17**(6): 1053–1063.
- Maione L, Memeo A, Pedretti L *et al.* 2014a; Autologous fat graft as treatment of post short stature surgical correction scars. *Injury* **45** Suppl 6: S126–S132.
- Maione L, Vinci V, Caviggioli F *et al.* 2014b; Autologous fat graft in postmastectomy pain syndrome following breast conservative surgery and radiotherapy. *Aesthetic Plast Surg* **38**(3): 528–532.
- Mazzola IC, Cantarella G, Mazzola RF. 2013; Management of tracheostomy scar by autologous fat transplantation: a minimally invasive new approach. *J Craniofac Surg* **24**(4): 1361–1364.
- Mizuno H, Tobita M, Uysal AC. 2012; Concise review: adipose-derived stem cells as a novel tool for future regenerative medicine. *Stem Cells* **30**(5): 804–810.
- Negenborn VL, Groen JW, Smit JM, Niessen FB, Mullender MG. 2016; The use of autologous fat grafting for treatment of scar tissue and scar-related conditions: a systematic review. *Plast Reconstr Surg* **137**(1): 31e–43e.
- Neuber G. 1893; Fettersplantation. *Chir Kongr Verhandl Deutsche Gesellschaft fur Chir*; 22: 66.
- Niessen FB, Spauwen PH, Schalkwijk J, Kon M. 1999; On the nature of hypertrophic scars and keloids: a review. *Plast Reconstr Surg* **104**(5): 1435–1458.
- Pallua N, Baroncini A, Alharbi Z, Stromps JP. 2014; Improvement of facial scar appearance and microcirculation by autologous lipofilling. *J Plast Reconstr Aesthet Surg* **67**(8): 1033–1037.
- Panettiè P, Marchetti L, Accorsi D. 2009; The serial free fat transfer in irradiated prosthetic breast reconstructions. *Aesthetic Plast Surg* **33**(5): 695–700.
- Pawitan JA. 2014; Prospect of stem cell conditioned medium in regenerative medicine. *Biomed Res Int* **2014**: 965849.
- Peltoniemi HH, Salmi A, Miettinen S *et al.* 2013; Stem cell enrichment does not warrant a higher graft survival in lipofilling of the breast: a prospective comparative study. *J Plast Reconstr Aesthet Surg* **66**(11): 1494–1503.
- Phulpin B, Gangloff P, Tran N, Bravetti P, Merlin JL, Dolivet G. 2009; Rehabilitation of irradiated head and neck tissues by autologous fat transplantation. *Plast Reconstr Surg* **123**(4): 1187–1197.
- Pittenger MF, Mackay AM, Beck SC *et al.* 1999; Multilineage potential of adult human mesenchymal stem cells. *Science* **284**(5411): 143–147.
- Pu LL, Coleman SR, Cui X, Ferguson Jr RE, Vasconez HC. 2008; Autologous fat grafts harvested and refined by the Coleman technique: a comparative study. *Plast Reconstr Surg* **122**(3): 932–937.
- Rehman J, Traktuev D, Li J *et al.* 2004; Secretion of angiogenic and antiapoptotic factors by human adipose stromal cells. *Circulation* **109**(10): 1292–1298.
- Ribuffo D, Atzeni M, Guerra M *et al.* 2013; Treatment of irradiated expanders: protective lipofilling allows immediate prosthetic breast reconstruction in the setting of postoperative radiotherapy. *Aesthetic Plast Surg* **37**(6): 1146–1152.
- Rigotti G, Marchi A, Galie M *et al.* 2007; Clinical treatment of radiotherapy tissue damage by liposiprate transplant: a healing process mediated by adipose-derived adult stem cells. *Plast Reconstr Surg* **119**(5): 1409–1422; discussion 1423–1404.
- Sardesai MG, Moore CC. 2007; Quantitative and qualitative dermal change with microfat grafting of facial scars. *Otolaryngol Head Neck Surg* **137**(6): 868–872.
- Spiekman M, Przybyl E, Plantinga JA, Gibbs S, van der Lei B, Harmsen MC. 2014; Adipose tissue-derived stromal cells inhibit TGF-beta1-induced differentiation of human dermal fibroblasts and keloid scar-derived fibroblasts in a paracrine fashion. *Plast Reconstr Surg* **134**(4): 699–712.
- Suga H, Eto H, Aoi N *et al.* 2010; Adipose tissue remodeling under ischemia: death of adipocytes and activation of stem/progenitor cells. *Plast Reconstr Surg* **126**(6): 1911–1923.
- Sultan SM, Barr JS, Butala P *et al.* 2012; Fat grafting accelerates revascularisation and decreases fibrosis following thermal injury. *J Plast Reconstr Aesthet Surg* **65**(2): 219–227.
- Sultan SM, Stern CS, Allen Jr RJ *et al.* 2011; Human fat grafting alleviates radiation skin damage in a murine model. *Plast Reconstr Surg* **128**(2): 363–372.
- Tang W, Zeve D, Suh JM *et al.* 2008; White fat progenitor cells reside in the adipose vasculature. *Science* **322**(5901): 583–586.
- Tanikawa DY, Agüena M, Bueno DF, Passos-Bueno MR, Alonso N. 2013; Fat grafts supplemented with adipose-derived stromal cells in the rehabilitation of patients with craniofacial microsomia. *Plast Reconstr Surg* **132**(1): 141–152.
- Thomson JA, Itskovitz-Eldor J, Shapiro SS *et al.* 1998; Embryonic stem cell lines derived from human blastocysts. *Science* **282**(5391): 1145–1147.
- Tiryaki T, Findikli N, Tiryaki D. 2011; Staged stem cell-enriched tissue (SET) injections for soft tissue augmentation in hostile recipient areas: a preliminary report. *Aesthetic Plast Surg* **35**(6): 965–971.
- Traktuev DO, Merfeld-Claus S, Li J *et al.* 2008; A population of multipotent CD34-positive adipose stromal cells share pericyte and mesenchymal surface markers, reside in a periendothelial location, and stabilize endothelial networks. *Circ Res* **102**(1): 77–85.
- Traktuev DO, Prater DN, Merfeld-Claus S *et al.* 2009; Robust functional vascular network formation in vivo by cooperation of adipose progenitor and endothelial cells. *Circ Res* **104**(12): 1410–1420.
- Tuin AJ, Domerchie PN, Schepers RH *et al.* 2016; What is the current optimal fat grafting processing technique? A systematic review. *J Craniomaxillofac Surg* **44**(1): 45–55.
- Ulrich D, Ulrich F, van Doorn L, Hovius S. 2012; Lipofilling of perineal and vaginal scars: a new method for improvement of pain after episiotomy and perineal laceration. *Plast Reconstr Surg* **129**(3): 593e–594e.
- Uysal CA, Tobita M, Hyakusoku H, Mizuno H. 2014; The effect of bone-marrow-derived stem cells and adipose-derived stem cells on wound contraction and epithelialization. *Adv Wound Care (New Rochelle)* **3**(6): 405–413.
- van der Veer WM, Bloemen MC, Ulrich MM *et al.* 2009; Potential cellular and molecular causes of hypertrophic scar formation. *Burns* **35**(1): 15–29.
- Verhoek JS, Mudera V, Walbeehm ET, Hovius SE. 2013; Adipose-derived stem cells inhibit the contractile myofibroblast in Dupuytren's disease. *Plast Reconstr Surg* **132**(5): 1139–1148.
- Vogel H, Niewisch H, Mاتيoli G. 1968; The self renewal probability of hemopoietic stem cells. *J Cell Physiol* **72**(3): 221–228.
- Wang G, Ren Y, Cao W, Yang Y, Li S. 2013; Liposculpture and fat grafting for aesthetic correction of the gluteal concave deformity associated with multiple intragluteal injection of penicillin in childhood. *Aesthetic Plast Surg* **37**(1): 39–45.
- Yang D, Wang W, Li L *et al.* 2013; The relative contribution of paracrine effect versus direct differentiation on

- adipose-derived stem cell transplantation mediated cardiac repair. *PLoS One* **8**(3): e59020.
- Yoshimura K, Shigeura T, Matsumoto D *et al.* 2006; Characterization of freshly isolated and cultured cells derived from the fatty and fluid portions of liposuction aspirates. *J Cell Physiol* **208**(1): 64–76.
- Yun IS, Jeon YR, Lee WJ *et al.* 2012; Effect of human adipose derived stem cells on scar formation and remodeling in a pig model: a pilot study. *Dermatol Surg* **38**(10): 1678–1688.
- Zellner EG, Pfaff MJ, Steinbacher DM. 2015; Fat grafting in primary cleft lip repair. *Plast Reconstr Surg* **135**(5): 1449–1453.
- Zhang Q, Liu LN, Yong Q, Deng JC, Cao WG. 2015; Intralesional injection of adipose-derived stem cells reduces hypertrophic scarring in a rabbit ear model. *Stem Cell Res Ther* **6**: 145.
- Zimmerlin L, Donnenberg VS, Pfeifer ME *et al.* 2010; Stromal vascular progenitors in adult human adipose tissue. *Cytometry A* **77**(1): 22–30.
- Zonari A, Martins TM, Paula AC *et al.* 2015; Polyhydroxybutyrate-co-hydroxyvalerate structures loaded with adipose stem cells promote skin healing with reduced scarring. *Acta Biomater* **17**: 170–181.
- Zuk PA, Zhu M, Mizuno H *et al.* 2001; Multilineage cells from human adipose tissue: implications for cell-based therapies. *Tissue Eng* **7**(2): 211–228.