

Received: 2017.06.26
Accepted: 2017.08.23
Published: 2017.12.09

Multiple Weekly Dalbavancin Dosing for the Treatment of Native Vertebral Osteomyelitis Caused by Methicillin-Resistant *Staphylococcus Aureus*: A Case Report

Authors' Contribution:
Study Design A
Data Collection B
Statistical Analysis C
Data Interpretation D
Manuscript Preparation E
Literature Search F
Funds Collection G

ABDEF 1 **Thamer A. Almagour**
ABDEF 2 **Valerie Fletcher**
DEF 3 **Mohammed Alessa**
DEF 4 **Abdullah A. Alhifany**
ABDEF 5 **Deanne Tabb**

1 Department of Pharmacotherapy and Experimental Therapeutics, University of North Carolina at Chapel Hill Eshelman School of Pharmacy, Chapel Hill, NC, U.S.A.
2 Infectious Diseases Physician, Columbus, GA, U.S.A.
3 College of Pharmacy, King Saud bin Abdulaziz University for Health Science, Riyadh, Saudi Arabia
4 Department of Pharmacy Practice and Science, University of Arizona College of Pharmacy, Tucson, AZ, U.S.A.
5 Department of Infectious Diseases Pharmacy, Midtown Medical Center, Columbus Regional Health, Columbus, GA, U.S.A.

Corresponding Author: Thamer A. Almagour, e-mail: talmangour@unc.edu
Conflict of interest: None declared

Patient: Male, 58
Final Diagnosis: Vertebral osteomyelitis
Symptoms: Back pain
Medication: Dalbavancin
Clinical Procedure: —
Specialty: Infectious Disease

Objective: Unusual clinical course

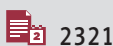
Background: Native vertebral osteomyelitis (NVO) is a common form of hematogenous osteomyelitis, with *Staphylococcus aureus* (*S. aureus*) being the most commonly isolated organism. Dalbavancin is approved by the US Food and Drug Administration (FDA) for the treatment of acute bacterial skin and skin structure infections (ABSSSI) and has a sufficiently promising pharmacokinetic and pharmacodynamic profile to be considered for the treatment of vertebral osteomyelitis. We describe here what is probably the first reported case of using multiple weekly dalbavancin to treat a complicated methicillin-resistant *Staphylococcus aureus* (MRSA) bacteremia and vertebral osteomyelitis.

Case Report: A 58-year-old man with a long history of recurrent MRSA bacteremia, who failed multiple courses of vancomycin and daptomycin, presented with recurrent MRSA bacteremia complicated by diskitis and osteomyelitis of the lumbar vertebrae. The patient was treated with dalbavancin 1000 mg intravenously weekly for two weeks followed by 500 mg weekly for six additional weeks. He improved clinically, his back pain resolved, and C-reactive protein (CRP) decreased to normal. Three months after the last dose of dalbavancin therapy, he underwent angiography for peripheral artery diseases, after which he developed a fever, mild leukocytosis, an elevated CRP, and the repeat blood cultures were positive for MRSA. No apparent adverse events were observed during dalbavancin therapy.


Conclusions: In this case, multiple weekly dalbavancin infusions appeared to be safe in the treatment of vertebral osteomyelitis caused by MRSA, but did not seem to prevent infection recurrence. However, reinfection with a new strain from the angiography catheter insertion is highly likely. Clinical studies are needed to further assess the safety and effectiveness of multiple weekly dalbavancin dosing in the management of vertebral osteomyelitis.

MeSH Keywords: Discitis • Glycopeptides • Methicillin-Resistant *Staphylococcus Aureus* • Osteomyelitis

Full-text PDF: <https://www.amjcaserep.com/abstract/index/idArt/905930>



2321



18



Background

Native vertebral osteomyelitis (NVO) is a common form of hematogenous osteomyelitis, with a higher risk seen in adults aged 50 years or older [1]. The overall incidence of NVO has been reported at 2.4 per 100,000; however, the incidence increases to 6.5 per 100,000 among persons older than 70 years of age [2]. *Staphylococcus aureus* (*S. aureus*) is the most frequently isolated organism in vertebral osteomyelitis [3–5]. Additionally, relapse has been previously reported at 14% [5]. The most common primary sources of infection for hematogenous NVO include the urinary tract, skin and soft tissue, intravenous access, genitourinary tract instrumentation, endocarditis, and bursitis or septic arthritis [3,5]. Lumbar osteomyelitis accounts for the majority of vertebral osteomyelitis cases (58%), followed by thoracic (30%) and cervical (11%) [6].

Clinical, laboratory, radiologic, and microbiologic findings should be considered in the diagnosis of vertebral osteomyelitis. Back pain, the most common symptom attributable to vertebral osteomyelitis, was reported in 86% of all cases [6]. Fever and leukocytosis are common and have been reported in up to 45% and 60% of all cases, respectively [7]. Erythrocyte sedimentation rate (ESR) and C-reactive protein (CRP) are commonly used adjunctively with clinical, imaging, and microbiologic findings to diagnose vertebral osteomyelitis. Elevated ESR or CRP in patients with back pain has a sensitivity that can range from 94% to 100% for vertebral osteomyelitis [7]. ESR and CRP are also used to monitor clinical response to antimicrobial treatment. Blood cultures yielded growth in only 58% of cases; however, image-guided aspiration biopsy or an open biopsy yielded the organism more often, with a sensitivity of about 77% [4]. Magnetic resonance imaging (MRI) of the spine has a diagnostic sensitivity of 97%, and specificity of 93%, and should be used when feasible in patients with suspected vertebral osteomyelitis; however, computed tomography (CT) scanning is also useful [7–9]. Image-guided aspiration biopsy is not necessary to confirm the diagnosis of NVO in patients with positive blood culture for *S. aureus* who have clinical, laboratory, and radiologic findings consistent with this disease [7].

Parenteral antimicrobial therapy for a total duration of 6 weeks is the standard treatment approach for the management of NVO caused by methicillin-resistant *Staphylococcus aureus* (MRSA) [7]. Intravenous vancomycin is the primary treatment option, and daptomycin is an alternative agent [7]. Despite the paucity of clinical data, other options, such as linezolid and ceftaroline, may be considered as salvage therapy in selected patients. However, drug allergy, adverse reactions, antimicrobial resistance, infection relapse, and clinical or microbiologic failure may further limit the treatment options for vertebral MRSA infections.

Dalbavancin, a long-acting glycopeptide, is approved by the US Food and Drug Administration (FDA) for the treatment of acute bacterial skin and skin structure infections (ABSSSI) caused by susceptible strains of Gram-positive microorganisms [10]. The dose of dalbavancin is 1000 mg given intravenously over 30 min followed by 500 mg one week later, or as a single dose of 1500 mg [10]. The long half-life, infrequent dosing, activity against MRSA, favorable safety profile, and high bone concentration in animal and phase I clinical studies, make dalbavancin a promising agent in the treatment of vertebral osteomyelitis [11,12]. To the best of our knowledge, this article is the first to report on the use of multiple weekly dalbavancin to treat a complicated MRSA bacteremia and vertebral osteomyelitis.

Case Report

A 58-year-old man with a history of penicillin-induced anaphylaxis and a long history of recurrent MRSA bacteremia presented with another recurrence. His past medical history was significant for congestive heart failure, insulin-dependent diabetes mellitus, diabetic neuropathy, chronic ulceration complicated by osteomyelitis of the right foot, hypertension, depression, peripheral artery disease, acute kidney injury, chronic kidney disease and pulmonary embolism. Past surgical history included trans-metatarsal amputation of the right foot followed by below-knee amputation. He recently stopped smoking cigarettes after 40 years and denied alcohol use. The patient has a significant family history of diabetes mellitus. Home medications included gabapentin, atorvastatin, sertraline, apixaban, losartan, furosemide, carvedilol, aspirin, pantoprazole, and insulin.

Originally, the patient developed a persistent MRSA bacteremia from a chronic right foot ulcer complicated by osteomyelitis and gangrene. At that time, he underwent a below-knee amputation. A transesophageal echocardiogram showed no evidence of endocarditis. He was initially treated with vancomycin 1.25 g intravenously every 12 h, and the trough serum vancomycin concentrations were maintained at 15–20 µg/ml; however, despite vancomycin therapy, his bacteremia persisted. Vancomycin was then changed to daptomycin 700 mg intravenously daily. The minimum inhibitory concentrations (MICs) of vancomycin, daptomycin, and linezolid were 1, 0.5 and 4 µg/ml, respectively. He completed a 6-week course of intravenous antibiotics and initially cleared his bacteremia.

Three weeks later, he was readmitted with wound dehiscence of the amputation site, recurrent MRSA bacteremia, and pyogenic arthritis of the left knee and left shoulder. He was treated with a 6-week course of intravenous vancomycin, which led to a complete resolution of his left knee, left shoulder, and right leg infections. For this isolate, the MICs of vancomycin,

daptomycin and linezolid were 2, 1 and 4 µg/ml, respectively. He was again noted to have recurrent MRSA bacteremia and was again treated with a long course of vancomycin. His intravenous catheter was removed at the end of treatment.

In this current admission, he presented to the emergency department with severe back pain. Body Temperature was 98.6°F (37°C), heart rate was 88 beats min⁻¹, respiratory rate was 18 breaths min⁻¹, and blood pressure was 143/83 mmHg. His weight was 70 kg and height was 5 feet 11 inches. On physical examination, he had no cardiorespiratory distress. Heart sounds 1 and 2 were regular, and he had a 2/6 systolic murmur. He had vesicular breath sounds with basal crackles. He had suprapubic and left flank tenderness. He was alert and oriented to time, place, and person and had no focal deficit. Abnormal laboratory findings included white blood cells (WBCs) 12.6×10⁹ l⁻¹, serum creatinine 1.3 mg/dl, and CRP 5.0 mg/dl. A lumbar CT scan showed L1 and L2 vertebral endplate destruction that appeared to be recent, suggesting diskitis and osteomyelitis. Two sets of aerobic blood cultures were drawn and grew MRSA with MICs of 2 µg/ml for both daptomycin and vancomycin, as well as an MIC of 4 µg/ml for linezolid. The isolate was reported sensitive to trimethoprim/sulfamethoxazole, tetracycline, and rifampin. Vancomycin was initiated because inpatient dalbavancin was initially unavailable.

A repeat transthoracic echocardiogram showed no evidence of endocardial vegetation. Following blood stream clearance, vancomycin was switched to dalbavancin 1000 mg intravenously weekly for 2 weeks, followed by 500 mg weekly for 6 additional weeks and rifampin 600 mg po daily. Complete blood count, comprehensive metabolic panel, and CRP were performed weekly. While on therapy, the patient reported feeling better, and the back pain subsided. The weekly reading of CRP from the baseline of 5.0 mg/dl trended down to 2.2, 0.9, 0.8, 0.5, and <0.3 mg/dl and WBCs were within normal limit. The range of blood urea nitrogen was 17–38 mg/dl, serum creatinine was 1.26–2.51 mg/dl, and the transaminases remained normal during the treatment. Blood culture continued to be negative at the follow-up visit 14 days after the last dose of dalbavancin. He did not complain of nausea, vomiting, diarrhea, headache, rash, pruritus, or other complaints during therapy.

Three months after the last dose of dalbavancin therapy, the patient underwent angiography for peripheral artery diseases, after which he developed a fever, mild leukocytosis, an elevated CRP, and the repeat blood cultures were again positive for MRSA possibly due to reinfection with a new strain of MRSA acquired during angiography. For this isolate, the MICs of vancomycin, daptomycin and linezolid were 1, 0.5 and 2 µg/ml, respectively.

Discussion

Vancomycin and daptomycin are the most commonly used antibiotics for the treatment of vertebral osteomyelitis caused by MRSA. However, drug allergy, adverse reactions, antimicrobial resistance, infection relapse, and clinical or microbiological failure can limit their use. Recurrence after the end of treatment has been defined as a new positive blood culture within 3 months after the first positive result [13]. In this case, due to multiple relapses and the use of salvage therapy, we were following the patient for 3 months after the last dose of dalbavancin.

Dalbavancin, a novel lipoglycopeptide, is FDA-approved for the treatment of ABSSSI caused by susceptible strains of Gram-positive microorganisms [10]. It requires infrequent dosing due to its prolonged terminal half-life of 14.4 days [12]. In addition, it has potent activity against MRSA, with MIC₉₀ of 0.06 µg/ml, resulting in 8-fold and 16-fold more activity compared to daptomycin (MIC₉₀ of 0.5 µg/ml) and vancomycin (MIC₉₀ of 1 µg/ml), respectively [14]. Furthermore, it has favorable safety profile, with no apparent drug accumulation after a 1000 mg loading dose followed by 500 mg for 7 additional weekly doses [12]. Moreover, dalbavancin has high bone concentrations in animal and phase I clinical studies with a mean non-infected cortical bone to plasma penetration ratio of 13%, which is higher than the mean ratio of 7% previously reported for vancomycin [11,12,15]. These are promising factors to be considered in the treatment of osteomyelitis caused by *S. aureus*.

Two phase I studies were conducted in healthy volunteers to evaluate the safety, tolerability, and pharmacokinetics of dalbavancin in bone and articular tissue aiming to design a dosing regimen appropriate for long-term use [12]. The first trial was a bone penetration study. Thirty healthy adults were enrolled and divided into 6 cohorts with 5 subjects each, and received single doses of dalbavancin 1000 mg intravenously over 30 min at 0.5, 1, 3, 7, 10, or 14 days before their scheduled elective orthopedic surgeries. Bone (µg/g) to plasma (µg/ml) concentration ratios were 6.3/85.3 and 4.1/15.3 after 12 h and 14 days, respectively. The mean bone to plasma area under the curve (AUC) penetration ratio was 13.1%. No serious adverse event or adverse event necessitating drug discontinuation or subject withdrawal occurred in the study. In the second trial, 18 subjects were enrolled and divided into 3 cohorts with 6 subjects each to assess the safety, tolerability, and pharmacokinetics of dalbavancin following 4 weekly doses (cohort I), 6 weekly doses (cohort II), and 8 weekly doses (cohort III). All subjects received 1000 mg of dalbavancin on day 1 followed by 500 mg weekly for the subsequent weekly doses. Blood samples were obtained 15 min before the next weekly scheduled dose. The range of the minimum serum concentrations (C_{min}) on days 8, 15, and 22 for cohort I was 33.0–31.9 µg/ml; the range on

days 8, 15, 22, 29, and 36 for cohort II was 38.1–43.2 µg/ml; and the range on days 8, 15, 22, 29, 36, 43, and 50 for cohort III was 36.5–40.6 µg/ml. For all 3 cohorts, C_{min} were consistent with steady-state concentrations achieved by day 8, and no apparent drug accumulation was observed. Among all subjects in this study, two adverse events were possibly related to drug therapy, transient urticarial rash, and mild pain in the forearm.

Dalbavancin antimicrobial activity appears to correlate well with PK/PD parameters 24-h AUC/MIC and maximum serum concentration (C_{max})/MIC [16]. The two regimens, with 1500 mg given on day 1 and day 8, as well as 1000 mg followed by 500 mg weekly for 4 weeks, are expected to achieve similar total AUC; however, experimental data suggest that the efficacy of drugs with long half-life is increased when higher doses are given earlier during the course of treatment [12]. In this case, due to recurrent MRSA bacteremia, drug resistance, and the presence of a significant penicillin allergy, dalbavancin therapy was selected to attempt microbiologic and clinical cure, as well as to prevent relapse. Ceftaroline was not considered due to the allergy status. Linezolid, despite being a bacteriostatic agent, can achieve adequate bone concentration that exceeds the MICs of most Gram-positive cocci and has shown successful outcomes in orthopedic infections in case reports and case series [17]. However, bone marrow suppression, peripheral neuropathy, and optic neuritis are more common in prolonged duration of therapy, which may limit the role of linezolid in the treatment of osteomyelitis.

In this case, at the end of dalbavancin therapy, the patient clinically improved, his back pain subsided, WBCs remained within normal limits, and CRP became normal. No adverse events were observed during dalbavancin therapy. Serum creatinine increased from 1.72 mg/dl a week before the last dose to 2.51 mg/dl at the last visit, then decreased to 2.00 mg/dl in the follow-up visit 14 days after the last dose of dalbavancin. Alanine

aminotransferase (ALT) was within normal range throughout the course of therapy. However, 3 months after the last dose of dalbavancin therapy, the patient developed a recurrence.

Recurrence is classified as relapse (same original infecting strain) or reinfection (different strain of same species). Reinfection usually occurs later after the completion of therapy. In one study, relapse of *S. aureus* bacteremia occurred after a median of 36 days following the completion of antibiotic therapy versus 99 days for reinfection [18]. Although molecular typing techniques, such as pulsed-field gel electrophoresis, are preferred to distinguish relapse from reinfection by comparing the genetic pattern unique to each strain, phenotypic tests may be used as a helpful tool by differentiating the sensitivity pattern of the isolates. Given the late recurrence, different MICs of the last isolate, and the angiography catheter insertion that preceded the infection in a chronically colonized patient, it is highly likely that the recurrence in this case was not a relapse, but rather a reinfection with a new strain of MRSA from a new portal of entry.

Conclusions

In this case, multiple weekly dalbavancin infusions appeared to be safe in the treatment of vertebral osteomyelitis caused by MRSA, but did not seem to prevent infection recurrence. However, reinfection with a new strain from the angiography catheter insertion is highly likely. Clinical studies are needed to further assess the safety and effectiveness of multiple weekly dalbavancin dosing in the management of vertebral osteomyelitis.

Conflict of interest

None.

References:

1. Jensen AG, Espersen F, Skinhoj P et al: Increasing frequency of vertebral osteomyelitis following *Staphylococcus aureus* bacteraemia in Denmark 1980–1990. *J Infect*, 1997;34: 113–18
2. Grammatico L, Baron S, Rusch E et al: Epidemiology of vertebral osteomyelitis (VO) in France: Analysis of hospital-discharge data 2002–2003. *Epidemiol Infect*, 2008; 136: 653–60
3. Torda AJ, Gottlieb T, Bradbury R: Pyogenic vertebral osteomyelitis: Analysis of 20 cases and review. *Clin Infect Dis*, 1995; 20: 320–28
4. Mylona E, Samarkos M, Kakalou E et al: Pyogenic vertebral osteomyelitis: A systematic review of clinical characteristics. *Semin Arthritis Rheum*, 2009; 39: 10–17
5. McHenry MC, Easley KA, Locker GA: Vertebral osteomyelitis: Long-term outcome for 253 patients from 7 Cleveland area hospitals. *Clin Infect Dis*, 2002; 34: 1342–50
6. Zimmerli W: Clinical practice. Vertebral osteomyelitis. *N Engl J Med*, 2010; 362: 1022–29
7. Berbari EF, Kanji SS, Kowalski TJ et al: 2015 infectious diseases society of America (IDSA) clinical practice guidelines for the diagnosis and treatment of native vertebral osteomyelitis in adults. *Clin Infect Dis*, 2015; 61(6): e26–46
8. Ledermann HP, Schweitzer ME, Morrison WB, Carrino JA: MR imaging findings in spinal infections: Rules or myths? *Radiology*, 2003; 228: 506–14
9. Dagirmanjian A, Schils J, McHenry M, Modic MT: MR imaging of vertebral osteomyelitis revisited. *Am J Roentgenol*, 1996; 167: 1539–43
10. Parsippany NJ: Durata therapeutics. Dalvance [package insert]; 2014
11. Solon EG, Dowell JA, Lee J et al: Distribution of radioactivity in bone and related structures following administration of [¹⁴C]dalbavancin to New Zealand White rabbits. *Antimicrob Agents Chemother*, 2007; 51: 3008–10
12. Dunne MW, Puttagunta S, Sprenger CR et al: Extended-duration dosing and distribution of dalbavancin into bone and articular tissue. *Antimicrob Agents Chemother*, 2015; 59: 1849–55
13. Jensen AG, Espersen F, Skinhoj P, Fridomdt-Møller N: Bacteremic *Staphylococcus aureus* spondylitis. *Arch Intern Med*, 1998; 158(5): 509–17

14. Jones RN, Sader HS, Flamm RK: Update of dalbavancin spectrum and potency in the U S A: Report from the SENTRY Antimicrobial Surveillance Program (2011). *Diagn Microbiol Infect Dis*, 2013; 75: 304–7
15. Graziani AL, Lawson LA, Gibson GA et al: Vancomycin concentrations in infected and noninfected human bone. *Antimicrob Agents Chemother*, 1988; 32: 1320–22
16. Andes D, Craig WA: *In vivo* pharmacodynamic activity of the glycopeptide dalbavancin. *Antimicrob Agents Chemother*, 2007; 51: 1633–42
17. Falagas ME, Siempos II, Papagelopoulos PJ, Vardakas KZ: Linezolid for the treatment of adults with bone and joint infections. *Int J Antimicrob Agents*, 2007; 29(3): 233–39
18. Chang FY, Peacock JE Jr., Musher DM et al: *Staphylococcus aureus* bacteremia: recurrence and the impact of antibiotic treatment in a prospective multicenter study. *Medicine (Baltimore)*, 2003; 82(5): 333–39