



All-Inside Partial Epiphyseal Anterior Cruciate Ligament Reconstruction Plus an Associated Modified Lemaire Procedure Sutured to the Femoral Button

Manuel Leyes-Vence, M.D., Ph.D., Tomas Roca-Sanchez, M.D., Cesar Flores-Lozano, M.D., and Gregorio Villarreal-Villareal, M.D.

Abstract: Anterior cruciate ligament (ACL) tears in skeletally immature patients are on the rise; pediatric athletes are now in constant year-round sports participation. Nonoperative treatment may lead to poor functional outcomes and an increase in associated intra-articular lesions and sometimes can cause drop-out from sports activity. The treatment of these injuries is not at all clear, and appropriate guidelines do not exist. Physéal-sparing and partial physéal-sparing techniques have been described. Concerns about restoring normal knee kinematics with the previously described ACL reconstruction (ACLR) techniques are open to debate. We describe a partial epiphyseal ACLR to be done in skeletally immature patients involved in highly demanding sport activities. This technique is performed with an extraphyseal femoral tunnel drilled retrograde, a transphyseal tibial tunnel, and a retrograde tibial drilling without trespassing the tibial physis. We added a modified Lemaire procedure to improve rotational instability to the previously performed ACLR.

In recent years the incidence of anterior cruciate ligament (ACL) tears in the pediatric or skeletally immature population is increasing, accounting for up to 26% to 65% of knee hemarthrosis among young athletes.^{1,2} The increase of this pathology is related to a rise in the number of children engaged in high-demand pivoting sports at a competitive level particularly soccer, skiing, football, hockey, and gymnastics, among others. It is true that awareness among coaches, team physicians, and trainers has helped to get a rapid diagnosis.³

The treatment of ACL injuries in pediatric patients has been a highly controversial topic to address. Some

surgeons fear the appearance of growth disturbances after ACL reconstructions (ACLR) secondary to physéal perichondral ring damage caused during surgical approach, tunnel drilling, or graft fixation.⁴ Nevertheless, the delay in surgical treatment causes an increase in medial meniscus injuries, irreparable meniscal tears, and other chondral injuries.³

In some pediatric athlete who are involved in high-demand pivoting sports, isolated ACLR may not provide enough rotational stability to allow them to perform at their preinjury level.⁵ In addition, in this age group, an increase of rotational and anterior translation conditions can be added to the above described conditions: valgus, generalized hypermobility, and hyperlaxity are found in most of these young athletes' knees.⁶ In this subgroup of patients good rotational and anterior stability can be achieved by combining ACLR and an associated lateral extra-articular tenodesis (LET).⁷ Among the LET procedures, the use of a strip of the iliotibial band (ILTB; modified Lemaire procedure), passing it deep to the lateral collateral ligament (LCL) and fixing it to the femur, can restore normal kinematics of the knee.⁸ The ILTB has been used for ACLR as a physéal-sparing technique in skeletally immature patients,⁹ achieving excellent outcomes and a mean durability of more than 6 years.¹⁰

We describe a partial physéal-sparing anatomic ACLR with an associated modified Lemaire procedure sutured

From Clínica CEMTRO (M.L-V., T.R-S., C.F-L.), Madrid, Spain; and Department of Orthopaedics and Traumatology, Universidad Autónoma de Nuevo León (G.V-V.), Monterrey, Nuevo León, México.

The authors report that they have no conflicts of interest in the authorship and publication of this article. Full ICMJE author disclosure forms are available for this article online, as [supplementary material](#).

Received November 6, 2018; accepted January 6, 2019.

Address correspondence to Gregorio Villarreal-Villareal, M.D., Department of Orthopaedics and Traumatology, Universidad Autónoma de Nuevo León, Francisco I. Madero y Av. Gonzalitos S/N, Col. Mitrás Centro, 64460, Monterrey, Nuevo León, México. E-mail: villarrealga@gmail.com

© 2019 by the Arthroscopy Association of North America. Published by Elsevier. This is an open access article under the CC BY-NC-ND license (<http://creativecommons.org/licenses/by-nc-nd/4.0/>).

2212-6287/181339

<https://doi.org/10.1016/j.eats.2019.01.003>

to the same femoral button used for femoral fixation of the ACL graft.

Surgical Technique

The surgical technique is demonstrated in [Video 1](#). First, we mark on the skin the superficial anatomy of the Gerdy's tubercle (GT), fibular head, and LCL contour, from its distal to the proximal attachment on the lateral femoral epicondyle; finally the tibial and femoral epiphyseal growth plates are marked using fluoroscopic assistance.

Then a 3- to 4-cm incision is made from the lateral femoral epicondyle directed to the GT. The ILTB is exposed, and a 1-cm-wide per 6-cm-long strip of the ILTB is elevated, preserving its distal attachment to the GT ([Fig. 1](#), ILTB harvest). A Krackow suture with a no. 2 Vycril is made along the free elevated proximal side of the ILTB strip ([Fig. 2](#), Krackow suture to the ILTB strip). We identify and dissect the LCL, using scissors, carefully separating the layer between the LCL and the lateral capsule. A curved clamp/kocher is passed under the LCL ([Fig. 3](#), identification of the LCL). Then the ILTB strip is taken deep to the LCL near its proximal insertion ([Fig. 4](#), passing under the LCL).

It is important to locate the femoral guide pin entry point just proximal and posterior to the lateral epicondyle ([Fig. 5](#), identification of femoral entry point). We then use fluoroscopy to ensure the correct location and entry point for our femoral guide pin, distal to and at a safe distance from the femoral physis.

We calculate the approximate length of our tunnels and the required length of our graft using preoperative magnetic resonance imaging. The semitendinosus tendon is harvested through a 3-cm oblique incision over the distal insertion of the hamstring tendons

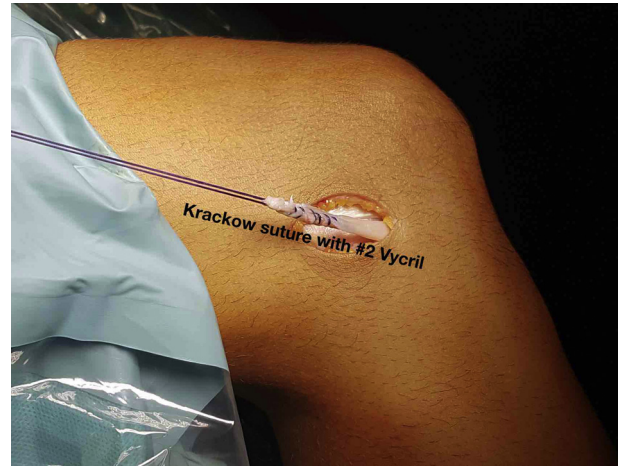

Fig 2. Krackow suture on the iliotibial band. A Krackow suture is created on the elevated free end of the iliotibial band strip with a no. 2 Vycril; a total of 5 to 7 throws are done.

([Fig. 6](#), semitendinosus tendon harvest). Our goal is to achieve a quadrupled graft of the appropriate length (40-50 mm) and diameter (≥ 8 mm).

The graft is prepared using the GraftLink technique (Arthrex, Naples, FL) with 2 TightRope RT suture buttons for fixation on the tibia and femur ([Fig. 7](#), semitendinosus graft preparation). The graft is sized and pretensioned to 20 pounds for 5 minutes.

Standard diagnostic knee arthroscopy is performed using a 30° arthroscope. All chondral and meniscal pathology should be addressed if necessary. The ACL tear is identified and debrided to show the tibial and femoral footprints. We have to make sure that the anteromedial portal is big enough for future graft passage.

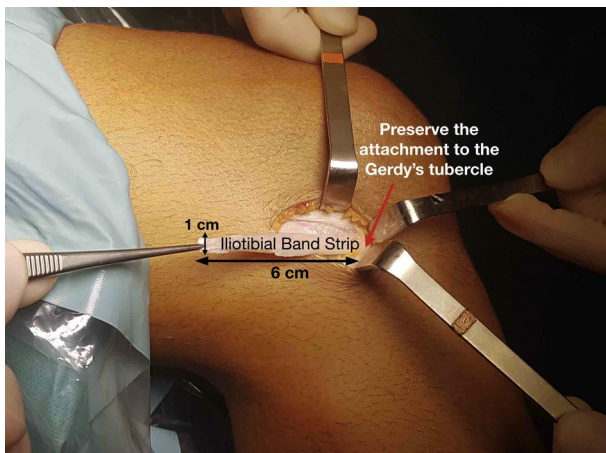


Fig 1. Iliotibial band harvest. Right knee, in decubitus position, with a 90° flexion. The iliotibial band is harvested, making a 1-cm-wide per 6-cm-long strip with a sharp incision, which is elevated, preserving its distal attachment to the Gerdy's tubercle.

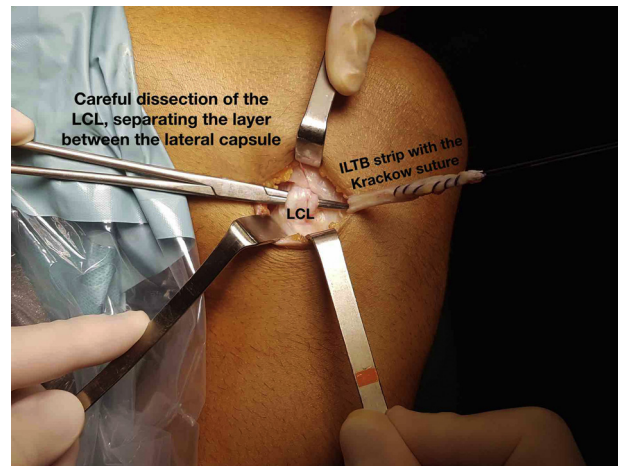


Fig 3. Identification of the lateral collateral ligament (LCL). With the knee flexed at 90°, the LCL is identified using scissors, and a curved clamp/kocher is passed under the LCL. Traction to the curved clamp/kocher is applied to palpate the contour of the ligament and to make sure we are under it.

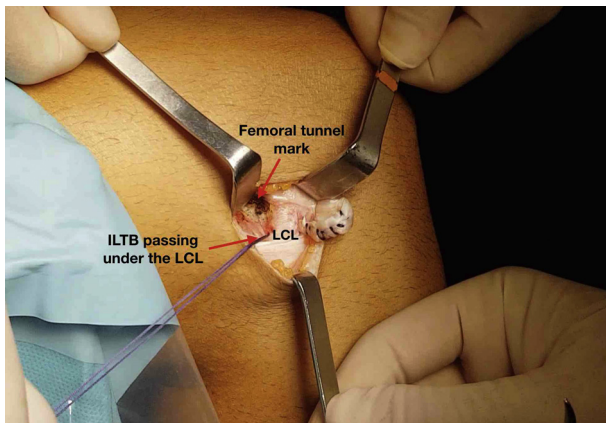


Fig 4. Passing the iliotibial band strip under the lateral collateral ligament. Under 90° of flexion, the free end sutures of the iliotibial band strip are clamped and taken deep to the lateral collateral ligament as a modified Lemaire procedure.

The femoral tunnel is addressed first placing an outside-in femoral ACL guide, connecting the intra-articular anatomic ACL femoral footprint and the previously marked entry point on the lateral cortex of the femur (Fig. 8, femoral footprint). An adequate positioning, distal to the physis, is carefully verified by fluoroscopy (anteroposterior, lateral, and oblique views are used; Fig. 9, oblique fluoroscopic image).

Once the adequate intra-articular position of the guide pin is confirmed, the drill sleeve is malleted through the lateral femoral cortex, ensuring at least a 7-mm bone bridge between the tunnel and the lateral cortex of the femur. We then change the guide pin for an appropriate size FlipCutter, and retrograde drilling is done ensuring a minimum of 20 to 25 mm in length (Fig. 10, change to FlipCutter), guided by fluoroscopy to avoid physeal damage (Fig. 11, FlipCutter guided by fluoroscopy). Then the drill is advanced into the joint, closed, and removed. A FiberStick (Arthrex) is

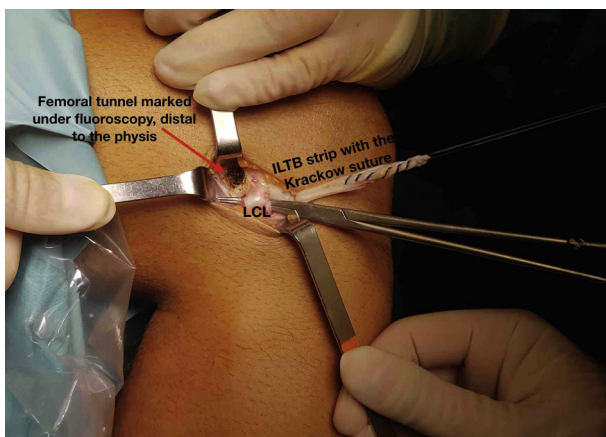


Fig 5. Identification of femoral entry point. Guided by the x-ray intensifier, the femoral guide entry point is confirmed distal to the femoral physeal growth plate.

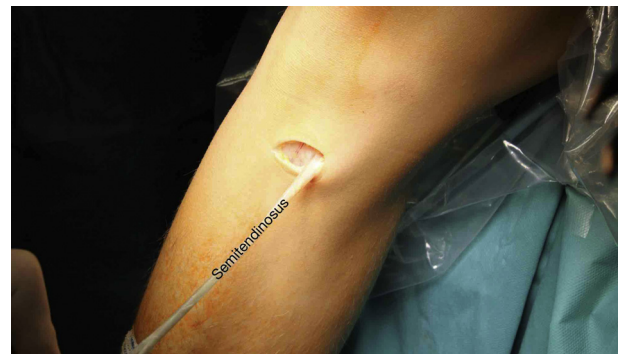

Fig 6. Semitendinosus tendon harvest, decubitus position, right knee flexed at 90°. A 3-cm oblique incision is performed. The sartorius tendon is sharply dissected; the gracilis tendon is identified, and under the gracilis tendon we find the semitendinosus tendon that is harvested with a tenotome stripper.

advanced and delivered out through the anteromedial portal and tagged (Fig. 12, FiberStick is advanced).

Then the tibial tunnel is addressed. The tibial ACL guide, set at 55°, is placed through the anteromedial portal. The guide is seated distal to the tibial physis and just medial to the anterior tibial tuberosity, through the previous incision for the tendon harvest. We first use a 2.9-mm ACL guide pin to ensure a correct positioning (Fig. 13, tibial transphyseal guide pin insertion). Then the drill sleeve is malleted, and an appropriate size FlipCutter is deployed into the joint, creating a single vertical 3.5-mm diameter hole in the tibial physis.

The retrograde drilling is performed controlled by fluoroscopy, ensuring a length of 15 to 20 mm to avoid trespassing the tibial physis (Fig. 14, tibial retrodrill guided by fluoroscopy). A FiberStick is then advanced

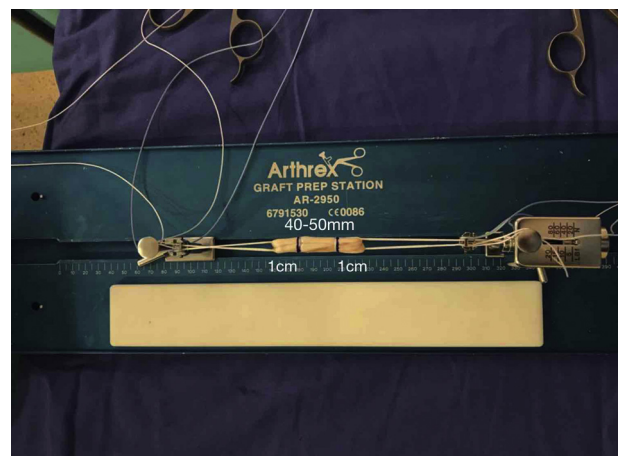

Fig 7. Semitendinosus graft preparation. The graft is prepared using the GraftLink technique (Arthrex) with 2 TightRope RT suture buttons for fixation on the tibia and femur. We achieve a quadrupled graft of a minimum of 40 to 50 mm in length and ≥ 8 mm in diameter. We mark 1 cm on each ends of the graft, for a proper arthroscopic identification.

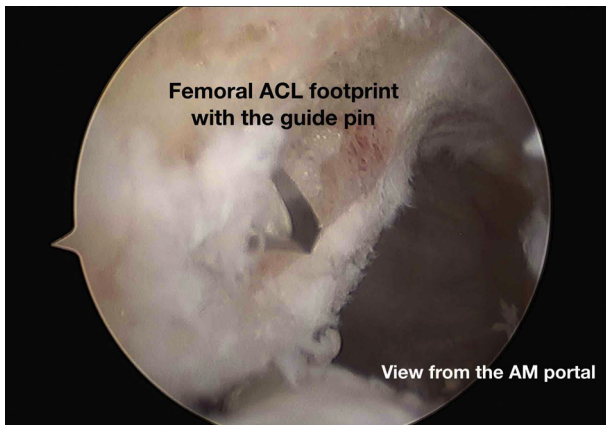


Fig 8. Femoral footprint. In a right knee, using a 30° arthroscope from the anteromedial portal, the femoral footprint is debrided. Then the femoral guide pin is drilled in the anatomic position.

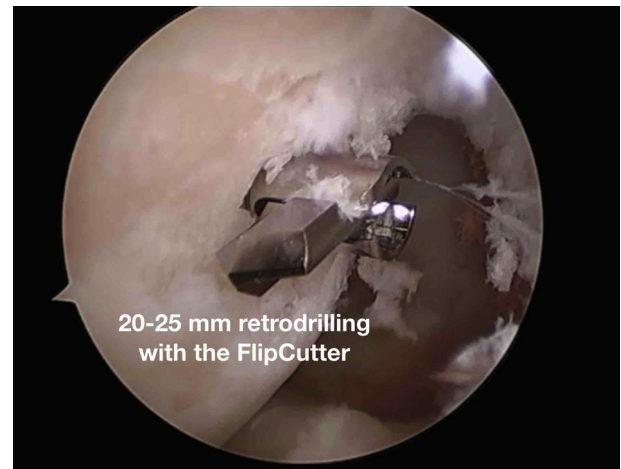

Fig 10. Change to FlipCutter. Viewing from the anteromedial portal, the FlipCutter is drilled and then deployed. Retrodrill begins, and a minimum of 20 to 25 mm is encouraged.

through the tibial tunnel and retrieved through the anteromedial portal and tagged for graft passage.

The femoral side of the graft is passed first through the anteromedial portal. The button is engaged on the lateral femoral cortex, and the graft is pulled into the femoral tunnel. Then the tibial button is retrieved through the tibial tunnel and pulled until the button is engaged on the tibial cortex. We then check that the tibial graft has docked into the tunnel. Under arthroscopic control and with the knee in 20° of flexion, the femoral and tibial buttons (TightRope RT, Arthrex) devices are both tensioned until tight (Fig. 15, new ACL).

Once both buttons are tensioned (Fig. 16, button at both ends), we proceed to fix the ILTB strip to the femoral button. The button (TightRope RT, Arthrex) has 2 nonbraided high-resistance sutures. We use the suture that emerges from the center of the button

(Fig. 17, identifying the central suture of the button). We first mark where the ILTB strip will be placed and knotted. We address this by extending the leg and marking the ILTB at the height of the button. A Krackow suture is now created through the ILTB strip, using a PDS as a guiding suture (Fig. 18, Krackow suture with the central button suture to the ILTB strip). Then both ends are knotted together acting as a sliding suture, and the ILTB strip is fixed to the femoral cortical button with the knee flexed to 30° and held in external rotation (Fig. 19, knotting the Lemaire to the button).

The incisions are irrigated and closed according to standard protocol (Fig. 20, closing and dressing the incision). The knee is dressed with sterile dressings and placed in a hinged knee brace locked in extension. Physical therapy is begun on postoperative day 1, and weight bearing is mandated as tolerated, unless meniscal or cartilage repair dictates the contrary.

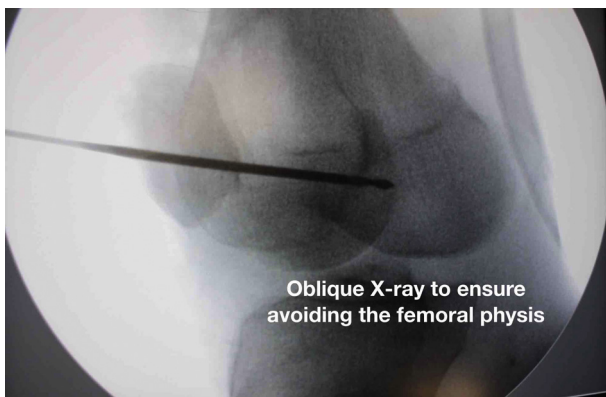


Fig 9. Oblique fluoroscopic image. The femoral guide pin was formerly introduced and with the assistance of the image intensifier, the position distal and safe of the femoral physis is confirmed. Oblique images are encouraged because of the curvilinear shape of the growth physis.

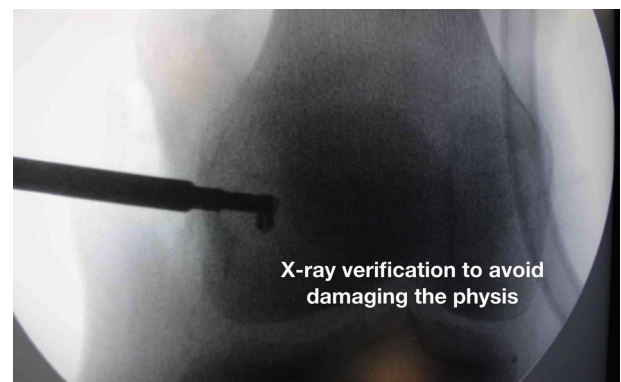

Fig 11. FlipCutter guided by fluoroscopy. The retrodrill is performed under fluoroscopy control to avoid damaging the femoral physis with the blade of the FlipCutter. Again, anteroposterior, lateral, and oblique views are encouraged.

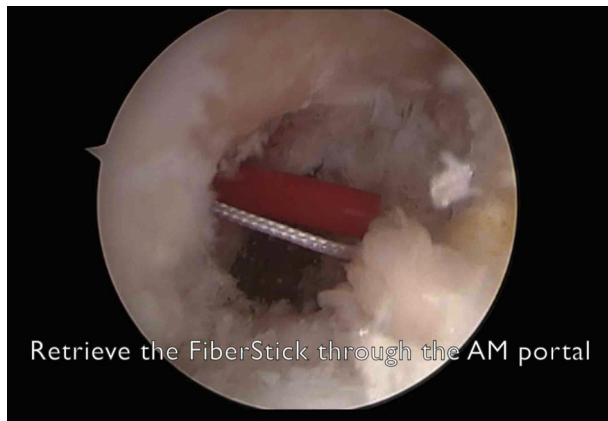


Fig 12. FiberStick is advanced. Viewing from the anterolateral portal, a FiberStick is advanced outside in, and the high-resistance suture is retrieved through the anteromedial portal and tagged for graft passage.

Discussion

In the past, nonoperative treatment of ACL tears in skeletally immature patients was advocated to avoid a possible damage of the physis. Recently, a meta-analysis by Froesh et al.¹¹ reported that growth disturbances occurred in <2% of the patients. Delaying the surgery only 6 to 12 weeks is associated with an increase of 11% to 36% in medial meniscus injuries.³ Unfortunately, ACL tears in prepubescent and pubescent skeletally immature patients are on a rise.^{4,10} The paradigm of young athletes in sports is changing: they are being instilled with a culture of competition, rigorous training sessions, and year-round trainings.¹⁰

Several surgical physeal-sparing or partial sparing surgical techniques have been described. Kocher et al.⁹ reported good outcomes in their initial series using the ILTB strip in an over-the-top position, combining an extra-articular and intra-articular procedure.⁹ Recently,

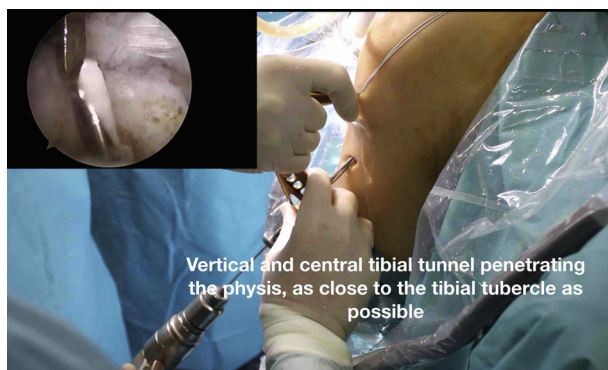

Fig 13. Tibial transphyseal guide pin insertion, in the decubitus position, with the knee flexed at 90°. The tibial guide is set at 55°, and a 2.9-mm anterior cruciate ligament guide pin is drilled, trespassing the tibial growth physis as close to the tibial tubercle as possible. A correct central, vertical, and anatomic position is achieved.

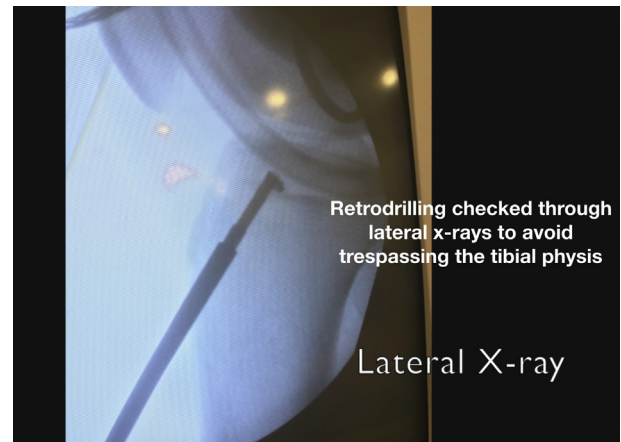


Fig 14. Tibial retrodrill guided by fluoroscopy. Once the tibial guide pin is changed into the FlipCutter, retrodrill begins with the assistance of fluoroscopy without trespassing the tibial growth physis. Again, anteroposterior, lateral, and oblique views are encouraged.

the same authors presented the follow-up on these patients with a sample size of 237 patients, achieving 96.8% grade A Lachman tests, 98.8% grade A pivot shift tests, and reported graft failure in 9 out of 137 knees.¹⁰ The advantages of this surgical technique are no physeal damage and no limb-length discrepancies.¹⁰ The disadvantages were described as a technically demanding, anatomy-distorting procedure and lateral thigh asymmetry in the ILTB harvest site (48%).¹⁰

Other more anatomic procedures have been described. Anderson¹² performed an all-epiphyseal procedure using a button/washer as femoral fixation method and sutures tied to a post as tibial fixation method. The drawbacks of this technique are the tibial fixation method and the eccentric epiphyseal tibial

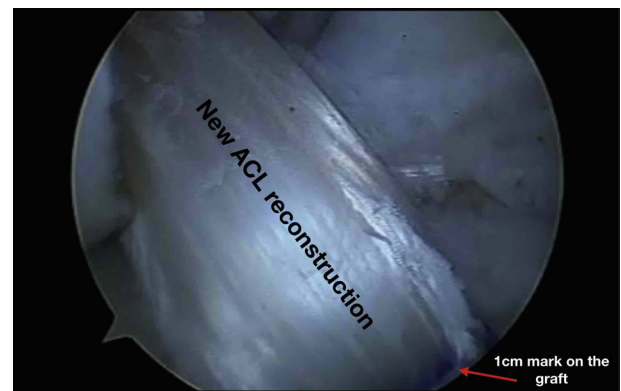


Fig 15. New anterior cruciate ligament, viewing from the anterolateral portal and working from the anteromedial portal. The femoral part of the graft is passed until the femoral button is engaged on the lateral cortex. Then the tibial part of the graft is docked inside the socket and the tibial button is engaged on the tibial cortex. At 20° the femoral and tibial parts of the graft are tensioned until tight.

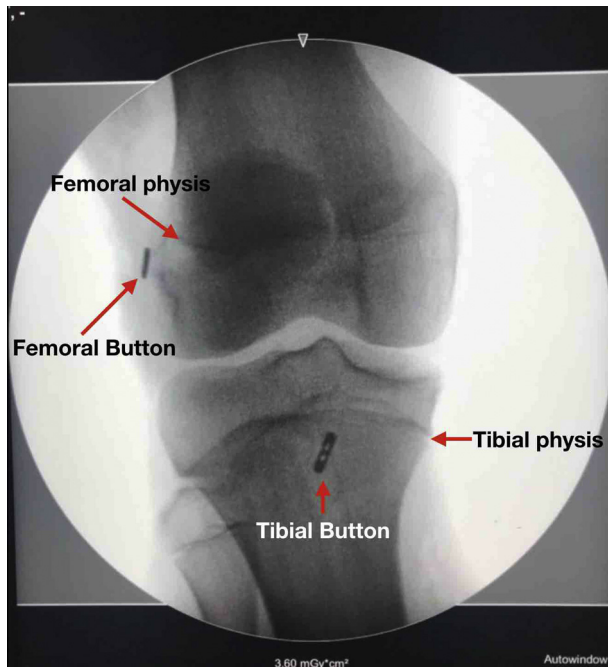


Fig 16. Buttons at both ends. A final anteroposterior intensifier image is performed to confirm the correct position of the buttons.

tunneling. This is a nonanatomic horizontal tunnel, which is short in length and creates a small bone bridge between the tunnel and the medial tibial plateau surface.

Lawrence et al.⁴ described a partial physeal-sparing technique, sparing the femoral physis using the Retro-Drill (Arthrex) and performing a transphyseal retrodrilling on the tibia. Disadvantages include the use of intraoperatively computed tomography scan and a RetroScrew (Arthrex) as a tibial fixation method, which

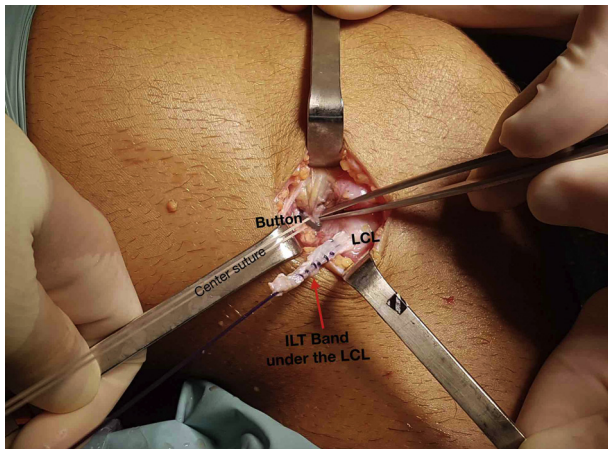


Fig 17. Identifying the central suture of the button, right knee flexed at 90°. From a lateral view, the button is identified as well as the central suture. We can see the lateral collateral ligament distal to the button and the iliotibial band strip posterior to it.

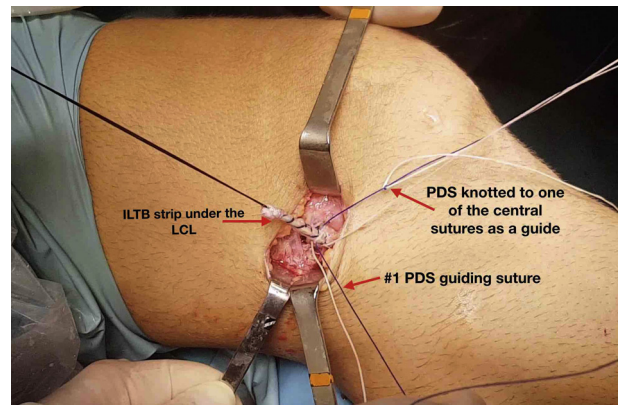


Fig 18. Krackow suture with the central button suture to the iliotibial band strip. From a lateral view, the iliotibial band strip is pulled to facilitate the Krackow suture with a no. 1 PDS (guide suture), knotting it with 1 end of central high-resistance suture from the button.

requires a minimum tunnel length of 20 mm, which can be difficult to achieve in small knees, even when an anatomic, central, and tranphyseal tunnel is done.

Then McCarthy et al.¹³ described the all-inside (Arthrex) and all-epiphyseal technique, sparing both femur and tibial growth physis and using buttons at the femoral and tibial ends as the fixation method. The disadvantage of this technique is the eccentric nonanatomic tibial drilling, as described before.

We describe a partial physeal-sparing ACLR, with cortical buttons at both ends (all-inside, Arthrex) plus a modified Lemaire procedure sutured to the femoral button (Tight-Rope RT, Arthrex). This technique allows an anatomic ACLR with minimal tibial physis damage limited to the width of the FlipCutter (3.5 mm). This tibial tunnel is longer and vertical and the bone bridge between the tunnel and the medial tibial plateau surface is also wider. We decided to add a LET procedure using the ILTB strip sutured to the button to improve rotational stability. The deep LET has emerged as an

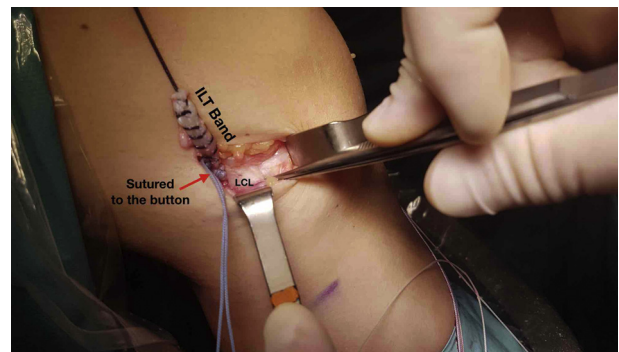


Fig 19. Knotting the modified Lemaire to the button, with the right knee flexed at 30° and external rotation. Both ends of the central suture are tightened and act as a sliding knot, tightening the iliotibial band strip to the button.

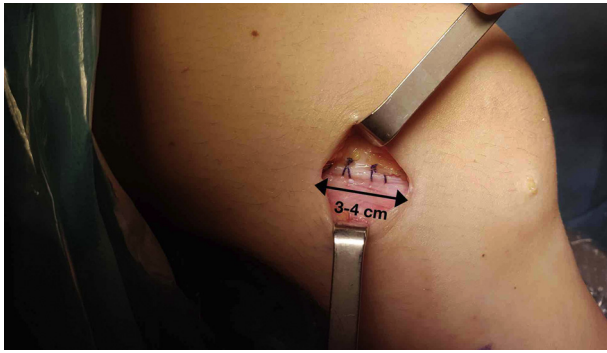


Fig 20. Closing and dressing the incision. The incisions are irrigated and closed according to standard protocol. The iliotibial band fascia is closed, as well as subcutaneous tissue and skin.

interesting procedure in adult patients that can restore rotational instability of the native knee⁸ and reduce the ACL rerupture incidence by up to 2.5 times less than when it is associated with an ACLR.¹⁴

Sonnery-Cottet et al.¹⁴ described indications for ACLR and an associated extra-articular procedure, which include grade III pivot shift, Second fracture, chronic ACL rupture, high sport level, pivoting sports, <25 years old, preoperative side-to-side laxity of 7 mm, lateral femoral notch sign on plain radiographs, and revision ACLR. We believe that we should add to these indications female skeletally immature patients with valgus, recurvatum alignment, and signs of generalized hyperlaxity.

Another important issue is choosing the femoral insertion site of the ILTB strip. Some authors described it to be superior and posterior to the former ACL femoral tunnel⁷; others use the former ACLR femoral tunnel as an attachment point.^{5,14} We decided to suture the ILTB strip to the button, because usually there is not much space on the femoral epiphysis, and placing a bone anchor or an interference screw superior and

posterior to the ACLR tunnel would lead directly to or near the growth physis. Meanwhile, fixing the ILTB proximal to the physis could create a tenodesis effect over the physis and possible growth disturbances. Another point to discuss is the fixation method, which can vary from sutures, bone anchors, or interference screws.^{5,7,14} As explained before, the femoral button includes 2 high-resistance sutures; we use the suture that pulls the graft and externally emerges from the center of the button. One end of this suture is stitched along the ILTB strip with a Krackow suture and tied up with the other free end of the suture, simulating a bone anchor sliding knot function. The sliding knot press fits the ILTB strip to the button and the button to the lateral femoral cortex. We believe that a biological fixation can be achieved due to the bleeding of the tunnel under the femoral button. Finally, using the same button to fix the ACL graft is a cost-effective procedure (Table 1).

The risks of this technique can be easily detected but can also create serious problems. We will describe some of the possible complications and their intraoperative solutions. First of all, the ILTB band harvest should be wide (1 cm) and long (6 cm) enough to pass it deep to the LCL and to achieve the tenodesis at the level of the femoral button. A short ILTB may not reach the desired attachment point. Another risk is the correct identification of the LCL. A pearl is to follow the LCL contour, from its distal attachment on the fibular head to its proximal insertion of the femur. Penetrating the femoral or tibial physis is a feared complication, with no solution; we recommend using a guide pin and fluoroscopic assistance anteroposterior, lateral, and oblique views (Figure 9). Another drawback is in creating a graft >55 mm in length; sometimes you can encounter very small knees that can lead to very short tunnels and future laxity of the ACL graft. As explained before, using the high-resistance suture that emerges from the lateral side of the button can tilt the femoral button and

Table 1. Advantages and Disadvantages of the Technique

Surgical Steps	Advantages	Disadvantages
Anatomic anterior cruciate ligament (ACL) reconstruction Hamstring graft	Restores native ACL footprints (femoral and tibial). Autologous graft, usually only the semitendinosus tendon is needed.	Outside-in adds a lateral incision that can increase morbidity. None. Due to the technique used (all-inside, Arthrex), hamstring graft is the recommended choice.
Tibial socket	Central anatomic tunnel, vertical tunnel, long tunnel (≥ 2 cm), sufficient bone bridge between the tibial tunnel and articular surface of the tibial plateau.	Minimal tibial physeal damage.
Lateral extra-articular tenodesis of the iliotibial band to the button	Adds rotational control to the former ACL; press fixation to the cortical button and femoral cortex; biological fixation can be achieved due to femoral tunnel bleeding; no physeal damage; save costs on material (interference screws, anchors).	Extra lateral incision that adds morbidity, possible micromovement of the iliotibial band, button, and graft.

Table 2. Surgical Steps, Pearls, and Pitfalls

Surgical Steps	Pearls	Pitfalls
Graft harvest, width, and length	Only semitendinosus, width 8 to 9.5 mm, length 40 to 50 mm (no more).	Width < 8 mm; length > 50 mm.
Femoral socket	3-cm oblique incision directed to Gerdy's tubercle, pin entry site distal to physis, fluoroscopic control.	Penetrating or damaging the the physis with pin or retrodrill; not leaving enough bone bridge on the lateral femoral cortex.
Tibial socket	Central, anatomic tunnel; pin entry site distal to physis; use an initial guide normal guide anterior cruciate ligament guide pin; deploy the FlipCutter facing posteriorly; fluoroscopic control.	Damage to the intermeniscal ligament or tibial plateau; penetrate the physis; breakage of FlipCutter when started in direct contact with tibial spines.
Iliotibial band strip to the button	1-cm width and 6-cm length; dissect lateral collateral ligament; pass the iliotibial band deep to the lateral collateral ligament near its proximal insertion; use the suture that emerges from the center of the button, to stitch it to the iliotibial band strip.	Use the suture that comes out from the lateral end of the button. This will tilt the button from 1 side.

will not be press fitted to the lateral femoral cortex (Table 2). Finally, we are concerned that possible micromovements can occur in the button due to the pulling effect of the ILTB strip and the ACL graft with the knee flexion and extension. This may lead to future inadequate fixation or ACL graft rupture. However, this is only a theory that has yet to be proven.

References

- Milewski MD, Beck NA, Lawrence JT, Ganley TJ. Anterior cruciate ligament reconstruction in the young athlete: A treatment algorithm for the skeletally immature. *Clin Sports Med* 2011;30:801-810.
- Eiskjær S, Larsen ST, Schmidt MB. The significance of hemarthrosis of the knee in children. *Arch Orthop Trauma Surg* 1988;107:96-98.
- Lawrence JTR, Argawal N, Ganley TJ. Degeneration of the knee joint in skeletally immature patients with a diagnosis of an anterior cruciate ligament tear: Is there harm in delay of treatment? *Am J Sports Med* 2011;39:2582-2587.
- Lawrence JTR, Bowers AL, Belding J, Cody SR, Ganley TJ. All-epiphyseal anterior cruciate ligament reconstruction in skeletally immature patients. *Clin Orthop Relat Res* 2010;468:1971-1977.
- Gomes JLE, Leie MA, Marczwski M, Sánchez G, Ferrari MB. Intra-articular anterior cruciate ligament reconstruction with extra-articular lateral tenodesis of the iliotibial band. *Arthrosc Tech* 2017;6:e1507-e1514.
- Hinton RY, Rivera VR, Pautz MJ, Sponseller PD. Ligamentous laxity of the knee during childhood and adolescence. *J Pediatr Orthop* 2008;28:184-187.
- Williams A, Ball S, Stephen J, White N, Jones M, Amis A. The scientific rationale for lateral tenodesis augmentation of intra-articular ACL reconstruction using a modified "Lemaire" procedure. *Knee Surg Sport Traumatol Arthrosc* 2017;25:1339-1344.
- Inderhaug E, Stephen JM, Williams A, Amis AA. Biomechanical comparison of anterolateral procedures combined with anterior cruciate ligament reconstruction. *Am J Sports Med* 2017;45:347-354.
- Kocher MS, Garg S, Micheli LJ. Physeal sparing reconstruction of the anterior cruciate ligament in skeletally immature prepubescent children and adolescents. *J Bone Joint Surg Am* 2005;87:2371-2379.
- Kocher MS, Heyworth BE, Fabricant PD, Tepolt FA, Micheli LJ. Outcomes of physeal-sparing ACL reconstruction with iliotibial band autograft in skeletally immature prepubescent children. *J Bone Joint Surg* 2018;100:1087-1094.
- Frosch K, Stengel D, Brodhun T, et al. Outcomes and risks of operative treatment of rupture of the anterior cruciate ligament in children and adolescents. 2010;26:1539-1550.
- Anderson AF. Transepiphyseal replacement of the anterior cruciate ligament using quadruple hamstring grafts in skeletally immature patients. *J Bone Joint Surg Am* 2004;86:201-209 (Suppl, Pt 2).
- McCarthy MM, Graziano J, Green DW, Cordasco FA. All-epiphyseal, all-inside anterior cruciate ligament reconstruction technique for skeletally immature patients. *Arthrosc Tech* 2012;1:e231-e239.
- Sonnery-Cottet B, Saithna A, Cavalier M, et al. Anterolateral ligament reconstruction is associated with significantly reduced ACL graft rupture rates at a minimum follow-up of 2 years: A prospective comparative study of 502 patients from the SANTI Study Group. *Am J Sports Med* 2017;45:1547-1557.