

Comparison of efficacy of thoracic paravertebral block with oblique subcostal transversus abdominis plane block in open cholecystectomy

Seema Jindal, Gurkaran Kaur Sidhu, Gurpreet Kaur Baryha¹, Baltej Singh², Samiksha Kumari, Rupali Mahajan

Department of Anaesthesia and Intensive Care, Guru Gobind Singh Medical College and Hospital, Faridkot, ¹Department of Anaesthesia and Intensive Care Fortis Hospital, Mohali, ²Department of Social and Preventive Medicine, Guru Gobind Singh Medical College and Hospital, Faridkot, Punjab, India

Abstract

Background and Aims: Sensory afferent nerve branches of lower six thoracic and upper lumbar nerves innervate the anterior abdominal wall and are the therapeutic focus of local anesthetics to provide analgesia for the abdominal surgical incision. Central neuraxial and regional analgesia can provide better control of pain due to right subcostal incision used in open cholecystectomy and attenuate the need for opioids. The earlier studies which showed the benefit of the thoracic paravertebral block (TPVB) for analgesia after upper abdominal surgeries did not compare TPVB with oblique subcostal transversus abdominis plane (OSTAP) block. Therefore, the current study compares the analgesic efficacy of TPVB and OSTAP block in open cholecystectomy.

Material and Methods: Seventy consenting adults scheduled for open cholecystectomy were allocated to one of the two groups: ultrasound-guided TPVB (Group I) and ultrasound-guided OSTAP block (Group II). The primary objective of this study is to assess and compare tramadol consumption in 48 h in both the groups along with VAS in post anaesthesia care unit, and then at 2, 4, 6, 8, 12, 24, and 48 h. The secondary objective of the study is to assess the incidence of PONV.

Results: The number of doses of rescue analgesia required was less in Group I when compared with Group II ($P < 0.001$). Patients in Group I had significantly lower pain scores than Group II. Although in the initial 8 h, both groups had comparable pain scores, after 8 h, these scores were significantly lower in patients in Group I. Less postoperative nausea and vomiting was seen in Group I patients (11.7%) in comparison to Group II (18.1%).

Conclusion: Ultrasound-guided TPVB is superior to OSTAP block because of its association with decreased postoperative opioid consumption, lower VAS score, and reduction in opioid-related side effects. Thus, it should be strongly considered as a part of multimodal analgesia regimen in upper abdominal surgeries.

Keywords: Analgesia, levobupivacaine, open cholecystectomy, postoperative nausea and vomiting, visual analog scale

Introduction

Postoperative pain relief has always been an important aspect of anesthetic management. Pre-emptive analgesia blocks nociception induced central sensitization.^[1] The right sub-costal incision of open cholecystectomy results in

moderate-to-severe postoperative pain because of input from the skin, the deep somatic structures, and the associated viscera.^[2] This intense postoperative pain has been modified with parenteral opioids, thoracic epidural analgesia, and nonsteroidal antiinflammatory drugs in various previous

Address for correspondence: Dr. Gurkaran Kaur Sidhu, Department of Anaesthesia and Intensive Care, Guru Gobind Singh Medical College and Hospital, Faridkot - 151203, Punjab, India. E-mail: sugarsidhu2007@outlook.com

This is an open access journal, and articles are distributed under the terms of the Creative Commons Attribution-NonCommercial-ShareAlike 4.0 License, which allows others to remix, tweak, and build upon the work non-commercially, as long as appropriate credit is given and the new creations are licensed under the identical terms.

Access this article online	
Quick Response Code:	Website: www.joacp.org
	DOI: 10.4103/joacp.JOACP_148_19

For reprints contact: WKHLRPMedknow_reprints@wolterskluwer.com

How to cite this article: Jindal S, Sidhu GK, Baryha GK, Singh B, Kumari S, Mahajan R. Comparison of efficacy of thoracic paravertebral block with oblique subcostal transversus abdominis plane block in open cholecystectomy. J Anaesthesiol Clin Pharmacol 2020;36:371-6.

Submitted: 20-May-2019 Revised: 10-Nov-2019 Accepted: 08-Jan-2020
Published: 26-Sep-2020

studies.^[3] The standard practice in our hospital for cholecystectomy includes general anesthesia (GA) along with intravenous (IV) opioids and nonsteroidal antiinflammatory drugs as analgesics intraoperatively and in the postoperative period. However, opioids are associated with deleterious effects such as nausea, constipation, pruritus, sedation, and occasionally respiratory depression. TPVB or OSTAP block as a part of multimodal analgesia regimen can provide better pain control in the postoperative period as they attenuate the need for opioids and occurrence of chronic postoperative pain.^[4] Sensory afferent nerve branches of lower six thoracic and upper lumbar nerves are the therapeutic focus of local anesthetics to provide analgesia for the abdominal surgical incision.^[5] The present study examines the superiority of one block over another with regard to analgesia and decrease in postoperative nausea and vomiting (PONV).

Material and Methods

This prospective, randomized study was approved by the Institutional Ethics Committee, reference number GGSMC/IEC/16/32 dated June 6, 2016. CTRI/2017/02/007936. After providing written informed consent, 70 American Society of Anesthesiologists (ASA) grade I–III patients of both genders in the age group of 18–60 years in a tertiary care hospital who were scheduled to undergo elective open cholecystectomy due to surgical indications under general anesthesia (GA) between October 2016 and September 2017 were enrolled in the study. Exclusion criteria were patient's refusal, intellectual disability, and any contraindication for regional anesthesia like infection at the puncture site, anatomical deformities such as kyphoscoliosis and coagulation disorders. All patients were kept fasting overnight and premedicated with alprazolam 0.25 mg and ranitidine 150 mg per oral the night before and 2 h before surgery. Patients were randomized by using a computer-generated random number table and randomly allocated in the ratio of 1:1 to one of the two groups using sealed opaque envelopes that were opened after enrolment of patients. Two first authors enrolled the participants and performed all the blocks and were not involved in data collection. The authors who performed the blocks were well versed with the techniques and had conducted at least 50 blocks. Group I received GA followed by TPVB under ultrasound guidance (MyLab™ One for regional anesthesia, Model No.SL3323 Esaote Netherlands Europe B.V.) with single injection using 0.3 mL/kg (maximum dose of 150 mg) of 0.5% levobupivacaine yielding a total dose of 1.5 mg/kg. The drug was given gradually after negative aspiration in small aliquots of 5 mL each over a minimum of 1 min at the level of T7. Group II received GA followed by OSTAP

block under ultrasound guidance using 0.6 mL/kg of 0.25% levobupivacaine yielding a total dose of 1.5 mg/kg.

Anesthesia was induced with injection morphine 0.1 mg/kg IV (1 mg/kg of tramadol equivalents) as a standard protocol in all the patients followed by propofol 1.5–2.0 mg/kg IV until loss of verbal response. Tracheal intubation was facilitated by vecuronium 0.1 mg/kg IV. Anesthesia was maintained with isoflurane (minimum alveolar concentration 1.0–1.3) and nitrous oxide 66% in oxygen. All the patients were monitored using Drager Primus® workstation. All the essential monitors were attached such as five lead electrocardiogram, noninvasive blood pressure, pulse oximetry, and ETCO₂. Heart rate and mean arterial pressure (MAP) were monitored every 5 min throughout the surgery. Crystalloids were used to treat any fall in the MAP below 60 mmHg. A note was made of the number of doses of mephenteramine used intraoperatively. Injection atropine 20 µg/kg bolus was given IV if the heart rate was <50 beats/min. Injection fentanyl was given at a dose of 0.5 µg/kg IV (0.5 mg/kg IV of tramadol equivalents) as rescue analgesia in case there was a rise in HR or MAP of more than 20% of baseline persisting for 5 min. Toward the end of the surgery, injection diclofenac sodium 1.5 mg/kg and ondansetron 0.1 mg/kg IV were given to all the patients as a standard protocol. At the onset of spontaneous respiration, injection neostigmine and glycopyrrolate were given and the trachea was extubated.

Both blocks were placed under ultrasound guidance after the induction of GA. The site of the block was sterilized with povidone-iodine before the procedure and the linear probe (MyLab™ One) was protected with a sterile cover. The spinous process of T₇ was tracked by placing an ultrasound linear probe (6–13 Hz) longitudinally parallel and medially with the patient lying in the left lateral position. The seventh thoracic vertebral level was identified by palpating and counting down from vertebrae prominens (C7) and the transverse process was searched by turning the probe laterally which appeared hyperechoic. The transverse process appeared squared and lay deeper than the ribs. The costotransverse ligament (CTL) along with proximal and distal pleura seen as echogenic line served as a landmark of wedge-shaped paravertebral space. To prevent pneumothorax, 23G spinal needle was attached to a closed system with fluid-filled tubing and was introduced in plane/out of plane. Distinctive loss of resistance was felt when the needle passed through CTL. Intravascular injection was eliminated by negative aspiration. About 1–2 mL of saline was administered to see the displacement of pleura downwards that confirmed the position of the needle in the right place and hence the success of block. To perform the OSTAP block with the operator standing on the left side of the patient, a linear 6–13 MHz ultrasound transducer was placed obliquely near the costal

margin and xiphoid process, and the rectus abdominis muscle, rectus sheath, and underlying transversus abdominis muscle were identified on the right hemi abdomen. A spinal needle of 23G was inserted 2–3 cm from the probe using the in-plane technique. TAP was accessed by placing the needle adjacent to costal margin but medial to linea semilunaris. The needle was advanced slowly in-plane to promote hydrodissection along the oblique subcostal line. This hydro dissection technique might result in more effective analgesia.^[6]

The patients were observed and assessed in the post anesthesia care unit (PACU) and at different time intervals by an anesthesiologist unaware of patient group assignment. Visual analog scale (VAS) rated 0 (no pain) to 10 (worst possible pain) was used to evaluate pain at rest, on movement, and on coughing, at the time of arrival in PACU and then at 2, 4, 8, 12, 24, and 48 h. The criteria used to rate pain during movement were (a) deep breathing and coughing and (b) changing posture from supine to sitting position. A score of 0 was given to a patient who was asleep. It was ensured to rate VAS without the patient receiving prior rescue analgesia. Injection tramadol 100 mg IV was prescribed as the first dose to patients demanding rescue analgesia or to those having pain score more than 3. The consecutive doses of tramadol, if needed, were 50 mg IV. After 24 h, patients were switched to 50 mg of oral tramadol. We defined “adequate pain relief” as VAS less than or equal to 3 consistently (no intervention required) throughout the observation period. The amount of tramadol consumed postoperatively in 48 h along with the time of first rescue analgesia, i.e. tramadol, was observed.

A categorical scoring scale (0 = none, 1 = mild, 2 = moderate, 3 = severe) was used to assess the degree of PONV. Mild is defined as one episode of vomiting with short-lasting nausea and no antiemetic required. Moderate is defined as one to two episodes of vomiting and onetime antiemetic used for each episode. Severe is defined as more than two episodes of vomiting with severe nausea and antiemetic used for each episode. Vomiting and retching were not differentiated. Injection metoclopramide 10 mg IV was given to any patient who had nausea score ≥ 2 . The number of patients free of nausea and vomiting was assessed. The patients were requested to document VAS, episode of nausea and vomiting, the requirement of rescue analgesia, duration of analgesia, and for any complication. In addition, the patients were asked to rate their satisfaction regarding pain control based on a 5-point Likert-type scale, with 5 indicating “excellent,” 4 “very good,” 3 “good,” 2 “fair,” and 1 “poor.” This type of scale is often assumed to be an equal-interval scale, where “excellent” is one unit better than “very good,” “very good” is one unit better than “good” and so on.^[7] The time taken to position the patient

and the time to carry out either of the blocks were noted. In addition, any side effects related to blocks like pneumothorax, local anesthetic toxicity, and injury to vascular or nervous structures were noted during the study.

Calculation of sample size was based on the pilot study done on seven patients in each group. Mean tramadol consumption of TPVB (Group I) was 102.85 ± 18.89 mg and in OSTAP block (Group II) was 128.57 ± 39.33 mg. Considering the coefficient of variance of 0.3 with the observed reduction of 20% in mean tramadol consumption in TPVB, the sample size comes out to be 29 patients in each group [using formula $n = \frac{16(CV)^2}{(\ln \mu_1 - \ln \mu_2)^2}$].^[8] To include the possible dropouts, 35 patients were enrolled in each group.

Variables such as age, weight, duration of surgery, duration of block, and VAS are normally distributed (normality plot on SPSS), expressed as mean (SD), and analyzed using unpaired *t*-test. The cumulative pain score is expressed as median (IQR) and presented as a box plot. Kaplan–Meier survival is used to analyze the proportion of patients at different time intervals for the pain-free period. All the analyses were performed using SPSS version 16.0 for windows (SPSS Inc., Chicago, IL, USA), and a $P < 0.05$ was considered statistically significant.

Results

Sixty seven out of 70 enrolled patients completed the study. There was a dropout of one patient in Group I and two patients in Group II who underwent extended cholecystectomy. All the patients enrolled in the study were subjected to open cholecystectomy. Patients in both groups were hemodynamically stable, and none of the patients required mephenteramine intraoperatively. Both groups were comparable with regard to ASA status, age, weight, and duration of surgery [Table 1]. None of the patients required intraoperative fentanyl as rescue analgesia. The total duration to perform the block was relatively more in TPVB

Table 1: Patient characteristics

	Group I (n=34)	Group II (n=33)	P
Age (year)	44.7 (12.8)	43.4 (11.4)	0.334
Weight (kg)	60.2 (5.8)	59.0 (3.6)	0.176
ASA grade (I/II/III)	16/13/5	17/13/3	-
Gender (male/female)	10/24	13/20	-
Duration of surgery (min)	60.2 (5.2)	62.1 (4.6)	0.061
Duration of Block (min)	11.0 (1.3)	10.4 (2.2)	0.081

All variables except ASA status and Gender are expressed as mean (SD). Group I stands for the group that received TPVB. Group II stands for the group that received OSTAP block

than OSTAP block, but the difference was not statistically significant ($P = 0.081$) [Table 1]. The mean tramadol consumption in 48 h was less in Group I (116.18 ± 23.74) when compared to Group II (142.42 ± 28.29) and the difference was statistically significant ($P = 0.000$). The mean VAS score was lower in TPVB group than OSTAP group at PACU and 2, 4, 8, 12, 24, and 48 h at rest, coughing, and on movement [Table 2]. The mean time to first rescue analgesia in the form of tramadol was 18.03 ± 5.50 h in Group I and 10.29 ± 4.55 h in Group II. The 95% confidence interval for time to first rescue analgesia was 5.3–10.1 h ($P = 0.000$). The incidence of PONV was more in Group II as compared to Group I but the difference was not statistically significant (18.1% in Group II vs. 11.7% in Group I, $P = 0.29$). Both the groups were similar regarding patient satisfaction and the difference was not statistically significant (Group I 3.9 ± 0.6 , Group II 3.8 ± 0.4 , $P = 0.122$). The difference between the two groups was statistically significant concerning the quality of postoperative analgesia. [Figure 1] None of the patients suffered from any complications like pneumothorax, inadvertent vascular puncture, or local anesthetic toxicity.

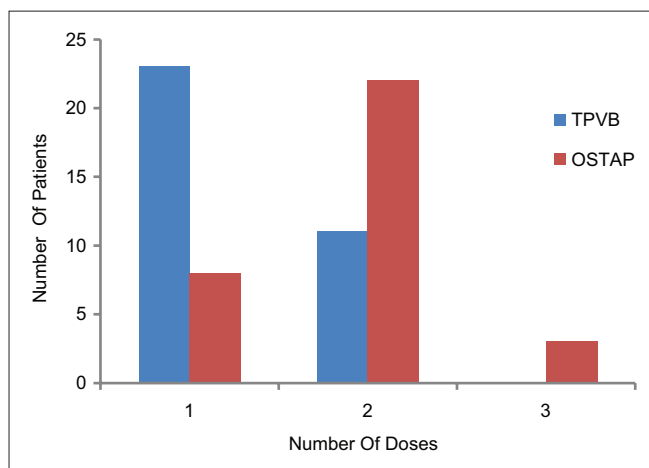


Figure 1: Comparison of number of doses of rescue analgesia between the two groups

Discussion

Use of regional anesthesia and analgesia is advocated in situations of pain and to tackle the neuroendocrine stress response to trauma. In a cohort study done by Gerbershagen *et al.*, open cholecystectomy was found to result in the highest pain intensity in which substantial constituent of pain is derived from the upper anterior abdominal wall incision.^[2,9] Satisfactory outcome after major abdominal surgery largely depends on adequate pain relief. Studies that showed benefit of using TPVB for analgesia after upper abdominal surgeries did not compare this technique with OSTAP block.^[10]

The foremost inference of this randomized prospective study was a remarkable enhancement of postoperative analgesia following open cholecystectomy in patients treated with TPVB compared with patients who received OSTAP block. Effective pain relief was achieved in both the blocks in the initial postoperative period. However, beyond initial 8 h, patients in OSTAP group demanded rescue analgesia on coughing and movement. Our findings are consistent with those of Yiquan and Fuli and Mcmorrow *et al.* who found analgesic efficacy of 6 h after OSTAP block in patients undergoing radical gastrectomy and caesarean sections, respectively. The reasons for a slight difference in duration may be due to VAS score measured at different time intervals when compared with our study. Moreover, Mcmorrow *et al.* used a landmark-based approach when compared with our study which is ultrasound-guided where sonoanatomy is more clearly defined as the spread of local anesthetic are not the same between two approaches.^[11,12] In our study, the analgesic efficacy of TPVB was 18 h at rest which is similar to the study done by Bhuvaneshwari *et al.* in patients undergoing mastectomy after single-shot TPVB using 0.5% bupivacaine.^[13] Bonder *et al.* also confirmed that single-shot TPVB provides analgesia up to 18 h.^[14] However, on coughing and movement, the analgesic effect of TPVB in our study lasted for 12 h in contrast to the study done by Greengrass *et al.* where analgesic effect lasted for 18 h. The discrepancy

Table 2: Comparison of VAS at different time intervals

VAS	Groups	PACU	2 h	4 h	8 h	12 h	24 h	48 h
AT	Group.I	0±0	0.15±0.36	0.161±0.77	1.32±0.64	1.67±0.72	1.52±0.70	0.88±0.59
REST	Group.II	0±0	0.18±0.39	0.69±0.58	1.63±0.99	2.63±1.47	2.57±1.00	1.18±0.88
	P	-	0.706	0.638	0.236	0.000*	0.000*	0.141
AT	Group.I	0.03±0.17	0.41±0.74	1.26±0.86	2.12±0.54	3.56±1.33	2.50±1.60	1.88±0.54
MOVE-	Group.II	0.00±0.00	0.60±0.50	1.66±0.54	3.82±0.63	2.24±1.56	4.30±1.40	1.64±0.74
MENT	P	0.321	0.212	0.061	0.000*	0.010*	0.000*	0.053
AT	Group.I	0.03±0.17	0.47±0.75	1.71±0.67	2.88±0.33	3.65±1.23	2.68±1.65	2.23±0.50
COUGH-	Group.II	0.00±0.00	0.70±0.47	1.88±0.73	3.79±1.57	2.24±1.56	4.36±1.36	2.00±0.75
ING	P	0.321	0.141	0.322	0.010*	0.000*	0.000*	0.061

Results are means±SD. Group I received an ultrasound-guided TPVB on right side with 0.3 ml/kg of 0.5% levobupivacaine and GA; Group II received an ultrasound-guided OSTAP block with 0.6 ml/kg of 0.25% levobupivacaine on right side and GA. *P<0.05

may be due to the multilevel technique and use of epinephrine along with 0.5% bupivacaine in their study.^[15] Adrenaline is known for its intrinsic analgesic quality. The duration of action of local anesthetics is prolonged by epinephrine because of a decrease in the rate of absorption.^[16,17] Although multilevel technique logically prolongs the duration of analgesia, at the same time, the risk of complications per patient also increases. Therefore, single-level TPVB was used in our study.^[18]

TPVB is found to be more effective in relieving the postoperative pain in upper abdominal surgery because of its profound analgesic coverage in the first 12 h. Our study correlates with studies done by Ruqaya and Eldahshan and Niraj *et al.* in which the time to first-rescue analgesia in TPVB group was longer than that of OSTAP group [Figure 2].^[19,20]

Our study demonstrates that the number of doses of tramadol required was less in TPVB group when compared with OSTAP group and the difference was statistically significant ($P = 0.000$) [Figure 1]. Our findings are consistent with those of Melnikov *et al.* and Kaya *et al.* who found the same results in patients undergoing major gynecological and inguinal hernia surgeries.^[21,22] In the study done by Schnabel *et al.*, the number of patients demanding opioids in the postoperative period was less in TPVB combined with GA group when compared with GA alone.^[23] The decreased requirement of tramadol as a rescue analgesia in TPVB may be attributed to efficacious block of the sympathetic chain and inhibition of somatosensory evoked potential at the site of injection.^[24] [Figure 3].

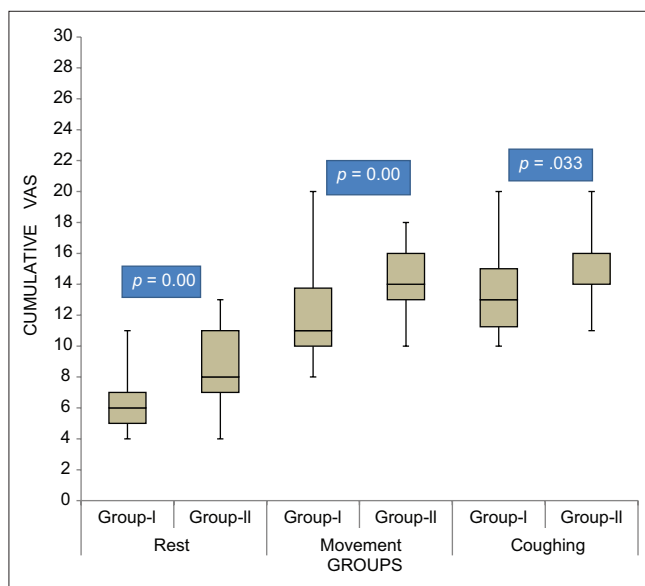


Figure 2: Cumulative pain scores for 48 h at rest, movement, and coughing. The line within each box indicates the median. The lower and upper limits of the box are 25th and 75th centiles. The lines extending above and below the box are 10th and 90th centiles

The remarkably enhanced quality of pain relief and decreased occurrence of PONV in the postoperative period have been seen in patients receiving TPVB. The results of this study concerning PONV showed a low incidence (11.7%) in TPVB when compared with OSTAP group (18.1%). Ruqaya and Eldahshan and Melnikov *et al.* also found a decreased requirement of antiemetics (21%) in PVB group when compared with TAP group (42%).^[19,21] The difference in incidence can be attributed to the absence of prophylactic antiemetic in their study.

Jenkins and Lahay recommended central α adrenergic mechanism as a stimulant for nausea and vomiting.^[25] The principal source of nausea is pain which is frequently neglected. Nausea usually precedes administration of opioid medication. Inadequate pain relief leads to persistence of nausea.^[26] In this study, patients receiving TPVB had less postoperative nausea despite giving prophylactic antiemetic in both the groups, the reason being a more pain-free interval in TPVB than OSTAP group.

Apart from providing splanchnic and somatic analgesia, TPVB also provides a platform between neuraxial blocks and abdominal wall plane blocks for major open abdominal surgeries. It also provides more substantial coverage of abdominal wall than OSTAP block.^[27] In OSTAP block, there is diversity and relative variability in the trajectory of uppermost thoracolumbar nerves (T6–T8) as they arise underneath the rectus muscle and traverse between transversus abdominis muscle and the posterior rectus sheath for a variable distance before piercing anteriorly into the rectus muscle. But, sometimes these nerves may be missed when the block is performed between rectus abdominis muscle and posterior rectus sheath because of their direct entry into rectus muscle.^[28] The limitation of this study was that we did not make any

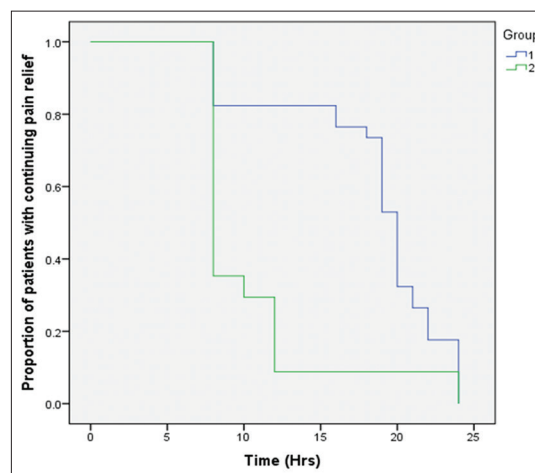


Figure 3: Kaplan Meir showing proportion of patients in each group with continuous pain relief until the administration of first rescue analgesic

sensory block assessment. However, VAS pain score and opioid consumption are more reliable indicators of analgesic effectiveness of TPVB and OSTAP blocks rather than sensory levels. Another limitation is that baseline pain scores have not been assessed.

Conclusion

Ultrasound-guided TPVB has appeared superior to OSTAP block because of its association with lower pain scores, decreased postoperative opioid requirements, and reduction in opioid-related side effects, i.e., PONV.

Financial support and sponsorship

Nil.

Conflicts of interest

There are no conflicts of interest.

References

- Aida S, Baba H, Yamakura T, Taga K, Fukuda S, Shimogi K. The effectiveness of pre-emptive analgesia varies according to the type of surgery: A randomized, double blind study. *Anesth Analg* 1999;89:711-6.
- Gerbershagen HJ, Aduckathil S, Van Wijck AJM. Pain intensity on the first day after surgery. A prospective cohort study comparing 179 surgical procedures. *Anesthesiology* 2013;118:934-44.
- Bigler D, Dirkes W, Hansen R, Rosenberg J, Kehlet H. Effects of thoracic paravertebral block with bupivacaine versus combined thoracic epidural block with bupivacaine and morphine on pain and pulmonary function after cholecystectomy. *Acta Anaesthesiol Scand* 1989;33:561-4.
- Grass JA. The role of epidural anaesthesia and analgesia in postoperative outcome. *Anaesthesiol Clin N Am* 2000;18:407-28, viii.
- Aveline C, Hetet HL, Roux AL, Vautier P, Cognet F, Vinet E, et al. Comparison of ultrasound-guided transversus abdominis plane and conventional ilioinguinal/iliohypogastric nerve blocks for day case open inguinal hernia repair. *Br J Anaesth* 2011;106:380-6.
- Maeda A, Shibata SC, Wada H, Marubashi S, Kamibayashi T, Eguchi H, et al. The efficacy of continuous subcostal transversus abdominis plane block for analgesia after living liver donation: A retrospective study. *J Anesth* 2016;30:39-46.
- Otani K, Waterman B, Faulkner KM, Boslaugh S, Dunagan S. Patient satisfaction: Focussing on "excellent." *J Healthcare Manage* 2009;54:93-102.
- Vanbelle G. *Statistical Rules of Thumb*. 2nd ed. Seattle, WA: John Wiley and Sons; 2008.
- Bhatia N, Arora S, Jyotsna W, Kaur G. Comparison of posterior and subcostal approaches to ultrasound-guided transverse abdominis plane block for postoperative analgesia in laparoscopic cholecystectomy. *J Clin Anesth* 2014;26:294-9.
- Ortiz J, Suliburk JW, Wu K, Bailard NS, Mason C, Minard CG, et al. Bilateral transversus abdominis plane block does not decrease postoperative pain after laparoscopic cholecystectomy when compared with local anaesthetic infiltration of trocar insertion sites. *Reg Anaesth Pain Med* 2012;37:188-92.
- Yiquan W, Fuli L. The analgesic efficacy of subcostal TAP block compared with thoracic epidural analgesia and intravenous opioid analgesia after radical gastrectomy. *Anaesth Analg* 2013;117:507-13.
- Mcmorrow RCN, Ni Mhuirheartaigh RJ, Ahmed KA, Aslani A, Ng SC, Conrick-Martin I, et al. Comparison of transversus abdominis plane block versus spinal morphine for pain relief after Caesarean section. *Br J Anaesth* 2011;106:706-12.
- Bhuvaneshwari V, Wig J, Mathew PJ, Singh G. Post-operative and analgesic requirement after paravertebral block for mastectomy: A randomized controlled trial of different concentration of bupivacaine and fentanyl. *Indian J Anesth* 2012;56:34-9.
- Bonder A, Szucs S, Iohom G. Thoracic paravertebral blockade. *Med Ultrasonogr* 2010;12:223-7.
- Greengrass R, O'Brien F, Lysterly K, Hardman D, Gleason D, D'Ercole F, et al. Paravertebral block for breast cancer surgery. *Can J Anaesth* 1996;43:858-61.
- Bromage PR, Camporesi EH, Durant PA. Influence of epinephrine as an adjuvant to epidural morphine. *Anesthesiology* 1983;58:257-62.
- Collins JG, Kitanata LM, Matsumoto M. Spinally administered epinephrine suppresses noxiously evoked activity of WDR neurons in dorsal horn of spinal cord. *Anesthesiology* 1984;60:269-75.
- Patel LP, Sanghvi PR, Agarwal MB, Prajapati GC, Patel BM. Thoracic paravertebral block for analgesia after modified radical mastectomy. *Indian J Pain* 2014;28:160-5.
- Goda RME, Eldahshan TAEK. Comparative study between ultrasound guided TAP block and paravertebral block in upper abdominal surgeries. *Egyptian J Anaesth* 2017;33:41-65.
- Niraj G, Kelkar A, Jeyapalan I, Graff Baker P, Williams O, Darbar A, et al. Comparison of analgesic efficacy of subcostal transversus abdominis plane block with epidural analgesia following upper abdominal surgery. *Anaesthesia* 2011;66:465-71.
- Melnikov AL, Bjoergo S, Kongsgaard UE. Thoracic paravertebral block versus transversus abdominis plane block in major gynaecological surgery: A prospective, randomized, controlled, observer-blinded study. *Local Reg Anesth* 2012;5:55-61.
- Kaya C, Koksall E, Ustun YB, Yilmaz MZ. Comparative effects of transversus abdominis plane and paravertebral block on postoperative pain in inguinal hernia surgery. *Acta Medica Mediterr* 2014;30:341-6.
- Schnabel A, Reichl SU, Kranke P, Pogatzki-Zahn EM, Zahn PK. Efficacy and safety of paravertebral blocks in breast surgery: A meta-analysis of randomized controlled trials. *Br J Anaesth* 2010;105:842-52.
- Richardson J, Jones J, Atkinson R. The effect of thoracic paravertebral blockade on intercostals somatosensory evoked potentials. *Anesth Analg* 1998;87:373-6.
- Jenkins LC, Lahay D. Central mechanism of vomiting related to catecholamines response; anaesthetic implications. *Can Anesth Soc J* 1971;18:434-41.
- Andersen R, Krohg K. Pain as a major cause of postoperative nausea. *Can Anaesth Soc J* 1976;23:366-9.
- Baeriswyl M, Kirkham KR, Kern C, Albrecht E. The analgesic efficacy of ultrasound guided transversus abdominis plane block in adult patients: A meta-analysis. *Anesth Analg* 2015;121:1640-54.
- Abdallah FW, Chan VW, Brull R. Transversus abdominis plane block: The effects of surgery, dosing, technique and timing on analgesic outcomes. A systematic review. *Reg Anaesth Pain Med* 2012;37:193-209.