


SHORT COMMUNICATION

Hepatoprotective effect of *Herpetospermum caudigerum* Wall. on carbon tetrachloride-induced hepatic fibrosis in rats

Xin Feng^{1,2} | Ge-jia Zhong² | Da Ji Deng Ba² | Bin Yang¹ |
Lvyi Chen^{3,4}  | Shouying Du¹

¹School of Chinese Materia Medica, Beijing University of Chinese Medicine, Beijing, China

²Tibetan medicine Institute, China Tibetology Research Center, Beijing, China

³National Demonstration Center for Experimental Ethnopharmacology Education, South-Central University for Nationalities, Wuhan 430074, China

⁴School of Pharmaceutical Sciences, South-Central University for Nationalities, Wuhan 430074, China

Correspondence

Lvyi Chen and Shouying Du
Emails: clyhappy05@163.com (LC) and dushouying@263.net (SD)

Funding information

Hubei Province Natural Science Foundation, Grant/Award Number: 2016CFB617; National Science and Technology Major Project Fund of the Major new drug discovery, Grant/Award Number: 2014ZX09301308-003; the Applied Basic Research Foundation of Wuhan City, Grant/Award Number: 201606010101003; the Fundamental Research Funds for the Central Universities, South-Central University for Nationalities, Grant/Award Number: CZP17093

Abstract

Tibetan medicine *Herpetospermum caudigerum* Wall. (HCW) has long been employed to treat hepatitis, inflammatory diseases and jaundice according to the records of “The Four Medical Tantras” in China. This study was investigated to explore the protective effects of HCW on hepatic fibrosis and the possible mechanism in a rat model. Hepatic fibrosis was established by intragastric administration of 3 ml/kg carbon tetrachloride (CCl₄) twice a week for 6 weeks. CCl₄-treated rats were received HCW (1 and 3 g/kg/d) and silymarin (0.1 g/kg/d) from 3 to 6 weeks. The results showed that HCW could significantly decrease the levels of AST, ALT, HA, LN, PCIII, Col IV, TNF- α , IL-1 β and IL-6. Moreover, HCW could effectively inhibit collagen deposition and reduce the pathological damage. Analysis experiments finally exhibited that HCW was able to markedly inhibit hepatic fibrosis by modulating the expressions of NF- κ B p65, I κ B α , Samd3 and TGF- β 1 proteins. Therefore, our results suggest that HCW has hepatoprotective activity against CCl₄-induced hepatic fibrosis in rats by regulating the inflammatory responses.

KEYWORDS

carbon tetrachloride, hepatic fibrosis, *Herpetospermum caudigerum* Wall., inflammation, Tibetan medicine

1 | INTRODUCTION

Hepatic fibrosis is a serious disease which affects human health around the world.¹ Evidences suggest that the pathogenesis of hepatic fibrosis is related to the inflammation in activated hepatic stellate cells.^{2,3} During the activation of hepatic stellate cells, plenty of pro-inflammatory cytokines including interleukin-6 (IL-6), IL-1 β and tumour necrosis factor α (TNF- α) are produced and play important pathogenic roles.⁴ Transforming growth factor- β 1 (TGF- β 1), nuclear factor- κ B (NF- κ B) and multiple growth factors can also promote the activation of hepatic stellate cells and

accumulation of extra cellular matrix proteins which contributed to fibrosis.⁵

To control the cirrhosis progression, hepatoprotective drugs are used properly at the stage of hepatic fibrosis. Recently, researchers identify the effective hepatoprotective drugs from herbal medicines due to their low toxicity and free from side effects.

Herpetospermum caudigerum Wall. (HCW), a well-known Tibetan medicine, is used to treat hepatitis, inflammatory diseases and jaundice according to the records of “The Four Medical Tantras” in China. It has the function of clearing heat and regulating “Ci ba dang jiu” in Tibetan medicine theory. Previous studies have showed that

This is an open access article under the terms of the Creative Commons Attribution License, which permits use, distribution and reproduction in any medium, provided the original work is properly cited.

© 2018 The Authors. Journal of Cellular and Molecular Medicine published by John Wiley & Sons Ltd and Foundation for Cellular and Molecular Medicine.

HCW is effective on decreasing inflammatory responses and inhibiting lipid peroxidation in CCl₄-treated mice.⁶⁻⁸ On the basis of these researches, our present study is designed to further investigate the hepatoprotective activity of HCW and the effect on modulating NF- κ B and TGF- β 1/Smad signalling pathways in CCl₄-induced hepatic fibrosis in rats.

2 | MATERIALS AND METHODS

2.1 | Identification of HCW

Herpospermum caudigerum Wall (HCW) were collected in Tibet of China in October 2016. The materials were identified by Professor Wu Ga, Tibetan academy of Tibetan medicine. A voucher specimen was stored in No. 20161012 at herbarium of Tibetan medicine Institute in China. HCW (5 kg) was extracted by 80% EtOH to obtain HCW extract (501 g). Then, HCW extract was extracted with petroleum ether and ethyl acetate to obtain ethyl acetate fraction (EAF, 100 g).

EAF was identified by HPLC (Welchrom-Ultimate XB-C₁₈, 4.6 mm \times 250 mm, 5 μ m) in comparison with reference substances. The detector wavelength was set at 282 nm. The flow rate was 0.8 mL/min, and the injection volume was 2 μ L. The mobile phase consists of water containing 50 mmol (w/v) KH₂PO₄ (A) and methanol (B) (pH = 3.0). Four reference substances including dehydrodiconiferyl alcohol, herpetrine, herpetin and herpetotriol were used for the qualitative analysis.

2.2 | Animals and experimental model

Sixty Sprague-Dawley rats (male, 230-270 g) were purchased from the Laboratory Animal Center of Huazhong University of Science

and Technology (Wuhan, China). All animal experiments were conducted according to the Provision and General Recommendation of Chinese Experimental Animals Administration Legislation. All rats were housed with food and water ad libitum under controlled conditions at 23 \pm 2°C with a 12-h light/dark cycle.

All rats were randomly divided into 5 groups (n = 12 per group): normal control rats and CCl₄-treated model rats were orally received 3 ml/kg olive oil and 3 ml/kg CCl₄ (mixed 1:1 in olive oil; Sigma-Aldrich, Co., MO, USA) twice a week for 6 weeks and normal saline daily from week 3 to week 6, respectively; rats in treatment groups were orally received 3 ml/kg CCl₄ twice a week for 6 weeks and silymarin (0.1 g/kg) or HCW (1 and 3 g/kg) daily from week 3 to week 6.

At the end of 6 weeks, rats were killed after overnight fast. Serum samples and liver samples were collected. Some liver tissues immediately were stored at -80°C for analysis, and the others were used for histopathologic examination.

2.3 | Determination of serum levels of amino transferase (AST), alanine amino transferase (ALT), hyaluronic acid (HA), laminin (LN), type III procollagen (PCIII) and type IV collagen (Col IV)

Serum levels of AST, ALT, HA, LN, PCIII and Col IV were determined according to the manufacturer's instructions of kits (Nanjing Jiancheng Bioengineering Research Institute, Nanjing, China).

2.4 | Assay of TNF- α , IL-1 β and IL-6 in serum and liver tissues

Levels of TNF- α , IL-1 β and IL-6 in serum and liver tissues were determined with ELISA kits (Nanjing Key GEN Biotech. Co. Ltd., Nanjing, China) in accordance with the instruction of the manufacturers.

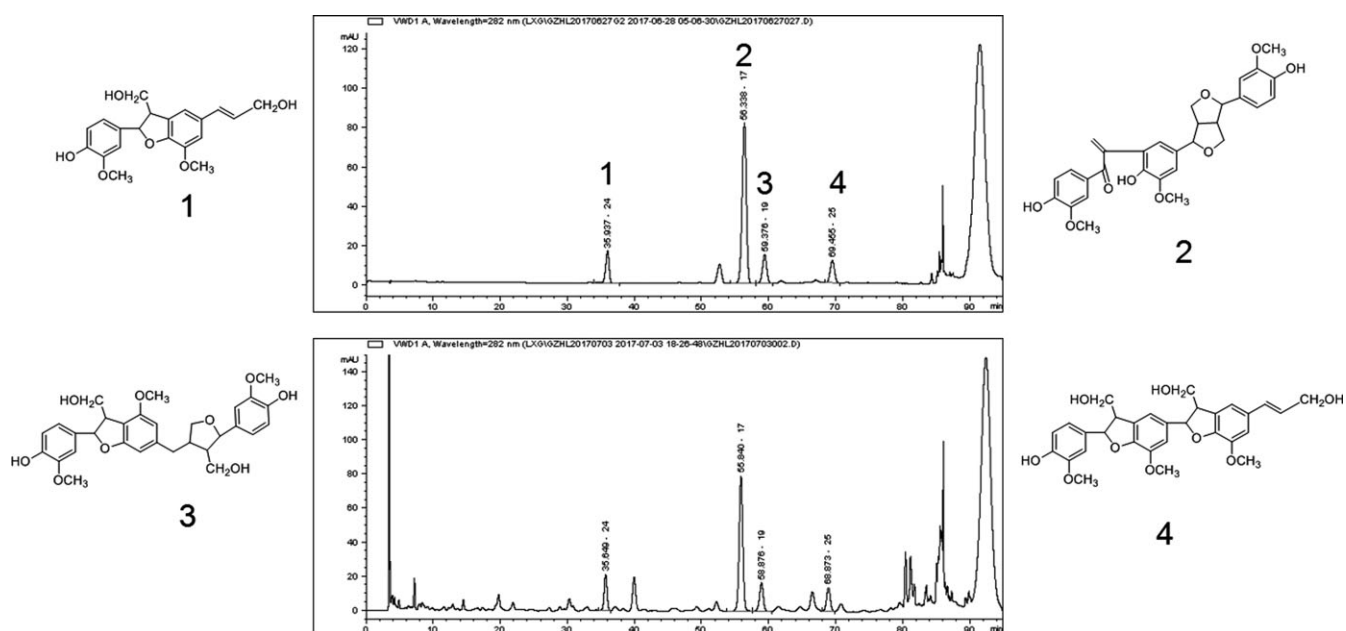


FIGURE 1 HPLC chromatogram of EAF. (1) Dehydrodiconiferyl alcohol; (2) Herpetrine; (3) Herpetin; (4) Herpetotriol

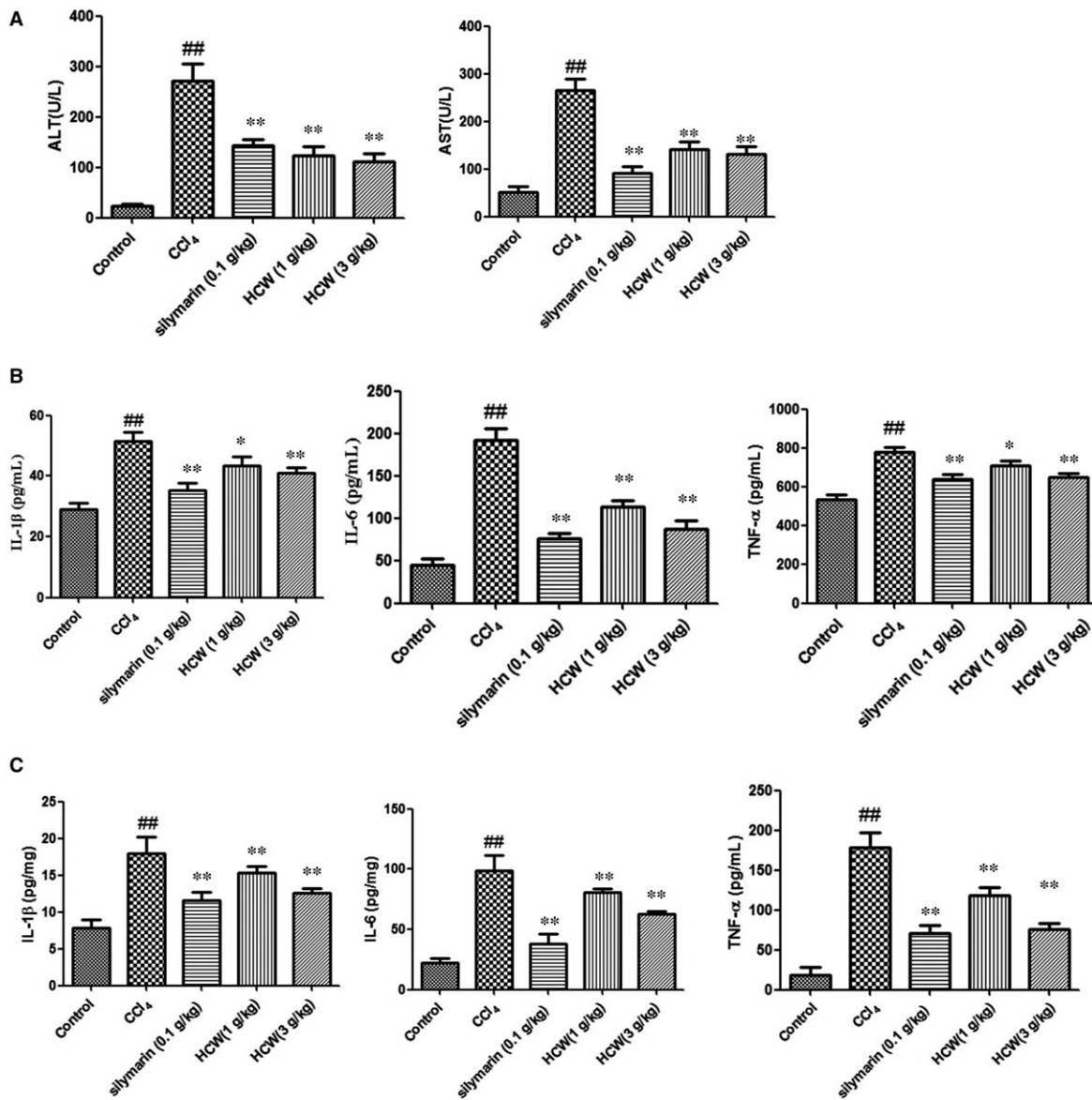


FIGURE 2 Effect of *Herpetospermum caudigerum* Wall. (HCW) on serum AST and ALT and TNF- α , IL-6 and IL-1 β in serum and liver. Values are expressed as mean \pm SD. # P < .05, ## P < .01 as compared with the normal control group; * P < .05, ** P < .01 as compared with the CCl₄-treated model group

TABLE 1 Effect of *Herpetospermum caudigerum* Wall. (HCW) on serum levels of hyaluronic acid (HA), laminin (LN), PCIII and Col IV

Groups	HA (μ g/L)	LN (μ g/L)	PCIII (μ g/L)	Col IV (μ g/L)
Control	49.35 \pm 5.26	73.55 \pm 13.06	75.57 \pm 5.11	58.75 \pm 23.14
CCl ₄ -treated model	75.37 \pm 22.65 ^{###}	131.74 \pm 20.94 ^{###}	117.65 \pm 29.45 ^{###}	75.15 \pm 14.70 [#]
silymarin (0.1 g/kg)	39.94 \pm 12.61 ^{***}	112.87 \pm 16.94 [*]	88.60 \pm 6.92 ^{**}	56.75 \pm 15.14 ^{**}
HCW (1 g/kg)	61.27 \pm 8.46 [*]	110.38 \pm 27.89 [*]	98.38 \pm 10.28 [*]	54.86 \pm 16.03 [*]
HCW (3 g/kg)	54.97 \pm 8.63 ^{**}	108.78 \pm 6.61 ^{**}	93.11 \pm 10.19 ^{**}	46.31 \pm 10.88 ^{***}

Values are expressed as mean \pm SD. # P < .05, ## P < .01, ### P < .001 as compared with the normal control group; * P < .05, ** P < .01, *** P < .001 as compared with the CCl₄-treated model group.

2.5 | Histopathological examination

Liver tissues were instantly fixed in 10% formalin and processed by routine histopathological procedures. The samples were stained with haematoxylin and eosin (HE) for photomicroscopic assessment.

2.6 | Immunohistochemical analysis

Liver tissues were fixed in 4% PFA and sectioned in 50 μ m/piece. The section was initially permeabilized with 0.4% Triton X-100 and 1% BSA for 2 hours and then incubated with anti-TGF- β 1 and anti-

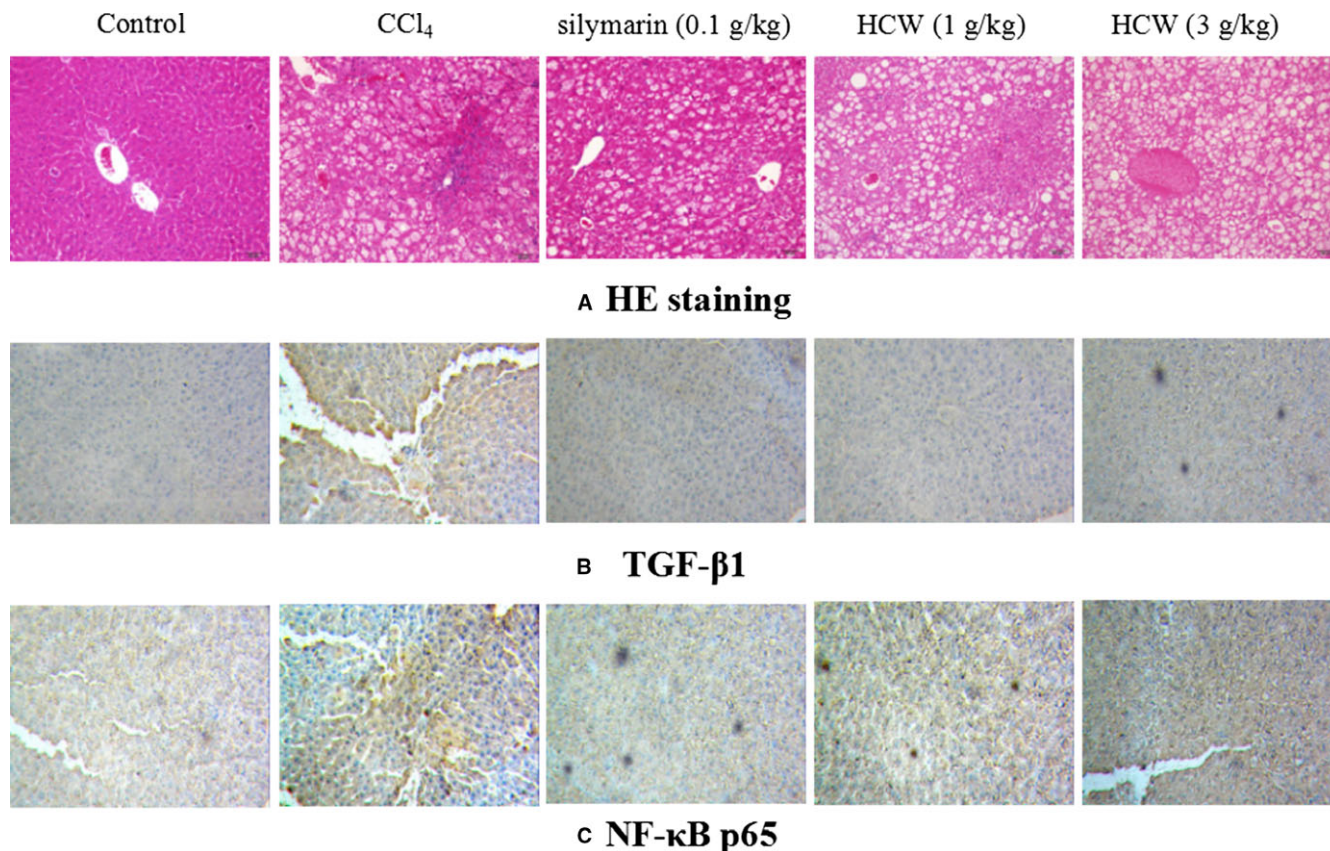


FIGURE 3 Effect of *Herpetospermum caudigerum* Wall. (HCW) against CCl_4 -induced hepatic fibrosis in rats. A: HE staining; B and C: Immunohistochemical analysis of TGF- β 1(B) and p-NF- κ B p65 (C). Magnification: 200 \times

NF- κ Bp65 antibodies (Cell Signaling Technology, Beverly, MA, USA) for 72 hours at 4°C. After being washed, sections were incubated with the second antibody for 2 hours at room temperature. Finally, sections were washed, dried and mounted. An arbitrary scope was given to each microscopic field and viewed at a magnification of 200 \times using a Leica confocal microscope.

2.7 | Western blot analysis

Liver tissues were homogenized in RIPA buffer with 1% PMSF and phosphatase inhibitor. The equal amount of proteins was separated in 10% SDS-PAGE gel and then transferred onto PVDF membranes (Millipore, USA). After blocked in 5% BSA, the membranes were incubated with primary antibodies (1:1000; Cell Signaling Technology, Beverly, MA, USA) at 4°C overnight. The membranes were then washed and incubated with the secondary antibodies for 2 hours. Finally, the membranes were exposed to X-ray film for 1 minute. The relative expression of various proteins was quantified by densitometric scanning using image analysis system.

2.8 | Statistical analysis

All of the data were presented as mean \pm SD. Divergence between groups was compared by one-way analysis of variance (ANOVA)

with Tukey's multiple comparison test. $P < .05$ was considered as significant.

3 | RESULTS

3.1 | Identification of HCW

Four compounds (dehydrodiconiferyl alcohol, herpetrine, herpetin and herpetotriol) were identified by comparing the individual peak retention times with those of the authentic reference standards (Figure 1).

3.2 | Effect of HCW on biochemical parameters

As illustrated in Figure 2A and Table 1, the serum levels of AST, ALT, HA, LN, PCIII and Col IV in CCl_4 -treated rats were significantly higher than those of the normal control rats, while treatment with HCW (1 and 3 g/kg) and silymarin (0.1 g/kg) effectively decreased these levels ($P < .05$).

In addition, there were significant increased levels of TNF- α , IL-6 and IL-1 β in CCl_4 -treated rats both in serum and in liver tissues. To the respective, however, the production of TNF- α , IL-6 and IL-1 β was effectively inhibited by HCW (1 and 3 g/kg) or silymarin (0.1 g/kg) (Figure 2B and C).

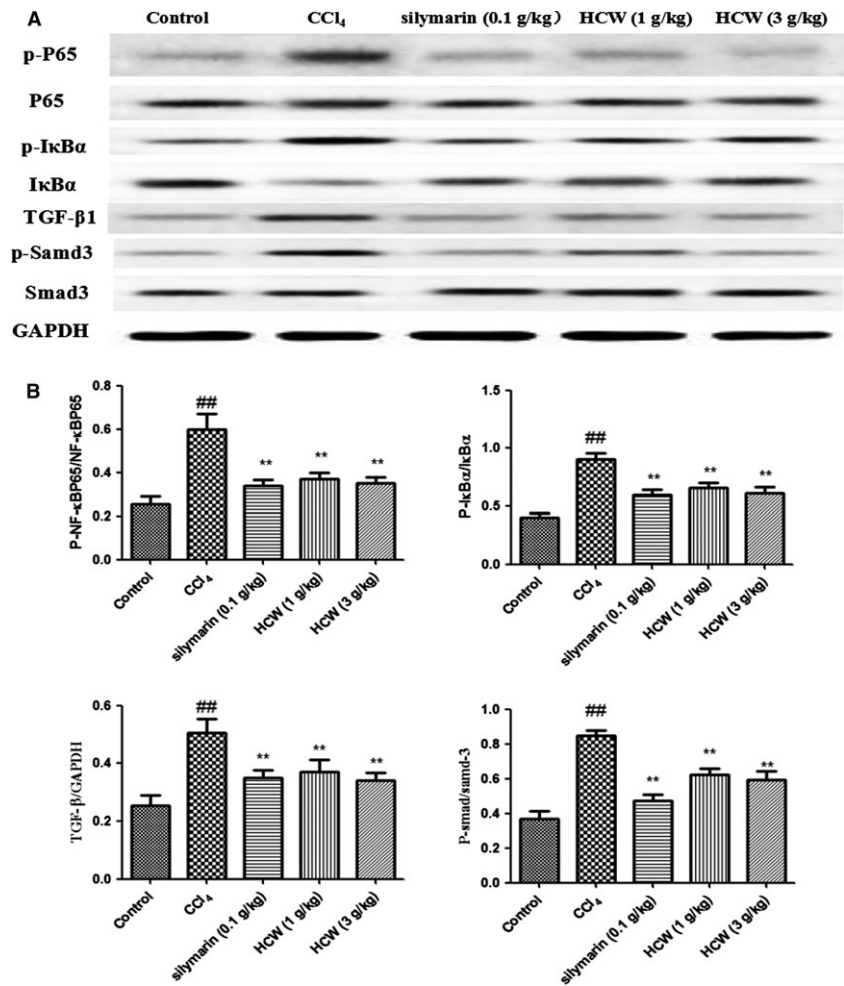


FIGURE 4 Effects of HCW on inflammation-related pathways in CCl_4 -treated rats. Values are expressed as mean \pm SD. $\#P < .05$, $\#\#P < .01$ as compared with the normal control group; $*P < .05$, $**P < .01$ as compared with the CCl_4 -treated model group

3.3 | Histopathological findings

As illustrated in Figure 3A, liver tissue sections in normal rats depicted normal architecture of hepatic central vein and surrounding hepatocytes. In CCl_4 -treated rats, several changes including ballooning, fat degeneration, necrosis and severe infiltration of inflammatory cells were observed, which demonstrated the successful establishment of hepatic fibrosis. However, HCW or silymarin effectively alleviated the pathological damage with mild ballooning degeneration and few inflammatory cells infiltration.

3.4 | Immunohistochemical analysis

The expression of TGF- β 1 and NF- κ B p65 proteins in liver tissues was determined by immunohistochemical staining. The expression of TGF- β 1 and NF- κ B p65 proteins was significantly up-regulated in CCl_4 -treated rats, while HCW (1 and 3 g/kg) or silymarin (0.1 g/kg) obviously ameliorated these situations (as shown in Figure 3B and C).

3.5 | Effects of HCW on protein expressions in live tissues of CCl_4 -treated rats

The expressions of NF- κ B p65, p-NF- κ B p65, I κ B α , p-I κ B α , TGF- β 1, p-Samd3 and Smad3 proteins in liver tissues were determined by

western blot. The protein expression ratios of p-I κ B α /I κ B α and p-NF- κ B p65/NF- κ B p65 were regulated in liver tissues of CCl_4 -treated rats compared with those of normal rats, while HCW (1 and 3 g/kg) or silymarin (0.1 g/kg) exerted suppressive effects on these proteins. Moreover, the up-regulated expression of TGF- β 1 protein and ratio of p-Samd3/Smad3 were observed in CCl_4 -treated rats, while HCW (1 and 3 g/kg) or silymarin (0.1 g/kg) significantly reversed the alterations of TGF- β 1 and p-Samd3/Smad3 (Figure 4).

4 | DISCUSSION

Hepatic fibrosis is associated with most chronic liver diseases which results in significant mortality rate around the world. Attentions have been focused on the inflammation-related pathways as promising therapies for hepatic fibrosis. In the present study, we demonstrated that HCW administration prevented the development of hepatic fibrosis in CCl_4 -treated rats.

CCl_4 is a hepatotoxin and has been widely adopted for experimental induction of hepatic fibrosis.⁹ In hepatic fibrosis, the increased levels of AST, ALT, HA, LN, PCIII and Col IV indicate the ability of CCl_4 to solubilize the lipid components and alter the ion channels of bio-membranes. In our present study, the hepatic fibrosis

was observed with the elevation of serum ALT, AST, HA, LN, PCIII and Col IV in CCl₄-treated rats, while HCW exhibited a significant therapeutic effect on decreasing the levels of those markers. In addition, HCW significantly restored ballooning degeneration and decreased inflammatory cells infiltration in liver tissues. These results indicated the effectiveness of HCW on hepatic regeneration after CCl₄ damaged.

Inflammatory response is a main event involved in the subsequent fibrogenesis. Upon liver damages, NF- κ B and its downstream signalling are stimulated, which contributes to the activation and survival of hepatic stellate cells.¹⁰ Evidence indicates that NF- κ B activation is controlled by the degradation of the I κ B α . NF- κ B up-regulates the levels of multiple inflammatory cytokines including TNF- α , IL-6 and IL-1 β in the hepatic fibrogenic process. In the present study, HCW obviously decreased the levels of TNF- α , IL-6 and IL-1 β and significantly down-regulated the protein expression ratios of p-NF- κ B p65/NF- κ B p65 and p-I κ B α /I κ B α in CCl₄-treated rats. These results suggested that HCW improved the hepatic damage induced by CCl₄ through regulating NF- κ B signalling to restrict the release of inflammatory mediators.

TGF- β 1 is an important mediator during the activation of hepatic stellate cells. It is ubiquitously distributed and has been recognized as one of most powerful pro-fibrogenic mediators.¹¹ Upon activation, TGF- β may bind to type I and type II serine/threonine kinase receptors and then activate receptor-regulated Smads including Smad3.¹² Previous studies have shown that TGF- β /Smad signalling pathway inactivation may relieve the hepatic fibrosis.^{13,14} The present study manifested that the higher expression of TGF- β 1 and ratio of p-Smad3/Smad3 were observed in CCl₄-treated rats. HCW remarkably inhibited phosphorylation of Smad3 and activation of TGF- β 1, suggesting that the inhibitory effects of HCW on hepatic fibrosis might be related to its action on hepatic stellate cells deactivation by controlling the TGF- β 1/Smad3 signalling pathway.

However, which is the exert compound that contributes to the effect of HCW on hepatic fibrosis? As reported, dehydroiconiferyl alcohol inhibits the activation of NF- κ B protein in LPS-treated macrophage and suggests as a potential agent for the treatment of inflammatory diseases.^{15,16} Herpetrine and herpetin have hepatoprotective effect on CCl₄-treated mice.^{17,18} Pinoresinol downregulated the inflammatory mediators by inhibiting the expression of NF- κ B and AP-1 proteins in CCl₄-induced liver injury.¹⁹ On the basis of these above-mentioned researches, we suggest that the comprehensive effect of these compounds on HCW contributes to the hepatoprotective effect of HCW. Whether other compounds have the hepatoprotective effect or not needs to be addressed in our future research.

In conclusion, the present study demonstrates that HCW has effectively therapeutic activity in the CCl₄-induced hepatic fibrosis in rats. The preliminary exploration of the underlying mechanisms exerts the hepatic protection via the modulations of NF- κ B and TGF- β 1/Smad3 signalling pathways. However, further researches are needed for more details in future. Therefore, based on our present

study, HCW may be considered as a promising drug for the prevention of hepatic fibrosis.

ACKNOWLEDGEMENTS

This work was supported by the National Science and Technology Major Project Fund of the Major new drug discovery (2014ZX09301308-003), Hubei Province Natural Science Foundation (2016CFB617), the Applied Basic Research Foundation of Wuhan City (2016060101010035) and the Fundamental Research Funds for the Central Universities, South-Central University for Nationalities (CZP17093).

CONFLICT OF INTEREST

The authors confirm that there are no conflicts of interest.

ORCID

Lvyi Chen  <http://orcid.org/0000-0002-4318-3033>

REFERENCES

1. Sánchezvalle V, Cháveztapia NC, Uribe M, Méndez-Sánchez N. Role of oxidative stress and molecular changes in liver fibrosis: a review. *Curr Med Chem*. 2012;19:4850-4860.
2. Hernandez-Gea V, Friedman SL. Pathogenesis of liver fibrosis. *Annu Rev Pathol*. 2011;6:425-456.
3. Reeves HL, Friedman SL. Activation of hepatic stellate cells – a key issue in liver fibrosis. *Front Biosci*. 2002;7:d808-d826.
4. Tacke F, Weiskirchen R. Update on hepatic stellate cells: pathogenic role in liver fibrosis and novel isolation techniques. *Expert Rev Gastroenterol Hepatol*. 2012;6:67-80.
5. He W, Dai C. Key fibrogenic signaling. *Curr Pathobiol Rep*. 2015;3:183-192.
6. Chen X, Zhang M, Tang PR, et al. Protective effect of *Herpetospermum caudigerum* extracts on liver injury induced by carbon tetrachloride in mice. *J Chengdu Univ Trad Chin Med*. 2008;31:45-46.
7. Chen L, Zhang M, Yao HE, et al. Protective effect of *Herpetospermum* seed oil on immunologic liver injury in the mice. *West China J Pharma Sci*. 2014;29:143-145.
8. Shen B, Chen H, Shen C, et al. Hepatoprotective effects of lignans extract from *Herpetospermum caudigerum* against CCl₄-induced acute liver injury in mice. *J Ethnopharmacol*. 2015;164:46-52.
9. Hernández-Muñoz R, Díaz-Muñoz M, Suárez J, Chagoya de Sánchez V. Adenosine partially prevents cirrhosis induced by carbon tetrachloride in rats. *Hepatology*. 1990;12:242-248.
10. Elsharkawy AM, Mann DA. Nuclear factor-kappaB and the hepatic inflammation-fibrosis-cancer axis. *Hepatology*. 2007;46:590-597.
11. Nakamura T, Sakata R, Ueno T, et al. Inhibition of transforming growth factor β prevents progression of liver fibrosis and enhances hepatocyte regeneration in dimethylnitrosamine-treated rats. *Hepatology*. 2000;32:247-255.
12. Inagaki Y, Okazaki I. Emerging insights into transforming growth factor beta Smad signal in hepatic fibrogenesis. *Gut*. 2007;56:284-292.
13. Moustakas A, Souchelnytskyi S, Heldin CH. Smad regulation in TGF-beta signal transduction. *J Cell Sci*. 2001;114:4359-4369.
14. Derynck R, Zhang YE. Smad-dependent and Smad-independent pathways in TGF-beta family signalling. *Nature*. 2003;425:577-584.

15. Pan LL, Zhang QY, Luo XL, et al. (7R,8S)-9-acetyl- dehydrodiconiferyl alcohol inhibits inflammation and migration in lipopolysaccharide-stimulated macrophages. *Phytomedicine*. 2016;23:541-549.
16. Lee J, Choi J, Lee W, et al. Dehydrodiconiferyl alcohol (DHCA) modulates the differentiation of Th17 and Th1 cells and suppresses experimental autoimmune encephalomyelitis. *Mol Immunol*. 2015;68:434-444.
17. Shen B, Jin S, Lv Q, et al. Enhanced intestinal absorption activity and hepatoprotective effect of herpetrine via preparation of nanosuspensions using pH-dependent dissolving-precipitating/homogenization process. *J Pharm Pharmacol*. 2013;65:1382-1392.
18. Gu J, Yuan Z, Tan R, Zhang X. Isolation of herpetin from *Herpetospermum* seed and hepatoprotective activity of liposomal herpetin against carbon tetrachloride-induced liver injury in mice. *Pharmazie*. 2015;70:745-752.
19. Kim HY, Kim JK, Choi JH, et al. Hepatoprotective effect of pinoresinol on carbon tetrachloride-induced hepatic damage in mice. *J Pharmacol Sci*. 2010;112:105-112.

How to cite this article: Feng X, Zhong G-J, Deng Ba DJ, Yang B, Chen L, Du S. Hepatoprotective effect of *Herpetospermum caudigerum* Wall. on carbon tetrachloride-induced hepatic fibrosis in rats. *J Cell Mol Med*. 2018;22:3691-3697. <https://doi.org/10.1111/jcmm.13568>