



## Case report

## Multifocal primary amyloidosis of the airways: Case report and review of the literature

S.M. Lang <sup>a,\*</sup>, D. Täuscher <sup>a</sup>, J. Füller <sup>b</sup>, A.H. Müller <sup>c</sup>, H. Schiffel <sup>d</sup><sup>a</sup> SRH Wald-Klinikum Gera, Department of Respiratory Medicine, Germany<sup>b</sup> SRH Wald-Klinikum Gera, Department of Radiation Therapy, Germany<sup>c</sup> SRH Wald-Klinikum Gera, Department of Otolaryngology/Head and Neck Surgery, Germany<sup>d</sup> Medizinische Klinik IV, University Hospital LMU Munich, Germany

## ARTICLE INFO

## Article history:

Received 7 February 2015

Accepted 3 May 2015

## Keywords:

Tracheobronchial amyloidosis

Amyloidosis of the nose

Radiation therapy

## ABSTRACT

Primary localized amyloidosis of the airways is an uncommon disorder characterized by amyloid deposits in the airway mucosa. In contrast to systemic amyloidosis other organs are not involved. Among the entities of airway amyloidosis, tracheobronchial amyloidosis is comparatively the most common subtype in the lower respiratory tract and laryngeal amyloidosis in the upper respiratory tract. The pathophysiology of localized airway amyloidosis is poorly understood. The clinical presentation is variable and often non-specific. No general consensus exists with regard to optimal treatment resulting in a variety of modalities used in clinical practice to manage this disorder. We report the case of a 50 year old woman with multifocal localized amyloidosis of the tracheobronchial tree and the upper airways. Tracheobronchial amyloidosis was treated with endoscopic debulking and external beam radiation, sinusoidal amyloid deposits were surgically excised and are currently under surveillance. The importance of this extremely rare case lies in the multifocal presentation of an uncommon disorder requiring a multidisciplinary approach to offer optimal treatment including external beam radiation.

© 2015 The Authors. Published by Elsevier Ltd. This is an open access article under the CC BY-NC-ND license (<http://creativecommons.org/licenses/by-nc-nd/4.0/>).

## 1. Background

Primary isolated amyloidosis involving the respiratory tract is a rare disease. It mostly affects the trachea and central bronchi [1,2], but amyloid deposits in other sections of the airways alone or in combination with tracheobronchial amyloidosis (TBA) have been reported [3–5]. TBA is typically not associated with systemic amyloidosis or pulmonary parenchymal deposits such as in Sjögren's syndrome. It represents a localized variant of amyloidosis and is characterized by multiple amyloid deposits within the airway walls [6].

The diagnosis of TBA is often delayed, as affected patients have signs and symptoms not differ from common airway diseases. Pulmonary function tests may or may not reveal an obstructive pattern. Chest x-rays are frequently unremarkable or a tracheal mass is overlooked. On computer tomography, diffuse TBA leads to

concentric smooth or nodular thickening of the submucosal tracheal wall. The diagnosis of TBA is made by means of bronchoscopy and biopsy of airway mucosa [1,7,8].

Management of this disease is directed at maintaining airway patency, but no general consensus exists with regard to optimal treatment, as debridement is often associated with severe and prolonged bleeding.

We report the case of a 50 year old woman with concurrent amyloidosis of the tracheobronchial tree and the upper airways. Our case illustrates the necessity for a multidisciplinary approach, including respiratory medicine and otorhinolaryngology, radiology, pathology and radiotherapy to achieve an accurate and timely diagnosis of this uncommon disorder and to offer currently optimal therapy.

## 2. Case presentation

A 50 year old woman was admitted to the hospital for bronchoscopic evaluation. She was an active smoker with a cigarette smoking history of 30 pack years and had suffered from repeated bronchitis, shortage of breath and hoarseness as well as repeated episodes of hemoptysis. She also complained of nasal congestion

\* Corresponding author. SRH Wald-Klinikum Gera, Department of respiratory medicine, Str. des Friedens 122, D-07548 Gera, Germany.

E-mail addresses: [lang\\_susanne@hotmail.com](mailto:lang_susanne@hotmail.com) (S.M. Lang), [dagmar.tauscher@wkg.srh.de](mailto:dagmar.tauscher@wkg.srh.de) (D. Täuscher), [juergen.fueller@wkg.srh.de](mailto:juergen.fueller@wkg.srh.de) (J. Füller), [andreas.mueller@wkg.srh.de](mailto:andreas.mueller@wkg.srh.de) (A.H. Müller), [h-schiffel@t-online.de](mailto:h-schiffel@t-online.de) (H. Schiffel).

and recurrent sinusitis. A pulmonary infiltrate in the right upper lobe had not resolved after antibiotic treatment.

On clinical examination, stridor was audible in the central airways. The physical examination of other organ systems was not remarkable. Laboratory investigations included normal blood count, normal erythrocyte sedimentation rate and normal biochemistry. A computer tomography scan revealed an atelectasis of the right upper lobe and diffuse nodular thickening of the sub-mucosal tracheal and bronchial walls (Fig. 1). The cartilage showed calcifications. There were no other parenchymal abnormalities. Arterial blood gases, while breathing room air, were normal. Pulmonary function tests revealed normal FVC, FEV1, FEV1/FVC; but decreased PEF and an expiratory plateau in the flow volume loop, suggestive of intrathoracic stenosis (Fig. 2).

Flexible bronchoscopy was performed and a completely irregular surface of the tracheal and bronchial mucosa with prominent white and reddish plaques, extending the lower half of the trachea and main bronchi with reduced airway diameters and diffuse bleeding was found (Fig. 3). Biopsies showed amorphous deposits, identified as amyloid by apple-green birefringence in sections stained with congo red and seen under polarized light. Immunohistochemical staining demonstrated AL amyloid. Systemic amyloidosis was excluded by normal serum protein electrophoresis, normal urine analyses (no Bence Jones protein in the urin), normal rectal biopsy specimens, normal bone marrow aspiration/biopsy, normal echocardiography and abdominal ultrasound.

The patient underwent bronchoscopic debridement with forceps debulking for more extensive bioptic work-up and treatment of airway stenosis. The procedure was complicated by prolonged but self-limited bleeding. The case was discussed at the multidisciplinary respiratory oncology board and it was felt that external beam radiation therapy (EBRT) was an appropriate treatment option. Radiation therapy was explained in detail to the patient because of the scarcity of clinical data regarding its use for TBA. She received EBRT, 20 Gy in 10 fractions. Opposed antero-posterior and posterior-anterior treatment fields were used to encompass the entire tracheobronchial tree. The treatment volume was determined using CT-guided simulation. Treatment was uneventful. Clinically her symptoms improved and the pulmonary function test stabilized during 12 month follow-up. Chest x-rays at 6 months and CT scans at 12 months after radiation therapy revealed that response to radiation was maintained, with no evidence of disease progression.

Meanwhile the symptoms of chronic sinusitis and nasal congestion worsened. She was transferred to the department of

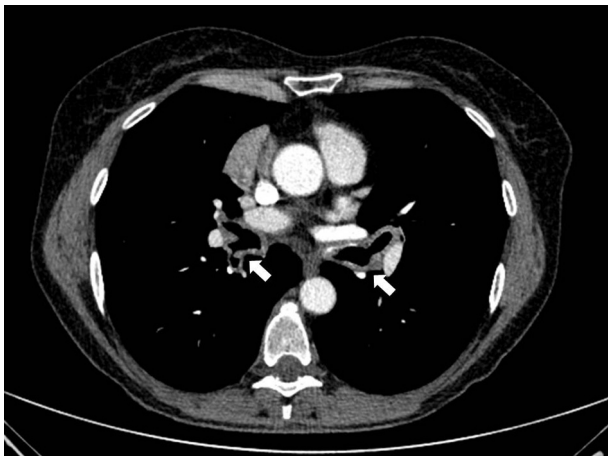


Fig. 1. Computer tomography scan revealing diffuse nodular thickening of the bronchial walls (arrows).

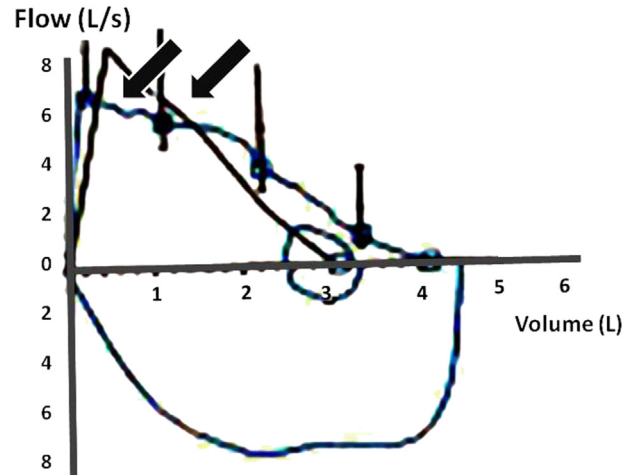


Fig. 2. Pulmonary function test showing an expiratory plateau in the flow volume loop (arrows).

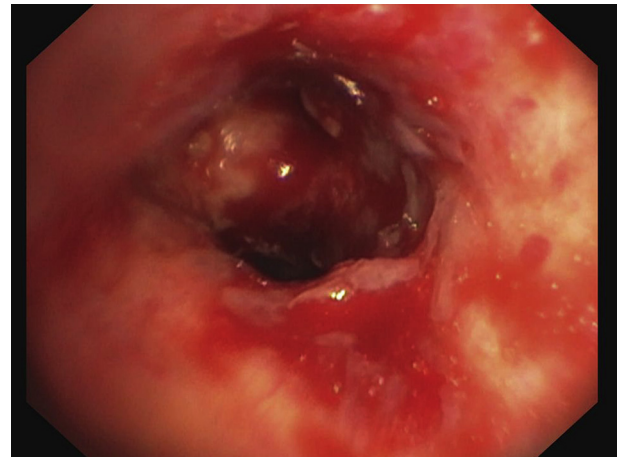


Fig. 3. Prominent white and reddish plaques and diffuse bleeding of the mucosa of the right upper lobe bronchi.

Otolaryngology/Head and Neck Surgery where a CT scan revealed a mass at the bottom of the left maxillary sinus and the nasopharynx. Surgical excision confirmed amyloid deposits submucosally at the roof of the nasopharynx. Functional endoscopic sinus surgery (FEES) was performed to ventilate the left maxillary sinus. To date no further treatment has been necessary.

### 3. Discussion

Amyloidosis restricted to the respiratory tract is a rare manifestation of an otherwise rare disorder. Less than 250 cases of pulmonary amyloidosis have been reported, predominantly as anecdotal reports or small series [1,2]. Localized pulmonary amyloidosis can manifest as parenchymal nodules, diffuse alveolar septal disease, or mostly tracheobronchial disease. Isolated nasal amyloidosis is extremely uncommon, some 20 cases have been reported in the literature [4,5,9–13]. Only a few cases with multifocal amyloidosis of the upper and lower airways have been described. By definition, localized amyloidosis affects only one organ system and inevitably occurs without systemic amyloidosis. It is not understood, why these disease processes are limited to the respiratory tract, but it has been proposed that light chains are deposited locally by plasma cells.

The condition tends to have a progressive course where up to 30% of patients with TBA may not survive beyond seven to twelve years after diagnosis [6] due to narrowing airways. There is no established treatment for TBA. Review of the literature shows that information about TBA is limited to small case series or case reports. Generally, the treatment options, as gathered from published data, can be categorized into 4 not necessarily exclusive groups: [1] systemic pharmacologic treatment, [2] bronchoscopic recanalisation techniques [3] the use of external beam radiation therapy and [4] surgery in a few cases.

Pharmacologic treatment with colchicine has been tried, although the evidence for its use is based on non-controlled trials that have suggested that adjuvant treatment in primary systemic amyloidosis may have some benefit. Systemic intermittent chemotherapy using melphalan and prednisolone has been prescribed with limited success and there is no proof, that pharmacologic treatment following repeated laser resection is synergistic [8,14].

Bronchoscopic debulking with forceps or laser can be effective for a short time [12,15], but does not slow down the underlying disease process. Bronchoscopic recanalization techniques are limited by severe bleeding [16] and the near inevitability of short term recurrence of the amyloid deposits.

Based on small series and few case reports, it appears that radiation therapy may change the progressive course of TBA [17–24]. EBRT is now recommended as a first-line therapy in patients with bulky or distal disease that is not amenable for bronchoscopic recanalization, especially if there is evidence of severe symptoms or functional decline. The successful use of radiation therapy for the treatment of TBA was first described by Kurrus et al. as a case report in 1998 [24]. A patient with life-threatening airway obstruction secondary to TBA received 20 Gy in 10 fractions to the distal and right main bronchi and 6 months later to the lower lobe bronchi. In both areas treated the patient responded radiologically and symptomatically. The benefits of EBRT were maintained in anecdotal cases for more than 5 years [18,20]. The mechanisms underlying the therapeutic effects of EBRT are unknown. Generally, patients treated with EBRT achieve a rapid symptomatic response as well as an objective improvement of pulmonary function tests, CT scan findings and bronchoscopic appearance. EBRT was well tolerated. However, the long-term effects of radiation therapy are still unknown in these patients and only few patients received a second course.

#### 4. Conclusions

TBA remains a rare and clinically challenging condition. The treatment of this disease needs to be evaluated on a case by case basis and managed with an appropriate multidisciplinary team including the evaluation of the upper airways. EBRT is a promising and well tolerated treatment option. Close follow-up to detect late re-occurrence of the disorder or complications of EBRT is required.

#### 5. Consent

Written informed consent was obtained from the patient for publication of this Case report and any accompanying images. A copy of the written consent is available for review by the Editor-in-Chief of this journal.

#### List of abbreviations

TBA	tracheobronchial amyloidosis
FEV1	forced expiratory volume in 1 s

FVC	forced vital capacity
PEF	peak expiratory flow
EBRT	external beam radiation therapy
CT	computed tomography
FEES	functional endoscopic sinus surgery

#### Conflict of interest

The author(s) declare that they have no competing interests.

S. Lang and D. Täuscher treated the patient and drafted the manuscript. J. Fueller carried out the radiation therapy and wrote the respective section in the manuscript. A.H. Mueller treated the upper airways and wrote the respective section in the manuscript. H. Schiffel scientifically guided the manuscript. All authors read and approved the final manuscript.

#### References

- [1] L. Ding, W. Li, K. Wang, Y. Chen, H. Xu, H. Wang, et al., Primary tracheobronchial amyloidosis in China: analysis of 64 cases and a review of literature, *J. Huazhong Univ. Sci. Technol. Med. Sci.* 30 (2010) 599–603.
- [2] H. Gibbaoui, S. Abouchacra, M. Yaman, A case of primary diffuse tracheobronchial amyloidosis, *Ann. Thorac. Surg.* 77 (2004) 1832–1834.
- [3] L. Xu, B.Q. Cai, X. Zhong, Y.J. Zhu, Respiratory manifestations in amyloidosis, *Chin. Med. J. Engl.* 20 (118) (2005) 2027–2033.
- [4] T. Nakayama, N. Otori, M. Komori, H. Takayanagi, H. Moriyama, Primary localized amyloidosis of the nose, *Auris Nasus Larynx* 39 (2012) 107–109.
- [5] D. Rauba, E. Lesinskas, M. Petrulionis, D. Sukyte, N. Valeviciene, D. Palionis, et al., Isolated nasal amyloidosis: a case report, *Med. Kaunas.* 49 (2013) 497–503.
- [6] A. O'Regan, H.M. Fenlon, J.F. Beamis Jr., M.P. Steele, M. Skinner, J.L. Berk, Tracheobronchial amyloidosis. The Boston University experience from 1984 to 1999, *Med. Baltim.* 79 (2000) 69–79.
- [7] D. Li, Z. Shi, Y. Wang, A. Thakur, Primary tracheobronchial amyloidosis: coronal CT scan may provide clues for early diagnosis, *J. Postgrad. Med.* 59 (2013) 223–225.
- [8] M. Paccalin, E. Hachulla, C. Cazalet, L. Tricot, M. Carreiro, M. Rubi, et al., Localized amyloidosis: a survey of 35 French cases, *Amyloid* 12 (2005) 239–245.
- [9] Y.S. Naidoo, R. Gupta, R. Sacks, A retrospective case review of isolated sino-nasal amyloidosis, *J. Laryngol. Otol.* 126 (2012) 633–637.
- [10] N.K. Panda, S.C. Sharma, S.B. Mann, B.D. Radotra, Localized amyloidosis of the nasopharynx, *Ear Nose Throat J.* 73 (1994) 335–336.
- [11] A. Patel, S. Pambuccian, R. Maisel, Nasopharyngeal amyloidosis, *Am. J. Otolaryngol.* 23 (2002) 308–311.
- [12] C. Piazza, S. Cavaliere, P. Foccoli, C. Toninelli, A. Bolzoni, G. Peretti, Endoscopic management of laryngo-tracheobronchial amyloidosis: a series of 32 patients, *Eur. Arch. Otorhinolaryngol.* 260 (2003) 349–354.
- [13] Q. Wang, H. Chen, S. Wang, Laryngo-tracheobronchial amyloidosis: a case report and review of literature, *Int. J. Clin. Exp. Pathol.* 7 (2014) 7088–7093.
- [14] M. Sepiolo, J. Skokowski, M. Kaminski, A case of primary tracheo-bronchial amyloidosis, *Pneumonol. Alergol. Pol.* 67 (1999) 481–484.
- [15] I. Alloubi, M. Thumerel, H. Begueret, J.M. Baste, J.F. Velly, J. Jougon, Outcomes after bronchoscopic procedures for primary tracheobronchial amyloidosis: retrospective study of 6 cases, *Pulm. Med.* 2012 (2012) 352719.
- [16] N.A. Shaheen, S.D. Salman, V.H. Nassar, Fatal bronchopulmonary hemorrhage due to unrecognized amyloidosis, *Arch. Otolaryngol.* 101 (1975) 259–261.
- [17] I. Firlinger, U. Setinek, H. Koller, P. Feurstein, H. Prosch, O.C. Burghuber, et al., A case of tracheobronchial amyloidosis treated with endoscopic debulking and external beam radiation therapy, *Pneumologie* 67 (2013) 398–400.
- [18] M.T. Truong, L.A. Kachnic, G.A. Grillone, H.K. Bohrs, R. Lee, O. Sakai, et al., Long-term results of conformal radiotherapy for progressive airway amyloidosis, *Int. J. Radiat. Oncol. Biol. Phys.* 83 (2012) 734–739.
- [19] S. Poovaneswaran, A.R. Razak, H. Lockman, M. Bone, K. Pollard, G. Mazdai, Tracheobronchial amyloidosis: utilization of radiotherapy as a treatment modality, *Medscape J. Med.* 10 (2008) 42.
- [20] M.A. Neben-Wittich, R.L. Foote, S. Kalra, External beam radiation therapy for tracheobronchial amyloidosis, *Chest* 132 (2007) 262–267.
- [21] S. Ren, G. Ren, External beam radiation therapy is safe and effective in treating primary pulmonary amyloidosis, *Respir. Med.* 106 (2012) 1063–1069.
- [22] A.T. Monroe, R. Walia, R.A. Zlotecki, M.A. Jantz, Tracheobronchial amyloidosis: a case report of successful treatment with external beam radiation therapy, *Chest* 125 (2004) 784–789.
- [23] S. Kalra, J.P. Utz, E.S. Edell, R.L. Foote, External-beam radiation therapy in the treatment of diffuse tracheobronchial amyloidosis, *Mayo Clin. Proc.* 76 (2001) 853–856.
- [24] J.A. Kurrus, J.K. Hayes, J.R. Hoidal, M.M. Menendez, M.R. Elstad, Radiation therapy for tracheobronchial amyloidosis, *Chest* 114 (1998) 1489–1492.