

This is an Open Access article licensed under the terms of the Creative Commons Attribution-NonCommercial-NoDerivs 3.0 License (www.karger.com/OA-license), applicable to the online version of the article only. Distribution for non-commercial purposes only.

Two Cases of Cerebral Sinus Venous Thrombosis Following Chemotherapy for Non-Seminomatous Germ Cell Tumor

C. Papet^a A. Gutzeit^b M. Pless^a

^aMedical Oncology and ^bDepartment of Radiology, Cantonal Hospital Winterthur, Winterthur, Switzerland

Key Words

Germ cell tumor · Cisplatin · Cerebral sinus venous thrombosis

Abstract

We report on two patients with cerebral sinus venous thrombosis following chemotherapy with cisplatin, bleomycin and etoposide for non-seminomatous germ cell tumor. Headache and neurological deficits were the leading symptoms. Cancer and cisplatin chemotherapy are well-known risk factors for thromboembolic events. The therapeutic strategy is an anticoagulant therapy. Symptoms are usually reversible within weeks under this therapy. Therefore, in patients with testicular cancer and chemotherapy who present with neurological symptoms, cerebral sinus venous thrombosis should be considered in the differential diagnosis.

Case Report

Case 1

A 47-year-old man presented with a two-day history of weakness in the left limb, prickling in the left part of the body and headache. Two months before, a high-risk non-seminomatous germ cell tumor with embryonal carcinoma stage I according to the UICC/AJCC classification was diagnosed, with presence of lymphatic invasion. Adjuvant chemotherapy with two cycles of cisplatin, etoposide and bleomycin (BEP) was started four weeks after radical orchiectomy. At the time of his admittance he had received two full doses of cisplatin and etoposide and four full doses of bleomycin. During chemotherapy he suffered from asthenia, nausea, loss of appetite and dehydration requiring intravenous rehydration. The patient stopped smoking one year ago with a total of three pack years and drank up to two glasses of wine or beer daily until the start of the chemotherapy. Otherwise his medical history was unremarkable.

Subsequent magnetic resonance imaging (MRI) scan showed a cerebral sinus venous thrombosis in the superior sagittal sinus ([fig. 1](#)), as well as in the right sigmoid and both transverse sinuses with bilateral venous congestion associated with cytotoxic edema within the precentral gyri ([fig. 2](#)). Routine blood tests were normal. The patient was placed on anticoagulant therapy and a neurorehabilitation was started. Symptoms resolved completely within a month. The remaining chemotherapy with one administration of bleomycin was given.

After three months, the MRI scan showed a residual thrombus in the right transverse sinus, the right sigmoid sinus and the superior sagittal sinus, respectively. The left transverse sinus was normal. The anticoagulant treatment was continued for a total treatment time of six months. So far, there has been no sign of a relapse of the testicular cancer.

Case 2

A high-risk non-seminomatous germ cell tumor with embryonal carcinoma stage I, according to the UICC/AJCC classification, with presence of lymphatic invasion was found in a 29-year-old man. After three months of active surveillance, retroperitoneal lymphadenopathy was diagnosed and chemotherapy with three cycles of BEP was initiated. On day 10 of the second cycle the patient was admitted with a headache which had persisted for two days. On the way to the hospital a generalized epileptic seizure occurred. Computed tomography (CT) scan of the brain showed a cerebral sinus venous thrombosis in the superior sagittal sinus, a subarachnoid hemorrhage in the right frontal region and the left precentral sulcus, with a hemorrhage in the right frontal lobe due to venous congestion ([fig. 3](#)). Therapy, initially with unfractionated heparin and then with low-molecular dalteparine, and an antiepileptic therapy with phenytoin was started and symptoms resolved quickly. The chemotherapy was changed to carboplatin instead of cisplatin.

On day 10 of the third cycle the patient was admitted again with recurrence of the headache. CT of brain showed a fresh venous thrombosis in the right sigmoid sinus. The superior sagittal sinus was recanalized and the former bleeding was dissolved. The dose of dalteparine was increased to a twice-daily application. Tests for coagulopathy, including antiphospholipid syndrome, were without pathological findings. The last dose of bleomycin was omitted. Three months later the MRI scan was normal and the anticoagulant treatment was stopped. CT scans of the chest and abdomen showed no residual sign of the testicular cancer.

Discussion

Thromboembolic events such as pulmonary embolism, arterial or deep venous thrombosis and cerebral ischemic stroke are rare but known complications during chemotherapy for germ cell cancer [1]. In patients with germ cell cancer, elevated serum lactate dehydrogenase, a high body surface area (>1.9 m²) [2], cisplatin-related hypomagnesemia, damage of the vascular endothelium, elevation of von Willebrand factor plasma levels [3], liver metastases and high doses of corticosteroids (≥ 80 mg dexamethasone per cycle) have been described as risk factors for thromboembolic events [1]. In our two cases, apart from von Willebrand factor plasma levels, which were not measured, none of these risk factors were present. Interestingly, most patients with germ cell cancer who showed a thromboembolic complication had embryonal carcinoma [1], as it was seen in our two cases.

Chemotherapy with cisplatin, etoposide and bleomycin is the standard treatment for germ cell cancer, both in the adjuvant setting as well as for advanced stages and it has resulted in high remission rates and improved survival [4]. Cisplatin and bleomycin have been associated with acute and long-term vascular toxicity, such as cardiovascular events, thromboembolic events or Raynaud's phenomenon [3]. An extensive retrospective analysis found that patients undergoing cisplatin-based chemotherapy

are at higher risk for thromboembolic events if they suffer from germ cell cancer rather than other tumors [2].

While there is abundant literature on thromboembolic complications in patients with testicular cancer, very few cases of cerebral sinus thrombosis have been reported thus far. Established risk factors for cerebral sinus venous thrombosis in general are inherited or acquired thrombophilia, nephritic syndrome, chronic inflammatory diseases, infections, pregnancy and puerperium, hormonal contraception or dehydration [5, 6]. It is more common in women than in men, with a female-to-male ratio of 3:1. In the International Study on Cerebral Venous and Dural Sinuses Thrombosis, 7.4% of cases of cerebral sinus venous thrombosis were associated with cancer [7]. Local tumor compression, hypercoagulable state and antineoplastic drugs like tamoxifene or l-asparaginase are risk factors according to a statement for healthcare professionals from the American Heart Association and American Stroke Association [8]. Cerebral sinus venous thrombosis associated with chemotherapy not due to the above-mentioned drugs or to a local tumor compression has so far been described in a patient with colon cancer treated with FOLFIRI/bevacizumab [9], in a patient with a brain tumor treated with temozolomide, focal brain radiotherapy plus bevacizumab [10] and an adolescent with Ewing sarcoma treated with cisplatin, ifosfamide, adriamycin, and vincristine [11]. In a further patient with malignant cutaneous melanoma, micrometastases were assumed to be the reason for the cerebral sinus venous thrombosis [12]. This etiology can be excluded in our two patients: in the first case, chemotherapy was given in the adjuvant setting and only retroperitoneal lymphadenopathy was known in the second case.

To the best of our knowledge only two other cases with cerebral sinus venous thrombosis following chemotherapy for germ cell cancer have been described in the literature so far. Karam and Koussa [13] described two cases of cerebral dural sinus thrombosis following cisplatin-based chemotherapy. As in our cases, one of them had a germ cell carcinoma and underwent chemotherapy with cisplatin, etoposide and methylprednisolone. Recently, a similar case was published [14].

In our two cases, we hypothesized that cisplatin-related hypercoagulability was the main risk factor for the occurrence of the cerebral sinus venous thrombosis according to the time interval between chemotherapy and the occurrence, and the missing risk factors for cancer-related thromboembolic events. In our second patient we felt that the platinum, as the most efficient class of drugs in this disease, should not be completely omitted. We therefore replaced cisplatin by carboplatin in the third cycle of the chemotherapy. Nevertheless, this patient experienced a second episode of a cerebral sinus venous thrombosis. To the best of our knowledge this is the first report of cerebral venous sinus thrombosis associated to chemotherapy with carboplatin, etoposide or bleomycin in the literature.

Conclusion

In patients with testicular cancer and platinum-based chemotherapy who present with neurological symptoms, cerebral sinus venous thrombosis should be considered in the differential diagnosis. Clinicians should be aware of this rare but dangerous complication, which can be treated successfully.

Acknowledgements

We thank the patients for allowing their case and accompanying images to be published.

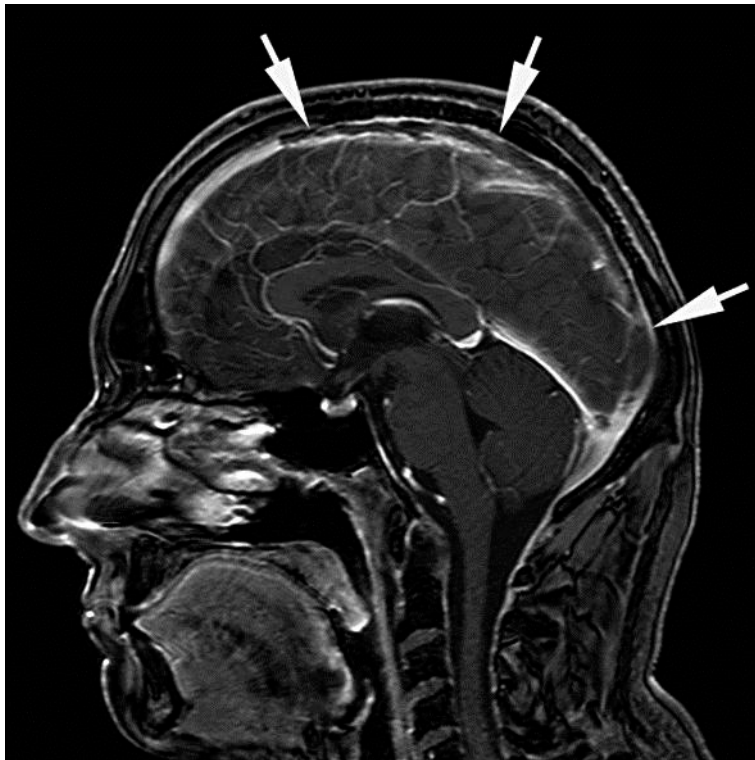


Fig. 1. Cerebral sinus venous thrombosis in the superior sagittal sinus.

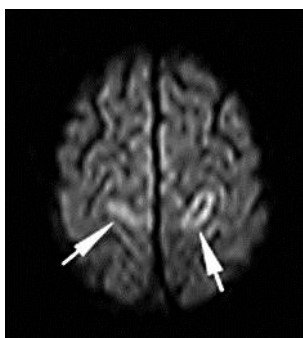


Fig. 2. Cerebral sinus venous thrombosis in the right sigmoid and both transverse sinuses with bilateral venous congestion associated with cytotoxic edema within the precentral gyri.

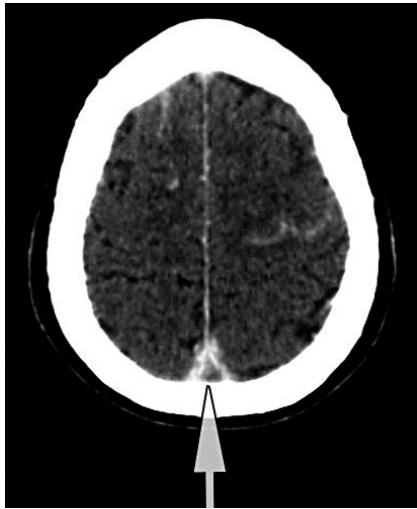

Fig. 3. Cerebral sinus venous thrombosis in the superior sagittal sinus, a subarachnoid hemorrhage in the right frontal region and the left precentral sulcus, with a hemorrhage in the right frontal lobe due to venous congestion.

References

- 1 Weijl NI, Rutten MF, Zwinderman AH, Keizer HJ, Nooy MA, Rosendaal FR, Cleton FJ, Osanto S: Thromboembolic events during chemotherapy for germ cell cancer: a cohort study and review of the literature. *J Clin Oncol* 2000;18:2169–2178.
- 2 Piketty AC, Fléchon A, Laplanche A, Nouyrigat E, Droz JP, Théodore C, Fizazi K: The risk of thromboembolic events is increased in patients with germ-cell tumours and can be predicted by serum lactate dehydrogenase and body surface area. *Br J Cancer* 2005;93:909–914.
- 3 Gerl A: Vascular toxicity associated with chemotherapy for testicular cancer. *Anticancer Drugs* 1994;5:607–614.
- 4 Schmoll HJ, Jordan K, Huddart R, Pes MP, Horwich A, Fizazi K, Kataja V; ESMO Guidelines Working Group: Testicular non-seminoma: ESMO Clinical Practice Guidelines for diagnosis, treatment and follow-up. *Ann Oncol* 2010;21(suppl 5):v147–v154.
- 5 Stam J: Cerebral venous and sinus thrombosis: incidence and causes. *Adv Neurol* 2003;92:225–232.
- 6 Ferro JM: Causes, predictors of death, and antithrombotic treatment in cerebral venous thrombosis. *Clin Adv Hematol Oncol* 2006;4:732–733.
- 7 Ferro JM, Canhão P, Stam J, Boussier MG, Barinagarrementeria F: Prognosis of cerebral vein and dural sinus thrombosis: results of the International Study on Cerebral Vein and Dural Sinus Thrombosis (ISCVT). *Stroke* 2004;35:664–670.
- 8 Saposnik G, Barinagarrementeria F, Brown RD Jr, Bushnell CD, Cucchiara B, Cushman M, deVeber G, Ferro JM, Tsai FY; American Heart Association Stroke Council and the Council on Epidemiology and Prevention: Diagnosis and management of cerebral venous thrombosis: a statement for healthcare professionals from the American Heart Association/American Stroke Association. *Stroke* 2011;42:1158–1192.
- 9 Ozen A, Cicin I, Sezer A, Uzunoglu S, Saynak M, Genchellac H, Karagol H: Dural sinus vein thrombosis in a patient with colon cancer treated with FOLFIRI/bevacizumab. *J Cancer Res Ther* 2009;5:130–132.
- 10 Vargo JA, Snelling BM, Ghareeb ER, John K, Frame JN, Schmidt JH, Peters KB: Dural venous sinus thrombosis in anaplastic astrocytoma following concurrent temozolomide and focal brain radiotherapy plus bevacizumab. *J Neurooncol* 2011;104:595–598.
- 11 Unal E, Yazar A, Koksall Y, Caliskan U, Paksoy Y, Kalkan E: Cerebral venous sinus thrombosis in an adolescent with Ewing sarcoma. *Childs Nerv Syst* 2008;24:983–986.
- 12 Basiri K, Dashti M, Fatehi F: Malignant cutaneous melanoma associated with cerebral venous sinus thrombosis. *Neurosciences (Riyadh)* 2010;15:190–192.
- 13 Karam C, Koussa S: Cerebral sinus thrombosis following cisplatin chemotherapy. *J Clin Neurosci* 2008;15:1274–1275.
- 14 Digkila A, Berthold D: A man presenting headache and photophobia while receiving BEP chemotherapy. *Schweizer Krebsbulletin* 2/2011;174–176.