

GAD antibody-associated limbic encephalitis in a young woman with APECED

Anna Kopczak^{1,2,*}, Adrian-Minh Schumacher^{3,*}, Sandra Nischwitz¹, Tania Kümpfel³,
Günter K Stalla¹ and Matthias K Auer¹

¹Max Planck Institute of Psychiatry, Clinical Neuroendocrinology Group, Munich, Germany, ²Institute for Stroke and Dementia Research and ³Institute of Clinical Neuroimmunology, Klinikum der Universität München, Ludwig-Maximilians Universität LMU, Munich, Germany

*(A Kopczak and A-M Schumacher contributed equally to this work)

Correspondence
should be addressed
to A Kopczak

Email
anna.kopczak@med.uni-muenchen.de

Summary

The autoimmune polyendocrinopathy–candidiasis–ectodermal dystrophy (APECED) syndrome is a genetic disorder caused by a mutation in the autoimmune regulator (AIRE) gene. Immune deficiency, hypoparathyroidism and Addison's disease due to autoimmune dysfunction are the major clinical signs of APECED. We report on a 21-year-old female APECED patient with two inactivating mutations in the AIRE gene. She presented with sudden onset of periodic nausea. Adrenal insufficiency was diagnosed by means of the ACTH stimulation test. Despite initiation of hormone replacement therapy with hydrocortisone and fludrocortisone, nausea persisted and the patient developed cognitive deficits and a loss of interest which led to the diagnosis of depression. She was admitted to the psychiatric department for further diagnostic assessment. An EEG showed a focal epileptic pattern. Glutamic acid decarboxylase (GAD) antibodies, which had been negative eight years earlier, were now elevated in serum and in the cerebrospinal fluid. Oligoclonal bands were positive indicating an inflammatory process with intrathecal antibody production in the central nervous system (CNS). The periodic nausea was identified as dialeptic seizures, which clinically presented as gastrointestinal aura followed by episodes of reduced consciousness that occurred about 3–4 times per day. GAD antibody-associated limbic encephalitis (LE) was diagnosed. Besides antiepileptic therapy, an immunosuppressive treatment with corticosteroids was initiated followed by azathioprine. The presence of nausea and vomiting in endocrine patients with autoimmune disorders is indicative of adrenal insufficiency. However, our case report shows that episodic nausea may be a symptom of epileptic seizures due to GAD antibodies-associated LE in patients with APECED.

Learning points:

- Episodic nausea cannot only be a sign of Addison's disease, but can also be caused by epileptic seizures with gastrointestinal aura due to limbic encephalitis.
- GAD antibodies are not only found in diabetes mellitus type 1, but they are also associated with autoimmune limbic encephalitis and can appear over time.
- Limbic encephalitis can be another manifestation of autoimmune disease in patients with APECED/APS-1 that presents over the time course of the disease.

Background

The autoimmune polyendocrine syndrome type I is an autosomal recessive disease caused by a mutation in the autoimmune regulator gene (AIRE) (1) characterized

by multiple autoimmune diseases with autoantibodies. Typically patients show hypoparathyroidism, Addison's disease and chronic mucocutaneous candidiasis. Therefore,



it is also known as autoimmune polyendocrinopathy–candidiasis–ectodermal dystrophy (APECED) syndrome.

We report on a 21-year-old female APECED patient who presented with limbic encephalitis. The diagnosis of limbic encephalitis was challenging because (A) nausea was interpreted at first only as a sign of Addison's disease and (B) autoimmune limbic encephalitis is not referred to as a common symptom of autoimmune polyendocrine syndromes. We aim to sharpen our colleagues' awareness about the clinical presentation of limbic encephalitis and establish autoimmune CNS disease as another potential clinical manifestation of autoimmune polyglandular syndromes. The case also hints towards the pathogenetic relevance of GAD antibodies in autoimmune CNS disease, since in this case, a rise in serum GAD titres preceded clinical presentation of autoimmune encephalitis, without signs of diabetes mellitus type 1.

Case presentation

The female patient presented for the first time to our endocrinological outpatient clinic for transition from the paediatric endocrinologist at the age of 18 years. APECED had been diagnosed during childhood showing the typical symptoms of hypoparathyroidism, hypothyroidism, hypogonadism and chronic mucocutaneous candidiasis. Molecular genetic testing revealed two pathogenic mutations in the AIRE gene locus (p.Met1Leu in exon 1; p.Arg257* in exon 6). On physical examination, she showed alopecia and nail dystrophy (Fig. 1A and B). Laboratory workup revealed negative glutamic acid decarboxylase (GAD) antibodies. During the following three years, the patient was seen in yearly intervals and remained stable until she developed sudden episodes of periodic nausea with vomiting.

Investigation

An acute adrenal crisis was suspected and adrenal insufficiency diagnosed with the 250 µg ACTH-test without a significant increase of cortisol from 251 nmol/L to 257 nmol/L after 30 min (normal increase >500 nmol/L) and very high ACTH levels of 192.7 pmol/L (normal range: 1.6–13.9 pmol/L). Sodium levels were low with 131 mmol/L (normal range: 135–145 mmol/L); potassium levels were in the upper normal range with 4.7 mmol/L (normal range: 3.6–5 mmol/L). Addison's disease was diagnosed, and the patient was immediately treated with hydrocortisone (HC) 20 mg/day and fludrocortisone 0.05 mg/day.

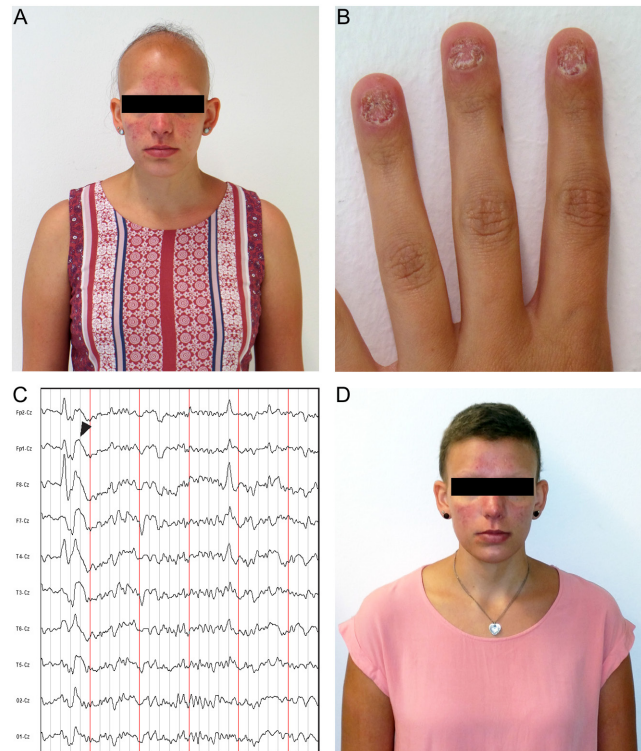


Figure 1

Female patient (21 years) with APECED presented with alopecia (A) and nail dystrophy (B). EEG at admission without antiepileptic medication showed frontotemporal sharp-slow wave discharges (C). Improvement of alopecia after 4 months of immunosuppressive treatment (D).

However, despite adequate gluco- and mineralocorticoid replacement and electrolyte normalization, recurrent nausea persisted and did not respond to antiemetic drugs. There were no signs for infectious diseases. A gastroscopy was performed without evidence for gastrointestinal disease or autoimmune gastritis. Diabetes mellitus (DM) was excluded according to unremarkable fasting glucose levels and normal HbA1c. For the first time, GAD antibodies turned out positive with highly elevated titres (>2000 IU/mL, normal <10 IU/mL) measured by enzyme-linked immunosorbent assay with human recombinant GAD isoform GAD65. In addition, the patient's psychiatric condition worsened. She reported cognitive impairment and loss of interest. Initially, depression was diagnosed and the general practitioner started a treatment with a selective serotonin reuptake inhibitor (SSRI).

Since SSRI were not well tolerated and psychiatric symptoms did not improve she was admitted to the psychiatric department for further multidisciplinary diagnostic investigations four months later. At this time point, she still suffered from episodes with nausea despite



temporary increase of HC dosage. On admission, she showed a depressive syndrome and cognitive impairment with a mini-mental state exam of 25 points. Neurological examination was normal and showed no evidence for stiff person syndrome or cerebellar syndrome.

Endocrinological workup showed no evidence of insulin-dependent diabetes mellitus (IDDM) with normal levels of HbA1c (5.2%) and fasting insulin (17.2IU/mL), and a normal glucose level (6.8mmol/L) in the oral glucose tolerance testing. Anti-pituitary antibodies were not present.

Magnetic resonance imaging of the brain revealed no pathologies. An electroencephalogram (EEG) showed a focal epileptic pattern with frontotemporal spikes, sharp waves, spike waves and slow-sharp-wave discharges (Fig. 1C). Episodic nausea was identified as dialeptic seizures which were clinically presented as gastrointestinal aura followed by episodes of reduced consciousness that occurred about 3–4 times per day. Investigation of cerebrospinal fluid (CSF) revealed a normal cell count and protein but positive oligoclonal bands indicating an inflammatory process in the central nervous system (CNS). GAD antibodies were not only elevated in serum (IgA 1:100, IgG 1:320) but also in CSF (IgG 1:100) measured by indirect immunofluorescence assessed using non-human tissues (rat hippocampus, monkey cerebellum and monkey pancreas). Phospho-Tau and β -amyloid were normal, and there was no evidence for a neurodegenerative disorder. Paraneoplastic antibodies were negative, and there was no evidence for a malignant disease.

Treatment

Diagnosis of autoimmune LE with GAD antibodies was established. Antiepileptic treatment with levetiracetam was initiated starting with a low dose of 250mg/day with rapid increase to 1500mg/day orally. Besides, a high-dose intravenous glucocorticoid therapy was given with 1000mg methylprednisolone for three days with oral taper. Thereafter, an immunosuppressive treatment with azathioprine (150mg/day) orally was initiated.

Outcome and follow-up

Three months after initiation, antiepileptic and immunosuppressive treatment resulted in a marked reduction of epileptic seizures (>50%), a slow amelioration of cognitive symptoms as well as positive effects on growth of hair (Fig. 1D) and nail integrity. Unfortunately, it has yet not been possible for her to return to work as an office

administrator. A follow-up is conducted regularly both in the endocrinology and neuroimmunology outpatient clinic.

Discussion

This case highlights two important findings: First, nausea and vomiting can not only be a symptom of Addison's disease, one of the major clinical characteristics of APECED, but may also occur as a symptom of temporal lobe epilepsy. Second, GAD antibodies have been described in patients with APECED but so far not in association with LE. The overlap of symptoms may cause a delay in diagnosing limbic encephalitis. GAD antibodies are known to be associated with LE (2). GAD is necessary for the synthesis of the inhibitory neurotransmitter γ -aminobutyric acid (GABA). Hence, antibodies against GAD might lead to a decrease in GABA levels and a shift towards excitatory systems. Our patient reported cognitive dysfunction which was associated with an increase of GAD antibodies. The presence of GAD antibodies is associated with worse cognitive performance despite the fact that epileptic seizures might also worsen cognition (3). Idiopathic generalized epileptiform seizures have been described in a girl with APECED (4), but GAD antibody-associated LE has not been reported in APECED patients so far.

From an endocrinological perspective, GAD antibodies are indicative of IDDM. This has so far not been confirmed in our patient. However, GAD antibodies can occur years before developing DM (5). GAD antibodies are a frequent finding in APECED and may affect as many as 41% of patients (6). Nevertheless, IDDM is only present in 12–18% of all APECED patients (5, 7), thus indicating that the prognostic and pathophysiological relevance of GAD antibodies seems to differ between APECED patients and patients with isolated IDDM. Usually, GAD antibodies are higher in APECED than in IDDM (5); and the presence of GAD antibodies in APECED patients is not necessarily associated with beta-cell damage, though being capable of provoking a T-cell response (8, 9). Other findings indicate that GAD antibodies may have a more important role with regard to their functional relevance on the CNS. GAD antibodies in APECED patients significantly inhibit the activity of GAD (10) possibly due to a distinct recognition pattern of GAD epitopes differentially affecting the catalytic centre of the enzyme. Thus, GAD antibodies in APECED could play a functional role in inhibiting GAD, while in patients with IDDM, GAD antibodies could be more an epiphenomenon of beta-cell destruction.



It is known that GAD antibodies in the CNS may cause stiff person syndrome, cerebellar syndrome and LE. Our patient newly developed GAD antibodies in the context of her underlying autoimmune polyendocrine syndrome and eventually presented with non-paraneoplastic LE. Interestingly, MRI brain scans showed neither hippocampal swelling nor T2/FLAIR signal increase in the temporal lobe(s). These acute findings may have been present in our patient at an earlier stage of disease. Thus, earlier MRI brain scans would have probably been able to support this diagnosis. Therapeutic intervention with immunosuppressive agents induced a measurable clinical improvement concerning the frequency of seizures. Therefore, we assume GAD antibodies to play a major role in the development of LE in our patient. Knowing that several organs can be affected from autoimmune disorders in APECED (6), we propose that the CNS can also be a potential target in patients with APECED.

Declaration of interest

The authors declare that there is no conflict of interest that could be perceived as prejudicing the impartiality of the research reported.

Funding

This research did not receive any specific grant from any funding agency in the public, commercial or not-for-profit sector.

Patient consent

Written informed consent has been obtained from the patient for publication of this article and the accompanying images.

Author contribution statement

Anna Kopczak was the treating physician during the patient's stay at the psychiatric department. Sandra Nischwitz helped with the EEG scans and with her neuroimmunological expertise. Adrian-Minh Schumacher and Tania Kümpfel are now the neuroimmunologists in charge of the patient. Matthias K Auer and Günter K Stalla are the treating endocrinologists. The manuscript was written by Anna Kopczak, Matthias K Auer and

Adrian-Minh Schumacher. It was carefully revised, especially by Tania Kümpfel, and accepted by all co-authors.

References

- 1 Eisenbarth GS & Gottlieb PA 2004 Autoimmune polyendocrine syndromes. *New England Journal of Medicine* **350** 2068–2079. (doi:10.1056/NEJMra030158)
- 2 Malter MP, Helmstaedter C, Urbach H, Vincent A & Bien CG 2010 Antibodies to glutamic acid decarboxylase define a form of limbic encephalitis. *Annals of Neurology* **67** 470–478. (doi:10.1002/ana.21917)
- 3 Takagi M, Ishigaki Y, Uno K, Sawada S, Imai J, Kaneko K, Hasegawa Y, Yamada T, Tokita A, Iseki K, *et al.* 2013 Cognitive dysfunction associated with anti-glutamic acid decarboxylase autoimmunity: a case-control study. *BMC Neurology* **13** 76. (doi:10.1186/1471-2377-13-76)
- 4 Qureshi AU, Abbas R & Ahmad TM 2011 A case of polyglandular autoimmune syndrome type I with unusual presentation. *Journal of the College of Physicians and Surgeons* **21** 187–189. (doi:10.1210/jc.81.4.1488)
- 5 Tuomi T, Björnses P, Falorni A, Partanen J, Perheentupa J, Lernmark A & Miettinen A 1996 Antibodies to glutamic acid decarboxylase and insulin-dependent diabetes in patients with autoimmune polyendocrine syndrome type I. *Journal of Clinical Endocrinology and Metabolism* **81** 1488–1494. (doi:10.1210/jcem.81.4.8636356)
- 6 Perniola R, Falorni A, Clemente MG, Forini F, Accogli E & Lobreglio G 2000 Organ-specific and non-organ-specific autoantibodies in children and young adults with autoimmune polyendocrinopathy-candidiasis-ectodermal dystrophy (APECED). *European Journal of Endocrinology* **143** 497–503. (doi:10.1530/eje.0.1430497)
- 7 Ahonen P, Myllärniemi S, Sipilä I & Perheentupa J 1990 Clinical variation of autoimmune polyendocrinopathy-candidiasis-ectodermal dystrophy (APECED) in a series of 68 patients. *New England Journal of Medicine* **322** 1829–1836. (doi:10.1056/NEJM19900628322601)
- 8 Klemetti P, Björnses P, Tuomi T, Perheentupa J, Partanen J, Rautonen N, Hinkkanen A, Ilonen J & Vaarala O 2000 Autoimmunity to glutamic acid decarboxylase in patients with autoimmune polyendocrinopathy-candidiasis-ectodermal dystrophy (APECED). *Clinical and Experimental Immunology* **119** 419–425. (doi:10.1046/j.1365-2249.2000.01167.x)
- 9 Wagner R, McNally JM, Bonifacio E, Genovese S, Foulis A, McGill M, Christie MR, Betterle C, Bosi E & Bottazzo GF 1994 Lack of immunohistological changes in the islets of nondiabetic, autoimmune, polyendocrine patients with beta-selective GAD-specific islet cell antibodies. *Diabetes* **43** 851–856. (doi:10.2337/diab.43.7.851)
- 10 Björk E, Velloso LA, Kämpe O & Karlsson FA 1994 GAD autoantibodies in IDDM, stiff-man syndrome, and autoimmune polyendocrine syndrome type I recognize different epitopes. *Diabetes* **43** 161–165. (doi:10.2337/diab.43.1.161)

Received in final form 28 March 2017

Accepted 21 April 2017