

# Bone Transport Distraction Osteogenesis in the Reconstruction of Pediatric Posttraumatic Calvarial Defects

Tarek Elbanoby, MD\*  
 Gaber M. Aly, MD†  
 Usama Abdelfattah, MD\*‡  
 Jong-Woo Choi, MD, PhD,  
 MMM†  
 Hollie A. Power, MD†  
 Yasser A. Abd El Fattah, MD‡

**Summary:** Reconstruction of posttraumatic calvarial bone defects in pediatric patients is a challenge due to the growing brain and limited autogenous bone supply. Traditional techniques such as split calvarial and particulate bone grafts are associated with prolonged operative time and significant blood loss, which is a major concern in children under the age of 3 years. Bone transport distraction osteogenesis has proven efficacy and safety in the reconstruction of other craniofacial deformities. This procedure is less invasive and requires shorter operative times and hospital stay. We report our experience with 2 cases of bone transport distraction osteogenesis for the reconstruction of large posttraumatic calvarial defects in pediatric patients. (*Plast Reconstr Surg Glob Open* 2019;7:2201; doi: 10.1097/GOX.0000000000002201; Published online 16 May 2019.)

## INTRODUCTION

Reconstruction of posttraumatic calvarial bone defects in pediatric patients remains challenging to craniofacial surgeons. The aim is to restore the anatomic structure and function to the greatest degree possible. The growth of the pediatric calvaria and the associated continuous contour changes, in addition to the higher rate of infection and extrusion, put more limitations for using alloplastic materials for reconstruction.<sup>1,2</sup> Autogenous cranioplasty with calvarial bone grafts for pediatric calvarial defects provides the optimal results in terms of biocompatibility and accommodating growth.<sup>3</sup> The advantages of using autologous bone graft include biocompatibility, strength, elasticity, easy availability, and marked resistance to infection compared with alloplastic prostheses. Furthermore, autogenous grafts accommodate a rapidly growing brain, promote osteoconduction, osteoinduction, and osteogenesis, and are therefore preferred over alloplastic materials in pediatric populations.

*Split calvarial grafts* represent the ideal tool for this purpose, replacing “like-with-like” with minimal donor site morbidity and utilizing the same operative field. The newly described *particulate grafts* have expanded the donor site of the calvarial bone, especially for large defects in young children. However, these procedures remain highly invasive, and have significant blood loss and long operative times, which is a major concern particularly in children less than 3 years.<sup>4</sup>

Distraction osteogenesis (DO) is a safe less invasive procedure which has been used for many years in orthopedic surgery and in the reconstruction of other craniofacial defects. In this article, we introduce the use of bone transport DO to reconstruct large posttraumatic calvarial defects in 2 young children with satisfactory results and long-term follow-up.

## CASE 1

A 2-year-old male patient with road traffic accident experienced extradural hematoma and was left with a right frontotemporal bone defect of  $7 \times 5 \text{ cm}^2$  (Fig. 1). At 4 months following injury, he underwent transport DO for defect reconstruction. The defect was exposed through the previous incisions and all fibrous attachments around the edges of the defect were released. Design of full-thickness bone flap to be distracted was 1–2 mm less than the width of the defect, to facilitate its mobilization during dis-

From the \*Department of Plastic and Reconstructive Surgery, Alazhar University, Cairo, Egypt; †Department of Plastic and Reconstructive Surgery, Asan Medical Centre, Seoul, Republic of Korea; and ‡Department of Diagnostic Radiology, Saudi German Hospital-Cairo.

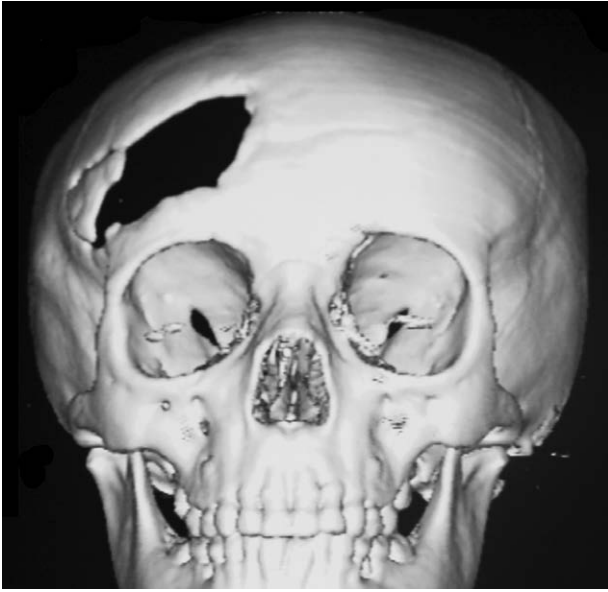
Received for publication September 30, 2018; accepted February 1, 2019.

Copyright © 2019 The Authors. Published by Wolters Kluwer Health, Inc. on behalf of The American Society of Plastic Surgeons. This is an open-access article distributed under the terms of the Creative Commons Attribution-Non Commercial-No Derivatives License 4.0 (CCBY-NC-ND), where it is permissible to download and share the work provided it is properly cited. The work cannot be changed in any way or used commercially without permission from the journal.

DOI: 10.1097/GOX.0000000000002201

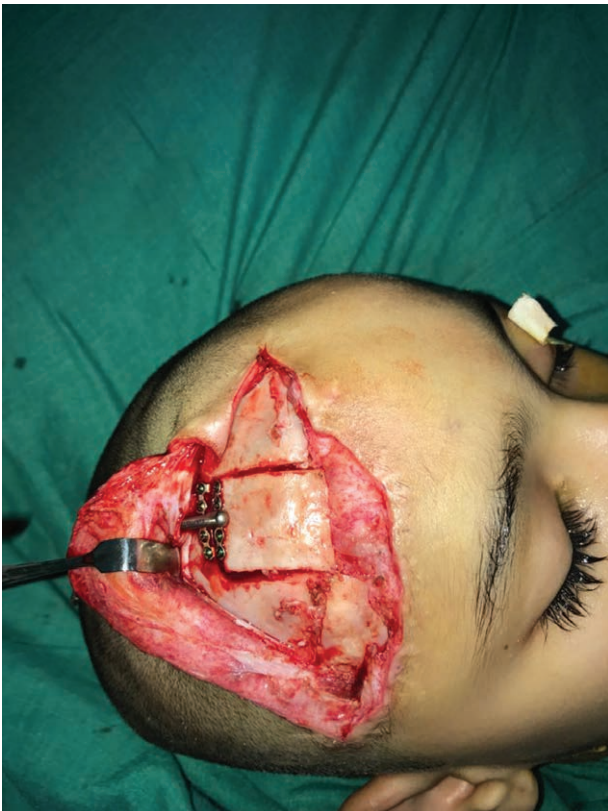**Disclosure:** The authors have no financial interest to declare in relation to the content of this article.

Supplemental digital content is available for this article. Clickable URL citations appear in the text.

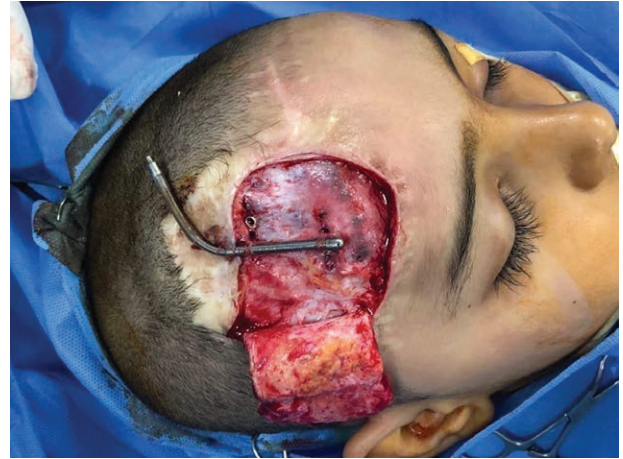

**Fig. 1.** 3D CT image, anterior view, of a male patient 28 months with a right frontotemporal bone defect of  $7 \times 5 \text{ cm}^2$ .

tractor activation (Fig. 2). Care was taken to keep a broad attachment of the bone flap to the underlying dura and avoiding dural injury. A cranial distractor was applied.



**Fig. 2.** Intraoperative photograph after the release of all fibrosis around the defect and then the design of the bone flap to be transported through DO with 1–2 mm less than the defect width using the Piezo electric saw, keeping the bone flap attached to the underlying dura, then fixation of the distractor.



**Fig. 3.** Intraoperative photograph at the time of distractor removal showing complete ossification at the site of the transported segment and the original defect with a little movement in the anterior part of the distracted bone which is fixed by 1 microplate for more stabilization.

Distraction was initiated after a 5-day latency period with 0.5 mm distraction twice daily for 50 days, followed by a 3-month consolidation period. Clinical and intraoperative findings at the removal of distractor showed complete ossification to the original site of the transferred bone segment and the original defect (Fig. 3). The same findings are obvious in CT 3D except for tiny defects mostly nonlamellar bone not apparent in x-ray (Fig. 4).

## CASE 2

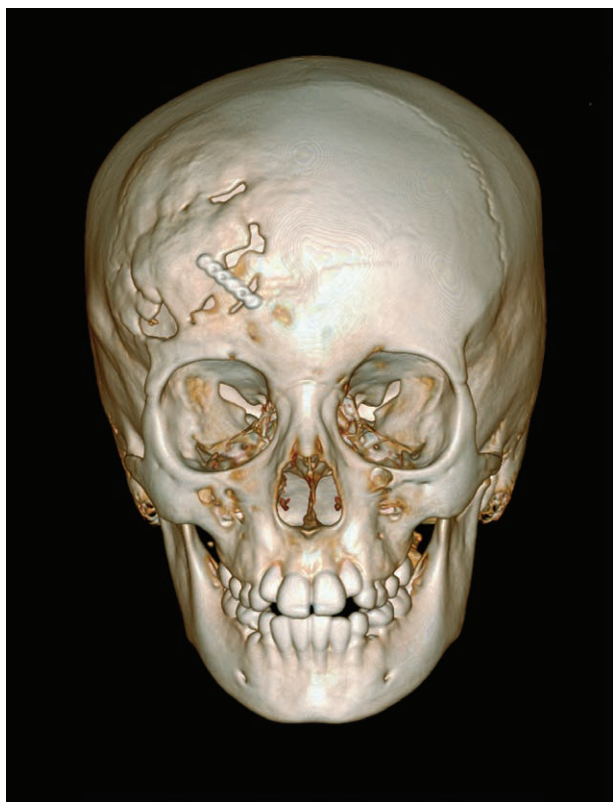A 20-month-old female with a history of decompressive craniectomy for an acute traumatic subdural hematoma. She presented 3 months after the initial trauma with 3D CT scanning showing a large  $8 \times 3.8 \text{ cm}^2$  occipitoparietal defect involving part of the lambdoid suture. We had reconstructed the defect through bone transport DO. This was approached through the previous scarring with complete release of dura around the defect; a bone flap designed to be distracted was 1–2 mm less than the width of the defect without any underlying dural dissection (see **video, Supplemental Digital Content 1**, which shows the intraoperative steps of case 2, <http://links.lww.com/PRSGO/B174>).

Distraction started after a 5-day latency period with 0.5 mm distraction twice daily for 38 days. After the 3-month consolidation period, the distractor was removed upon clinical and intraoperative findings of complete ossification to the original site of the transferred bone segment and the original defect (Table 1).

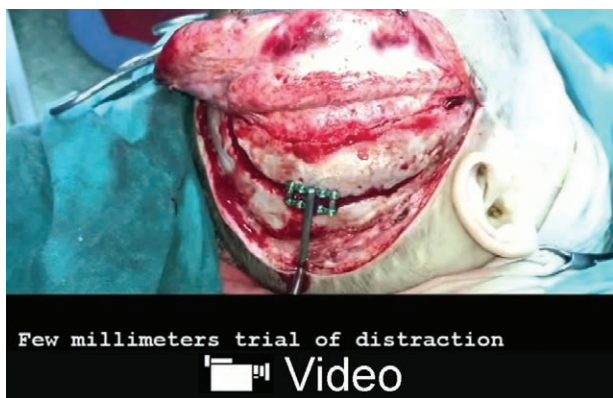## DISCUSSION

Reconstruction of posttraumatic calvarial defects in children is challenging with limited sources of autogenous grafts. Although small defects can heal spontaneously with the osteogenic potential of the dura, large defects require reconstruction. Autologous cranial bone is the ideal material to restore the native form and function of the calvar-





**Fig. 4.** Postoperative 3D reconstructed CT anterior view showing almost complete ossification of the original and transported segment defects with tiny defects which are a nonlamellar bone that was not apparent in CT.



**Video Graphic 1.** See Video, Supplemental Digital Content 1, which displays intraoperative steps of case 2. This video is available in the Related Videos section of the Full-Text article at PRSGlobalOpen.com or at <http://links.lww.com/PRSGO/B43>.

ia. Traditional reconstructive approaches including split calvarial and particulate bone grafts have limitations, as discussed above.<sup>6,7</sup> Split calvarial bone grafts have the advantage of using autologous bone in reconstruction and replacing like-with-like but add morbidity to a donor site and result in 2 reconstructions both with reduced thickness and stability.<sup>8</sup> Also, it is reported that bone grafts over the donor and recipient sites do not heal to the accurate

**Table 1. Demographic, Operative, and Postoperative Details of the 2 Patients**

Case	1	2
Age in months	24	20
Sex	Male	Female
Cause of defect	Posttraumatic	Posttraumatic
Site of defect	Frontotemporal	Temporo-occipital
Size of defect (cm <sup>2</sup> )	7×5	8×3.8
No. distractors used	1	1
Distance of distraction accomplished (cm)	4.8	3.8
Rate of distraction (mm/d)	1	1
Latency period in days	5	5
Activation period in days	50	38
Consolidation period in months	3	3
Operative time (min)	70	55
Complications	No	No
Blood loss (cm)	15	10
Follow-up period in months	8	9.5

full thickness.<sup>8,9</sup> Although harvesting the split calvarial grafts in children less than 3 years old is a controversial issue, recently Vercler et al<sup>10</sup> debunked this surgical myth with their experience in safe harvesting split cranial grafts in a large series of patients less than 3 years old. However, it should be noted that splitting bone grafts in that setting (vault reconstruction in craniosynostosis) was used for limited defect sizes compared with massive cranial defects where split cranial grafts may not be a practical exercise or may be due to the hyperossification which is an affixed fact in craniosynostosis.

Recently, particulate bone grafts have been shown to effectively heal cranial defects in children with minimal donor site morbidity<sup>11</sup>; however, they do not afford the structural integrity or resistance to resorption till complete healing, particularly in absence of rigid fixation which is the mainstay in bone graft integration.<sup>12</sup>

Bone distraction was first introduced by Codvilla 110 years ago and was popularized during the 1940s by Ilizarov.<sup>13–16</sup> Although DO has been used by orthopedic surgeons for several decades to reconstruct long bone defects, the procedure has only gained popularity for correction of craniofacial deformities in the past 2 decades. There is growing evidence of the reliability of applying bone transport DO experimentally in the management of calvarial defects in animals. Song et al<sup>17</sup> demonstrated the effectiveness and the promising results of bone regeneration (clinically, histologically, and using 3D CT) using transport DO combined with recombinant human bone morphogenetic protein-2 in dog models with large calvarial defects.

Also, Gerety et al<sup>18</sup> conducted almost similar study in sheep animal model without using any growth enhancement factors; the outcomes were evaluated and focused on radiological, histological, and mechanical properties of the resultant newly formed bone. They concluded that bone transport DO is a promising technique for cranio-plasty that may be readily translated, and the distraction rates did not have significant effects on regenerate quantity or quality.<sup>18</sup>

Bone transport DO is a simple procedure for reconstruction of pediatric calvarial defects. It offers numerous advantages: (1) it is a less invasive procedure with shorter operative time and hospital stay, requiring less tissue dissection and bone manipulation, and resulting in decreased blood loss; (2) there is less risk of growth restriction compared with bone grafting and plate fixation; and (3) there is theoretically less risk of bone resorption, particularly in large defects with a scarred soft tissue bed. Disadvantages of using DO include prolonged time to achieve a complete reconstruction, cost of the device, possible device malfunction (not observed in our cases), and the need for a second procedure to remove the device.

Our first 2 clinical cases confirmed our expectations for feasibility and outcomes of using bone transport DO as a primary approach for the reconstruction of calvarial defects in children.

**Tarek Elbanoby, MD**

Plastic and Reconstructive Surgery Department  
Alazhar University  
1st Elmokhiam Eldaem St., Madinat Nasr  
Cairo, Egypt  
E-mail: Elbanoby@Azhar.Edu.Eg

#### REFERENCES

- Vignes JR, Jeelani Nu, Dautheribes M, et al. Cranioplasty for repair of a large bone defect in a growing skull fracture in children. *J Craniomaxillofac Surg.* 2007;35:185–188.
- Lin AY, Kinsella CR Jr, Rottgers SA, et al. Custom porous polyethylene implants for large-scale pediatric skull reconstruction: early outcomes. *J Craniofac Surg.* 2012;23:67–70.
- Salam AA, Ibbett I, Thani N. Paediatric cranioplasty: a review. *Interdisciplinary Neurosurgery.* 2018;13:59–65.
- Grant GA, Jolley M, Ellenbogen RG, et al. Failure of autologous bone-assisted cranioplasty following decompressive craniectomy in children and adolescents. *J Neurosurg.* 2004;100(2 Suppl Pediatrics):163–168.
- Koenig WJ, Donovan JM, Pensler JM. Cranial bone grafting in children. *Plast Reconstr Surg.* 1995;95:1–4.
- Goodrich JT, Argamaso R, Hall CD. Split-thickness bone grafts in complex craniofacial reconstructions. *Pediatr Neurosurg.* 1992;18:195–201.
- Sahoo NK, Rangan M. Role of split calvarial graft in reconstruction of craniofacial defects. *J Craniofac Surg.* 2012;23:e326–e331.
- Lam S, Kuether J, Fong A, et al. Cranioplasty for large-sized calvarial defects in the pediatric population: a review. *Craniofac Trauma Reconstr.* 2015;8:159–170.
- Agrawal A, Garg LN. Split calvarial bone graft for the reconstruction of skull defects. *J Surg Tech Case Rep.* 2011;3:13–16.
- Vercler CJ, Sugg KB, Buchman SR. Split cranial bone grafting in children younger than 3 years old: debunking a surgical myth. *Plast Reconstr Surg.* 2014;133:822e–827e.
- Greene AK, Mulliken JB, Proctor MR, et al. Pediatric cranioplasty using particulate calvarial bone graft. *Plast Reconstr Surg.* 2008;122:563–571.
- Feroze AH, Walmsley GG, Choudhri O, et al. Evolution of cranioplasty techniques in neurosurgery: historical review, pediatric considerations, and current trends. *J Neurosurg.* 2015;123:1098–1107.
- Codvilla A. On the means of lengthening in the lower limbs, the muscles and tissues which are shortened through deformity. *Am J Orthop Surg.* 1905;2:353–369.
- Ilizarov GA. Basic principles of transosseous compression and distraction osteosynthesis. *Ortop Travmatol Protez.* 1971;32:7–15.
- Ilizarov GA. The principles of the Ilizarov method. *Bull Hosp Jt Dis Orthop Inst.* 1988;48:1–11.
- Imola MJ, Hamlar DD, Thatcher G, et al. The versatility of distraction osteogenesis in craniofacial surgery. *Arch Facial Plast Surg.* 2002;4:8–19.
- Song SY, Yun IS, Kim CH, et al. Transport distraction osteogenesis with recombinant human bone morphogenic protein-2 for large calvarial defect reconstruction. *J Craniofac Surg.* 2014;25:502–508.
- Gerety PA, Wink JD, Sherif RD, et al. Treatment of large calvarial defects with bone transport osteogenesis: a preclinical sheep model. *J Craniofac Surg.* 2014;25:1917–1922.