

CASE REPORT

Giant solitary fibrous tumor of the pleura: A case report

Baodong Liu, Lei Liu & Yuanbo Li

Department of Thoracic Surgery, Xuanwu Hospital, Capital Medical University, Beijing, China

Keywords

Double lobectomy; radiofrequency ablation; giant solitary fibrous tumors of the pleura.

Correspondence

Baodong Liu, Department of Thoracic Surgery, Xuanwu Hospital, Capital Medical University, No.45 Changchun St, Xicheng District, Beijing 100053, China.

Tel: +86 10 83198646

Fax: +86 10 63027064

Email: xwliubaodong@aliyun.com

Received: 25 June 2014;

Accepted: 7 September 2014.

doi: 10.1111/1759-7714.12175

Thoracic Cancer 6 (2015) 368–371

Introduction

Solitary fibrous tumors of the pleura (SFTP) are relatively uncommon with only 900 cases reported previously.¹ We report a patient with SFTP who showed malignant behavior and underwent a successful resection.

Case report

A 62-year-old male farmer weighing 79 kg was presented to a hospital after experiencing exertional dyspnea and shortness of breath for a month. He had no other chest complaints, such as cough, bloody sputum or chest pain. His medical history was unremarkable and he had no history of exposure to asbestos. His smoking history consisted of one pack of cigarettes per day for the past ten years. Examination of the chest revealed dullness and diminished breath sounds on the right infra-axillary and infrascapular regions. A plain chest X-ray showed a right side basal opacity masked by a moderate amount of pleural effusion (Fig 1a), and thoracic ultrasound showed a mobile effusion. A thoracocentesis drained about 600 mL of clear citrine and exudative fluid. Cytologic examination was negative for malignant cells. A contrast-enhanced computed tomography (CT) revealed a giant homogeneous mass in the right hemithorax (Fig 1b) with no evidence of chest wall or mediastinal invasion, or significant associated

Abstract

A 62-year-old male farmer weighing 79 kg was taken to a hospital after experiencing exertional dyspnea and shortness of breath for a month. A chest roentgenogram and computed tomography showed a giant mass in his right thorax. A CT-guided biopsy demonstrated a solitary fibrous tumor of the pleura (SFTP). Because of the large size of the tumor and the substantial pleural effusion in the right hemithorax, the patient was referred to our institution for radiofrequency ablation. After one month, we performed an exploratory thoracotomy to dissect the giant mass with the right, middle, and lower lobes. The measurement of the tumor was 20 cm × 18 cm × 13 cm and it weighed 3250 g. The histopathology of the resected specimen confirmed SFTP. The patient had no postoperative complications; six months after surgery, no recurrence occurred.

mediastinal shift. CT-guided transthoracic core needle biopsy demonstrated SFTP. Because of the substantial pleural effusion in the right hemithorax and the suspicion that the patient was in advanced stage, he was referred to our institution for radiofrequency ablation (RFA) of a giant SFTP. On 12 September 2013, an RFA for the large tumor was performed (Fig 1c). During the procedure, thoracocentesis drained with a pigtail catheter retrieved 2800 mL of clear citrine fluid. The patient was discharged four days after the procedure, with a pigtail catheter.

After one month, this patient was admitted to our hospital again after draining 7000 ml of pleural fluid, accumulated over the month. On the contrast-enhanced CT image, the well-circumscribed giant mass was heterogeneous and there was evidence of focal necrosis (Fig 1d). Hemoglobin and blood counts were in the normal range and hematology lab test results were normal. However, serum albumin and pre-albumin levels were abnormal. The erythrocyte sedimentation rate was 10 mm in the first hour. Tumor markers were submitted and CA-125 was 70 U/mL. Arterial blood gas analysis results were PaO₂ 64.8 mmHg and PaCO₂ 43 mmHg. Lung function tests showed a forced expiratory volume in 1 second of 2.19 L (65% of predicted). Because pleural fluid was draining at a rate of 1000 mL/day, we decided to perform an exploratory thoracotomy.

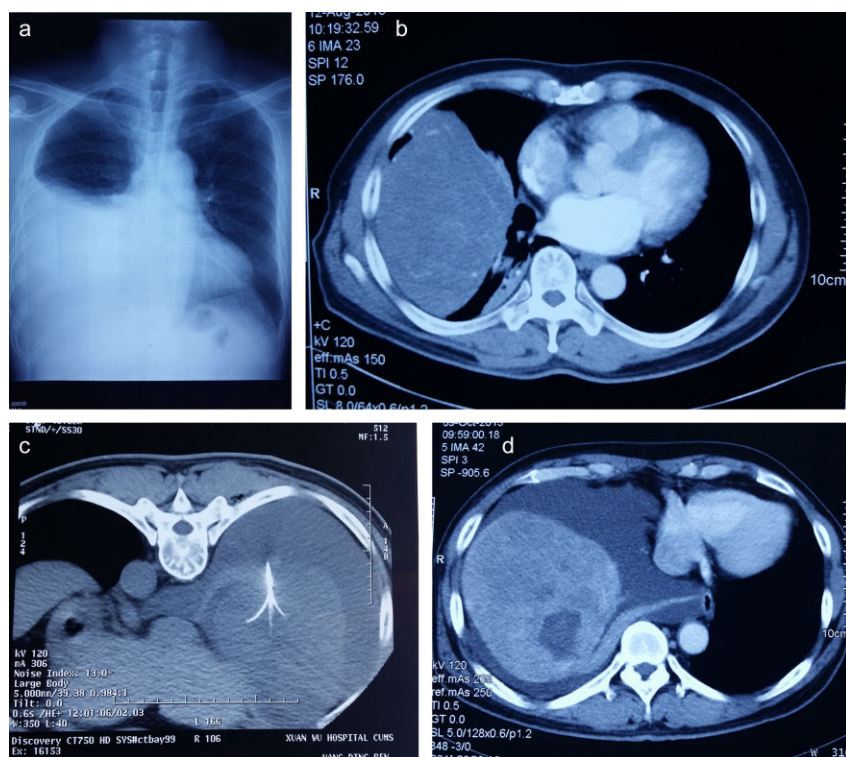


Figure 1 Chest radiography and computed tomography (CT) scan images. (a) A plain chest X-ray showed a right side basal opacity masked by a moderate amount of pleural effusion. (b) Contrast-enhanced CT showing a giant homogeneous mass in the right hemithorax. (c) Prone axial CT showing radiofrequency electrode within the mass in the right hemithorax. (d) Contrast-enhanced CT showing a well-circumscribed giant heterogeneous mass in the right hemithorax. It also shows pleural effusion and atelectasis of the right lung.

On 17 October 2013, a right lateral thoracotomy was performed through the seventh intercostal spaces. Upon entering the pleura to explore, 200 mL of clear citrine fluid was evacuated, and the parietal pleura were smooth. We could easily visualize the encapsulated circumscribed gigantic tumor, growing from the visceral pleura of the right, middle, and lower lobes, causing atelectasis of the right, middle, and lower lobes (Fig 2a). The main vascular pedicle of the tumor from the upper lobe was ligated with non-absorbable ties. A GIA stapling device (Covidien llc, Mansfield, MA, USA) was used to excise the tumor with the right, middle, and lower lobes. The volume of bleeding during the operation was 800 mL. Two drains were placed into the thorax and the incision was closed after four costal nerve branches (at the incision, above and below the incision, and one for inserting the drainage tube) were isolated and frozen for 90 seconds at -55 to -60°C . Drains were removed on the second and fourth postoperative days. The postoperative course was uneventful and the patient was discharged on the sixth day. A chest X-ray after surgery proved that the right upper lobe had expanded completely. The patient is currently alive without any recurrence six months after the surgery.

The tumor size was $20\text{ cm} \times 18\text{ cm} \times 13\text{ cm}$ and appeared smooth surfaced and well circumscribed on macroscopic

examination, weighing 3250 g (Fig 2b–d). The histological findings revealed spindle tumor cells arranged with varying amounts of collagen and hyalinization of fibrous tissue (Fig 3a,b). Mitosis was rarely present. Immunohistochemistry revealed a diffuse positivity for CD34 (Fig 4a) and Bcl-2 (Fig 4b), while cytokeratin (CK) was negative.

Discussion

Giant SFTP is a rare form of pleural disease that is only occasionally cited in the literature, usually in single cases.^{2–7} Larger tumors, more than 10 cm or 15 cm in diameter, occupying a larger space, and compressing other thoracic structures, may cause symptoms such as dyspnea, chest pain, cough, and fatigue.^{8,9} Pleural effusions are generally in small volumes; however, our case reports a volume greater than 7 L. Preoperative diagnosis of SFTP is difficult with only a chest X-ray or CT scan. A confident pre-operative diagnosis of a fibrous tumor of the pleura can be made by histologic and immunohistochemical analysis of material obtained by transthoracic Tru-Cut needle biopsy.

In this case, the tumor was huge with a large number of pleural effusions, but was not malignant; therefore we used radiofrequency ablation, instead of direct surgery. After

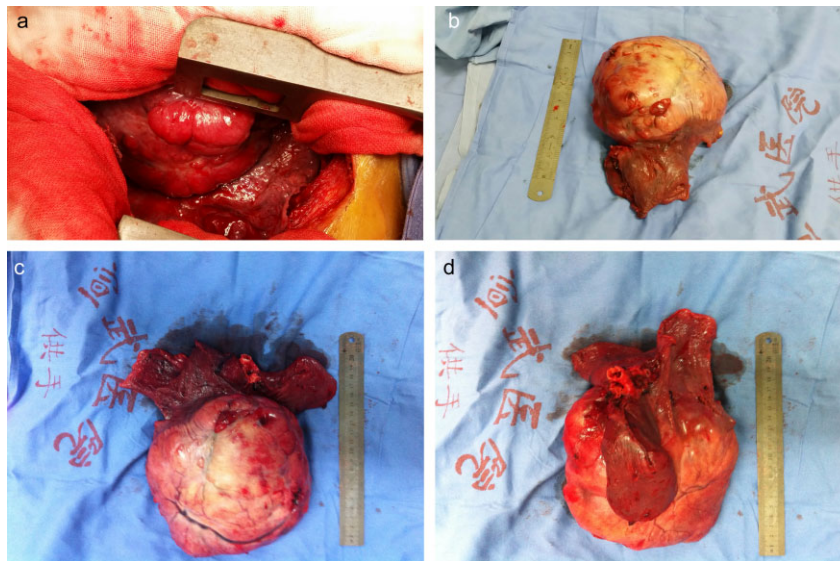


Figure 2 Tumor specimens. (a) Surgical field showing the giant mass. (b) The gigantic encapsulated tumor weighed 2870 g and measured 20 × 18 × 13 cm. (c) Costal surface of the tumor. (d) Mediastinal surface of the tumor, showing bronchus intermedius, middle, and lower lobes.

complete tumor resection, pathological results confirmed the tumor as benign. Therefore, the size of tumor and whether pleural effusion has been merged are not factors indicating malignancy.

In our opinion, every suspected or proven SFTP should be surgically treated because clinical or radiological criteria cannot accurately distinguish benign from malignant forms.

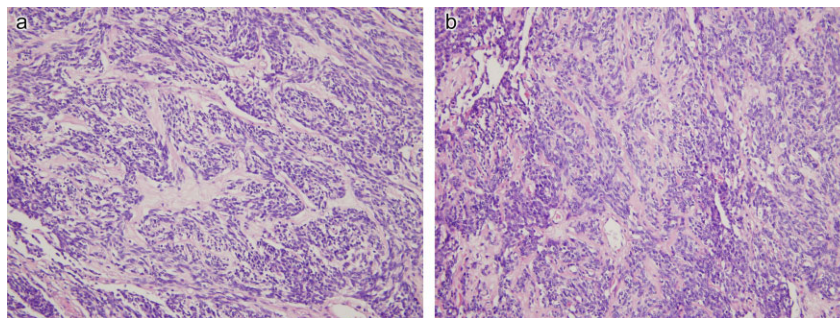


Figure 3 Microscopic examination of the solitary fibrous tumor of the pleura (SFTP). (a) Microscopic specimen of the tumor shows patternless spindle tumor cells mixed with varying amounts of collagen, and hyalinization of fibrous tissue (hematoxylin & eosin [H&E], ×200). (b) Microscopic specimen of the tumor shows spindle tumor cells with a hemangiopericytoma-like vascular pattern and areas of hyalinization (H&E, ×200).

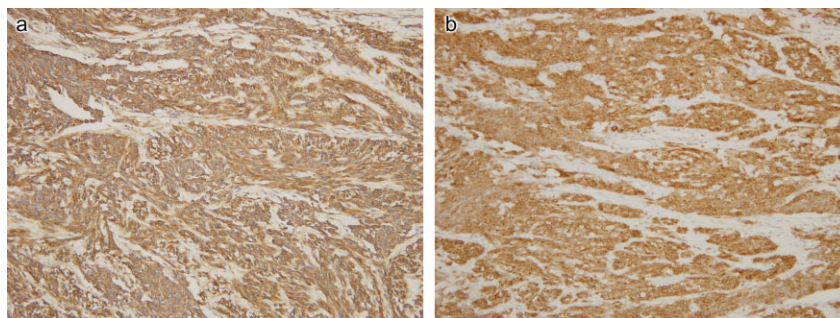


Figure 4 Spindle-shaped tumor cells show diffuse positivities for immunohistochemical staining with (a) CD34 and (b) Bcl-2 (DAB ×200).

Disclosure

No authors report any conflict of interest.

References

- 1 Harrison-Phipps KM, Nichols FC, Schleck CD *et al.* Solitary fibrous tumors of the pleura: results of surgical treatment and long-term prognosis. *J Thorac Cardiovasc Surg* 2009; **138**: 19–25.
- 2 Guo JT, Chu XY, Sun YE, Zhang LB, Zhou NK. Giant solitary fibrous tumor of the pleura: an analysis of five patients. *World J Surg* 2010; **34**: 2553–7.
- 3 Thakkar RG, Shah S, Dumbre A, Ramadwar MA, Mistry RC, Pramesh CS. Giant solitary fibrous tumour of pleura -an uncommon intrathoracic entity- a case report and review of the literature. *Ann Thorac Cardiovasc Surg* 2011; **17**: 400–3.
- 4 Filosso PL, Asioli S, Ruffini E *et al.* Radical resection of a giant, invasive and symptomatic malignant solitary fibrous tumour (SFT) of the pleura. *Lung Cancer* 2009; **64**: 117–20.
- 5 Aydemir B, Celik S, Okay T, Doğusoy I. Intrathoracic giant solitary fibrous tumor. *Am J Case Rep* 2013; **14**: 91–3.
- 6 Huang L, Chai Y. Giant fibrous tumours of the pleura with mucus secretion. *Niger J Clin Pract* 2013; **16**: 260–2.
- 7 Bodtger U, Pedersen JH, Skov BG, Clementsen P. Giant solitary fibrous tumour of the pleura: a rare but usually benign intrathoracic neoplasm. *Clin Respir J* 2009; **3**: 109–11.
- 8 Pusiol T, Pisciole I, Scialpi M, Hanspeter E. Giant benign solitary fibrous tumour of the pleura (>15 cm): role of radiological pathological correlations in management. Report of 3 cases and review of the literature. *Pathologica* 2013; **105**: 77–82.
- 9 Cardillo G, Carbone L, Carleo F *et al.* Solitary fibrous tumors of the pleura: an analysis of 110 patients treated in a single institution. *Ann Thorac Surg* 2009; **88**: 1632–7.