

Outcomes after slipped capital femoral epiphysis: a population-based study with three-year follow-up

B. Herngren^{1,2}
M. Stenmarker^{2,3}
K. Enskär⁴
G. Häggglund⁵

Abstract

Purpose To evaluate outcomes three years after treatment for slipped capital femoral epiphysis (SCFE): development of avascular necrosis (AVN), subsequent surgery, hip function and the contralateral hip.

Methods This prospective cohort study included a total national population of 379 children treated for SCFE between 2007 and 2013. A total of 449 hips treated for SCFE and 151 hips treated with a prophylactic fixation were identified. The Barnhöft questionnaire, a valid patient-reported outcome measure (PROM), was used.

Results In all, 90 hips had a severe slip, 61 of these were clinically unstable. AVN developed in 25 of the 449 hips. Six of 15 hips treated with capital realignment developed AVN. A peri-implant femur fracture occurred in three slipped hips and in two prophylactically pinned hips. In three of these five hips technical difficulties during surgery was identified. In 43 of 201 hips scheduled for regular follow-up a subsequent SCFE developed in the contralateral hip. Implant extraction after physeal closure was performed in 156 of 449 hips treated for SCFE and in 51 of 151 prophylactically fixed hips. Children with impaired hip function could be identified using the Barnhöft questionnaire.

Conclusion Fixation *in situ* is justified to remain as the primary treatment of choice in SCFE. Overweight is more common in children with SCFE than in the average population.

¹Lund University, Department of Clinical Sciences, Lund, Sweden

²Futurum - Academy for Health and Care, Jonkoping County Council, Department of Orthopaedics, Ryhov County hospital, Jonkoping, Sweden

³Institute for Clinical Sciences, Department of Paediatrics, Gothenburg University, Gothenburg, Sweden

⁴Department of Nursing, School of Health and Welfare, CHILDR Research Group, Jonkoping University, Jonkoping, Sweden

⁵Department of Orthopaedics, Skane University Hospital, Lund, Sweden

Correspondence should be sent to B. Herngren, Department of Orthopaedics, Ryhov County Hospital, S-551 85 Jonkoping, Sweden. E-mail: bengt.herngren@med.lu.se

Prophylactic fixation is a safe procedure when performed using a correct technique. The number of patients who developed AVN after capital realignment is of concern. We recommend rigorous follow-up of both hips, including PROM evaluation, until physeal closure.

Level of Evidence II - prospective cohort study

Cite this article: Herngren B, Stenmarker M, Enskär K, Häggglund G. Outcomes after slipped capital femoral epiphysis: a population-based study with three-year follow-up. *J Child Orthop* 2018;12:434-443. DOI: 10.1302/1863-2548.12.180067

Keywords: slipped capital femoral epiphysis; outcome; complications; patient-reported outcome measures

Introduction

Slipped capital femoral epiphysis (SCFE) is the most common orthopaedic condition causing groin pain at the time of the adolescent growth spurt. In SCFE, the epiphysis remains in the acetabulum while the femur usually rotates outwards and in extension.^{1,2}

The aetiology of SCFE is thought to be multifactorial. Obesity is a known risk factor.^{3,4} The severity of the slip can affect the range of hip movement and increasing loss of internal rotation and flexion capacity can follow a more severe slip.⁵ In children with a unilateral SCFE at first presentation the contralateral hip is at risk of developing a sequential slip until the proximal femoral physis is closed.⁶⁻⁸ Depending on the degree of physeal stability,⁹ severe complications such as avascular necrosis (AVN) are more common in association with unstable SCFE.¹⁰

Ideally, health-related quality of life (HRQoL) instruments, both general and disease specific, are included in the evaluation of outcomes in paediatric orthopaedic patients. In 2013, a validated Swedish hip-specific patient-reported outcome measure (PROM), called the Barnhöft questionnaire, became available.¹¹

The aim of this study was to describe the outcomes within 36 months from the primary surgery in a prospective cohort study of a total national population of children with SCFE. Analysis included complications in hips treated for SCFE and prophylactically fixed hips, subsequent surgery needed and development of a sequential SCFE. A PROM was used to measure hip function and HRQoL.

Methods

Study design

This was a prospective cohort study of a total national population of 379 children treated for SCFE between 2007 and 2013.

Inclusion criteria were: children living in Sweden, who were registered in the Swedish Population Register with a Swedish personal identity number, with SCFE in the index hip during the study period. Exclusion criteria were: SCFE because of high energy trauma or septic coxitis.

All 34 hospitals that treated SCFE in Sweden participated. The study population is described in Figure 1.

Data collection

Consecutive follow-ups were made annually for each child up to 36 months after the primary surgery, through contact with the hospital where the primary surgery or follow-up was performed.

All reported events within 36 months from the date of the primary surgery were registered based on analysis of medical records, school health records and radiographs by one of the authors (BH). Radiographic evidence of progression of the slip severity, loss of fixation, accuracy of implant placement,¹² AVN of Ficat stage III and IV osteonecrosis with at least collapse of a sequestered area into the femoral head¹³ or chondrolysis (joint space narrowing of 3 mm)^{14,15} was registered.

Re-operations and radiographic complications that did not require subsequent surgery were analyzed for all 379 children. This also included routinely scheduled surgery (e.g. extraction of implants after physal closure).

When calculating the number of subsequent procedures performed, the development of AVN was considered the end point for that specific hip; that is, no subsequent operations for these hips were included in the results.

Slip severity was graded as mild (13° to 29°), moderate (30° to 49°) or severe (> 50°).^{1,16–18} To measure slip severity, we used the calcar femorale method on a Lauenstein view¹⁹ or the Billing method on a lateral Billing view.²⁰ For both methods a minimum slip angle of 13° was required for diagnosis.^{1,19–21}

The clinical classification of stability described by Loder et al⁹ was used. An unstable SCFE was defined as one causing severe pain that makes walking impossible even with crutches, regardless of the duration of the symptoms. The postoperative radiographs were re-analyzed by one of the authors (BH), subtracting the slip angle of the preoperative film from the immediate postoperative film to determine whether a reduction had been achieved. We used the same criteria as Kennedy et al,²² in which a difference of > 10° was considered a reduction which was then classified further into intentional or incidental reductions based on the surgical reports. When the clinical classification made by the surgeon indicated a stable SCFE, this was altered in the study protocol if an obvious reduction could be visualized on postoperative radiographs.

The accuracy of implant placement within the epiphysis was graded according to the method of Pring et al¹² using anteroposterior and lateral radiographs. For a 'correct implant position', the implant had to be placed within the central 50% of the physal width, with the screw tip > 5 mm across the physis and at an angle of 70° to 90° to the capital physis. 'Poor implant position' was identified when the implant was located outside the central 75% of

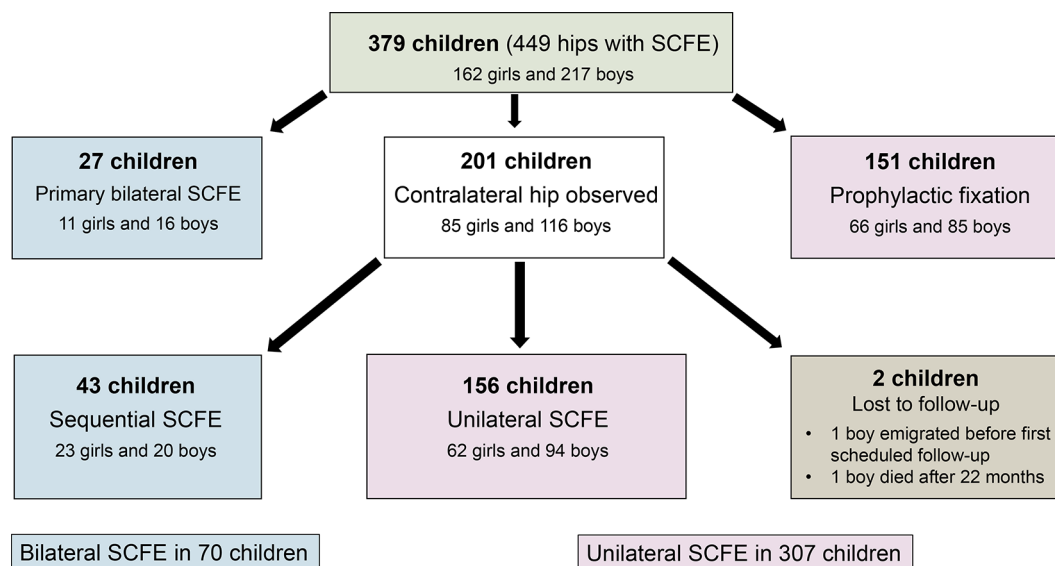


Fig. 1 Study population (SCFE, slipped capital femoral epiphysis).

the physal width, with the screw tip < 2.5 mm across the physis, tip of the implant located within < 2.5 mm from the subchondral bone, or the implant was introduced at an angle of < 50° to the physis.

All radiographs were re-analyzed by one of the authors (BH). Both inter- and intraobserver reliability of radiographic measurements for slip severity were found to be good according to the procedure of Herngren et al.²³

Body mass index (BMI)

Age-adjusted BMI was calculated using the method of Karlberg et al²⁴ for 307 of the 379 children (81%). We accepted data from within 12 months before or after the date of the primary surgery.

PROM

PROM-instruments are used to capture generic and disease-specific HRQoL issues.²⁵ The validated Barnhöft questionnaire includes a pain domain (one-item) together with a hip function domain (five-items). The pain scale in the Barnhöft questionnaire¹¹ includes a rating for each hip with a maximum of 40 points, which is equal to 'no pain at all'. The function domain is based on daily activities, including dressing, sitting, walking and stair climbing, with a maximum of 32 points. A high score indicates good hip function. From the youth version of the five-dimension EuroQol instrument (EQ-5D-Y),²⁶ a general instrument for assessing HRQoL, we chose the domain 'Feeling worried, sad, or unhappy' to be complementary to the domains covered by the Barnhöft questionnaire. The EQ-5D-VAS,²⁷ a visual analogue scale which is rated as 0 to 100 with 100 as the best health, was used as a quantitative measure of health outcome as judged by the individual respondents. Permission was obtained from the EuroQol group to use the Swedish version of the EQ-5D-Y in this study.

The questionnaires were distributed consecutively through ordinary mail 24 months after the primary surgery to 107 children diagnosed with unilateral SCFE. Two reminders were sent to those who had not returned the questionnaires.

Statistical analysis

Continuous data were checked for normality using the Kolmogorov-Smirnov test together with an analysis of the histogram and are reported as the median with minimum and maximum values. Discrete data are reported as frequencies and/or percentages. An independent sample *t*-test was used to compare mean values for continuous data between two groups that were normally distributed. To compare proportions between two independent groups, we used a cross-table and chi-squared test. The significance threshold was set at 0.05.

IBM SPSS Statistics for Windows (version 24; IBM Corp, Armonk, New York) was used for the statistical analyses.

Results

This study cohort included a total of 61 unstable hips (60 in the index hip) and 90 severe slips (89 in the index hip).

The characteristics for each subgroup of the study population are presented in Table 1. The 151 children with unilateral SCFE who received prophylactic fixation were younger than the 201 children with unilateral SCFE who were selected for scheduled radiographic and clinical follow-up ($p = 0.001$). This statistical difference was considered of clinical relevance. However, the groups did not differ significantly in the severity of the slip, clinical classification (stable/unstable) or age-adjusted BMI.

AVN

A total of 25 of 449 hips (6%) developed AVN within 36 months from the primary surgery for SCFE (Table 2). Of the 380 hips with a stable slip treated with *in situ* fixation, only five developed AVN, compared with 11 of the 56 unstable slips treated with a percutaneous fixation.

Of the 56 unstable hips treated with percutaneous internal fixation, an intentional reduction manoeuvre (traction, internal rotation and mild flexion) was performed in 32 hips and an incidental reduction from simple positioning on the operating table was described and was visualized on the postoperative radiographs in 14 hips.

Of the 41 severe unstable hips, 8/36 treated with pinning and 3/5 treated with open reduction and internal fixation (i.e. capital realignment or open reduction according to Parsch et al²⁸ developed AVN. This difference was not statistically significant.

Of the 24 unstable hips treated with percutaneous internal fixation without intention of reduction, 5/24 hips developed AVN, whereas 6/32 hips where an intentional reduction was performed developed AVN. This difference was not statistically significant.

An arthrocentesis was made in seven of the 56 unstable hips. An intentional reduction manoeuvre was performed in one and an incidental reduction occurred in five. No AVN was identified in these seven hips. Among the unstable 49 hips, where no arthrocentesis was performed, 11 hips developed AVN. This difference was not statistically significant.

Peri-implant femur fractures

In hips treated for SCFE, three peri-implant femur fractures occurred, all in the index hip. For two of these three hips, technical problems were described in the surgical reports. During the operation, either multiple entry points were

Table 1 Characteristics for the study population of 449 hips (379 children) (SCFE, slipped capital femoral epiphysis)

Group	Sex	N	Median age at surgery (range), yrs	Unstable (n)	Severe slip (n)	High BMI* (n)
27 hips	F	11	11.9 (10.6 to 15.4)	2	6	5
Index hip	M	16	12.2 (9.6 to 14.8)	3	7	9
Bilateral SCFE at first presentation						
27 hips	F	11	11.9 (10.6 to 15.4)	0	0	5
Second hip						
Bilateral SCFE at first presentation	M	16	12.2 (9.6 to 14.8)	0	0	9
43 hips	F	23	11.4 (8.4 to 14.7)	4	2	11
Index hip	M	20	12.3 (9.5 to 15.1)	4	3	14
Sequential bilateral SCFE	F	23	12.3 (9.8 to 14.8)	0	0	11
Second hip						
Sequential bilateral SCFE	M	20	13.2 (10.7 to 15.8)	1	1	14
156 hips	F	62	12.2 (9.1 to 14.6)	10	14	28
Unilateral SCFE						
No prophylactic fixation						
151 hips	M	94	13.5 (3.9 to 16.8)	19	26	56
Index hip	F	66	11.1 (7.2 to 15.1)	7	14	31
Unilateral SCFE						
Prophylactic fixation						
2 hips	M	85	13 (9.5 to 17.7)	11	17	54
Index hip	M†	1	14.5	0	0	1
Lost to follow-up						
Unilateral SCFE	M‡	1	13.5	0	0	1
TOTAL	F	196	11.7 (7.2 to 15.4)	23	36	91
449 hips						
With SCFE	M	253	13 (3.9 to 17.7)	38	54	156

*Age-adjusted body mass index (BMI) according to Karlberg et al²⁴ of 25 or above
 Values were available for only 81% of the children
 †one boy emigrated before the first scheduled follow-up
 ‡one boy died after 22 months

Table 2 Development of avascular necrosis (AVN) in 449 hips treated for slipped capital femoral epiphysis (SCFE)

Surgical procedure	Hips (n)	AVN (n)
Percutaneous internal fixation for stable SCFE	380	5*
Percutaneous internal fixation for unstable SCFE	56	11†
Capital realignment as primary surgery for stable SCFE	8‡	2
Capital realignment as primary surgery for unstable SCFE	3‡	2
Open reduction and internal fixation for unstable SCFE (Parsch et al) ²⁸	2‡	1
Capital realignment as reconstructive surgery before physeal closure	4	2
Surgery for a subsequent peri-implant femur fracture	3	2
Total		25

*two of five hips had a severe SCFE
 †eight of 11 hips had a severe SCFE; six of 11 hips had an intentional reduction manoeuvre and four had an incidental reduction
 ‡all of these hips had a severe SCFE

used for guide wire insertion before the implant was introduced or the first drill bit used was blunt and did not penetrate the cortex completely. One of these three hips developed AVN secondary to this event.

In prophylactically treated hips a peri-implant femur fracture occurred in two hips. For one of these hips, the surgical report described technical problems during surgery requiring multiple guide wire insertion attempts before a correct entry point was achieved. In the other hip, a subsequent deep infection developed that necessitated surgical wound debridement.

Chondrolysis

Chondrolysis developed in three stable severe slipped hips. Subsequent AVN later developed in two of the three hips. Penetration of the joint with an intra-articular position of the implant was observed in one of the hips.

Poor implant position

The implant position was assessed as poor in 38 of the 380 stable hips treated with *in situ* fixation for SCFE. Two

Table 3 Re-operations in 449 hips treated for slipped capital femoral epiphysis (SCFE)

Surgical procedure	Hips (n)
Routine extraction of implant after closure of the proximal physis	156
Extraction of implant after primary capital realignment	2
Early re-operation because of poor implant position (before discharge after primary surgery)	15*
Exchange of implant because of growth	13
Osteochondroplasty because of femoroacetabular impingement, closed proximal physis	9†
Change in implant because of slip progress despite internal fixation	8‡
Physiodesis around the contralateral knee because of leg-length discrepancy	5
Deep infection requiring surgical wound debridement	4**
Capital realignment procedure	4
Trochanteric overgrowth treated with apophysiodesis of the greater trochanter	2
Intertrochanteric corrective osteotomy because of limited range of movement	2††
Fixation of a peri-implant femur fracture	3

*implant position too anterior or completely outside the epiphysis
 †seven of the procedures were arthroscopy assisted
 ‡five hips with a poor implant position, a physiodesis as a secondary procedure was performed in one of these five hips
 **the hip treated with an intertrochanteric corrective osteotomy that later developed a deep infection is not counted here
 ††one hip treated with an intertrochanteric corrective osteotomy developed a deep infection that required surgical wound debridement

of the 38 hips developed AVN; one was diagnosed early and one after subsequent reconstructive surgery.

A poor implant position was also identified in 14 of the 56 unstable hips treated with percutaneous internal fixation for SCFE. Four of the 14 hips developed AVN, all of them were diagnosed early after the initial procedure.

Subsequent surgery

Of the 436 slipped hips treated with percutaneous fixation the implant was extracted as a routine procedure in 156 hips (for 22 hips the procedure had to be converted from a percutaneous to a more extensive approach). Another 67 hips were subsequently operated on for various reasons (Table 3). Of the 151 hips treated with prophylactic fixation, the implant was extracted as a routine procedure in 51 hips (five of these procedures were converted to a more extensive approach). Five of the 151 hips required further surgery for other reasons (Table 4).

PROM

A total of 87 of 107 children (81%) with a unilateral SCFE returned the questionnaires (Fig. 2). Age, gender, severity of the slip and clinical classification did not differ significantly between the non-responders (n = 20) and responders. Of the 75 children with a stable SCFE, two developed AVN and of the 12 children with an unstable SCFE, three developed AVN.

Children with a stable mild or moderate SCFE at the initial presentation (n = 66) scored a median of 30 (0 to 40) for the Barnhöft pain domain and a median of 32 (11 to 32) for the function domain. In the EQ-5D-VAS, they

Table 4 Re-operations in 151 hips treated with prophylactic fixation (SCFE, slipped capital femoral epiphysis)

Surgical procedure	Hips (n)
Routine extraction of implant after physeal closure	51
Exchange of implant because of growth	2
Re-fixation because of loss of fixation and development of a mild SCFE	1*
Fixation of a peri-implant femur fracture	2†

*the implant was placed in the correct position in the primary surgery
 †the hip subsequently developed a deep infection that required surgical wound debridement

scored a median of 88 (30 to 100). In response to the EQ-5D-Y item 'Feeling worried, sad, or unhappy', two children answered that they were 'very' worried, sad or unhappy, 12 answered that they were 'a bit' worried, sad or unhappy and 52 that they were 'not' worried, sad or unhappy.

Children with a stable severe SCFE at the initial presentation (n = 9) scored a median of 20 (0 to 40) for the Barnhöft pain domain and a median of 26 (20 to 32) for the function domain. In the EQ-5D-VAS, they scored a median of 80 (30 to 100). In response to the EQ-5D-Y item 'Feeling worried, sad, or unhappy' no child answered that he or she was 'very' worried, sad or unhappy, whereas five answered that they were 'a bit' worried, sad or unhappy, and four that they were 'not' worried, sad or unhappy.

Children who developed AVN (n = 5) scored a median of 20 (10 to 20) for the Barnhöft pain domain and a median of 24 (16 to 28) for the function domain. In the EQ-5D-VAS, they scored a median of 60 (35 to 100). In response to the EQ-5D-Y item 'Feeling worried, sad, or unhappy', two children answered that they were 'very' worried, sad or unhappy, one answered that he or she was 'a bit' worried, sad or unhappy and two that they were 'not' worried, sad or unhappy.

Discussion

The strength of this study is that all children treated for SCFE in Sweden during a seven-year period were identified and gave their informed consent to participate. The cumulative incidence for SCFE in the index hip for children 9 to 15 years old in Sweden was 40.6 per 100 000 for girls and 52.2 per 100 000 for boys for the period studied.²⁹ The male-to-female ratio was 1.3:1 and 76% of the boys and 56% of the girls were overweight or obese.²⁹ In comparison with a Swedish population of 12-year-old school children, 16% of the boys and 13% of the girls were overweight.³⁰ All participants were followed for 36 months after the primary surgery for SCFE; the only exception was one child who emigrated and another child who died. We used a hip-specific instrument for self-assessment, the Barnhöft questionnaire, which has been validated for children from eight years of age together with a general

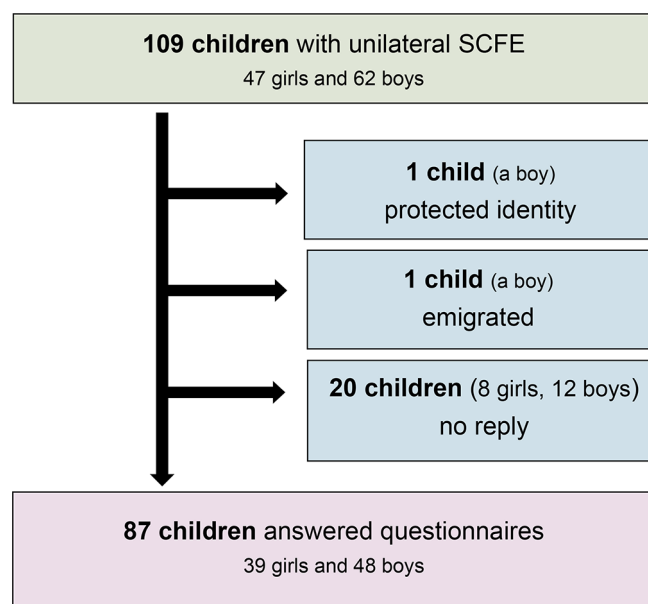


Fig. 2 Responders and non-responders to questionnaires (SCFE, slipped capital femoral epiphysis).

health status questionnaire, the EQ-5D-Y including the EQ-5D-VAS. Outcome studies for children with orthopaedic disorders should include aspects beyond radiographic findings or surgical complications.

AVN

AVN is the most devastating complication of SCFE. Unstable SCFE increases the risk of AVN, and the risk increases further with slip severity.^{31,32} Loder et al⁹ found AVN in 47% of the cases in their series of 55 patients with unstable SCFE treated with internal fixation. Chen et al³³ reported that four of 30 unstable hips treated with gentle positioning and internal fixation developed AVN. In a recent review of the literature, Loder³⁴ estimated the historical average of AVN as 21% but found that more recent studies show promising results with a lower AVN rate after urgent reduction, decompression and fixation or open reduction and fixation. However, Loder³⁴ noted some concerns about the accuracy of the definition of an 'unstable SCFE' used in some of the studies. In the present study, AVN occurred in 25 of 449 hips (6%). In all, 14 of these 25 AVN occurred in the group of 61 unstable hips.

Kinking of the retinacular vessels was reported in an angiographic study of unstable SCFE with restoration of blood supply after reduction.³⁵ Jackson et al³⁶ used perioperative angiography in nine patients who underwent a capital realignment procedure. They showed that blood flow was restored after reduction for four of six patients who did not have arterial flow to the femoral head on the preoperative angiogram. Novais et al³⁷ used different techniques in the perioperative setting for 29 patients with unstable SCFE who underwent a capital realignment

procedure to evaluate the restoration of blood flow to the femoral head during the operation. They concluded that assessment of femoral head blood perfusion can be used as a predictor of the later development of AVN. In our study, only three capital realignment procedures were performed as primary surgery for unstable hips with SCFE, and different techniques were used to assess blood flow to the femoral head at surgery. However, two of these three hips developed AVN.

Partial reduction to the position before the acute component of the slip, using an open approach for hip joint decompression and reduction on a regular operating table, is associated with AVN rates of less than 5% at five years.²⁸ Kennedy et al²² analyzed the outcomes for 27 unstable hips with SCFE. Four of the 27 unstable hips developed AVN, but no association was found with the reduction or magnitude of the slip. Chen et al³³ used gentle positioning only and no forceful reduction for 30 unstable hips followed for a minimum of two years. They performed arthrocentesis or open capsulotomy in 21 hips. Four of the 30 hips developed AVN. Using the surgical reports in our study, we were able to determine whether an intentional or an incidental reduction was achieved. We found no statistically significant difference of the development of AVN between the group (n = 32) where an intentional reduction manoeuvre and percutaneous internal fixation was performed compared with the group (n = 24) where only an incidental reduction or no reduction was implemented.

The presence of an increased intracapsular hip pressure and the effect of joint decompression has been studied in unstable hips with SCFE with divergent conclusions.^{38,39} In the present study, we analyzed the development of AVN after joint decompression (n = 7) versus no joint decompression (n = 49) in 56 unstable hips treated with percutaneous internal fixation. The number of hips that had a joint decompression procedure was limited and we found no statistically significant difference between the groups.

Timing of surgery is thought to be crucial to the development of AVN. It is also thought that surgery should be performed within 24 hours from the onset of symptoms.⁴⁰⁻⁴² In the present study, no preoperative traction or prolonged bed rest was used. All patients with an unstable hip intended for percutaneous internal fixation were brought to the operating room within 24 hours after admission to hospital. However, it was not possible to analyze the data regarding the exact onset of symptoms counted in hours.

Routine extraction of an implant after physeal closure

For most of the 156 hips treated with implant extraction after physeal closure, the procedure was performed without any reason outlined in the medical reports other than a scheduled routine procedure. There is little evidence to

support this as a routine procedure in a child without any symptoms related to the implant.^{43–46} The appearance of complications after removal of hardware in hips treated for SCFE depends on the implant used.^{47,48}

For 51 of the 151 hips treated with a prophylactic fixation in this study, a similar subsequent routine extraction was performed.

Some of these children might have had localized pain around a protruding implant but for 22 hips treated for SCFE and five hips treated with prophylactic fixation the extraction procedure had to be converted from a percutaneous procedure to a more extensive approach due to technical difficulties. However, there were no secondary complications reported to these procedures. There is a risk that future surgery might be more difficult and require a two-stage approach but the evidence supporting routine removal of all hip implants in children treated for SCFE is limited.⁴³

Prophylactic fixation

Prophylactic fixation remains a controversial issue for unilateral SCFE. However, there is no controversy about the need for prophylactic fixation in children with a concomitant endocrine disorder.⁶

Proponents of prophylactic fixation stress the risks for a subsequent contralateral slip with functional limitations or AVN if an unstable slip develops, risk of osteoarthritis and a low risk of iatrogenic complications associated with modern techniques.^{6,49,50} Others support the idea of clinical and radiographic follow-up until physeal closure.^{8,51–53} Some have tried to present an algorithm in which prophylactic fixation is offered to children with a higher risk of developing a sequential slip in the contralateral hip based on skeletal immaturity,^{54,55} gender^{50,55} and modified Oxford bone age score.⁵⁶ Compliance regarding the family's ability to return for regular follow-up visits has also been proposed as a factor to consider.⁵²

In this cohort study, after excluding one hip with obvious technical difficulties observed during surgery leading to a peri-implant femur fracture, we identified no AVN in this group of 151 hips and only one peri-implant femur fracture occurred. However, we question the routine use of implant extraction after physeal closure.^{43–46} The low number of complications within 36 months from surgery involving prophylactic fixation in this study does not show that this routine is linked to serious complications. Use of a correct technique (i.e. a satisfactory entry point established and maintained with the aid of optimal fluoroscopy views and sharp drill bits) is crucial. We note that, for the 70 children with a bilateral SCFE (27 had bilateral SCFE at the initial presentation), only one child developed a severe and unstable SCFE in the other hip (one of the 43 sequential hips with SCFE); this rate is similar to that in some

reports^{51,57} but contrasts with that of other reports.^{6,58–60} A regular follow-up schedule, with repeated radiographs together with repeated and thorough information given to the family about the necessity for an urgent radiographic examination whenever symptoms occur in the contralateral hip, might explain the difference between reports.

In this cohort study the group selected for prophylactic fixation (n = 151) included younger children than those scheduled for regular follow-up, but no differences were found concerning age-adjusted BMI, clinical classification or slip severity. There was one child who developed SCFE in spite of a prophylactic fixation. The number of children that were selected for scheduled follow-up (for most children with an interval of three to four months) with available data at follow-up were 199 (initially 201 but two were lost to follow-up). We could then calculate the absolute risk reduction: 21.6% (43/199) minus 0.7% (1/151) which equals 20.9%. The 'Number Needed to Treat' would then become 4.8 (1/0.209). If a prophylactic fixation would have been offered to all 352 children with a primarily unilateral SCFE, then 74 children of the 352 would have been prevented from a subsequent SCFE in the contralateral hip. The consequence would then be that 5/352 children would have to change implant due to further growth of the femoral neck, five would develop a peri-implant femur fracture and of these five, two would develop a deep infection secondary to a peri-implant femur fracture. However, extraction of implants after physeal closure would in most cases not be necessary and we believe that the number of peri-implant femur fractures could be further reduced using a correct technique.

In summary, this calculation gives us a total risk of 2/352 deep infections (0.5%) and 5/352 (1.4%) peri-implant femur fractures if all 352 children with a unilateral SCFE had received a prophylactic fixation of the contralateral hip. These figures are similar to what has been reported previously^{49,61,62} and prophylactic fixation has been found to be a cost-effective procedure that limits the morbidity from the complications of a further slip.^{8,63}

Peri-implant femur fractures

Five hips with a peri-implant femur fracture were identified in this study. Two of these complications occurred in hips after prophylactic fixation. Technical difficulties might have been the cause for these complications in three of five hips. In obese children it might be more difficult to obtain an optimal fluoroscopic view. Therefore, specific precautions ought to be considered even while positioning the child on a suitable operating table so that a correct lateral view can be obtained at surgery during insertion of the implant. The subsequent use of sharp drill-bits together with a surgical technique that creates access at the first attempt to the correct entry point for the guide

wire are both crucial for high-quality surgery. The number of peri-implant femur fractures in this study was similar to that in other reports.^{61,64,65}

PROM

From the child's perspective, it has been found that a range of issues about health are important to discuss.⁶⁶ When healthcare professionals have access to information about the child's HRQoL assessment, it is more likely that they will discuss the issues with the child.⁶⁷ Children also want to answer questions about their health status if they understand the reason behind the questions, if they feel that the questions are relevant and when they notice that their answers are received and commented upon.⁶⁸ To increase the number of domains used for comparison, we chose to use one dimension ('Feeling worried, sad, or unhappy') in the EQ-5D-Y that addresses problems that are more common in children's lives than impairment of mobility, self-care or everyday activities.²⁶ The previous validation study of the Barnhöft questionnaire¹¹ proposed that this questionnaire could be used together with the EQ-5D-Y as a screening tool to identify children with a complication of SCFE or a more severe slip. The results in this study confirm these preliminary results. There was one child in each group of stable mild-moderate and stable severe SCFE, respectively, that had no complications to SCFE but still scored very low in the pain domain of the Barnhöft questionnaire, thus indicating the need for a clinical follow-up to be able to analyze the actual health status in more detail.

We suggest that a child with a score of < 20 for the pain domain of the Barnhöft questionnaire and a score of < 26 for the function domain or a score of < 60 in the EQ-5D-VAS needs a more thorough analysis together with a clinical follow-up. Children who unexpectedly report a lower hip function or severe pain (e.g. without the development of AVN or an initial severe slip) need an individualized assessment.

Conclusions

It is justified that fixation *in situ* should remain as the primary treatment of choice in stable SCFE. A gentle incidental reduction performed together with a percutaneous internal fixation gives acceptable results in unstable SCFE. Being overweight or obese is more common in children with SCFE than the average population. Prophylactic fixation is a safe procedure when performed using the correct technique. The number of patients who developed AVN after capital realignment is of concern. The Barnhöft instrument could be used as a screening tool to identify children with severe pain or with a considerable limitation of hip function after being treated for SCFE. We recommend rigorous follow-up, including PROM evaluation, until physeal closure.

Limitations

Because of the limited follow-up of 36 months for each child, late complications or surgeries were not included.

The 379 children were treated with routine care in 34 different hospitals and it was not possible to confirm hip effusion with ultrasonography or magnetic resonance tomography for clinically unstable hips.

The surgical reports might not have covered all technical difficulties, such as the use of multiple entry points for the guide wire before the implant insertion was accomplished.

We could not evaluate the time from the onset of symptoms to surgery for the 61 unstable hips with SCFE (i.e. the actual timing of surgery counted in hours).

A PROM was not used during the entire study period. The questionnaires were developed in Swedish for children from eight years of age after the inclusion period started. Only children with a unilateral SCFE were included. Unlike the setup used by the original developer of the Children's Hospital Oakland Hip Evaluation Scale (CHOHES),⁶⁹ the questionnaires were not distributed during a scheduled follow-up visit but through ordinary mail. We did not consider it possible for all children, from eight years of age, to comply with the Barnhöft hip-specific questionnaire if both hips were affected without professional assistance for guidance.

Received 24 April 2018; accepted after revision 19 July 2018.

COMPLIANCE WITH ETHICAL STANDARDS

FUNDING STATEMENT

This study was funded only by institutional grants: Futurum - Academy for Health and Care, Jonköping County Council, Sweden, grant number F-767911.

OA LICENCE TEXT

This article is distributed under the terms of the Creative Commons Attribution-Non Commercial 4.0 International (CC BY-NC 4.0) licence (<https://creativecommons.org/licenses/by-nc/4.0/>) which permits non-commercial use, reproduction and distribution of the work without further permission provided the original work is attributed.

ETHICAL STATEMENT

Ethical approval: Ethical approval for the study was authorized by the Regional Ethical Review Board. The study was in accordance with the ethical principles of the 1964 Declaration of Helsinki for medical research involving humans and its later amendments.

Informed consent: Informed consent was obtained from all individual participants included in the study and one parent or guardian of each child.

Availability of data and materials: The datasets used and/or analyzed during the current study are available from the corresponding author on reasonable request.

ICMJE CONFLICT OF INTEREST STATEMENT

None declared.

REFERENCES

1. **Jerre R.** Physiolyis of the hip: epidemiology, diagnosis and long-term follow-up [unpublished doctoral dissertation]. Department of Orthopaedics, Institute of Surgical Sciences, Gothenburg University, Gothenburg, Sweden, 1995.
2. **Loder RT.** Unstable slipped capital femoral epiphysis. *J Pediatr Orthop* 2001;21:694-699.
3. **Nasreddine AY, Heyworth BE, Zurakowski D, Kocher MS.** A reduction in body mass index lowers risk for bilateral slipped capital femoral epiphysis. *Clin Orthop Relat Res* 2013;471:2137-2144.
4. **Nguyen AR, Ling J, Gomes B, et al.** Slipped capital femoral epiphysis: rising rates with obesity and aboriginality in South Australia. *J Bone Joint Surg [Br]* 2011;93-B:1416-1423.
5. **Schoenecker PL, Gordon JE, Luhmann SJ, et al.** A treatment algorithm for stable slipped capital femoral epiphysis deformity. *J Pediatr Orthop* 2013;33:S103-S111.
6. **MacLean JG, Reddy SK.** The contralateral slip. An avoidable complication and indication for prophylactic pinning in slipped upper femoral epiphysis. *J Bone Joint Surg [Br]* 2006;88-B:1497-1501.
7. **Schur MD, Andras LM, Broom AM, et al.** Continuing Delay in the Diagnosis of Slipped Capital Femoral Epiphysis. *J Pediatr* 2016;177:250-254.
8. **Baghdadi YM, Larson AN, Sierra RJ, Peterson HA, Stans AA.** The fate of hips that are not prophylactically pinned after unilateral slipped capital femoral epiphysis. *Clin Orthop Relat Res* 2013;471:2124-2131.
9. **Loder RT, Richards BS, Shapiro PS, Reznick LR, Aronson DD.** Acute slipped capital femoral epiphysis: the importance of physeal stability. *J Bone Joint Surg [Am]* 1993;75-A:1134-1140.
10. **Sankar WN, McPartland TG, Millis MB, Kim YJ.** The unstable slipped capital femoral epiphysis: risk factors for osteonecrosis. *J Pediatr Orthop* 2010;30:544-548.
11. **Herngren B, Stenmarker M, Enskär K.** Barnhöft: a hip specific 6-item questionnaire for children. *J Patient Rep Outcomes* 2017;1:16-24.
12. **Pring M, Adamczyk M, Hosalkar HS, et al.** In situ screw fixation of slipped capital femoral epiphysis with a novel approach: a double-cohort controlled study. *J Child Orthop* 2010;4:239-244.
13. **Ficat RP.** Idiopathic bone necrosis of the femoral head. Early diagnosis and treatment. *J Bone Joint Surg [Br]* 1985;67-B:3-9.
14. **Ingram AJ, Clarke MS, Clarke CS Jr, Marshall WR.** Chondrolysis complicating slipped capital femoral epiphysis. *Clin Orthop Relat Res* 1982;165:99-109.
15. **Tudisco C, Caterini R, Farsetti P, Potenza V.** Chondrolysis of the hip complicating slipped capital femoral epiphysis: long-term follow-up of nine patients. *J Pediatr Orthop B* 1999;8:107-111.
16. **Loder RT, Starnes T, Dikos G, Aronsson DD.** Demographic predictors of severity of stable slipped capital femoral epiphyses. *J Bone Joint Surg [Am]* 2006;88-A:97-105.
17. **Hansson G, Billing L, Högstedt B, Jerre R, Wallin J.** Long-term results after nailing in situ of slipped upper femoral epiphysis. A 30-year follow-up of 59 hips. *J Bone Joint Surg [Br]* 1998;80-B:70-77.
18. **Bellemore JM, Carpenter EC, Yu NY, Birke O, Little DG.** Biomechanics of slipped capital femoral epiphysis: evaluation of the posterior sloping angle. *J Pediatr Orthop* 2016;36:651-655.
19. **Hansson LI, Hägglund G, Ordeberg G, Sandström S.** The calcar femorale as a landmark in hip physiolyis. *Acta Orthop Scand* 1988;59:134-138.
20. **Billing L, Bogren HG, Wallin J.** Reliable X-ray diagnosis of slipped capital femoral epiphysis by combining the conventional and a new simplified geometrical method. *Pediatr Radiol* 2002;32:423-430.
21. **Billing L.** Roentgen examination of the proximal femur end in children and adolescents; a standardized technique also suitable for determination of the collum-, anteversion-, and epiphyseal angles; a study of slipped epiphysis and coxa plana. *Acta Radiol Suppl* 1954;110:1-80.
22. **Kennedy JG, Hresko MT, Kasser JR, et al.** Osteonecrosis of the femoral head associated with slipped capital femoral epiphysis. *J Pediatr Orthop* 2001;21:189-193.
23. **Herngren B, Lindell M, Hägglund G.** Good inter- and intraobserver reliability for assessment of the slip angle in 77 hip radiographs of children with a slipped capital femoral epiphysis. *Acta Orthop* 2018;89:217-221.
24. **Karlberg J, Luo ZC, Albertsson-Wikland K.** Body mass index reference values (mean and SD) for Swedish children. *Acta Paediatr* 2001;90:1427-1434.
25. **Meadows KA.** Patient-reported outcome measures: an overview. *Br J Community Nurs* 2011;16:146-151.
26. **Wille N, Badia X, Bonsel G, et al.** Development of the EQ-5D-Y: a child-friendly version of the EQ-5D. *Qual Life Res* 2010;19:875-886.
27. **Feng Y, Parkin D, Devlin NJ.** Assessing the performance of the EQ-VAS in the NHS PROMs programme. *Qual Life Res* 2014;23:977-989.
28. **Parsch K, Weller S, Parsch D.** Open reduction and smooth Kirschner wire fixation for unstable slipped capital femoral epiphysis. *J Pediatr Orthop* 2009;29:1-8.
29. **Herngren B, Stenmarker M, Vavruch L, Hägglund G.** Slipped capital femoral epiphysis: a population-based study. *BMC Musculoskelet Disord* 2017;18:304.
30. **de Munter JS, Friedl A, Lind S, et al.** Stability in the prevalence of Swedish children who were overweight or obese in 2003 and 2011. *Acta Paediatr* 2016;105:1173-1180.
31. **Tokmakova KP, Stanton RP, Mason DE.** Factors influencing the development of osteonecrosis in patients treated for slipped capital femoral epiphysis. *J Bone Joint Surg [Am]* 2003;85-A:798-801.
32. **Palocaren T, Holmes L, Rogers K, Kumar SJ.** Outcome of in situ pinning in patients with unstable slipped capital femoral epiphysis: assessment of risk factors associated with avascular necrosis. *J Pediatr Orthop* 2010;30:31-36.
33. **Chen RC, Schoenecker PL, Dobbs MB, et al.** Urgent reduction, fixation, and arthrotomy for unstable slipped capital femoral epiphysis. *J Pediatr Orthop* 2009;29:687-694.
34. **Loder RT.** What is the cause of avascular necrosis in unstable slipped capital femoral epiphysis and what can be done to lower the rate? *J Pediatr Orthop* 2013;33:S88-S91.
35. **Maeda S, Kita A, Funayama K, Kokubun S.** Vascular supply to slipped capital femoral epiphysis. *J Pediatr Orthop* 2001;21:664-667.
36. **Jackson JB III, Frick SL, Brighton BK, et al.** Restoration of blood flow to the proximal femoral epiphysis in unstable slipped capital femoral epiphysis by modified Dunn procedure: a preliminary angiographic and intracranial pressure monitoring study. *J Pediatr Orthop* 2018;38:94-99.

37. **Novais EN, Sink EL, Kestel LA, et al.** Is assessment of femoral head perfusion during modified Dunn for unstable slipped capital femoral epiphysis an accurate indicator of osteonecrosis? *Clin Orthop Relat Res* 2016;474:1837-1844.
38. **Herrera-Soto JA, Duffy MF, Birnbaum MA, Vander Have KL.** Increased intracapsular pressures after unstable slipped capital femoral epiphysis. *J Pediatr Orthop* 2008;28:723-728.
39. **Ibrahim T, Mahmoud S, Riaz M, Hegazy A, Little DG.** Hip decompression of unstable slipped capital femoral epiphysis: a systematic review and meta-analysis. *J Child Orthop* 2015;9:113-120.
40. **Kalogrianitis S, Tan CK, Kemp GJ, Bass A, Bruce C.** Does unstable slipped capital femoral epiphysis require urgent stabilization? *J Pediatr Orthop B* 2007;16:6-9.
41. **Phillips SA, Griffiths WE, Clarke NM.** The timing of reduction and stabilisation of the acute, unstable, slipped upper femoral epiphysis. *J Bone Joint Surg [Br]* 2001;83-B:1046-1049.
42. **Kohno Y, Nakashima Y, Kitano T, et al.** Is the timing of surgery associated with avascular necrosis after unstable slipped capital femoral epiphysis? A multicenter study. *J Orthop Sci* 2017;22:112-115.
43. **Raney EM, Freccero DM, Dolan LA, et al.** Evidence-based analysis of removal of orthopaedic implants in the pediatric population. *J Pediatr Orthop* 2008;28:701-704.
44. **Crandall DG, Gabriel KR, Akbarnia BA.** Second operation for slipped capital femoral epiphysis: pin removal. *J Pediatr Orthop* 1992;12:434-437.
45. **Jago ER, Hindley CJ.** The removal of metalwork in children. *Injury* 1998;29:439-441.
46. **Kahle WK.** The case against routine metal removal. *J Pediatr Orthop* 1994;14:229-237.
47. **Ilchmann T, Parsch K.** Complications at screw removal in slipped capital femoral epiphysis treated by cannulated titanium screws. *Arch Orthop Trauma Surg* 2006;126:359-363.
48. **Gruber MA, Starkweather KD, Healy WA III, Haralabatos S.** Percutaneous screw removal in slipped upper femoral epiphysis. *J Bone Joint Surg [Br]* 1996;78-B:137-139.
49. **Dewnany G, Radford P.** Prophylactic contralateral fixation in slipped upper femoral epiphysis: is it safe? *J Pediatr Orthop B* 2005;14:429-433.
50. **Hägglund G.** The contralateral hip in slipped capital femoral epiphysis. *J Pediatr Orthop B* 1996;5:158-161.
51. **Jerre R, Billing L, Hansson G, Wallin J.** The contralateral hip in patients primarily treated for unilateral slipped upper femoral epiphysis. Long-term follow-up of 61 hips. *J Bone Joint Surg [Br]* 1994;76-B:563-567.
52. **Kocher MS, Bishop JA, Hresko MT, et al.** Prophylactic pinning of the contralateral hip after unilateral slipped capital femoral epiphysis. *J Bone Joint Surg [Am]* 2004;86-A:2658-2665.
53. **Hansson G, Nathorst-Westfelt J.** Management of the contralateral hip in patients with unilateral slipped upper femoral epiphysis: to fix or not to fix--consequences of two strategies. *J Bone Joint Surg [Br]* 2012;94-B:596-602.
54. **Loder RT, Starnes T, Dikos G.** Atypical and typical (idiopathic) slipped capital femoral epiphysis. Reconfirmation of the age-weight test and description of the height and age-height tests. *J Bone Joint Surg [Am]* 2006;88-A:1574-1581.
55. **Riad J, Bajelidze G, Gabos PG.** Bilateral slipped capital femoral epiphysis: predictive factors for contralateral slip. *J Pediatr Orthop* 2007;27:411-414.
56. **Popejoy D, Emara K, Birch J.** Prediction of contralateral slipped capital femoral epiphysis using the modified Oxford bone age score. *J Pediatr Orthop* 2012;32:290-294.
57. **Castro FP Jr, Bennett JT, Doulens K.** Epidemiological perspective on prophylactic pinning in patients with unilateral slipped capital femoral epiphysis. *J Pediatr Orthop* 2000;20:745-748.
58. **Nowicki PD, Silva S, Toelle L, et al.** Severity of asynchronous slipped capital femoral epiphyses in skeletally immature versus more skeletally mature patients. *J Pediatr Orthop* 2017;37:e23-e27.
59. **Yildirim Y, Bautista S, Davidson RS.** Chondrolysis, osteonecrosis, and slip severity in patients with subsequent contralateral slipped capital femoral epiphysis. *J Bone Joint Surg [Am]* 2008;90-A:485-492.
60. **Hägglund G, Hansson LI, Ordeberg G, Sandström S.** Bilaterality in slipped upper femoral epiphysis. *J Bone Joint Surg [Br]* 1988;70-B:179-181.
61. **Sankar WN, Novais EN, Lee C, et al.** What are the risks of prophylactic pinning to prevent contralateral slipped capital femoral epiphysis? *Clin Orthop Relat Res* 2013;471:2118-2123.
62. **Kumm DA, Schmidt J, Eisenburger SH, Rütt J, Hackenbroch MH.** Prophylactic dynamic screw fixation of the asymptomatic hip in slipped capital femoral epiphysis. *J Pediatr Orthop* 1996;16:249-253.
63. **Clement ND, Vats A, Duckworth AD, Gaston MS, Murray AW.** Slipped capital femoral epiphysis: is it worth the risk and cost not to offer prophylactic fixation of the contralateral hip? *Bone Joint J* 2015;97-B:1428-1434.
64. **Seller K, Raab P, Wild A, Krauspe R.** Risk-benefit analysis of prophylactic pinning in slipped capital femoral epiphysis. *J Pediatr Orthop B* 2001;10:192-196.
65. **Canale ST, Azar F, Young J, et al.** Subtrochanteric fracture after fixation of slipped capital femoral epiphysis: a complication of unused drill holes. *J Pediatr Orthop* 1994;14:623-626.
66. **Davies A, Randall D.** Perceptions of children's participation in their healthcare: a critical review. *Issues Compr Pediatr Nurs* 2015;38:202-221.
67. **Marshall S, Haywood K, Fitzpatrick R.** Impact of patient-reported outcome measures on routine practice: a structured review. *J Eval Clin Pract* 2006;12:559-568.
68. **Petersson C.** Using health-related quality of life instruments for children with long-term conditions [PhD thesis]. *Jönköping University, Sweden: Dissertation Series* 2017;77.
69. **Aguilar CM, Neumayr LD, Eggleston BE, et al.** Clinical evaluation of avascular necrosis in patients with sickle cell disease: Children's Hospital Oakland Hip Evaluation Scale--a modification of the Harris Hip Score. *Arch Phys Med Rehabil* 2005;86:1369-1375.