

Acute appendicitis after colorectal endoscopic mucosal resection: a case report

Journal of International Medical Research

50(5) 1–7

© The Author(s) 2022

Article reuse guidelines:

sagepub.com/journals-permissions

DOI: 10.1177/03000605221096273

journals.sagepub.com/home/imr

Yu Liu^{1,2,*}, Hui Wang^{1,*}, Xiao-Yi Yin^{3,*},
Teng Wang^{2,*}, Jiong Liu¹, Lin Wu¹,
Liang-Hao Hu²  and Fang-Yu Wang¹ 

Abstract

Endoscopic mucosal resection (EMR) was originally described in 1973 and is currently a popular practice used in treating polyps, small adenomas, and early cancers. Although the safety of EMR has been proven in numerous studies, complications occur occasionally. We report a case in which the patient complained of severe upper abdominal pain and who was diagnosed with acute appendicitis after colorectal EMR. The patient recovered well after surgery. Cautious observation is necessary when resuming oral intake in patients who undergo colorectal EMR and who complain of postoperative abdominal pain. Observation is especially important for patients with a fecalith that may have originally existed in the appendix or in the colon near the appendix.

Keywords

Endoscopic mucosal resection, colonic polyp, acute appendicitis, case report, abdominal pain, complication, polyp, adenoma, early cancer

Date received: 31 July 2021; accepted: 6 April 2022

Introduction

Endoscopic mucosal resection (EMR) was originally described by Deyhle et al. in 1973 and was considered a risky procedure at that time.¹ With the development of technology since that time, EMR has become a popular practice that is used when treating

¹Department of Gastroenterology, Jingling Hospital, Medical School of Nanjing University, Nanjing, China

²Department of Gastroenterology, Changhai Hospital, Second Military Medical University, Shanghai, China

³Department of Hepatobiliary Pancreatic Surgery, Changhai Hospital, Second Military Medical University, Shanghai, China

*These authors contributed equally to this study.

Corresponding author:

Liang-Hao Hu, Department of Gastroenterology, Changhai Hospital, The Second Military Medical University, 168 Changhai Road, Shanghai 200433, China. Email: lianghao-hu@hotmail.com



polyps, small adenomas, and early cancers.² Although the safety of EMR has been proven in numerous studies, unexpected conditions occur occasionally.³ Here, we report a rare unexpected complication after colorectal EMR.

Case Report

The reporting of this study conforms to the CARE guidelines.⁴ A 62-year-old male patient was admitted to our hospital for the evaluation of changes in his defecation patterns for over 2 years. He complained of an increasing number of defecations (up to five defecations daily). The stools were soft, yellow, formed, and without blood. The patient had been diagnosed as having chronic gastritis for more than 10 years and denied having diabetes mellitus, hypertension, and other comorbidities. He had a history of multiple colonic polyps (one polyp each in the ascending colon, hepatic flexure of the colon, transverse colon, and sigmoid colon) 1 year earlier, and he underwent colorectal EMR in a local hospital. The pathological results revealed that the polyps were tubular adenomas with low-grade intraepithelial neoplasia. He had a history of smoking (40 pack-years) and drinking alcohol for over 40 years (100–250 g/day, 3–5 times per week).

The laboratory test results were as follows: white blood cell count (WBC): $5.91 \times 10^9/L$, red blood cell count (RBC): $4.76 \times 10^{12}/L$, and C-reactive protein (CRP): $<0.5 \text{ mg/L}$. There were no contraindications for endoscopic examinations and thus, colonoscopy was scheduled for 3 days after admission. Colonoscopy was performed after bowel preparation with polyethylene glycol electrolyte lavage solution in the Digestive Endoscopy Center of Jinling Hospital using an Olympus EVIS LUCERA CV290 processor (Olympus Medical Systems Corp., Tokyo, Japan) and a colonoscope (Olympus Medical

Systems Corp.). During the procedure, the colonoscope was inserted into the sigmoid colon through the anal aperture with air inflation. After reaching the ileocecal junction, polyps were observed during withdrawal. Five polyps were observed, and all were away from the appendiceal orifice. The largest polyp was a 6×6 -mm flat sessile polyp located in the distal descending colon. Another polyp was a 4×4 -mm hemispheric polyp near the hepatic flexure in the ascending colon. The remaining three polyps all measured approximately 3×3 mm; one was located in the transverse colon, one in the proximal descending colon, and one in the sigmoid colon. The largest polyp was treated by EMR (Figure 1). The lesion was positioned at 5 to 6 o'clock in the endoscopic field in the opposite direction to the biopsy channel before EMR. This was followed by the inject and cut technique. First, the submucosal fluid cushion was created. The submucosal injection fluid, which was composed of methylthionine chloride, normal saline, and diluted epinephrine, was injected into the submucosal layer of the intestinal wall from the margin of the lesion but away from the submucosal vessels. Second, a Cook Acusnare polypectomy snare (Wilson-Cook Medical Inc., Winston-Salem, NC, USA) was used to complete the en bloc resection using a hot snare. The snare was closed tightly while maintaining the snare base at the lesion edge during snare resection. After resection, the mucosal defect was cleaned with the colonoscope fluid jet (saline was used), which confirmed that there were no lesions remaining and no deep mural injury. Electrocoagulation was used during the EMR procedure. The remaining four polyps were removed with biopsy forceps (Olympus Medical Systems Corp.). All resected polyps were examined pathologically. After excising the lesions, the colonoscope was withdrawn, and the remainder of

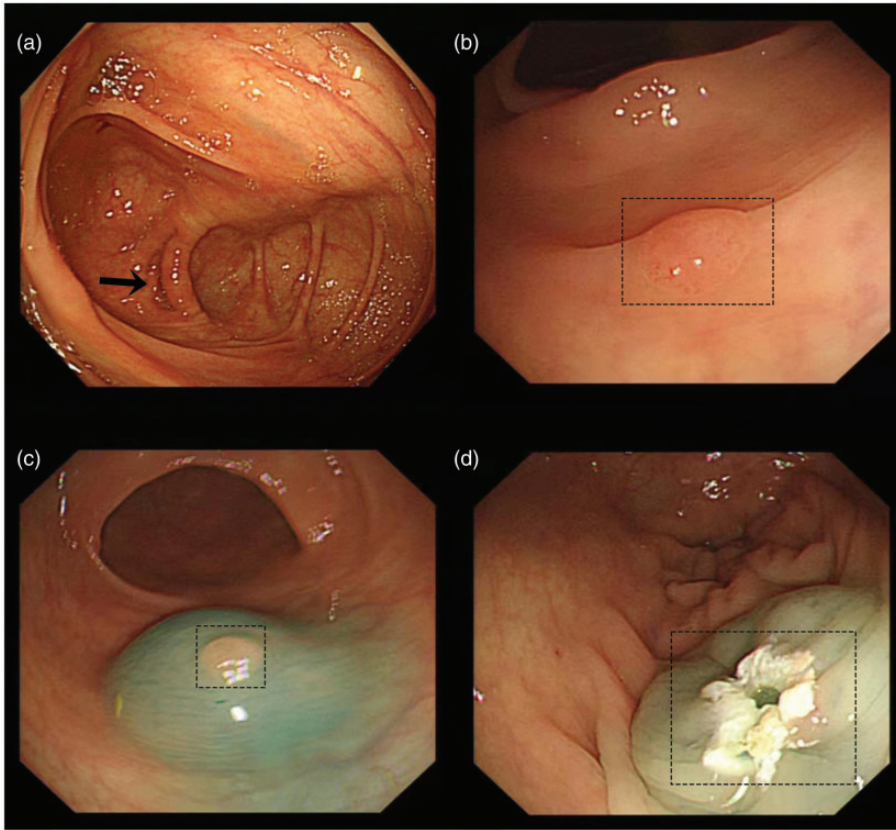


Figure 1. Colonoscopy and endoscopic mucosal resection (EMR) of the polyp located in the distal descending colon. (a) The appendiceal orifice is clear and normal. The black arrow indicates the opening of the vermiform appendix. (b) The flat sessile polyp located in the distal descending colon before EMR. (c) Creating the submucosal fluid cushion. The submucosal injection fluid, which was composed of methylthionine chloride, normal saline, and diluted epinephrine was injected into the submucosal layer of the intestinal wall from the margin of the lesion but away from the submucosal vessels and (d) An EMR-induced ulcer was identified after the polyp was removed with a hot snare.

the intestinal tract was observed. Air insufflation was used during the procedure. The colonoscopy was successful, and no abnormalities were found in the ileocecal junction and appendiceal orifice. The polyp located in the distal descending colon and the polyp located in the sigmoid colon were proven to be adenomatous polyps, and the remainder of the polyps were proven to be hyperplastic polyps.

The patient was fasted for the first day after colorectal EMR, and standard fluid

support was administered. There were no complaints of discomfort by the patient, and an oral liquid diet was initiated 24 hours after colorectal EMR. However, the patient complained of upper abdominal pain in the evening 30 hours after colorectal EMR. There was no vomiting or defecation. The pain was severe enough that the patient could not fall asleep. The first emergency computed tomography (CT) scan was scheduled, and the results showed that the appendix was slightly thickened

with a fecalith in the appendiceal lumen, and some effusion was observed (Figure 2a). The laboratory test results showed that the WBC was within the normal range. Thus, the patient was fasted again and given conservative therapy comprising a fluid and antibiotic (third-generation cephalosporins: ceftriaxone and ornidazole) infusion. After approximately 12 hours, the pain worsened and was located in the right lower abdominal quadrant, accompanied by abdominal tension. The patient's body temperature had increased to 38.9°C. Thus, the second emergency CT scan was scheduled, and the laboratory examinations were repeated. The laboratory test results showed that the WBC had increased to $12.57 \times 10^9/L$, and the percentage of neutrophils was 84.5%. CRP, serum amylase, and serum lipase concentrations were all within their respective normal ranges. CT findings suggested moderate effusion around the appendix (Figure 2b). Based on the patient's symptoms, laboratory test results, and the CT findings, acute appendicitis was considered, and emergent surgery was scheduled immediately after consultation with surgeons. Pathological analysis of the resected appendix confirmed acute appendicitis (Figure 3). After surgery, the patient recovered well, with both the

laboratory test results and his body temperature returning to normal. Five days later, he was discharged from the hospital. Three months after his admission, he was followed-up by telephone, and there was no complaint of discomfort.

Discussion

We reported a case of acute appendicitis after colorectal EMR. There was no sign of acute appendicitis before the colorectal EMR, and no colonoscopic findings suggested chronic appendicitis. The patient's symptoms developed just 24 hours after colorectal EMR and immediately after resuming an oral diet. He was finally diagnosed as having acute appendicitis after colorectal EMR.

Colorectal EMR is a technique used to treat polyps and early-stage colorectal neoplasms. Although the safety of EMR has been proven in numerous studies, complications occur occasionally.³ Abdominal pain after colorectal EMR could be caused by complications, such as perforation, bleeding, and post-polypectomy coagulation syndrome (PPCS).³ Perforation and bleeding are the most common complications after colorectal EMR, with reported incidences of 3.2% and 0.3%, respectively.⁵

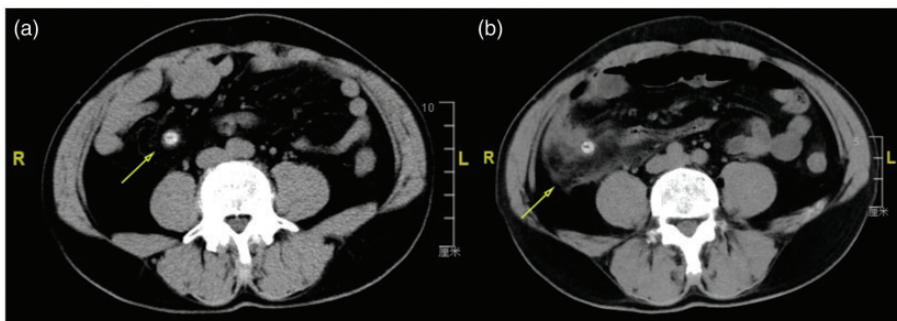


Figure 2. The emergency computed tomography (CT) images. (a) The first image shows that the appendix is slightly thickened and a fecalith is visible in the lumen of the appendix, with some effusion (yellow arrow) and (b) The second scan, obtained 12 hours later, demonstrates substantial effusion around the appendix (yellow arrow).

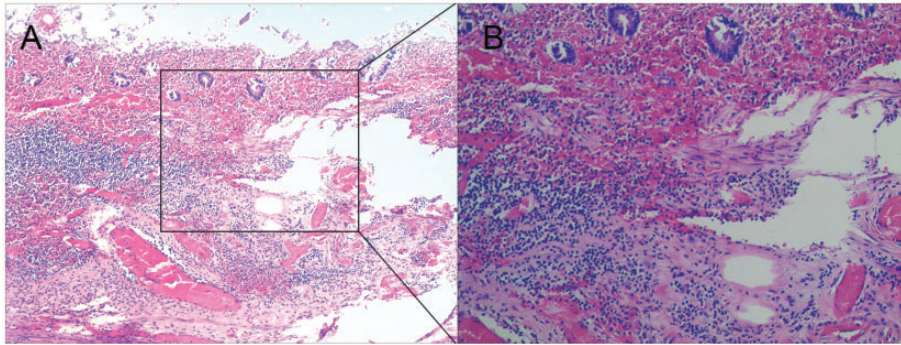


Figure 3. Pathological analysis of the resected appendix (hematoxylin-eosin staining; $\times 100$ (left) and $\times 200$ (right)). Inflammatory cells (the dark blue cells in the figure) are prominent and involve some or all layers of the appendiceal wall.

Perforation can be diagnosed by imaging, and bleeding can be confirmed by the presence of bloody stool or occult blood in the stool. PPCS refers to the development of abdominal pain, fever, leukocytosis, and peritoneal inflammation in the absence of frank perforation that occurs after colorectal EMR with electrocoagulation.⁶ In our patient, there were no signs of bleeding or perforation. Conservative treatment was administered to relieve the patient's symptoms. However, typical abdominal symptoms suggested the presence of acute appendicitis, and the surgical procedure and pathological results confirmed that the patient's abdominal pain was caused by acute appendicitis.

There have been several reports of acute appendicitis after endoscopic resection (ER) for tumors near the appendiceal orifice.^{7–10} However, the current case was very rare because none of the resected polyps was near the appendiceal orifice. The pathogenic mechanism of appendicitis is complex. Luminal obstruction may result from mucosal inflammation, lymphoid hyperplasia, or a fecalith, or a cecal tumor could lead to distension of the appendix and subsequent inflammation.¹¹ Genetic factors may play a role in the development

of appendicitis, although no specific gene has been identified.¹² Studies have shown that the risk of developing appendicitis is higher in members of families with a history of appendicitis than in those without such a family history.¹² Environmental factors may also be a reason for appendicitis. Studies have reported that the incidence of appendicitis was higher during the summer than the incidence in other seasons.¹³ The risk of appendicitis was lower in pregnant women than in non-pregnant women,¹⁴ and ethnicity may also play a role in appendicitis;¹⁵ however, the mechanism remains unknown.

In the present case, the patient was admitted to the hospital because of changes in his defecation patterns, and no contradictions for EMR were identified. However, post-EMR, he suffered abdominal pain that was caused by acute appendicitis. None of the polyps were close to the appendiceal orifice, and there was no sign of bowel luminal obstruction, based on the patient's symptoms and the CT findings. Several reasons may have contributed to the development of acute appendicitis in this patient. First, there was a fecalith in the lumen of the appendix, which is a definitive risk factor associated with acute

appendicitis. The statistical association between the presence of a fecalith and acute appendicitis in adults has been proven in previous studies.¹⁶ Second, the EMR procedure may irritate the appendix. Air and water infused into the enteric cavity could expand the appendix and cause inflammation. It is possible that feces could be delivered into the appendix during the EMR procedure and lead to infection. Third, the resumption of oral intake might increase intestinal motility, which increases the potential for the contents of the intestinal lumen to enter the appendix. Fourth, the patient had a history of changes in his defecation patterns for over 2 years. These changes may have been the result of intestinal flora disturbance, which may also affect defecation patterns. Additionally, intestinal flora disturbance may play a role in the development of appendicitis. Thus, we may infer that intestinal flora disturbance, changes in defecation patterns, and the existence of a fecalith might explain the physiological basis for the acute appendicitis in our patient. Furthermore, the EMR procedure and reinitiating food intake may have been merely triggers and not the direct cause of the acute appendicitis. All of these factors led to the development of acute appendicitis after colorectal EMR in our patient.

In conclusion, it is worth noting that EMR for tumors anywhere in the colorectum other than near the appendiceal orifice can trigger appendicitis if certain unfortunate conditions coexist. For patients with prior known fecaliths in the lumen of the appendix or in the colon near the appendix, the risk of acute appendicitis after EMR could be increased. Thus, colorectal EMR should be performed with greater caution, and cautious observation should be performed after the operation.

Acknowledgements

The authors acknowledge the patient for providing informed consent.

Author contributions

YL, HW, XYY, and TW participated in the analysis and interpretation of the data, as well as in drafting of the manuscript; JL, LW, LHH, and FYW contributed to the study conception and data interpretation and also revised the manuscript for important intellectual content.

Declaration of conflicting interest

The authors declare that there is no conflict of interest.

Ethics approval and consent

The treatment of this patient was approved by the Ethics Committee of Jinling Hospital. Written informed consent was obtained from the patient for publication of this case report and any accompanying images.

Funding

The authors disclosed receipt of the following financial support for the research, authorship, and/or publication of this article: This work was supported by the National Natural Science Foundation of China [Grant No. 81770635 (LHH)].

ORCID iDs

Liang-Hao Hu  <https://orcid.org/0000-0001-7535-7475>

Fang-Yu Wang  <https://orcid.org/0000-0002-7129-8655>

References

1. Deyhle P, Jenny S and Fumagalli I. [Endoscopic polypectomy in the proximal colon. A diagnostic, therapeutic (and preventive?) intervention]. *Dtsch Med Wochenschr* 1973; 98: 219–220.
2. Nishizawa T and Yahagi N. Endoscopic mucosal resection and endoscopic submucosal dissection: technique and new directions. *Curr Opin Gastroenterol* 2017; 33: 315–319.

3. Ahmed Yand Othman M. EMR/ESD: techniques, complications, and evidence. *Curr Gastroenterol Rep* 2020; 22: 39.
4. Gagnier JJ, Kienle G, Altman DG, et al. The CARE guidelines: consensus-based clinical case reporting guideline development. *Headache* 2013; 53: 1541–1547.
5. Zheng JC, Zheng K, Zhao S, et al. Efficacy and safety of modified endoscopic mucosal resection for rectal neuroendocrine tumors: a meta-analysis. *Z Gastroenterol* 2020; 58: 137–145.
6. Cha JM, Lim KS, Lee SH, et al. Clinical outcomes and risk factors of post-polypectomy coagulation syndrome: a multicenter, retrospective, case-control study. *Endoscopy* 2013; 45: 202–207.
7. Nemoto Y, Tokuhisa J, Shimada N, et al. Acute appendicitis following endoscopic mucosal resection of cecal adenoma. *World J Gastroenterol* 2015; 21: 8462–8466.
8. Serrano González J, López Monclús J and Román García de León L. Acute appendicitis after a colonic endoscopic submucosal resection. *Rev Esp Enferm Dig* 2018; 110: 211–212.
9. Kato R, Harada K, Harada K, et al. Acute appendicitis caused by previous endoscopic submucosal dissection for an adenoma adjacent to the appendiceal orifice. *Case Rep Gastroenterol* 2017; 11: 271–276.
10. Jacob H, Toyonaga T, Ohara Y, et al. Endoscopic submucosal dissection of cecal lesions in proximity to the appendiceal orifice. *Endoscopy* 2016; 48: 829–836.
11. Bhangu A, Søreide K, Di Saverio S, et al. Acute appendicitis: modern understanding of pathogenesis, diagnosis, and management. *Lancet* 2015; 386: 1278–1287.
12. Ergul E. Heredity and familial tendency of acute appendicitis. *Scand J Surg* 2007; 96: 290–292.
13. Wei PL, Chen CS, Keller JJ, et al. Monthly variation in acute appendicitis incidence: a 10-year nationwide population-based study. *J Surg Res* 2012; 178: 670–676.
14. Zingone F, Sultan AA, Humes DJ, et al. Risk of acute appendicitis in and around pregnancy: a population-based cohort study from England. *Ann Surg* 2015; 261: 332–337.
15. Anderson JE, Bickler SW, Chang DC, et al. Examining a common disease with unknown etiology: trends in epidemiology and surgical management of appendicitis in California, 1995-2009. *World J Surg* 2012; 36: 2787–2794.
16. Ramdass MJ, Young Sing Q, Milne D, et al. Association between the appendix and the fecalith in adults. *Can J Surg* 2015; 58: 10–14.