

Review article

Late onset adrenoleukodystrophy: A review related clinical case report

Santiago Paláu-Hernández^{a,b,1}, Ildefonso Rodriguez-Leyva^{a,b,*,1},
Juan Manuel Shiguetomi-Medina^{a,c}

^a Faculty of Medicine, Universidad Autónoma de San Luis Potosí, Mexico

^b Service of Neurology of Hospital Central "Dr. Ignacio Morones Prieto" San Luis Potosí, S.L.P., Mexico

^c Department of Postgraduate, Faculty of Medicine, Universidad Autónoma de San Luis Potosí, Mexico



ARTICLE INFO

Keywords:

Adrenoleukodystrophy
Adrenomyeloneuropathy
Cerebral adrenoleukodystrophy
Demyelination
Myelopathy

ABSTRACT

Our objective is to review the initial presentation, evolution, progression, final stage, and images in the follow up of an adult patient who presented an uncommon peroxisomal disease (1/20,000 males) that occurred by *ABCD1* gene mutation in the Xq28 chromosome; to bring forward the imaging features (which nowadays is the most useful and accessible diagnostic tool) and clinical presentation of adrenoleukodystrophy in adulthood; to propose a differential diagnosis in aid of a prompt recognition of the disease hereafter from a neurologist approach.

In relation of a clinical case we reviewed the literature to correlate the principal findings and evolution of the disease. This thrilling but at the same time unfortunate disease is not only a diagnostic problem is also a therapeutic quest besides all the related familial, labor, and social related problems.

The very-long chain fatty acids (VLCFA) accumulation leads to a not completely understood mechanisms that precipitate the specific malfunction of the nervous system and adrenal gland. The initial corticospinal bilateral involvement provokes a spastic paraparesis but with the affection of others pathways multiple manifestations appears, with dementia and finally loss of the most of cortical functions secondary to the white matter affection. Since the hematopoietic stem cell transplantation can be treated with variable results, other treatments, as the Lorenzo's oil, have not been consistent with a substantial improvement of the affected individual. The genetic advice and support to the patient and the family are essentials as well as the screening in individuals at risk before the onset of the disease.

1. Case presentation

A 38-year-old male presents with a three-year history of spastic paraparesis, gait disturbances, fasciculations, urinary urgency, and sexual impotence; a family history of one uncle with the diagnosis of probable spastic familial paraparesis or primary lateral sclerosis, and a daughter with a motor neuron illness no otherwise specified. The only alterations found on the physical examination at the first medical consult were hyperreflexia of the lower limbs, pseudohypertrophy, and bilateral Babinski. A Magnetic Resonance Image (MRI) study of the brain was indicated in which there were slightly evident hyperintense signals on T2-Weighted-Fluid-Attenuated Inversion Recovery (T2FLAIR) in the parietal-occipital lobes and the periventricular white matter, with the involvement of the posterior limb of the internal capsule and splenium of the corpus callosum (Fig. 1). The MRI of the spinal cord showed a slight atrophy and a subtle hyperintense signal predominantly over the ventral-lateral zones of the thoracic spinal cord

(Fig. 1). At that time motor neuron disease was suspected.

In the five coming years the neurologic status of the patient progressively deteriorated presenting muscle cramps, increasing falls, pain, anxiety, insomnia, apathy, and depression. At this moment the probable diagnosis was familial spastic paraparesis. Two years later, in a genetic study, the finding of an *ABCD1* gene mutation, as well as elevated levels of very long chain fatty acids (VLCFA), established the diagnosis of X-linked adrenoleukodystrophy in its adrenomyeloneuropathy variation or phenotype with cerebral involvement.

A bone marrow transplant was proposed as a treatment but without showing any improvement in the symptoms posteriorly. Over time, aggressivity, distal paresthesia in the lower limbs, and generalized hyperreflexia were found, and lately requiring the use of a wheelchair.

In a new MRI study (thirteen years of evolution), the previously described findings were compatible with bilateral symmetrical demyelination, occupying a higher brain extension involving the thalamus, bilateral frontotemporal lobes, bilateral corticospinal tracts, the

* Corresponding author at: Avenida Venustiano Carranza 2405, Los Filtros, CP 78210 San Luis Potosí, S.L.P., México.

E-mail addresses: palauhs@gmail.com (S. Paláu-Hernández), ilrole@yahoo.com.mx (I. Rodriguez-Leyva).

¹ These authors contributed equally to this work.

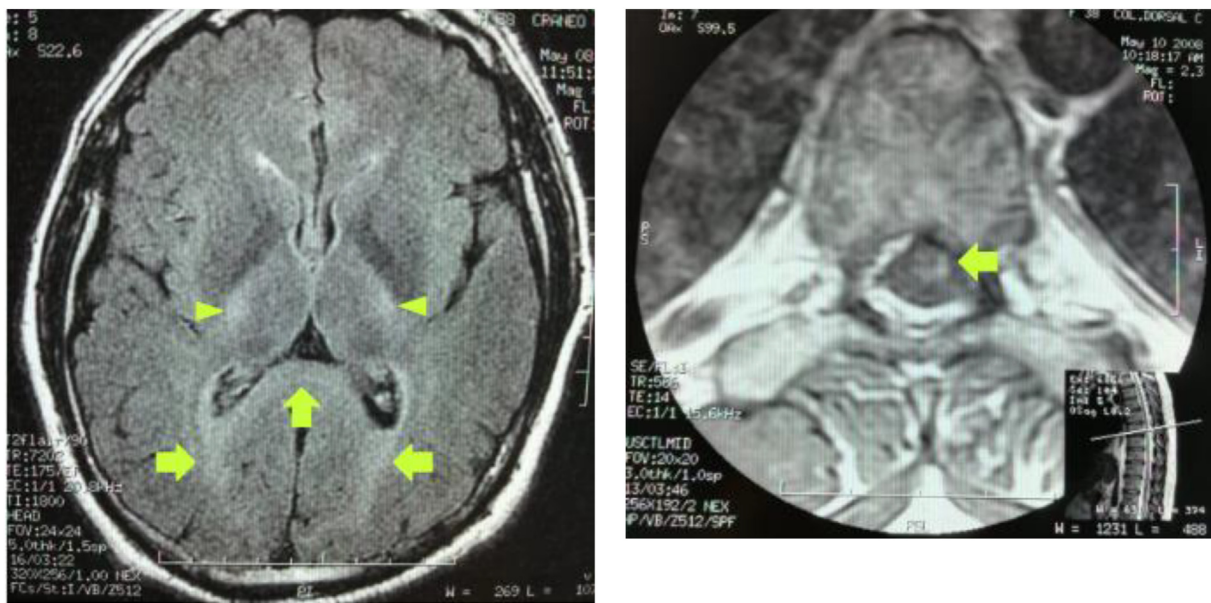


Fig. 1. (Left) Brain MRI showing T2FLAIR hyperintense signals in the periventricular white matter of the occipital lobe and splenium of the corpus callosum (arrows) as well as in the posterior limb of the internal capsule (arrowhead). (Right) A subtle hyperintense region probably corresponding to the ventral column of the spinal cord (arrow). The patient also presented hyperintense lesions on the parietal lobe (not shown).

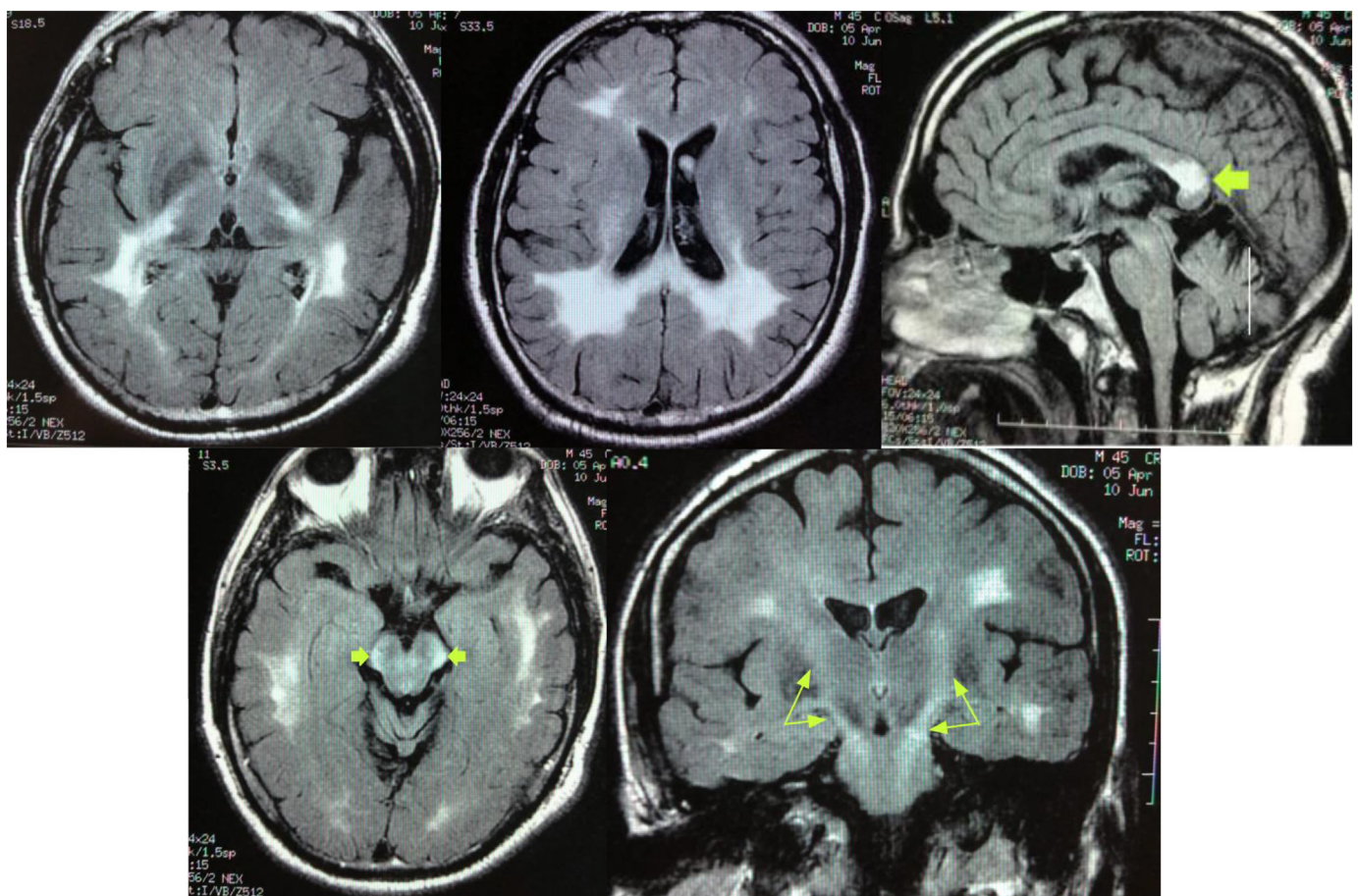


Fig. 2. Thirteen years later the second MRI study shows the previous lesions now compatible with demyelination involving a higher brain white matter extension and with increased intensity in T2FLAIR (up-left and middle) and evident in the splenium of the corpus callosum (up-right; arrow). The demyelination progresses into the brainstem through the motor pathways seen in the cerebral peduncles at the mesencephalon (down-right; arrows) and follows the track of the corticospinal tract from the brain to the brainstem in a bilateral manner (down-left; arrows).

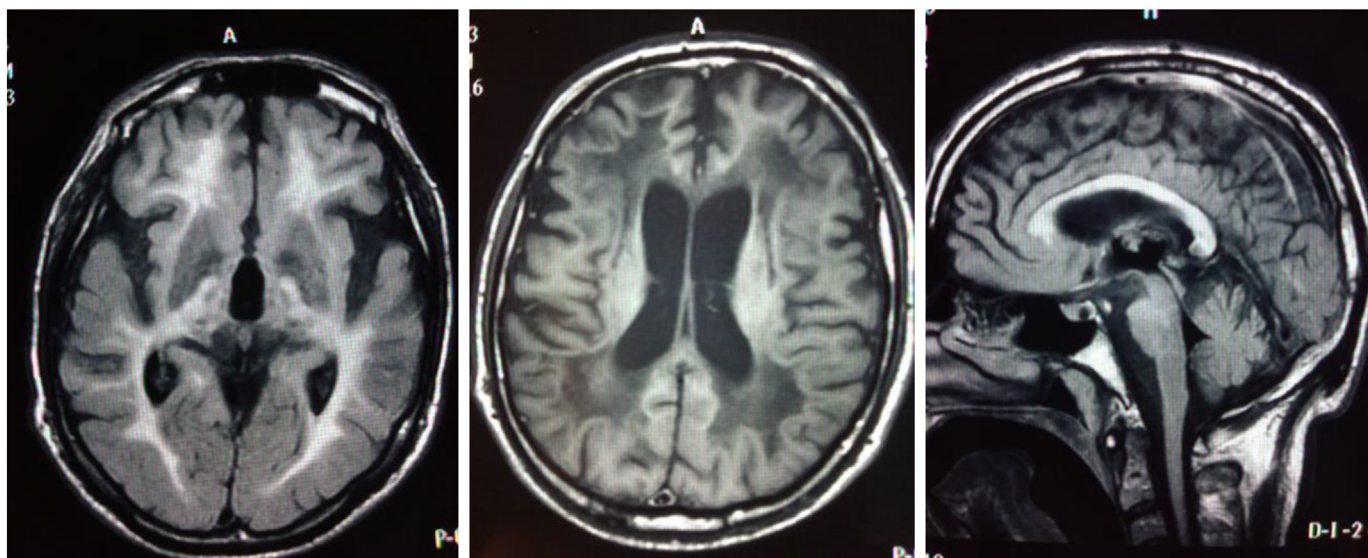


Fig. 3. On the third MRI the previous lesions almost span over the whole brain white matter presenting as T1 hypointensities while cavitation takes place (middle) and now cover the corpus callosum in its entirety (right). A severe cortical and subcortical atrophy can be observed.

cerebellum, and probably the mesencephalon and the pons with a marked cortical and subcortical atrophy (Fig. 2). In the same year a Mini-Mental State Exam was applied getting a score of 23/30. Half year later the score dropped to 15/30 and three months later to 4/30 with a rapidly progressive deterioration in the superior cognitive functions, amnesia, rigidity, headache, speechless, dementia, and dysmetria. Because of recurrent urinary infections the patient got admitted to the hospital for a second time in a year. Meanwhile, a MRI study was taken showing a severe increase in the extension of the demyelinating lesions and in their intensity in T2FLAIR now present as hypointense signals in T1 and fully involving the corpus callosum with severe generalized atrophy (Fig. 3). The patient died after fifteen years of evolution without any communication, prepositives movements, and the apparent loss of vision and hearing.

2. Discussion

X-linked Adrenoleukodystrophy (X-ALD) is the most common leukodystrophy and peroxisomal disease with an incidence ranging from 1:15,000–20,000 [1,2] to even 1:40,000–50,000 males [2,3]. X-ALD results from a variety of mutations of the ABCD1 gene (ATP-binding cassette, D1 subtype) in the Xq28 chromosome that encodes a peroxisome membrane transporter protein (the adrenoleukodystrophy protein or ALDP). This mutated transporter is involved in the membrane traffic of fatty acid chains of up to 24–30 carbon atoms [4]. Hence, mutations in its gene cause abnormal β -oxidation reactions resulting in a VLCFA elevation and their posterior accumulation in the cell and the organism especially in the cerebral white matter, the spinal cord, and the adrenal cortex [5]. Why adrenocortical and glial cells are more susceptible to toxicity by VLCFA accumulation remains unknown although cell damage by VLCFA oxidative stress could be the leading mechanism [6].

X-ALD manifests as adrenal insufficiency in the form of Addison's disease in 90% of the patients independently of the neurologic affection which affects 50% of the males [7]. The neurologic symptoms use to begin at three to ten years of age with attention deficit and development regression, spasticity, cortical blindness, cognitive decline, total disability and death. For late-onset presentation in adults such as the previously described that do not present typical childhood symptoms, later in life present dementia, behavioral changes, and a progression and prognosis similar to that in the childhood form [7]. Because the disease is linked to the X chromosome female individuals can act as heterozygous carriers of the mutation or can develop the full spectrum

of XALD if they are homozygous and both X chromosomes carry the ABCD1 mutation. Contrary to the X-linked diseases dogma even the female carriers show elevated VLCFA and are highly likely to exhibit neurological symptoms beyond the 60 years of age. The most common manifestation is myelopathy in the form of sphincter disturbance as fecal incontinence [8].

There are different phenotypes of X-ALD described: childhood cerebral (frequency of 31–35%), adolescent cerebral (4–7%), adrenomyeloneuropathy, adult cerebral, olivo-ponto-cerebellar (1–2%), Addison-only (frequency varies with age), and asymptomatic (frequency diminishes with age) [5,9]. Because our patient exhibited the adrenomyeloneuropathy (AMN) and adult cerebral phenotypes and being the most common findings in adult onset X-ALD we will proceed to describe each one of these two variations of the disease.

2.1. Adrenomyeloneuropathy

The AMN phenotype has an approximate incidence of 1:42,000 [10] and a frequency of 40–46% in individuals with X-ALD. It initiates around the third decade of life (earliest in the second decade and latest in the fifth) [11] as a non-inflammatory primary axonopathy of the spinal cord that involves descending corticospinal tracts in the thoracic and lumbosacral regions and ascending posterior columns in the cervical region [12]. Before the arrival of the MRI study AMN was frequently misdiagnosed as multiple sclerosis or hereditary spastic paraparesis [2,5]. The clinical presentation and findings are slowly progressive spastic paraparesis that hinders the gait, ataxia, a positive Babinski test, sexual impotence, and loss of sensitivity and of sphincter control with vesical dysfunction and urinary urgency. Peripheral axonal degeneration can be observed in most of the patients. The disease does not manifest intellectual decline at the very beginning unless the cerebral form develops in 20–40% of the patients (AMN-Brain/cerebral phenotype) [7,12,13], or could progress without brain involvement at all and with a less obscure prognosis (Pure AMN) [10,13]. The principal abnormality seen in a MRI at the spinal cord is atrophy, but corticospinal and corticopontine tracts may also be involved [14], as well as bilateral pyramidal tract, posterior limb of the internal capsule and pontocerebellar fibers if concurrent cerebral phenotype has established [2,15] (as seen in Figs. 1 and 2).

2.2. Adult cerebral

The adult-onset cerebral phenotype occurs in 2–5% of the adult patients without previous manifestations of X-ALD [11]. It has a probable traumatic etiology not yet elucidated or a brain-blood barrier (BBB) endothelial dysfunction that precipitates the leakage of leukocytes into the brain tissue and the outbreak of demyelination [16]. An explanation for the demyelination could be the myelin sheath instability from VLCFA excess in the lipid membrane as it would normally help with its stability and insulating properties [17]. High levels of VLCFA could also be cytotoxic to oligodendrocytes and microglia contributing to the demyelination process [17]. In this variant of the disease the demyelinating zones frequently begin at the splenium of the corpus callosum (as seen in Fig. 1) and lately in the posterior periventricular white matter extending through the parietal and occipital lobes. The symptoms appear until there are noticeable lesions in the MRI. In the beginning there are few to none symptoms and there is no evidence of inflammation. It is hypothesized that an underlying immunopathogenic mechanism could cause the inflammatory lesions by reacting against unstable myelin from VLCFA accumulation in oligodendrocytes [18]. The inflammatory phase starts suddenly with a rapid progression of symptoms such as emotional lability, hyperactivity, loss of visual acuity, frontal syndrome, hemiplegia, quadriplegia, cerebellar ataxia, cortical blindness, seizures, visual field defects, and loss of central auditory discrimination. It progresses to a vegetative state in a time lapse from two to five years.

There are alterations compatible with demyelination in the white matter in 80% of the patients, involving the parietal and occipital lobes, splenium of the corpus callosum (this being the earliest finding), and visual and auditory tracts. The demyelination spreads anteriorly through the corpus callosum and posterior limb of the internal capsule [3] (as seen in Fig. 2). Ten to 15% have an initial predominant anterior pattern with involvement of the frontal white matter, genu of the corpus callosum and frontopontine tracts [5,14,19,20]. The cerebellum, corticospinal tracts, and spinal cord could be involved in the presence of AMN [20] (Figs. 1 and 2). The visible lesions can be divided in regions as: the central zone, which has an irreversible demyelination and gliosis corresponding to the T2 highly hyperintense areas and latter hypointense as cavitation sets (as seen in Fig. 3); the intermediate zone of active demyelination, lymphocytic infiltration and blood-brain barrier breakdown, seen as T2 isointense areas; the outer zone, with active demyelination but with preserved axons, which can be highlighted with contrast enhancement in T1 to evaluate the disease progression [7,21]. This gadolinium enhancement is correlated with disruption of the BBB and the area of future inflammation [22,23]. The Loes Scoring System is a practical method to define the natural history of the disease and to monitor response to therapies [24], although only described in males under 20 years.

3. Diagnosis

The presence of VLCFA with an ABCD1 gene mutation associated with a progressive sensorimotor deficit in the lower limbs and a family history of myelopathy should establish the diagnosis of AMN. An MRI study with the presence of white matter lesions in the periventricular area, parietal and occipital region and the corpus callosum (Fig. 1.) should conjoin the cerebral form of the disease to the diagnostic suspicion. A spinal cord MRI study showing corticospinal or bilateral pyramidal tract involvement without any brain affection may isolate the pure-AMN phenotype as the diagnostic suspicion.

3.1. Differential diagnosis

The differential diagnosis of the AMN variant of X-ALD could be, principally, mainly against the diseases that course with spastic paraparesis. The diseases that most commonly develop this clinical sign are

the large group of myelopathies: infectious, immune-mediated, degenerative, congenital, vascular, toxic/metabolic, and neoplastic [25]. Other rarer pathologies such as the leukodystrophies (e.g., metachromatic leukodystrophy, Krabbe disease, gangliosidosis, amongst others) and the motor neuron diseases that behave like an upper motor neuron (UMN) disorder (e.g., familial spastic paraparesis or hereditary spastic paraplegia, and primary lateral sclerosis) can also show spastic paraparesis with other neurologic manifestations as well as cerebral involvement.

3.1.1. Myelopathies

A myelopathy can present a variety of different signs and symptoms depending on the area of damage in the spinal cord. They can be divided into multiple groups depending on the cause of the lesion, the affected zone, and the clinical presentation (i.e. etiologic, anatomic, and clinical diagnosis). While there is a myriad of spinal cord disorders only the few that impairs the corticospinal tract can feature spastic paraparesis or lower limb weakness independently of their localization within the spinal cord (i.e. extradural, intradural-medullary, intradural-intramedullary or intradural-tract specific) [25]. The anterior spinal cord syndrome (most commonly caused by anterior spinal artery infarct) affects the lateral and ventral tracts displaying as weakness and loss of nociception and thermoception below the level of the lesion; lower motor neuron (LMN) pattern at the same level by comprising the anterior horn; bladder, bowel, and sexual dysfunction from the autonomic fibers impairing [26,27].

While commonly presenting motor symptoms they rarely affect the encephalon unless the spinal cord affection is from a systemic disease that could manifest rostrally in the central nervous system.

3.1.2. Leukodystrophies

The leukodystrophies are a conglomerate of inherited disorders that affect the cerebral white matter, mostly the axon-unit conformed by the astrocytes, oligodendrocytes, ependymal cells and microglia [1]. Frequently from genetic background, therefore, caused by a variety of mutations depending on each pathology. Each disease impairs a different metabolic route by decreasing the quantity of a disease-specific enzyme, causing the posterior accumulation of a disease-specific substance in an organ and affecting its regular activity. Clinically they display similar neurologic features between them (e.g. spasticity, peripheral neuropathy, and ataxia). In some cases the only significant difference is the MRI pattern that each disease presents or the finding of a precise mutation or lack of a metabolic product of a specific enzyme (Table 1). A high percentage of the leukodystrophies are seen in the pediatric population and a lower incidence is present in the juvenile and adult populations with a similar or a different set of manifestations from the childhood form.

3.1.3. Motor neuron disease

The affection of the motor neurons is a group of disorders of both the UMN and LMN, which result from their dysfunction and generally manifest as limb weakness without sensory impairment. The most common type of motor neuron disease is amyotrophic lateral sclerosis but exhibiting as an LMN predominant disorder it rarely presents spasticity or other UMN signs and symptoms and thus if these are present it should be considered as primary lateral sclerosis. Other motor neuron disease to consider could be familial spastic paraparesis also known as hereditary spastic paraplegia which is a variety of conditions characterized by lower limb spasticity and weakness (Table 1).

4. Treatment

The hematopoietic stem cell transplantation (HSCT) stands as the only probed treatment for X-ALD with varying results, giving the possibility of arresting the progression of the disease. The mechanism by which the HSCT works against the process of demyelination is still

Table 1
MRI: magnetic resonance imaging; CT: computed tomography; GM1: Only the leukodystrophies and the motor neuron diseases that course with spastic paraparesis and gait disturbance are displayed.

Pathology	Gene mutated	Physiopathology	Clinical presentation	Imaging
Metachromatic Leukodystrophy	ARSA	Absence of aryl-sulfatase activity and posterior accumulation of sulfated lipids in the myelin sheath [14]	Spasticity, gait disturbances, absence of peripheral reflexes, peripheral neuropathy, ataxia, movement disorders and seizures.	Frontal and parietal periventricular white matter involvement seen as T2 hyperintensities in a centrifugal pattern. A striped tigroid or a butterfly appearance may be seen [20].
Krabbe disease or globoid cell leukodystrophy	GALC	Absence of galactosylceramidase activity and posterior galactosylceramide and psychosine accumulation [28].	Spastic paraparesis, visual impairment, ataxia, seizures, behavioral or cognitive decline, and peripheral neuropathy [14].	Hyperintensities on the basal ganglia, the parietooccipital white matter involvement, and selective of the corticospinal tract [14,28].
Alexander's disease	GFAP	Cytoplasmic astrocyte inclusion bodies containing the intermediate glial filament protein (Rosenthal fibers) [29].	Bulbar and pyramidal tract involvement, with sleep disturbance, cerebellar ataxia, autonomic and urinary dysfunction and palatal myoclonus [29].	Upper spinal cord and medullary atrophy, periventricular and frontal white matter change, and basal ganglia involvement [29].
Gangliosidosis	GLB1 and HEXA	Absence of hexosaminidase and β -galactosidase activity for GM2 and GM1 variants, respectively. Excessive neuronal glycolipid storage [14].	GM1 variation: display gait disturbances and speech impairment. GM2 variation: from fasciculations, spasticity, weakness, ataxia, and dystonia, to psychosis [14].	T2 signal hyperintensities in the caudate nucleus and the putamen, while hypointensities are observable in the globus pallidus [14].
Cerebrotendinous xanthomatosis	CYP27A1	Deficiency of sterol 27-hydroxylase, leading to an abnormal conversion of cholesterol into cholic and chenodeoxycholic acids which elevates the cholesterol levels in plasma and its posterior accumulation in brain, tendons, eyes and other tissues [30].	Systemic disease (xanthomas of the Achilles tendon, atherosclerosis, osteoporosis, and respiratory, endocrine and hepatic abnormalities) with neurologic manifestations: spastic paraparesis, ataxia, peripheral neuropathy and dementia [30].	Periventricular white matter change with sparing of the corpus callosum. T2 high intensities in cerebellar white matter and low intensity in dentate nucleus [29].
Hereditary spastic paraplegia	High variety of involved genes: SPG4 or SPAST for autosomal dominant, SPG11 for autosomal recessive, and SPG1 or LICAM for X-linked, are the most common mutations of each type of heritage [31].	Axonal degeneration of the long descending corticospinal tracts and ascending dorsal columns, probably by disrupting axonal macromolecules and organelles transport, affecting the distal part of these neurons [31].	Pure form: spastic paraparesis. Complicated form: spastic paraparesis with ataxia, amyotrophy, optic atrophy, pigmentary retinopathy, mental retardation, extrapyramidal signs, dementia, deafness, ichthyosis, peripheral neuropathy and epilepsy [31].	Thinning of the cervical and thoracic spinal cord [31].
Primary lateral sclerosis	Unknown; probably from multiple genetic mutations [32].	Dysfunction of the descending corticospinal tracts.	Spasticity, hyperreflexia, and mild weakness; dysarthria, dysphagia, and emotional lability.	There are not structural abnormalities described, except there can be precentral gyrus atrophy [32].

unknown [22,23]. The efficacy of the transplantation therapy has been associated with the state of progression and early stages of the disease, meaning that once neurologic symptoms have aggravated the treatment has not shown to stop the pace of the cerebral form of ALD [33].

Other treatments such as low-fat diet and Lorenzo's Oil have shown to reduce VLCFA concentrations but lack to make any improvement in the disease progression and symptoms [34,35]. However, both approaches could help to reduce the risk of developing the cerebral disease in individuals with pre-symptomatic ALD [36,37].

There is a newborn screening in the United States (New York) that involves biochemical studies based on quantification of a lysophosphatidylcholine derivative of VLCFA, which is elevated in the individuals that could potentially exhibit the disease. A confirmatory molecular genetic testing is also performed to assist in the diagnosis determining if there is any mutation in the ABCD1 gene. This is for the purpose to identify the individuals that could be treated with HSCT and to establish a follow up [9,38]. The possibility of an extended family screening has been considered to identify both female and male with X-ALD before the onset of adrenocortical or neurological affection, as well as heterozygous individuals [9]. Female carriers could potentially transfer the ABCD1 mutated gene to their male offspring so genetic counseling and prenatal diagnosis by different techniques are recommended [5,6]. Although adrenocortical function evaluation is not a neurological approach the presence of adrenal insufficiency could be useful in detecting young individuals with ALD before the onset of symptoms and in which adrenal hormone therapy should be administered to avoid an endocrinological morbidity [39,40].

5. Conclusion

The X-ALD is a genetic disease that is transmitted by the mother and endured by the male offsprings, although female patients can show up in a less degree and in an older age. With a general early onset at the three years of age it rarely presents in adults also with a progressive white matter affection and clinical manifestations of damage in spinal cord and encephalon. We correlated the current concepts with a clinical case and we tried to show how is the progression, the image evolution, and the available treatments of an unfortunate disease where the consolation of the family is sometimes the only alternative that we can be offering as physicians. We must continue looking for new therapeutic possibilities or perhaps the prompt diagnosis in individuals with genetic risk before the initial symptoms come up.

References

- [1] W. Köhler, J. Curiel, A. Vanderver, Adulthood leukodystrophies, *Nat Rev Neurol* 14 (2) (2018) 94–105.
- [2] H. Liu, Y. Chen, Y. Mo, Adrenomyeloneuropathy, a dynamic progressive disorder: brain magnetic resonance imaging of two cases, *Neuroradiology* 46 (4) (2004) 296–300.
- [3] J. Masdeu, R. González, *Neuroimaging*, 1st ed, Elsevier, Amsterdam, Netherlands, 2016.
- [4] R. Lisak, D. Truong, R. Bhidayasiri, et al., *International Neurology*, 2nd Ed, John Wiley & Sons, Chichester, West Sussex; Hoboken, NJ, 2016.
- [5] M. Engelen, S. Kemp, M. de Visser, et al., X-linked adrenoleukodystrophy (X-ALD): clinical presentation and guidelines for diagnosis, follow-up and management, *Orphanet J Rare Dis* 7 (1) (2012) 51.
- [6] M. Engelen, S. Kemp, B. Poll-The, X-Linked adrenoleukodystrophy: pathogenesis and treatment, *Curr Neurol Neurosci Rep* 14 (10) (2014).
- [7] D. Renaud, Adult-onset leukoencephalopathies, *Continuum* 22 (2, Dementia) (2016) 559–578.
- [8] M. Engelen, M. Barbier, I. Dijkstra, et al., X-linked adrenoleukodystrophy in women: a cross-sectional cohort study, *Brain* 137 (3) (2014) 693–706.
- [9] S. Kemp, A. Pujol, H. Waterham, et al., ABCD1 mutations and the X-linked adrenoleukodystrophy mutation database: role in diagnosis and clinical correlations, *Hum Mutat* 18 (6) (2001) 499–515.
- [10] J. Powers, D. DeCiero, M. Ito, et al., Adrenomyeloneuropathy: a neuropathologic review featuring its noninflammatory myelopathy, *J. Neuropathol. Exp. Neurol.* 59 (2) (2000) 89–102.
- [11] S. Kemp, I. Huffnagel, G. Linthorst, et al., Adrenoleukodystrophy – neuroendocrine pathogenesis and redefinition of natural history, *Nat Rev Endocrinol* 12 (10) (2016) 606–615.
- [12] R. Daroff, W. Bradley, J. Jankovic, et al., *Bradley's Neurology in Clinical Practice*, 7th ed., Elsevier, London, UK, 2016.
- [13] H. Moser, A. Mahmood, G. Raymond, X-linked adrenoleukodystrophy, *Nat Clin Pract Neurol* 3 (3) (2007) 140–151.
- [14] A. Vanderver, Genetic leukoencephalopathies in adults, *Continuum* 22 (3) (2016) 916–942.
- [15] C. Teriethau, C. Adamsbaum, V. Merzoug, et al., Subtle brain abnormalities in adrenomyeloneuropathy, *J Radiol* 88 (2007) 957–961.
- [16] P. Musolino, Y. Gong, J. Snyder, et al., Brain endothelial dysfunction in cerebral adrenoleukodystrophy, *Brain* 138 (11) (2015) 3206–3220.
- [17] D. Trompier, A. Vejux, A. Zarrouk, et al., Brain Peroxisomes, (2018).
- [18] M. Hudspeth, G. Raymond, Immunopathogenesis of adrenoleukodystrophy: current understanding, *J Neuroimmunol* 182 (1–2) (2007) 5–12.
- [19] M. Filippi, *Oxford Textbook of Neuroimaging*, 1st ed, Oxford University Press, New York, NY, 2015.
- [20] A. Osborn, G. Hedlund, K. Salzman, *Osborn's Brain*, Elsevier, Philadelphia, PA, 2018.
- [21] J. Howard, A. Singh, *Neurology Image-Based Clinical Review*, 1st ed, Demos Medical Publishing, New York, NY, 2016.
- [22] P. Aubourg, Cerebral adrenoleukodystrophy: a demyelinating disease that leaves the door wide open, *Brain* 138 (11) (2015) 3133–3136.
- [23] C. Peters, Cerebral X-linked adrenoleukodystrophy: the international hematopoietic cell transplantation experience from 1982 to 1999, *Blood* 104 (3) (2004) 881–888.
- [24] D. Loes, S. Hite, H. Moser, et al., Adrenoleukodystrophy: a scoring method for brain MR observations, *Am J Neuroradiol* 15 (9) (1994) 1761–1766.
- [25] L. Zhovtis Ryerson, J. Herbert, J. Howard, et al., Adult-onset spastic paraparesis: an approach to diagnostic work-up, *J Neurol Sci* 346 (1–2) (2014) 43–50.
- [26] T. Cho, S. Bhattacharyya, Approach to myelopathy, *Continuum (Minneapolis, Minn)* 24 (2, Spinal Cord Disorders) (2018) 386–406.
- [27] C. Kramer, Vascular disorders of the spinal cord, *Continuum (Minneapolis, Minn)* 24 (2, Spinal Cord Disorders) (2018) 407–426.
- [28] A. Waldman, Leukodystrophies, *Continuum (Minneapolis, Minn)* 24 (1, Child Neurology) (2018) 130–149.
- [29] C. Clarke, R. Howard, M. Rossor, et al., *Neurology: A Queen Square Textbook*, 2nd Ed, John Wiley & Sons, Oxford, UK, 2016.
- [30] K. Flemming, L. Jones, *Mayo Clinic Neurology Board Review: Clinical Neurology for Initial Certification and MOC*, 1st ed, Oxford University Press, New York, NY, 2015.
- [31] S. Salinas, C. Proukakis, A. Crosby, et al., Hereditary spastic paraplegia: clinical features and pathogenetic mechanisms, *Lancet Neurol.* 7 (12) (2008) 1127–1138.
- [32] J. Statland, R. Barohn, M. Dimachkie, et al., Primary lateral sclerosis, *Neurol Clin* 33 (4) (2015) 749–760.
- [33] F. Eichler, C. Duncan, P. Musolino, et al., Hematopoietic stem-cell gene therapy for cerebral adrenoleukodystrophy, *New England J. Med.* 377 (17) (2017) 1630–1638.
- [34] P. Aubourg, C. Adamsbaum, M. Lavallard-Rousseau, et al., A two-year trial of oleic and erucic acids (“Lorenzo’s oil”) as treatment for adrenomyeloneuropathy, *New England J. Med.* 329 (11) (1993) 745–752.
- [35] A. Poulos, R. Gibson, P. Sharp, et al., Very long chain fatty acids in X-linked adrenoleukodystrophy brain after treatment with Lorenzo’s oil, *Ann Neurol* 36 (5) (1994) 741–746.
- [36] B. Turk, A. Moser, A. Fatemi, Therapeutic strategies in adrenoleukodystrophy, *Wiener Medizinische Wochenschrift* 167 (9–10) (2017) 219–226.
- [37] H. Moser, G. Raymond, S. Lu, et al., Follow-up of 89 asymptomatic patients with adrenoleukodystrophy treated with Lorenzo’s oil, *Arch Neurol* 62 (7) (2005) 1073.
- [38] A. Kemper, J. Brosco, A. Comeau, et al., Newborn screening for X-linked adrenoleukodystrophy: evidence summary and advisory committee recommendation, *Genet Med* 19 (1) (2016) 121–126.
- [39] P. Dubey, G. Raymond, A. Moser, et al., Adrenal insufficiency in asymptomatic adrenoleukodystrophy patients identified by very long-chain fatty acid screening, *J Pediatr* 146 (4) (2005) 528–532.
- [40] N. Shimozawa, A. Honda, N. Kajiwara, et al., X-linked adrenoleukodystrophy: diagnostic and follow-up system in Japan, *J Hum Genet* 56 (2) (2010) 106–109.