



A Staged Arthroscopic Approach to Fixation of Unstable Osteochondritis Dissecans in the Medial Femoral Condyle of the Knee Using Nonabsorbable Fixation Screws

Anirudh K. Gowd, M.D., Edward C. Beck, M.D., M.P.H.,
Darren Nabor, M.D., and Brian R. Waterman, M.D.

Abstract: Osteochondritis dissecans is a focal lesion of articular cartilage that can result in fragment instability with progression of early osteoarthritis. Regarding the knee joint, salvage of an unstable lesion can be achieved using arthroscopic-assisted reduction and fixation via a 2-stage process. The first involves arthroscopic fixation of the fragment using nonbioabsorbable screws, whereas the second stage performed 12 weeks later involves removal of the screws and confirmation of successful healing of the lesion. Previous studies have demonstrated excellent outcomes in patients undergoing fixation for unstable chondral lesions not amenable to conservative treatment. A critical component of successful treatment is understanding the importance of hardware placement and technique. The purpose of the Technical Note is to describe a method performing this 2-stage arthroscopic repair of an unstable chondral lesion located on the medial femoral condyle of the knee.

Osteochondritis dissecans (OCD) is a focal, idiopathic subchondral bone lesion with potential for instability and disruption of adjacent articular damage that may lead to early-onset osteoarthritis of the affected joint.^{1,2} Although OCD can develop in other joints including the hip, ankle, elbow, and wrist, the most common site is the knee. Previous literature has described the medial femoral condyle as the most common site of OCD in the knee (70%-80% of cases), followed by the lateral femoral condyle (15%-20%).³⁻⁵ Many factors contribute to the optimal treatment regimen for OCD lesions, including symptoms, stability and size of the lesion, quality of subchondral bone and ability of salvaging the bony fragment, as well as skeletal maturity of the patient.^{4,6-8}

Previous studies have demonstrated that operative fixation of unstable and salvageable fragments can result in favorable short- and long-term clinical outcomes. In a retrospective cohort study, Sanders et al.⁹ identified 221 patients with OCD lesions treated operatively over a 34-year period. The authors observed that patients treated with fragment preservation had significantly lower rates of osteoarthritis and rates of conversion to arthroplasty when compared with patients treated with fragment excision. Others have reported high numbers of patients achieving fragment union (82%) after undergoing fragment fixation, with satisfactory activity levels and knee outcomes scores when compared to non-union patients.¹⁰

In cases when the lesion is unstable and the bony fragment is salvageable, arthroscopic fixation of the

From the Division of Sports Medicine, Department of Orthopedic Surgery, Wake Forest Baptist Health, Winston-Salem, North Carolina, U.S.A.

The authors report the following potential conflict of interest or source of funding: B.R.W. reports other from the American Academy of Orthopaedic Surgeons, other from the American Journal of Orthopedics, other from Arthroscopy, other from the Arthroscopy Association of North America, personal fees from Elsevier, personal fees from Genzyme, and other from the Society of Military Orthopaedic Surgeons, outside the submitted work. Full ICMJE author disclosure forms are available for this article online, as supplementary material.

Received October 29, 2019; accepted November 29, 2019.

Address correspondence to Edward C. Beck, M.D., M.P.H., Department of Orthopedic Surgery, Wake Forest Baptist Health, 1 Medical Center Blvd., Winston-Salem, NC 27101. E-mail: Ebeck@wakehealth.edu or Edward.Beck@rushortho.com

© 2020 by the Arthroscopy Association of North America. Published by Elsevier. This is an open access article under the CC BY-NC-ND license (<http://creativecommons.org/licenses/by-nc-nd/4.0/>).

2212-6287/191314

<https://doi.org/10.1016/j.eats.2019.11.021>

fragment is recommended.⁷ These include OCD lesions with partially detached fragments (International Cartilage Repair Society [ICRS] grade 3) or lesions with displaced intra-articular loose bodies (ICRS grade 4).^{4,10,11} A critical component in most cases is the ability to achieve 2 points of fixation to provide compression and rotational stability.¹² The purpose of this Technical Note is to describe a 2-stage arthroscopic approach for fixation of an unstable chondral defect located on the medial femoral condyle of the knee using non-bioabsorbable screws.

Surgical Technique

Patient Positioning

The patient is positioned supine on a standard operating room table, padding all bony prominences. A bump is placed below the buttock of the operative side to neutralize external hip rotation, and a nonsterile tourniquet is placed on the thigh. A lateral post is then placed at the mid-thigh to support the operative limb during applied valgus stress. A footrest is secured to the operative bed to allow a resting position in approximately 70° to 90° of knee flexion while still allowing the knee to hang off the side of the bed for arthroscopy.

Arthroscopic Technique (With Video Illustration)

A diagnostic arthroscopy is performed to confirm the anticipated chondral pathology (Video 1). Standard inferomedial and inferolateral arthroscopic portals are established. Diagnostic arthroscopy revealed a large ICRS grade 3 OCD lesion on the medial femoral condyle (Fig 1). An arthroscopic probe is used to evaluate the stability of the lesion (Fig 2). In the video, arthroscopic

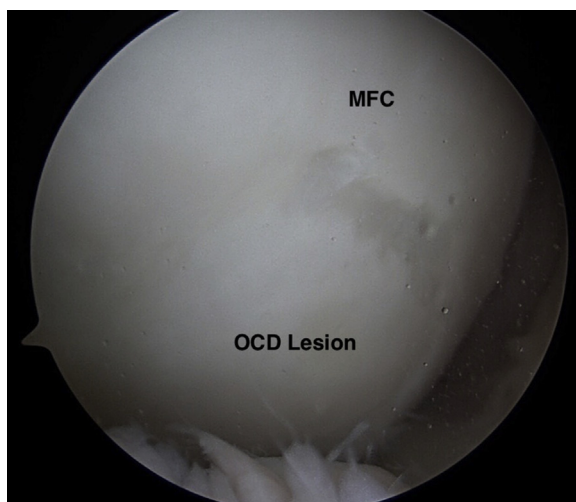


Fig 1. Intra-articular image of a right knee diagnostic arthroscopy viewed from the inferomedial portal demonstrating a large osteochondritis dissecans lesion located on the medial femoral condyle. (MFC, medial femoral condyle; OCD, osteochondritis dissecans lesion.)

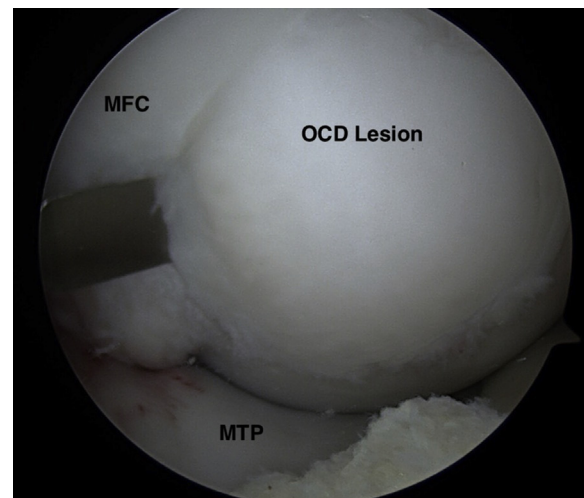


Fig 2. Arthroscopic image of a right knee viewed through the inferomedial portal demonstrating the use of an arthroscopic freer/elevator to evaluate the stability of a large osteochondritis dissecans lesion located on the medial femoral condyle. (MFC, medial femoral condyle; MTP, medial tibial plateau; OCD, osteochondritis dissecans lesion.)

evaluation of the fragment demonstrates a “trap door” mobile lesion, with the cartilage fissuring at the periphery, while being able to hinge open.¹ The anterior portion of the flap is preserved to maintain stability of the OCD lesion. Fragment fixation preparation is performed with an arthroscopic shaver and curettes. All debris and fibrotic tissue are removed to expose healthy underlying subchondral bone with punctate bleeding. In addition, microfracture awls should be used at the base to promote blood flow (Fig 3).

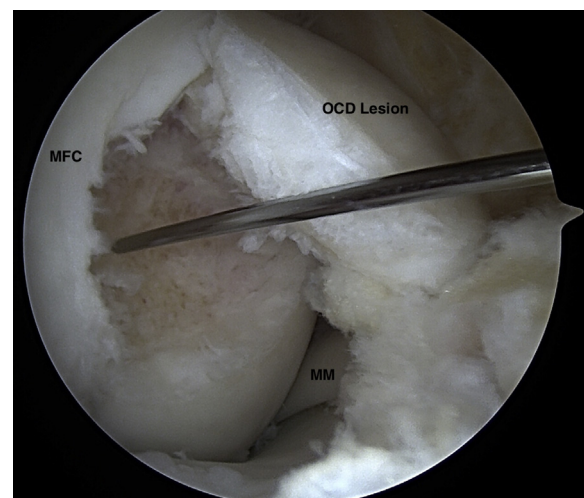


Fig 3. Arthroscopic image of a right knee viewed through the inferomedial portal demonstrating the use of a microfracture awl on the base of the osteochondritis dissecans lesion defect, which promotes blood flow and tissue healing. (MFC, medial femoral condyle; MM, medial meniscus; OCD, osteochondritis dissecans lesion.)

After thorough fragment preparation, a transpatellar portal is established under needle localization approximately 2 cm lateral and 1 cm proximal to the previous anteromedial tunnel. K-wires are inserted through the transpatellar portal perpendicular to the lesion to provide compression with cannulated screws (Fig 4). The chondral fragment is then drilled and a mini-headless compression screw is placed through the same portal. The screw is countersunk slightly beneath the chondral surface to prevent opposing articular cartilage wear (Fig 5). A second screw is placed in close proximity to provide compression and rotational stability. Visual confirmation of fragment stability and screw placement is performed (Fig 6). Lastly, an adjunctive biologic, such as platelet-rich plasma, may be introduced at the base of the fragment with a syringe to further promote healing. Optionally, larger subchondral bony defects may be grafted with autogenous cancellous autograft harvested from the ipsilateral tibia. In this case, an admixture of demineralized bone matrix and cancellous autograft were introduced via a small cannula. A tamp was used to build up and compress the bony defect before flap reduction and screw fixation.

At approximately 10 to 12 weeks after surgery, the second phase of treatment is carried out after confirmation of early osseous healing on serial plain film radiographs. Evidence of union is established by using a probe to attempt mobilization of the fragment (Fig 7). Once union is confirmed, K-wires are used to locate the screws, which are then removed. Once both screws are removed, a dynamic examination of the knee joint under arthroscopy is performed to ensure that the OCD lesion is stable, including probe evaluation (Fig 8). Of

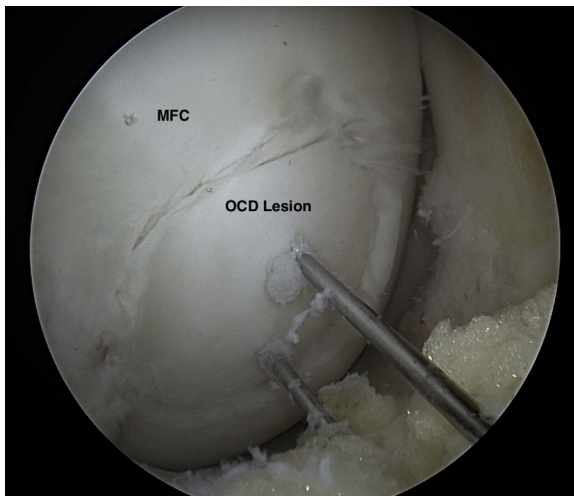


Fig 4. Arthroscopic image of a right knee viewed through the inferomedial portal demonstrating insertion of K-wires are inserted into the osteochondritis dissecans lesion through the transpatellar portal to pin the fragment and assist in placement of the fixating screws. (MFC, medical femoral condyle; OCD, osteochondritis dissecans lesion.)

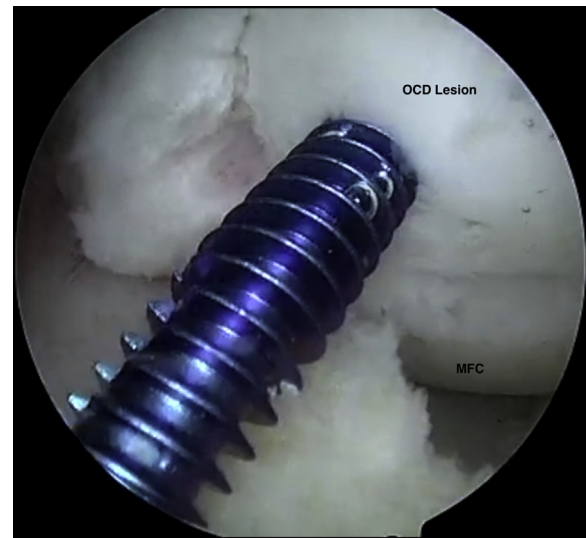

Fig 5. Arthroscopic image of a right knee viewed through the inferomedial portal demonstrating inserted of headless compression screw over the K-wire onto the osteochondritis dissecans lesion, ensuring that placement is completely perpendicular to the fragment surface. (MFC, medical femoral condyle; OCD, osteochondritis dissecans lesion.)

note, as previously mentioned, bioabsorbable fixation remains an alternative option (Bio-Compression Screws; Arthrex, Naples, FL). The benefit of revisiting the lesion postoperatively is to confirm healing and remove hardware that might become prominent if the fragment were to settle around the screws.¹²

Postoperative Rehabilitation

Rehabilitation is started on postoperative day 1 for all patients. During the initial 6 weeks postoperatively,

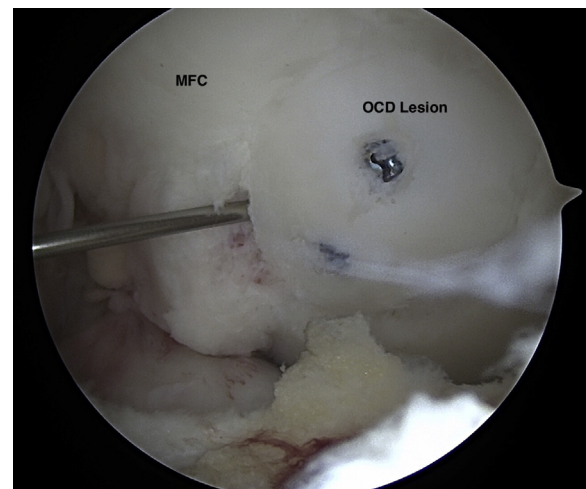


Fig 6. Arthroscopic image of a right knee viewed through the inferolateral portal demonstrating visual confirmation of fragment stability and hardware recessed beneath the cartilage surface. (MFC, medical femoral condyle; OCD, osteochondritis dissecans lesion.)

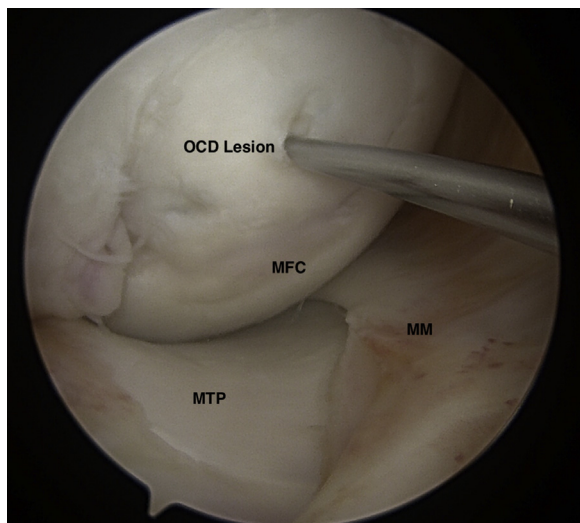


Fig 7. Arthroscopic image of a right knee viewed through the inferomedial portal demonstrating using a probe to ensure successful union of the osteochondritis dissecans lesion by attempt mobilization of the fragment. (MFC, medical femoral condyle; MM, medial meniscus; MTP, medial tibial plateau; OCD, osteochondritis dissecans lesion.)

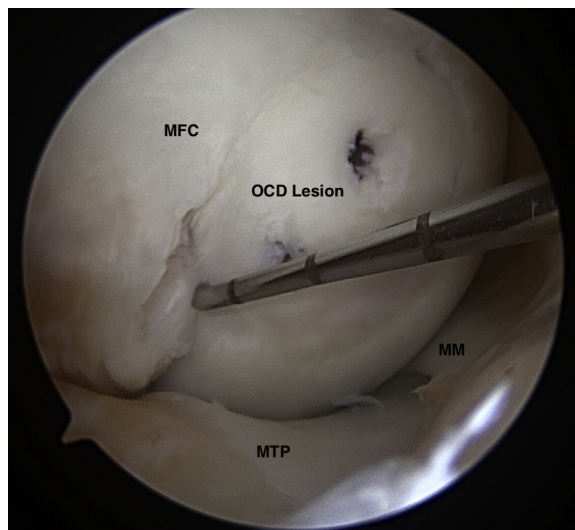


Fig 8. Arthroscopic image of a right knee viewed through the inferomedial portal demonstrating using a probe to confirm successful union of the fragment after both screws have been removed. (MFC, medical femoral condyle; MM, medial meniscus; MTP, medial tibial plateau; OCD, osteochondritis dissecans lesion.)

patients are instructed to toe-touch weight-bearing with crutches, followed by 6 weeks of weight-bearing as tolerated between the first and second stages. Following the second procedure, the patient is placed in a hinged knee brace for the first 4 to 6 weeks with partial weight-bearing as tolerated and locked in extension for the first 2 weeks. Once the patient shows quadriceps strength necessary to support ambulation and perform a straight leg raise without extension lag, the brace is discontinued. At 6 weeks, patients are permitted to bear full weight, and the patient initiates a walk-to-run protocol at 6 weeks after secondary screw removal. At 6 months postoperatively, patients may begin greater-impact exercises, with progression to unrestricted sport-specific activities as tolerated.

Discussion

In this Technical Note, we describe a method for arthroscopic internal fixation of an unstable, “trap door” OCD lesion of the knee. Although there is limited literature looking at outcomes after OCD fixation, most

studies have demonstrated favorable outcomes at short- and long-term follow-up. In a multicenter retrospective study, Wu et al.¹³ identified 87 patients who underwent arthroscopic fixation of unstable OCD knee lesions using either removable or bioabsorbable screws. At a mean follow-up of 60 months, the survival rate was 75.9%, with no statistically significant difference in survivorship between skeletally immature and mature patients. In a small case series, Din et al.¹⁴ evaluated fixation of 12 knees undergoing arthroscopic fixation of OCE lesion using bioabsorbable pins. At a mean follow-up time of 32.4 month, all OCD fragments viewed on magnetic resonance imaging demonstrated evidence of healing. Furthermore, all patients returned to sport within 8 months after surgery. However, as previously mentioned, use of bioabsorbable implants may have the inherent limitation of not requiring direct visual inspection of the fixed fragment during a second arthroscopic procedure. In a study that reviewed 96 knees with juvenile OCD, 13 of them had open physes treated with arthroscopic fixation using bioabsorbable pins.

Table 1. Advantages and Disadvantages to OCD Fragment Fixation Using an Arthroscopic Approach With Nonbioabsorbable Screws

Advantages	Disadvantages
Technique leads to less complications over the open approach	Arthroscopic procedures have an inherently larger learning curve over open approaches
Preserves the native cartilage instead of removing the fragment or inserting an allograft in its place	Use of nonbioabsorbable screws requires 2 separate arthroscopic procedures 4-6 weeks apart
Use of nonbioabsorbable screws allows for direct visual confirmation of fragment union	Possible iatrogenic injury caused by the screws if not secured below the level of the fragment surface

OCD, osteochondritis dissecans.

Table 2. Pearls and Pitfalls to OCD Fragment Fixation Using an Arthroscopic Approach With Nonbioabsorbable Screws**Pearls**

- Familiarity with the anatomic location of the chondral lesion is important, as well as full visual arthroscopic inspection of the entire articular surface to prevent undiagnosed lesion.
- Inspection of a “trap-door” type chondral lesion using an arthroscopic freer is necessary for assessing the viability of the cartilage and for performing microfracture at the subchondral bed
- Rehabilitation is started on postoperative day 1 with strict weight bearing regimens to allow for fragment adhesion, while preventing joint stiffness from excessive immobilization

Pitfalls

- Placing the screws within close proximity to each other or not parallel to the chondral surface can cause shifting of the fragment and mal-union
- Not placing the nonbioabsorbable screws below the level of the fragment surface and anticipating settling of the fragment can result in iatrogenic cartilage damage by protruding screws

OCD, osteochondritis dissecans.

Ishikawa et al.¹⁵ found that 4 required revisions (failure rate 23%) and all of the revision cases were unstable on magnetic resonance imaging follow-up. Other case series examining outcomes in skeletally mature patients with metal screws used for fixation demonstrated failure rate of 18% (n = 4) with a mean follow-up of 31 months.¹⁰

The advantages of the current technique are numerous (Table 1). First, this arthroscopic technique is preferred over an open approach, which may lead to further complications.¹⁶ Second, this technique offers an efficient method of cartilage preservation by fixating the native lesion. As mentioned previously, preserving of the native cartilage is preferred over removal of the fragment or insertion of an allograft in its place.⁷ Third, the method detailed demonstrates fixation of an unstable OCD lesion with nonbioabsorbable screws. While this technique does require an additional arthroscopic procedure, it allows for direct visual confirmation of fragment union. The risks of this technique are few. Arthroscopic procedures have an inherently larger learning curve over open approaches. Furthermore, iatrogenic injury caused by the screws is possible if they are not secured below the chondral surface as well as anticipating potential fragment settling with resultant prominent hardware. The advantages and limitations of this technique are summarized in Table 1, whereas Table 2 lists salient pearls and pitfalls.

Conclusions

In conclusion, arthroscopic techniques for repair of unstable OCD lesions represent a promising development to benefit patients with reduced morbidity and progression of osteoarthritis. More robust studies are needed to compare this technique with other alternative methods.

References

1. Carey JL, Wall EJ, Grimm NL, et al. Novel arthroscopic classification of osteochondritis dissecans of the knee: A multicenter reliability study. *Am J Sports Med* 2016;44:1694-1698.
2. Edmonds EW, Shea KG. Osteochondritis dissecans: Editorial comment. *Clin Orthop Relat Res* 2013;471:1105-1106.
3. Kocher MS, Tucker R, Ganley TJ, Flynn JM. Management of osteochondritis dissecans of the knee: Current concepts review. *Am J Sports Med* 2006;34:1181-1191.
4. Erickson BJ, Chalmers PN, Yanke AB, Cole BJ. Surgical management of osteochondritis dissecans of the knee. *Curr Rev Musculoskelet Med* 2013;6:102-114.
5. Kon E, Vannini F, Buda R, et al. How to treat osteochondritis dissecans of the knee: Surgical techniques and new trends: AAOS exhibit selection. *J Bone Joint Surg Am* 2012;94(1-8):e1.
6. Cruz AI Jr, Shea KG, Ganley TJ. Pediatric knee osteochondritis dissecans lesions. *Orthop Clin North Am* 2016;47:763-775.
7. Cavalheiro CM, Cotter EJ, Waterman BR, Cole BJ. Osteochondritis dissecans of the knee. *Cartilage Restoration* 2018;51-64.
8. Cahill B. Treatment of juvenile osteochondritis dissecans and osteochondritis dissecans of the knee. *Clin Sports Med* 1985;4:367-384.
9. Sanders TL, Pareek A, Obey MR, et al. High rate of osteoarthritis after osteochondritis dissecans fragment excision compared with surgical restoration at a mean 16-year follow-up. *Am J Sports Med* 2017;45:1799-1805.
10. Barrett I, King AH, Riester S, et al. Internal fixation of unstable osteochondritis dissecans in the skeletally mature knee with metal screws. *Cartilage* 2016;7:157-162.
11. Brittberg M, Winalski CS. Evaluation of cartilage injuries and repair. *J Bone Joint Surg Am* 2003;85-A:58-69 (suppl 2).
12. Pascual-Garrido C, McNickle AG, Cole BJ. Surgical treatment options for osteochondritis dissecans of the knee. *Sports Health* 2009;1:326-334.
13. Wu IT, Custers RJH, Desai VS, et al. Internal fixation of unstable osteochondritis dissecans: do open growth plates improve healing rate? *Am J Sports Med* 2018;46:2394-2401.
14. Din R, Annear P, Scaddan J. Internal fixation of undisplaced lesions of osteochondritis dissecans in the knee. *J Bone Joint Surg Br* 2006;88:900-904.
15. Ishikawa M, Nakamae A, Nakasa T, et al. Limitation of in-situ arthroscopic fixation for stable juvenile osteochondritis dissecans in the knee. *J Pediatr Orthop B* 2018;27:516-521.
16. Lu Y, Li YJ, Guo SY, Zhang HL. Is there any difference between open and arthroscopic treatment for osteochondritis dissecans (OCD) of the humeral capitellum: A systematic review and meta-analysis. *Int Orthop* 2018;42:601-607.