

Available online at [www.sciencedirect.com](http://www.sciencedirect.com)

journal homepage: [www.elsevier.com/locate/radcr](http://www.elsevier.com/locate/radcr)

## Case Report

# Palpable abdominal mass and recurrent fecal incontinence due to failure of artificial bowel sphincter

Tim Zellmer, BS<sup>a,1,\*</sup>, William MacDonald, MD<sup>b,2</sup>

<sup>a</sup> Medical College of Wisconsin, 8701 W Watertown Plank Rd, Milwaukee, WI 53226, USA

<sup>b</sup> Aurora St. Luke's Medical Center, 2900 W Oklahoma Avenue, Milwaukee, WI 53215, USA

### ARTICLE INFO

#### Article history:

Received 14 June 2018

Revised 22 August 2018

Accepted 26 August 2018

Available online 17 October 2018

#### Keywords:

Artificial Bowel Sphincter (ABS)

Fecal Incontinence (FI)

### ABSTRACT

Artificial bowel sphincters (ABS), specifically the Acticon Neosphincter, have been used to treat fecal incontinence (FI) since the early 2000s. This report and literature review focuses on possible device malfunctions of previously placed ABS for FI. We present a case of device malfunction in a patient with FI who had a previously placed ABS, review relevant literature, and discuss outcomes of ABS placement with possible device malfunctions.

© 2018 The Authors. Published by Elsevier Inc. on behalf of University of Washington.

This is an open access article under the CC BY-NC-ND license.

(<http://creativecommons.org/licenses/by-nc-nd/4.0/>)

## Introduction

Fecal incontinence (FI) is defined as the involuntary loss of solid or liquid feces. FI that is refractory to other treatments can be treated with placement of an Artificial Bowel Sphincter (ABS) such as the Acticon Neosphincter. The Acticon Neosphincter is a solid silicone elastomere that consists of 3 fluid-filled components connected by tubing. The components include a cuff that is implanted around the anal canal, a pressure-regulating balloon that is placed in the space of Retzius, and a control pump which is placed in the labia or scrotum. When the cuff is filled with fluid, it occludes the anal canal. The fluid is transferred from the cuff to the pressure regulating balloon by squeezing the control pump. This al-

lows the cuff to open and the patient to evacuate stool. The pressure from the balloon allows the fluid to fill back into the cuff and back to its resting state, once again occluding the anal canal [1].

## Case report

Patient is a 63-year-old female with past medical history of refractory FI status post-Acticon Neosphincter placement in 2008 who presented with a left lower quadrant abdominal mass for 1 year, worsening FI, and diarrhea. She denied any urinary incontinence or any other urinary symptoms. Patient has had 4 pregnancies, 2 live births, 2 vaginal deliveries, and an

\* Corresponding author.

E-mail addresses: [tzellmer@mcw.edu](mailto:tzellmer@mcw.edu) (T. Zellmer), [William.MacDonald@aurora.org](mailto:William.MacDonald@aurora.org) (W. MacDonald).

<sup>1</sup> B.S Investigative and Medical Sciences, Saint Louis University, 2015; Doctorate of Medicine, Medical College of Wisconsin, Anticipated 2019.

<sup>2</sup> Doctorate of Medicine, Wayne State University School of Medicine; Residency in Diagnostic Radiology, William Beaumont Hospital.

<https://doi.org/10.1016/j.radcr.2018.08.024>

1930-0433/© 2018 The Authors. Published by Elsevier Inc. on behalf of University of Washington. This is an open access article under the CC BY-NC-ND license. (<http://creativecommons.org/licenses/by-nc-nd/4.0/>)

episiotomy during childbirth that cut into anal sphincter causing original problem of FI. On physical exam, external rectum was normal and ABS was palpated. Patient had no abdominal tenderness, but there was about a 10-cm by 10-cm induration in left lower quadrant. A CT of her abdomen and pelvis was ordered. CT scan confirmed previous placement of ABS with an inappropriately decompressed cuff around anal canal and an inappropriately expanding balloon reservoir in the patient's lower abdomen compressing the bladder. There was no prior CT. Patient was referred to colorectal surgery to consider revision, explantation, or other possible surgical interventions. Presently, no final decision has been made on treatment.

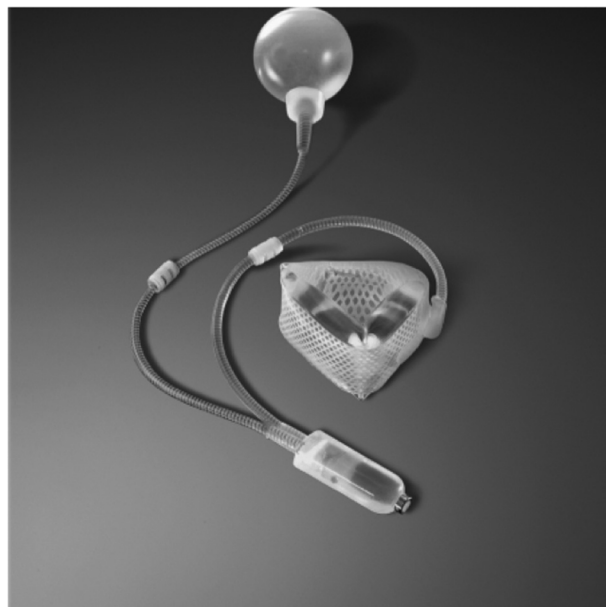## Discussion

This patient had an Acticon Neosphincter ABS placed in 2008 for her refractory FI. While this device originally had been working, her worsening FI, abdominal mass, and CT results are suggestive of a malfunctioning ABS. This prompted a literature review on the success and complications associated with the Acticon Neosphincter. The Acticon Neosphincter was FDA approved in 2001 for use in FI and consists of an occlusive cuff, a control pump, and a balloon reservoir. In a 112-patient prospective study of patients implanted with this device, 51 patients (46%) required revision and 41 patients (37%) required explantation, while 60 patients (53%) reported clinically significant improved FI scores [2]. In a small randomized control trial, 14 patients with refractory FI were assigned to conservative management with medications and biofeedback or placement of an ABS. This study concluded that as compared to baseline, ABS, but not conservative management resulted in significant improvement in continence and quality of life [3]. Additionally, a single-center study was conducted from 1996 to 2010 and included 52 patients with refractory FI who received the Acticon Neosphincter. All of these patients had end stage FI that failed conservative management and pelvic floor training for 1 year. 26 patients (50%) required revision of the device. Indications for revision included device malfunction (leaking cuff or leaking pressure regulated balloon), erosion (erosion of cuff in perineum or erosion of tubing in the groin), pump migration, or pain. Fourteen patients (27%) required explantation of the device. Indications included infection, ineffective device, pain, and erosion of cuff into anal canal. Risk of revision was found to rise to above 80% after 10 years of having the device and risk of explanation nearing 40% over the same time period [4].

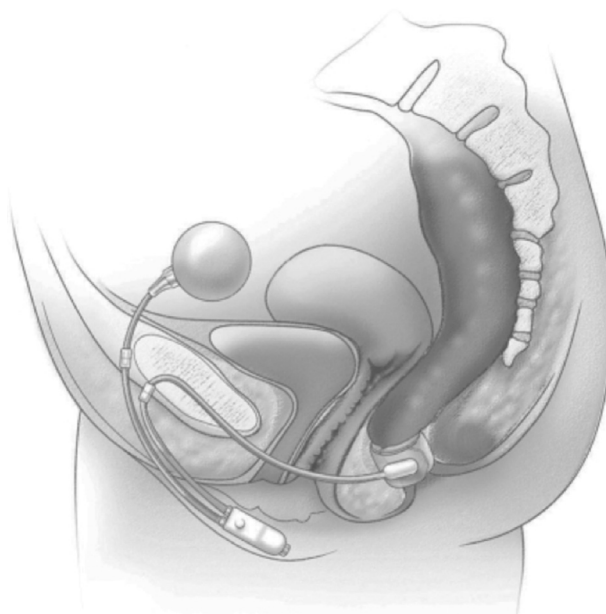
The exact nature of our patient's device malfunction is uncertain. It appears that the balloon reservoir was not draining fluid properly and was thus expanding in her abdomen. It is conceivable that over time the balloon hardened and lost some of its elasticity hindering its ability to drain fluid back into the cuff. Additionally, failure of the control pump could result in dysfunctional movement of fluid throughout the device leading to balloon expansion. Last, failure or kinking of the tubing could prevent fluid from draining properly from the balloon back to the cuff and cause expansion of the balloon in the abdomen. All of these possible device malfunctions could explain the patient's worsening FI and hardened, indurated left lower quadrant of her abdomen.

Of note, the FDA recalled the Acticon Neosphincter in 2011 due to failure of the control pump resulting in malfunction of the control pump activation mechanism. At time of recall, 225 were in commerce. As this patient's ABS was placed in 2008, this recall could be relevant to her case and her symptoms could be explained by control pump malfunction.

While the patient is currently experiencing ABS device malfunction, it should be noted that the device had been

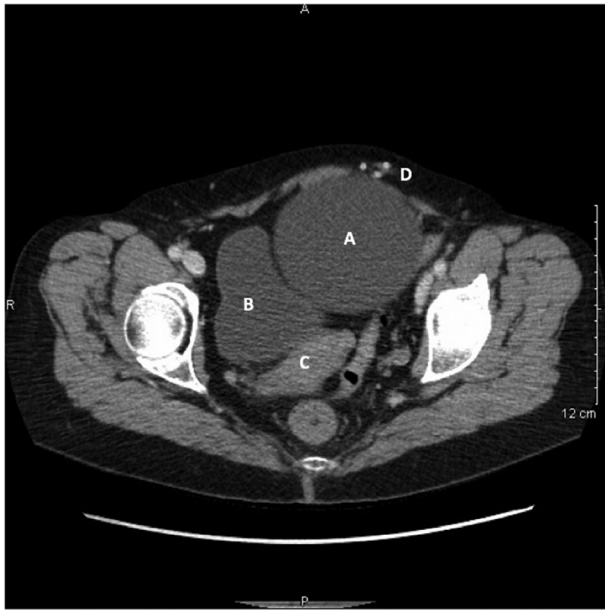

**Fig. 1 – An artificial bowel sphincter device, Acticon Neosphincter (courtesy of American Medical Systems, Inc, Minnetonka, MN, [www.AmericanMedicalSystems.com](http://www.AmericanMedicalSystems.com)).**

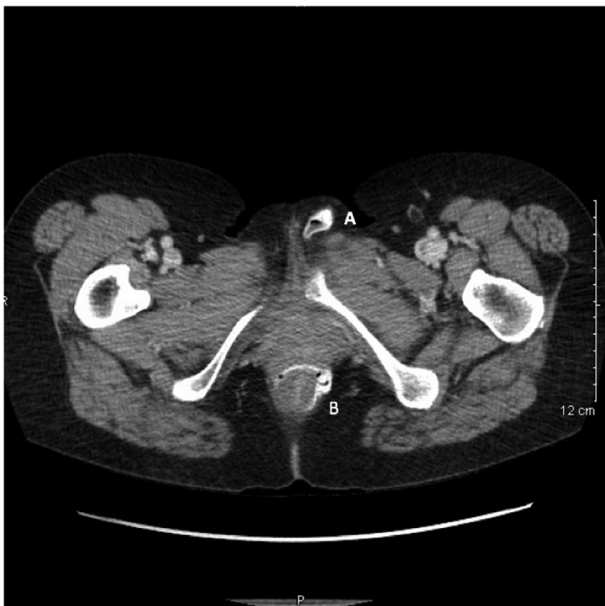

**Fig. 2 – Artificial Bowel Sphincter device, Acticon Neosphincter, implanted in a female (courtesy of American Medical Systems, Inc, Minnetonka, MN, [www.AmericanMedicalSystems.com](http://www.AmericanMedicalSystems.com)).**

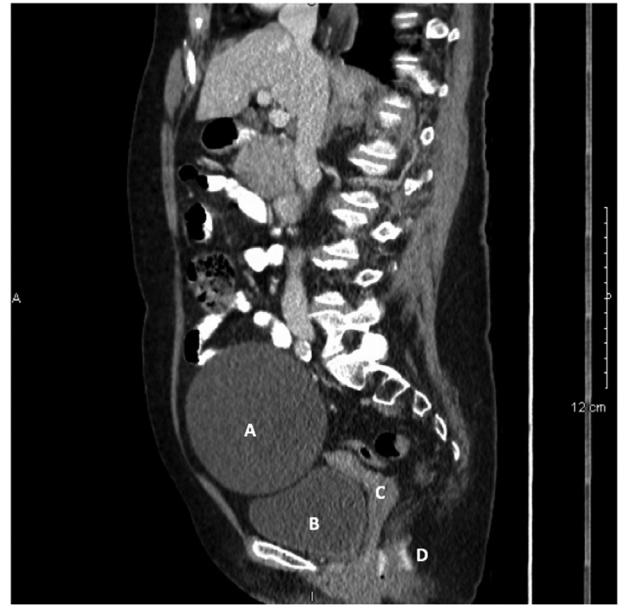
functioning for 10 years before failure. Given the risk of early revision and over an 80% risk of revision and 40% risk of explantation after 10 years of having device, this appears to be a good result. The exact life expectancy of the Acticon neosphincter is unknown. One study reported that 8 of 17 (47%) of their patients had their original ABS still in place after 5 years while another study had patients with functioning devices for more than 10 years after implantation [5,6].



**Fig. 3 – Axial CT showing balloon reservoir (A) displacing urinary bladder (B) and uterus (C). Tubing (D) seen in anterior subcutaneous tissue.**



**Fig. 4 – Axial CT showing control pump (A) in labia with cuff (B) around anal canal.**



**Fig. 5 – Sagittal CT showing balloon reservoir (A) displacing urinary bladder (B) and uterus (C). Cuff (D) seen around anal canal.**

## Conclusion

In conclusion, this case provided an atypical etiology of a left lower quadrant mass secondary to a malfunctioning ABS that was diagnosed on CT (Figs. 1–5).

## Supplementary materials

Supplementary material associated with this article can be found, in the online version, at doi: [10.1016/j.radcr.2018.08.024](https://doi.org/10.1016/j.radcr.2018.08.024).

## REFERENCES

- [1] Gregorcyk S. The current status of the acticon® neosphincter. *Clin Colon Rectal Surg* 2005;18(1):32–7.
- [2] Wong W, Congliosi S, Spencer M, Corman M, Tan P, Opelka F, et al. The safety and efficacy of the artificial bowel sphincter for fecal incontinence: results from multicenter cohort study. *Dis Colon Rectum* 2002;45:1139.
- [3] O'Brien P, Dixon J, Skinner S, Laurie C, Khera A, Fonda D. A prospective, randomized, controlled clinical trial of placement of Artificial Bowel Sphincter for control of fecal incontinence. *Dis Colon Rectum* 2004;47:1852.
- [4] Wong M, Meurette G, Wyart V, Glemain P, Lehur P. The artificial bowel sphincter: A single institution experience over a decade. *Ann of Surg* 2011;254:6.
- [5] Christiansen J, Rasmussen O, Lindorff-Larsen K. Long-term results of artificial anal sphincter implantation for severe anal incontinence. *Ann Surg* 1999;230:45–8.
- [6] Parker S, Spencer M, Madoff R, Jensen L, Wong W, Rothenberger D. Artificial bowel sphincter: long-term experience at a single institution. *Dis Colon Rectum* 2003;46:722.