

A novel technique for the reconstruction of resected sternoclavicular joints: A case report with a review of the literature

Waseem M. Hajjar, Sami Alnassar, Saleh N. Abu-Daff¹, Saleh F. Al-Dhahri²

Department of Surgery
College of Medicine,
King Saud University,
¹Thoracic Surgery
Division, Department of
Surgery, ²Department
of ENT, King Fahad
Medical City, Riyadh,
Saudi Arabia

**Address for
correspondence:**

Dr. Waseem Hajjar, MD,
FRCS. Assistant Professor
and Consultant Thoracic
Surgeon, Department
of Surgery, College of
Medicine, King Saud
University, King Khalid
University Hospital,
Riyadh, Saudi Arabia.
E-mail: washajjar@yahoo.
com

Submission: 27-10-2011
Accepted: 13-02-2012

Abstract:

Sternal metastasis in thyroid cancer is an uncommon occurrence with only a handful of cases of chest wall resections being done. Sternal reconstruction for both primary and secondary tumors has been performed using various techniques and materials such as the mesh, methyl acrylate resin, and steel plates; however, this is a case of papillary thyroid cancer involving the sternum in a 50-year-old woman who had resection of the sternum with reconstruction using titanium bars and clips (STRATOS system) fixed to the clavicles with an underlying Proceed mesh. STRATOS system showed good recovery postoperatively. The functional results were excellent with the patient being able to perform all daily activities unassisted after 1 month and almost complete range of motion with acceptable limitations in power of the shoulder muscles after 2 months. We have reviewed all the English language publications of the subject by doing Medline search for the last 25 years and we present here the surgical management of this pathology with our novel approach by using the titanium steel bars to stabilize both medial aspects of the resected clavicles as a promising therapy for manubrial reconstruction and clavicular fixation.

Key words:

Reconstruction, sternum, stratos, thyroid, titanium

Thyroid cancer metastasizing to the sternum is an uncommon occurrence and only a handful of cases of chest wall resections for this condition exist in the English language literature.^[1-4] In fact, Mansour *et al.* reported of 200 cases of sternal resection and reconstruction over a 25-year period, of which only one case was due to a thyroid malignancy.^[5] Despite its relative rarity, accounts on the necessity for surgical intervention for this condition are uniform, and this is mainly because of the high failure rate of radioactive Iodine therapy in bony metastases of thyroid origin.^[6]

Reconstruction of the sternum for both primary and secondary tumors has been performed by a variety of techniques and using a variety of materials, the most popular methods of synthetic repair are the mesh, methyl acrylate resin, and steel plates.^[5,7]

Usually, in these repairs, the clavicle is resected with variable complications and effects including skin necrosis, chronic pain, loss of function and power^[8] at the shoulder join and an unsatisfying cosmetic outcome.

The STRATOS (Strasburg Thoracic Osteosyntheses System) is a unit composed of multiple multi-length titanium bars and clips

recently developed for chest wall reconstruction by MedXpert GmbH (Heitersheim, Germany).

We have reviewed all the English language publications of the subject by doing Medline search for the last 25 years, and we have found only one recent case report in the literature of the use of this system in sternal reconstruction.^[9] However, our case report which we present here is the second case of sternal repair using STRATOS system. We also reviewed in this article all the various techniques of the surgical management of this pathology and we compare it with our novel approach of clavicular fixation by using the titanium steel bars to stabilize both medial aspects of the resected clavicles.

Case Report

This is a 52-year-old female patient who underwent sub-total thyroidectomy with a preoperative diagnosis of multinodular goiter; however, the postoperative pathology findings revealed a papillary thyroid cancer.

Two months after her surgery, she noticed a swelling just below the original collar incision which was hard in consistency and rapidly increasing in size. The swelling was located at the level of the manubrium, with a conspicuous

Access this article online

Quick Response Code:



Website:

www.thoracicmedicine.org

DOI:

10.4103/1817-1737.105722

erythema on the overlying skin. The rest of her examination was unremarkable.

A CT scan of the chest was performed and showed extensive bone destruction of the manubrium that is causing mild compression of the innominate vein [Figure 1]. Tc-99m bones scan showed intense activity at the manubrium coinciding with the CT findings, with no uptake elsewhere in the body. Work up for distal metastasis was negative.

With these findings, direct invasion of the manubrium from residual retrosternal thyroid tumor was suspected and this was confirmed by fine needle aspiration biopsy from this swelling which showed papillary thyroid cancer; however, the patient was scheduled for en-block resection of the residual tumor. The surgery started with a vertical sternal midline incision meeting the previous collar incision at the middle which was also opened over the previous scar, then both pectoralis major muscles flaps created bilaterally by undermining the medial border of the muscles. The internal mammary arteries were ligated bilaterally and the manubrium was excised at the level of first and second ribs on both sides together with the medial thirds of the clavicles [Figure 2a, b]. Bilateral neck dissection was performed through her new midline and previous collar incisions. For the reconstruction we placed a dual-layer Proceed mesh on the mediastinal surface that was sutured to underlying tissue with prolene 2.0 sutures, overlying the mesh, two pieces of titanium bars and clips with 45° angles placed at the clavicles and crossing in an X fashion connected to the 2nd ribs bilaterally. The clips were fixed in place using special pliers provided with the STRATOS system [Figure 3]. Two drains were left overlying the mediastinum; a second Proceed mesh was used and was placed between underlying bars and soft tissue. Closure of the defect was achieved with the pectoral flap and the overlying soft tissue.

Postoperatively, recovery was uneventful, the patient discharged one week after the surgery in a very good condition. The histopathology report of the specimens revealed a differentiated papillary thyroid carcinoma involving the manubrium with five positive lymph nodes: Two located in the central pre-tracheal area, two in the superior mediastinal beside the innominate vein, and one lymph node adjacent to the right internal jugular vein. However, the surgical resection margins were clear. She was referred to the oncologist and he advised for postoperative ablation treatment in the form of high dose of radioactive iodine.

The functional results are excellent with the patient being able to perform all her daily activities unassisted one month after the procedure. The patient was followed up 8 weeks after the procedure for functional scoring of her shoulders, scoring was performed by an independent party for both active and passive range of motion as well as power testing of the shoulder muscles, and achieved almost complete range of motion, and with functionally acceptable limitations in power [Table 1].

Discussion

Thyroid tumors involving the sternum are rare and the literature provides only a handful of case reports on the surgical management of this pathology; to our knowledge,

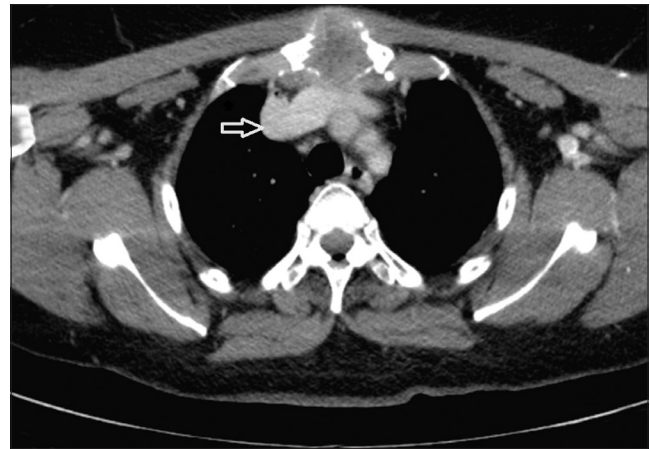

Figure 1: CT image showing extensive destruction of the manubrium

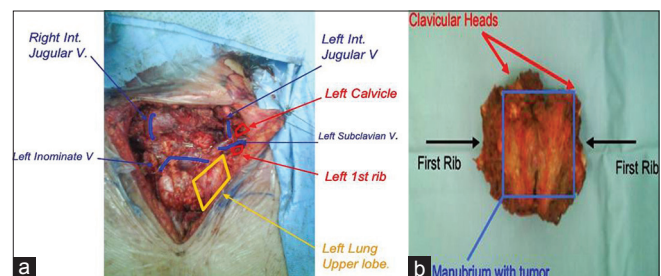


Figure 2: (a) The operative field after the specimen has been resected; (b) The resected specimen

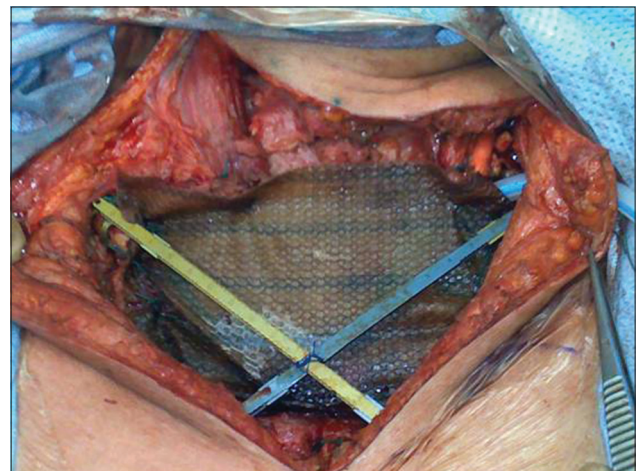


Figure 3: Operative image showing fixation of the titanium bars to the clavicles and 2nd ribs

there are nine cases published in the English language as case reports, with four more cases included within large case series [Table 2].

Interestingly enough, most of the cases (5 of 9) published were verified as follicular thyroid carcinoma rather than papillary. This seems unusual since overall papillary thyroid carcinoma is overtly more common and more likely to direct extension than follicular thyroid carcinoma, and as of present there is no clear explanation of this observation.

Table 1: Functional assessment of shoulder joint

	PROM	AROM	Power
Flexion	170°/180°	180°/180°	3/3
Abduction	180°/180°	165°/180°	3/3
Extension	60°/60°	60°/60°	4/4
Internal rotation	90°/90°	90°/90°	5/5
External rotation	90°/90°	90°/90°	5/5

*PROM = Passive range of motion, AROM = Active range of motion values are described as right arm/Left arm, respectively, values in red represent limitations in range of motion, Power is expressed on the 5-point scale

Table 2: Cases of surgical resection of the sternum for thyroid cancer in the literature: Cases presented within case series had no mention of the type of thyroid malignancy involved

Author (Year)	No. of cases	Pathology
Ozaki (1995) ^[10]	2	Follicular/Papillary
Muthuphei (1998) ^[11]	1	Follicular
Mishra (2001) ^[1]	2	Follicular/Poorly differentiated
Carbognani (2001) ^[7]	1 of 13	N/A
Mansour (2002) ^[5]	1 of 200	N/A
Lequaglie (2002) ^[12]	2 of 98	N/A
Kinoglou (2003) ^[13]	1	Papillary
Haraguchi (2004) ^[2]	1	Papillary
Meyer (2005) ^[3]	1	Follicular
Erogulu (2006) ^[4]	1	Follicular
Present case (2009)	1	Papillary

Despite the good outcome of thyroid cancers in general, patients who develop bone metastasis do not fair too well, with 10-year survival rate from 95% to 40% with bone metastasis. The conventional therapy of radio-iodine has shown limited success rates in thyroid cancer bone metastasis, and Zettinig *et al.*^[6] have shown improved overall survival with surgical resection of these metastases in patients with no extra-skeletal involvement of the tumor.

As for reconstruction, prosthetic materials used to reconstruct the chest wall are varied and depend mainly on the type and size of the defect, the presence of infection, and the surgeon's preference. Sternal resections limited to the manubrium however are usually treated by simple closure or closure over an underlying mesh, since the integrity of the chest wall in terms of paradoxical movement post-resection is not an issue. The largest comparative study for prosthetic materials used in chest wall reconstruction that we could identify was performed in the Mayo clinic with 197 patients over a 20-year period and was for PTFE "Gore-Tex" vs prolene mesh, with comparable results for both materials in terms of postoperative complications.^[14]

The STRATOS system of titanium bars is a new modality that has only been described in one case report in the literature, a case of chondrosarcoma of the sternum that was reconstructed with titanium bars and rib clips of this system in combination with a titanium sternal plate and prolene mesh.^[9] As reported, they reconstructed the ribs using the STRATOS system by applying it to the resected margins in a horizontal fashion. However, in our case, we have reconstructed the sternoclavicular junction bilaterally in an X-shaped repair.

Although many surgeons recognize the varying degrees of shoulder weakness and the several incidence of dislocations post-resection of the sternoclavicular joint, there is still no clear consensus as yet, about the exact incidence or magnitude of this problem post-resection of sternal tumors.

Eskola *et al.*^[8] have published 12 cases of sternoclavicular resections in patients with old dislocations comparing those that had simple resection vs resection with a graft fixed to the remaining segment of clavicle either by tendon grafting or placing a fascial loop. He was able to show a wide discrepancy in pain and function of the joint for those who had simple excision in comparison with those who had fixation of the clavicles, and it was well noted by Eskola that this group of patients had to leave their jobs and go on disability pension. Specifically, he was able to show that three of four patients who had resection without reconstruction had less than 50% power of shoulder abduction, and all four had severe limitation of range of motion for internal and external rotation and abduction.

An independent assessor has performed a scoring functional assessment of our patient's shoulder joint function 10 weeks after surgery, and he found that the patient was able to maintain almost complete range of motion in both shoulders by active and passive motion, and strength was largely preserved [Table 1].

In summary, we describe the use of the titanium steel bars in a novel approach to stabilize both medial aspects of the resected clavicles. We believe this therapy to be very promising for cases of manubrial reconstruction and clavicular fixation, and draw the attention to the possible functional benefits of this method of repair.

References

- Mishra A, Mishra SK, Agarwal A, Agarwal G, Agarwal SK. Surgical treatment of sternal metastases from thyroid carcinoma: Report of two cases. *Surg Today* 2001;31:799-802.
- Haraguchi S, Yamashita Y, Yamashita K, Hioki M, Matsumoto K, Shimizu K. Sternal resections for metastasis from thyroid carcinoma and reconstruction with sandwiched marlex and stainless steel mesh. *Jpn J Thor Cardiovasc* 2004;52:4:209-12.
- Meyer A, Behrend M. Partial resection of the sternum for osseous metastasis of differentiated thyroid cancer: Case report. *Anticancer Research* 2005;25:4389-92.
- Eroglu A, Karaoglanoglu N, Bilen H, Gursan N. Follicular thyroid carcinoma: Metastases to the sternum 13 years after total thyroidectomy. *Int J Clin Pract* 2006;60:1506-8.
- Mansour KA, Thourani VH, Losken A, Reeves JG, Miller JI Jr, Carlson GW, *et al.* Chest wall resections and reconstruction: A 25-year experience. *Ann Thorac Surg* 2002;73:1720-6.
- Zettinig G, Feuger BJ, Passler C, Kaserer K, Pirich C, Dudczak R, *et al.* Long term follow-up for patients with bone metastases from differentiated thyroid carcinoma-Surgery or conventional therapy? *Clin Endocrin* 2002;56:377-82.
- Carbognani P, Vagliasindi A, Costa P, Pascarella L, Pazzini L, Bobbio A, *et al.* Surgical treatment of primary and metastatic sternal tumors. *J Cardiovasc Surg* 2001;42:411-4.
- Eskola A, Vainionpaa S, Vastamaki M, Slätis P, Rokkanen P. Operation for old sternoclavicular dislocation: Results in 12 cases. *J Bone Joint Surg Br* 1989;71:63-5.
- Gonfiotti A, Santini PF, Campanacci D, Innocenti M, Ferrarello S, Janni A. Use of moldable titanium bars and rib clips for total

- sternal replacement: A new composite technique. *J Thor Cardiovasc Surg* 2009;138:1248-50.
10. Ozaki O, Kitagawa W, Koshiishi H, Sugino K, Mimura T, Ito K. Thyroid carcinoma metastasized to the sternum: Resection of the sternum and reconstruction with acrylic resin. *J Surg Oncol* 1995;60:282-5.
 11. Muthuphei MN, Mabua MP. Retro-sternal thyroid carcinoma metastatic to the sternum: A case report. *Cent Afr J Med* 1998;44:292-3.
 12. Lequaglie C, Masone PB, Giudice G, Conti B. Gold standard for sternectomies and plastic reconstructions after resections for primary or secondary sternal neoplasms. *Ann Surg Onc* 2002;9:472-9.
 13. Kinoglou C, Vandeweyer E, Lothaire P, Gebhart M, Andry G. Thyroid carcinoma metastasis to the sternum: Resection and reconstruction. *Acta Chir Belg* 2001;101:253-5.
 14. Deschamps C, Tirnaksiz BM, Darbandi R, Trastek VF, Allen MS, Miller DL, *et al.* Early and long-term results of prosthetic chest wall reconstruction. *J Thorac Cardiovasc Surg* 1999;117:588-92.

How to cite this article: Hajjar WM, Alnassar S, Abu-Daff SN, Al-Dhahri SF. A novel technique for the reconstruction of resected sternoclavicular joints: A case report with a review of the literature. *Ann Thorac Med* 2013;8:60-3.

Source of Support: Nil, **Conflict of Interest:** None declared.

New features on the journal's website

Optimized content for mobile and hand-held devices

HTML pages have been optimized of mobile and other hand-held devices (such as iPad, Kindle, iPod) for faster browsing speed.

Click on **[Mobile Full text]** from Table of Contents page.

This is simple HTML version for faster download on mobiles (if viewed on desktop, it will be automatically redirected to full HTML version)

E-Pub for hand-held devices

EPUB is an open e-book standard recommended by The International Digital Publishing Forum which is designed for reflowable content i.e. the text display can be optimized for a particular display device.


Click on **[EPub]** from Table of Contents page.

There are various e-Pub readers such as for Windows: Digital Editions, OS X: Calibre/Bookworm, iPhone/iPod Touch/iPad: Stanza, and Linux: Calibre/Bookworm.

E-Book for desktop

One can also see the entire issue as printed here in a 'flip book' version on desktops.

Links are available from Current Issue as well as Archives pages.

Click on  View as eBook