



All-Arthroscopic Biceps Tenodesis Using the Anterolateral Anchor During Concomitant Double-Row Rotator Cuff Repair

Mitchell Meghpara, M.D., William Schulz, B.S., Elan Golan, M.D., and Dharmesh Vyas, M.D., Ph.D.

Abstract: Arthroscopic biceps tenodesis is a commonly performed procedure; however, there is a paucity of literature regarding concomitant biceps tenodesis and double-row rotator cuff repair. In this Technical Note, we describe an all-arthroscopic biceps tenodesis using the stay sutures from the anterolateral anchor in the setting of a double-row rotator cuff repair. The anterolateral anchor is placed adjacent to the bicipital groove to accommodate the tenodesis. Two sutures loaded into the anterolateral anchor are passed through the long head of the biceps tendon in a cinch configuration without the need to externalize the tendon. The sutures are tied arthroscopically, thereby securing the tendon to the anterolateral row anchor and completing the tenodesis.

Long head of the biceps tendon pathology is commonly encountered in the presence of a rotator cuff tear.¹ Patients with this pathology usually present with pain in the anterior shoulder and tenderness over the bicipital groove. In such cases, either a tenotomy or tenodesis can be performed during rotator cuff repair (RCR).

Many studies looking at the superiority of one technique over the other have shown no significant differences between measures such as American Shoulder and Elbow Surgeons scores postoperatively, pain, and cramping.²⁻⁴ However, the general consensus is that biceps tenodesis does demonstrate some advantages, including restoration of the resting muscle length so as to avoid spasm or cramping, preservation of elbow flexion and supination strength, and avoidance of a

cosmetic deformity or “Popeye Sign,” which can result from a tenotomy.⁵

Multiple techniques for biceps tenodesis have been described, with much variability in the approach and method of fixation employed. The traditional approach to a bicep tenodesis has been described through an open subpectoral or suprapectoral approach⁶; however, arthroscopic techniques also have been described.⁷ Multiple techniques similarly exist for tendon fixation, including a simple suture, an interference screw, a suture anchor, or through a bone tunnel.

In this Technical Note, we present a simple and cost-effective, all-arthroscopic technique for biceps tenodesis in the setting of a double-row RCR. During this technique, when the biceps tendon is mobile and not scarred within the groove, the tenodesis is performed using the stay sutures loaded in the anterolateral anchor of the RCR. This all-arthroscopic technique is technically straightforward, avoids an extra incision, thus decreasing risk of infection and possible neurovascular injury, and decreases both operative time and costs by avoiding the need for a separate implant solely for long head of the biceps tendon fixation.

Technique (With Video Illustration)

The patient is placed in the beach-chair position and a 30° arthroscope is introduced in the standard posterior viewing portal. An anterior portal is established through the rotator interval. A standard diagnostic arthroscopy is then performed. The biceps tendon is

From UPMC Freddie Fu Sports Medicine Center, Pittsburgh, Pennsylvania, U.S.A.

The authors report that they have no conflicts of interest in the authorship and publication of this article. Full ICMJE author disclosure forms are available for this article online, as [supplementary material](#).

Received July 15, 2019; accepted September 2, 2019.

Address correspondence to Mitchell Meghpara, M.D., UPMC Freddie Fu Sports Medicine Center, 3200 South Water St., Pittsburgh, PA 15203. E-mail: mmeghpara@gmail.com

© 2019 by the Arthroscopy Association of North America. Published by Elsevier. This is an open access article under the CC BY-NC-ND license (<http://creativecommons.org/licenses/by-nc-nd/4.0/>).

2212-6287/19898

<https://doi.org/10.1016/j.eats.2019.09.005>

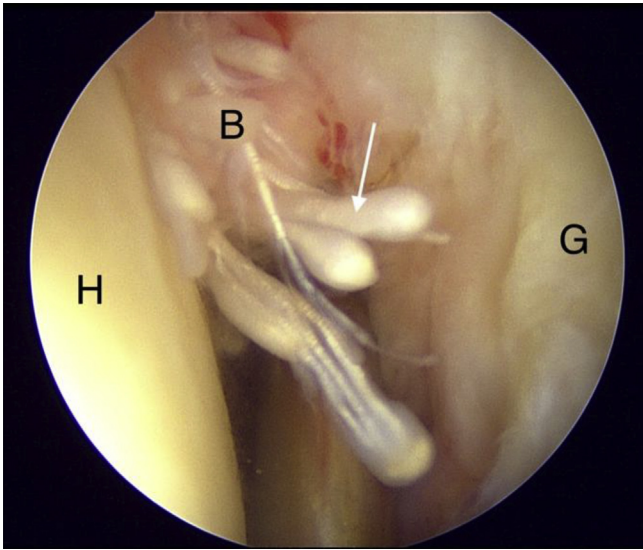


Fig 1. With the patient in the beach chair position, viewing the left shoulder from the posterior portal, pathology to the long head of biceps tendon (white arrow) is seen in the form of a pulley lesion. (B, biceps tendon; G, glenoid; H, humeral head.)

probed, and its integrity and mobility are evaluated. When significant pathology is identified (Fig 1) and a mobile tendon is confirmed, a biceps tenotomy is performed with an arthroscopic scissor and the stump is debrided to a smooth edge (Fig 2).

The arthroscope is then transitioned into the subacromial space. A standard working lateral portal is established. The subacromial and subdeltoid bursa is debrided as required to optimize visualization. If an acromial enthesophyte is encountered, an acromioplasty is performed. At this point, attention is directed toward RCR. The camera is placed through a posterolateral viewing portal for better visualization of the rotator cuff tear. Once the tear is localized, the tendon is mobilized, and the edges are debrided. The tuberosity is prepared with a rasp and motorized burr, allowing for a bleeding edge to accept repair. Our preferred technique for a double-row RCR is a transosseous-equivalent suture bridge repair.

Two medial row 4.75-mm BioComposite SwiveLock C anchors (Arthrex, Naples, FL) are placed through stab incisions localized by a spinal needle. Each anchor is loaded with 2 FiberTapes (Arthrex) and two #2 FiberWires (Arthrex). Two FiberTapes from the anteromedial anchor are placed anteriorly and posteriorly with the intervening segments captured through a horizontal mattress configuration with FiberWire stitches passed within the tendinous portion of the torn rotator cuff tissue. These sutures are then secured with sliding arthroscopic knots to provide additional compression, which acts as a “spot wheld” of the medial most aspect of the RCR. Next, one FiberTape from each medial row anchor is shuttled through another 4.75-mm BioComposite SwiveLock C anchor for a

lateral row repair. The position of the anterolateral anchor is approximately 2 cm lateral to the greater tuberosity and adjacent to the bicipital groove to accommodate for biceps tenodesis (Fig 3). The FiberTapes are tensioned appropriately, and the anchor is seated into the proximal humerus. The additional double-loaded sutures, which are preloaded in the anterolateral anchor, are then secured with a clamp and preserved for later tenodesis. This process is repeated again for the posterolateral anchor for a transosseous-equivalent suture bridge double-row repair.

Following RCR, attention is then afforded towards the biceps tenodesis (Video 1). The arm is positioned in 30° of abduction and 20 to 30° of external rotation. With the arthroscope in the posterolateral portal, a radio-frequency ablation device is placed through the lateral portal. Soft tissues adjacent to the anterolateral row anchor overlying the bicipital groove are debrided and the biceps tendon sheath is incised (Fig 4). The biceps tendon is freed from the groove and secured with a Kelly clamp inserted through the anterior portal to hold the tendon taut within the subacromial space for the remainder of the tenodesis (Fig 5).

With tendon position and tension controlled via manipulation of the Kelly clamp, the position for suture passage through the tendon can be identified to achieve a tension-free tenodesis. The sutures are passed approximately 3 to 4 cm distal on the tenotomized tendon. A limb of one of the #2 FiberWire stay sutures from the anterolateral anchor is then retrieved out the lateral portal and is passed through the tendon in a cinch configuration with a Scorpion self-retrieving suture passer (Arthrex). This is then repeated for the

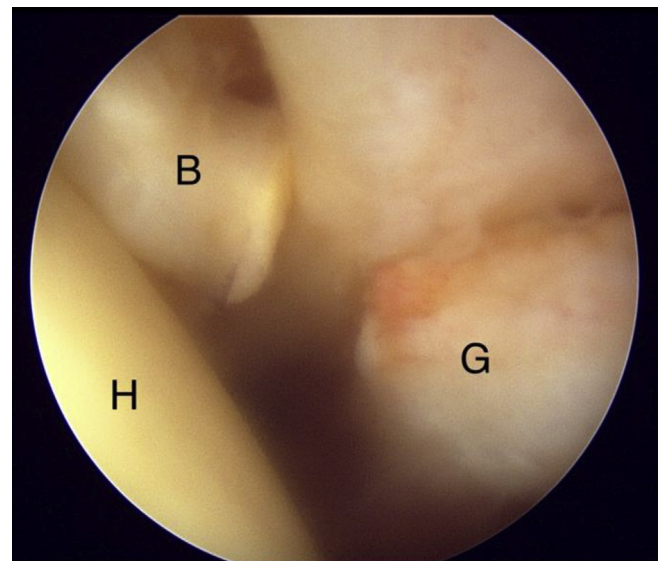


Fig 2. With the patient in the beach chair position, viewing the left shoulder from the posterior portal, the diseased biceps tendon is debrided and released from the supraglenoid tubercle. (B, biceps tendon; G, glenoid; H, humeral head.)

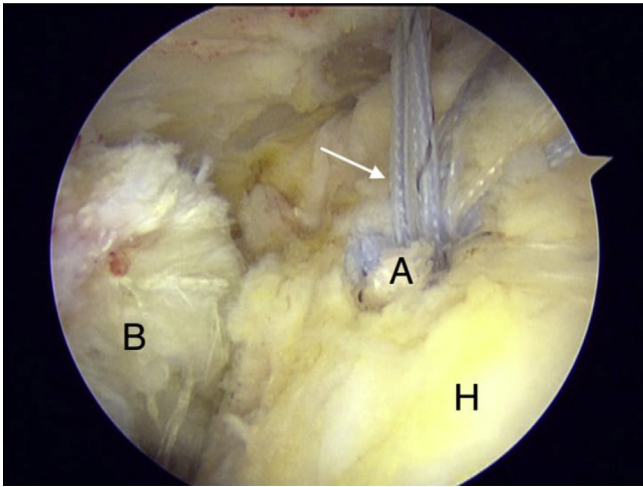


Fig 3. With the patient in the beach chair position, viewing the left shoulder from the posterolateral portal, the anterolateral anchor is positioned adjacent to the biceps groove when placed for the double-row RCR. The anchor is double loaded with 2 stay sutures (white arrow) that are kept in place to be used for later tenodesis. (A, suture anchor; B, biceps tendon; H, humeral head; RCR, rotator cuff repair.)

second suture and placed just distal to the initial suture (Fig 6). Excess tendon proximal to the sutures is cut, with careful attention paid to avoid damaging the sutures. The first set of corresponding sutures are pulled out through the lateral cannula. The limb through the anchor acts as the post and the limb through the tendon serves as the non-post limb. The passed sutures are then tied with alternating half-hitch knots, securing the tendon to the suture anchor and completing the tenodesis (Fig 7).

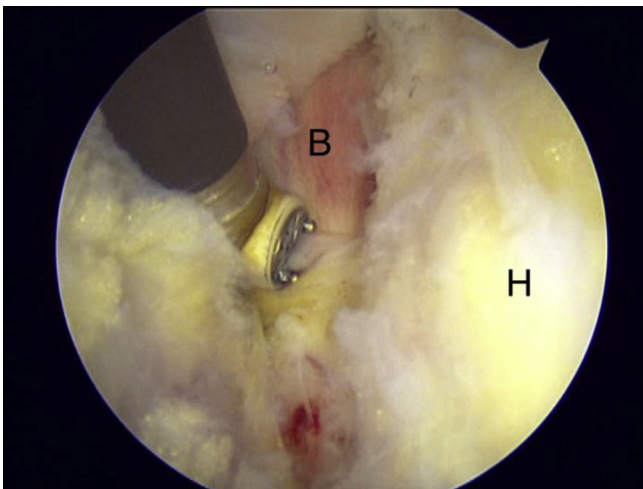


Fig 4. With the patient in the beach chair position, viewing the left shoulder from the posterolateral portal, a radio-frequency ablation device is used to debride soft tissue surrounding the biceps groove as well as the biceps sheath and transverse humeral ligament. (B, biceps tendon; H, humeral head.)

Arthroscopic portals are closed with interrupted 3-0 nylon nonabsorbable suture. The arm is placed in a shoulder abduction sling and kept for 6 weeks after surgery. The patient is encouraged to perform pendulum exercises as well as elbow and wrist range of motion exercises during this time. After 6 weeks, range of motion exercises for the shoulder and active biceps exercises are started. At 12 weeks, strengthening of the rotator cuff and biceps is initiated.

Discussion

In this Technical Note, we present an all-arthroscopic biceps tenodesis using the anterolateral suture anchor of a concomitant double-row RCR. Levy⁸ described a similar technique using the anterolateral row anchor; however, the biceps tendon is externalized from the shoulder to perform a whip stitch prior to fixation. George⁹ described a method that uses a single anchor but incorporates the same suture used for the RCR to perform the tenodesis employing a simple stitch configuration.

The tenodesis technique described herein is unique in that it is all-arthroscopic, avoids externalizing the tendon or increased surgical dissection required with an extra incision, and thereby may minimize the chances of complications (Table 1). Deep infection, brachial plexus injuries, as well as axillary artery injury have all been reported with open tenodesis techniques, which can be minimized through this all-arthroscopic procedure.¹⁰⁻¹² Further, recent studies have demonstrated no difference in outcomes when open and all-arthroscopic methods were compared.^{13,14}

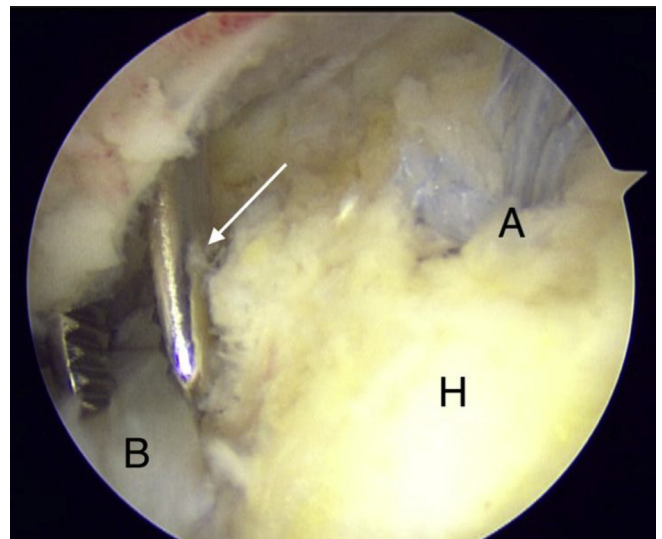


Fig 5. With the patient in the beach chair position, viewing the left shoulder from the posterolateral portal, a Kelly clamp (white arrow) is inserted from the anterior portal and used to manipulate the tendon for the rest of the procedure. (A, suture anchor; B, biceps tendon; H, humeral head.)

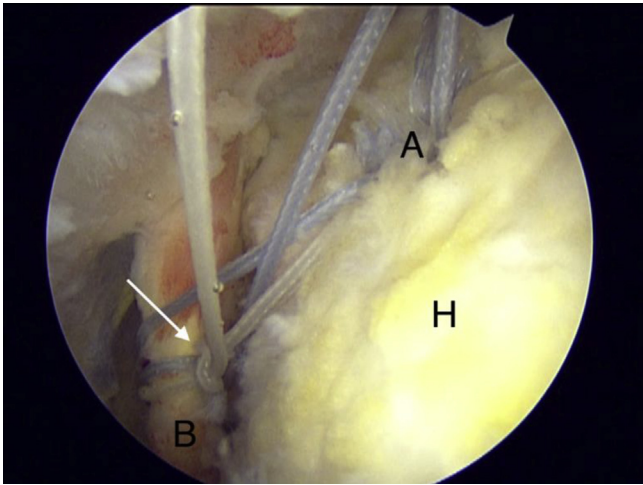


Fig 6. With the patient in the beach chair position, viewing the left shoulder from the posterolateral portal, a self-retrieving suture passing device is used to deliver one limb of the #2 FiberWire stay suture through the tendon in a cinch configuration (white arrow). (A, suture anchor; B, biceps tendon; H, humeral head.)

In addition, this technique avoids an additional implant being inserted into the proximal humerus by using the anterolateral rotator cuff anchor for the tenodesis. Avoidance of other fixation devices decrease the risk of a stress riser and possible fracture reported with other techniques.¹⁵ Moreover, employing an anchor already present with double-row repair provides a cost-effective alternative, which decreases the total number of implants needed for the procedure. In an age in which health care costs are of especial importance, we believe such cost-saving techniques to be of particular value. One way of

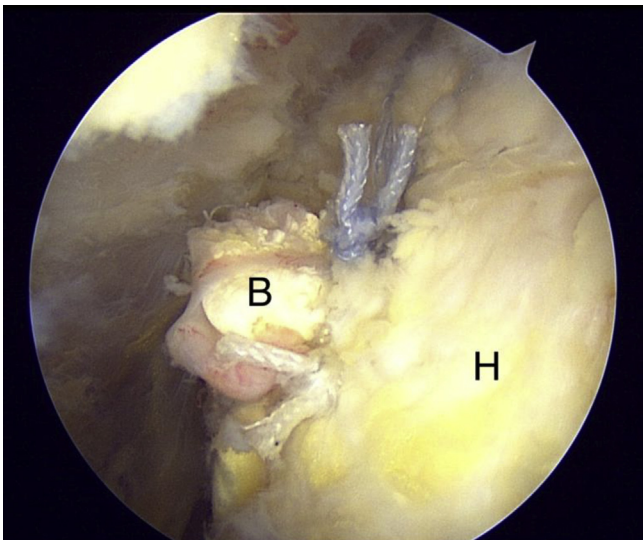


Fig 7. With the patient in the beach chair position, viewing the left shoulder from the posterolateral portal, arthroscopic knots are tied to secure the biceps tendon to the suture anchor. (B, biceps tendon; H, humeral head.)

Table 1. Advantages and Limitations

Advantages	Limitations
<ul style="list-style-type: none"> • Quick and technically simple all-arthroscopic method for biceps tenodesis during double-row RCR • LHBHT does not need to be externalized from shoulder, which can be difficult in patients with excess soft tissue or a large pectoralis major muscle • Avoid morbidity associated with an open incision • Reduced cost as an implant solely for tenodesis is not needed 	<ul style="list-style-type: none"> • Suture anchor fixation may be compromised when tissue quality is poor • Unable to perform if LHBHT is scarred within the groove and immobile • Does not address distal biceps pathology

LHBHT, long head of the biceps tendon; RCR, rotator cuff repair.

doing so is decreasing the number of implants used for a procedure, as a significant correlation between greater total direct cost and total number of anchors used has been shown.¹⁶

Our technique is not without limitations. First, suture anchor fixation may be compromised when tissue quality is poor, as opposed to tissue independent techniques such as interference screw or cortical button fixation. In addition, this procedure cannot be performed if the biceps tendon is scarred within the groove and is unable to be mobilized arthroscopically, thus requiring a familiarity with a second technique. In these instances, we prefer to perform an open suprapectoral tenodesis. Increased arthroscopic time can also lead to increased soft-tissue and compartment swelling and suboptimal viewing conditions if not performed in a timely fashion. Lastly, the suture placement for the tenodesis in our technique is dependent on an

Table 2. Pearls and Pitfalls

Pearls	Pitfalls
<ul style="list-style-type: none"> • Use of a posterolateral viewing portal aids in improved visualization for rotator cuff repair as well as biceps tenodesis • Place arm in 30° of shoulder abduction and 20-30° of external rotation for improved visualization of the bicipital groove from the subacromial space • Use of a self-retrieving suture passer allows for easier suture passage through the LHBHT • If bone quality in the proximal humerus is poor for the lateral row anchor, increase to a 5.5-mm anchor and use smaller punch 	<ul style="list-style-type: none"> • Possible to over- or under-tension the tenodesis if suture placement through the tendon is incorrectly placed • Added arthroscopic time may contribute to increased soft-tissue and compartment swelling, leading to suboptimal visualization

LHBHT, long head of the biceps tendon.

intraoperative assessment of the mobility of the tendon. This can result in over- or undertensioning the tenodesis, leading to altered biomechanics of the arm (Table 2).

In conclusion, we believe the described technique to represent a quick and reproducible method for arthroscopic biceps tenodesis in the setting of double-row RCR. We prefer this technique in the setting of a mobile tendon to avoid the morbidity associated with an open incision and the increased costs of an additional implant.

References

- Mardani-kivi M, Keyhani S, Ebrahim-zadeh MH, Hashemi-motlagh K, Saheb-ekhtiari K. Rotator cuff tear with concomitant long head of biceps tendon (LHBT) degeneration: What is the preferred choice? Open subpectoral versus arthroscopic intraarticular tenodesis. *J Orthop Traumatol* 2019;20:26.
- Castricini R, Familiari F, De gori M, et al. Tenodesis is not superior to tenotomy in the treatment of the long head of biceps tendon lesions. *Knee Surg Sports Traumatol Arthrosc* 2018;26:169-175.
- Gervasi E, Sebastiani E, Cautero E. No-holes transpectoral tenodesis technique tenotomy of the long head of the biceps brachii. *Muscles Ligaments Tendons J* 2016;6:427-432.
- MacDonald PB, McRae S, Stranges GA, et al. Biceps tenodesis versus tenotomy in treatment of lesions of long head of biceps brachii in patients undergoing arthroscopic shoulder surgery. *Orthop J Sports Med* 2017;5(7 suppl 6).
- Hufeland M, Wicke S, Verde PE, Krauspe R, Patzer T. Biceps tenodesis versus tenotomy in isolated LHB lesions: A prospective randomized clinical trial. *Arch Orthop Trauma Surg* 2019;139:961-970.
- Arena C, Dhawan A. Mini-open subpectoral biceps tenodesis using a suture anchor. *Arthroscopy Tech* 2017;6:1625-1631.
- Forsythe B, Zuke WA, Puzitiello RN, Romeo AA. Arthroscopic suprapectoral biceps tenodesis with tenodesis screw. *Arthrosc Tech* 2018;7:e417-e422.
- Levy JC. Simultaneous rotator cuff repair and arthroscopic biceps tenodesis using lateral row anchor. *Arthrosc Tech* 2012;1:e1-e4.
- George MS. Arthroscopic biceps tenodesis incorporated into rotator cuff repair using suture anchors. *Orthopedics* 2008;31:552-555.
- Virk MS, Nicholson GP. Complications of proximal biceps tenotomy and tenodesis. *Clin Sports Med* 2016;35:181-188.
- Rhee PC, Spinner RJ, Bishop AT, Shin AY. Iatrogenic brachial plexus injuries associated with open subpectoral biceps tenodesis: A report of 4 cases. *Am J Sports Med* 2013;41:2048-2053.
- Oflazoglu K, Menendez ME, Ring D, O'Brien TM, Archibald JD. Axillary artery injury associated with subpectoral biceps tenodesis: A case report. *J Shoulder Elbow Surg* 2016;25:e25-e28.
- Forsythe B, Agarwalla A, Puzitiello RN, Mascarenhas R, Werner BC. Rates and risk factors for revision open and arthroscopic proximal biceps tenodesis. *Orthop J Sports Med* 2019;7:2325967118825473.
- Abraham VT, Tan BH, Kumar VP. Systematic review of biceps tenodesis: Arthroscopic versus open. *Arthroscopy* 2016;32:365-371.
- Overmann AL, Colantonio DF, Wheatley BM, Volk WR, Kilcoyne KG, Dickens JF. Incidence and characteristics of humeral shaft fractures after subpectoral biceps tenodesis. *Orthop J Sports Med* 2019;7:2325967119833420.
- Chalmers PN, Granger E, Nelson R, Yoo M, Tashjian RZ. Factors affecting cost, outcomes, and tendon healing after arthroscopic rotator cuff repair. *Arthroscopy* 2018;34:1393-1400.