



Contents lists available at ScienceDirect

International Journal of Surgery Case Reports

journal homepage: www.casereports.com

Laparoscopic resection of recurrent ectopic hepatocellular carcinoma: A case report with review of the literature and guidelines for follow-up



Arne Marino Aarås^a, Truls André Reitan-Gjersøe^{a,*}, Anne Waage^b, Tom Mala^c, Bjørn Edwin^{a,b,d}, Else Marit Løberg^e, Andreas Abildgaard^f, Bård Ingvald Røsok^b

^a Institute of Clinical Medicine, Faculty of Medicine, University of Oslo, Oslo, Norway

^b Department of Hepato-Pancreato-Biliary Surgery, Oslo University Hospital, Sognsvannsveien 20, 0372 Oslo, Norway

^c Department of Gastrointestinal Surgery, Oslo University Hospital, Kirkeveien 166, 0450 Oslo, Norway

^d The Interventional Centre, Oslo University Hospital, Sognsvannsveien 20, 0372 Oslo, Norway

^e Department of Pathology, Oslo University Hospital, Kirkeveien 166, 0450 Oslo, Norway

^f Department of Radiology and Nuclear Medicine, Oslo University Hospital, Sognsvannsveien 20, 0372 Oslo, Norway

ARTICLE INFO

Article history:

Received 17 September 2015

Received in revised form 6 October 2015

Accepted 13 October 2015

Available online 28 October 2015

Keywords:

Ectopic
Hepatocellular
Carcinoma
Laparoscopic
Resection
Follow-up

ABSTRACT

INTRODUCTION: Hepatocellular carcinoma (HCC) in ectopic liver tissue is extremely rare.

PRESENTATION OF CASE: A 64-year-old woman presented initially with abdominal complaints. Computed tomography (CT) revealed a tumor in the diaphragm and laparoscopic resection of the tumor was performed. Histology showed HCC. During the next 4 years four more tumors, all of which showed HCC on histology and were located extrahepatically, was treated with laparoscopic resection. During this course the patient was followed with regular thoracoabdominal CT and measurement of serum alpha-fetoprotein (AFP). A negative magnetic resonance imaging (MRI) examination of the liver excluded a primary intrahepatic tumor.

DISCUSSION: The literature available on ectopic HCC and the guidelines for management of HCC do not address the postoperative surveillance of patients undergoing curative treatment. A follow-up regime has been proposed by Hatzaras et al. (2014) to include cross-sectional imaging of the liver and measurement of serum AFP levels [1]. CT would be the preferred study of choice in a total radiologic investigation of the abdomen. While MRI is prone to artifacts due to movements, CT scans allows so rapid recordings that this no longer is an issue. An early investigation of the liver for intrahepatic HCC should nevertheless be performed early to exclude primary intrahepatic HCC.

CONCLUSION: We recommend that patients with ectopic HCC should be followed every 6 months with measurement of AFP and abdominal CT imaging. MRI of the liver should be performed early to exclude primary intrahepatic HCC.

© 2015 The Authors. Published by Elsevier Ltd. on behalf of IJS Publishing Group Ltd. This is an open access article under the CC BY-NC-ND license (<http://creativecommons.org/licenses/by-nc-nd/4.0/>).

1. Introduction

Ectopic liver tissue derives from a developmental anomaly due to aberrant hepatic tissue migration [2], and is incidentally encountered by laparoscopy, laparotomy or autopsy. The prevalence of extrahepatic liver tissue is reported between 0.24 and 0.47% [3,4]. Hepatocellular carcinoma (HCC) in ectopic liver tissue is extremely rare. Including our patient, a total of 60 cases have been reported [5]. Ectopic liver tissue seems to be prone to development of HCC and various theories have been made to explain the development of HCC in ectopic liver tissue [2,6,7]. The presentation of an ectopic

HCC varies from acute abdominal crisis caused by rupture of the tumor to incidental finding on routine medical investigations. Surgical resection is the preferred treatment and may be curative. Laparoscopic resection has been reported with successful outcome [5,8]. Postoperative follow-up for potential recurrence of ectopic HCC has not been established and reported follow-up programs vary.

We present a patient with recurrent ectopic HCC handled by repeated laparoscopic resections. We also make recommendations for postoperative surveillance based on guidelines for follow-up after resection of intrahepatic HCC and a review of the literature.

* Corresponding author.

E-mail address: trulsagjersoe@gmail.com (T.A. Reitan-Gjersøe).

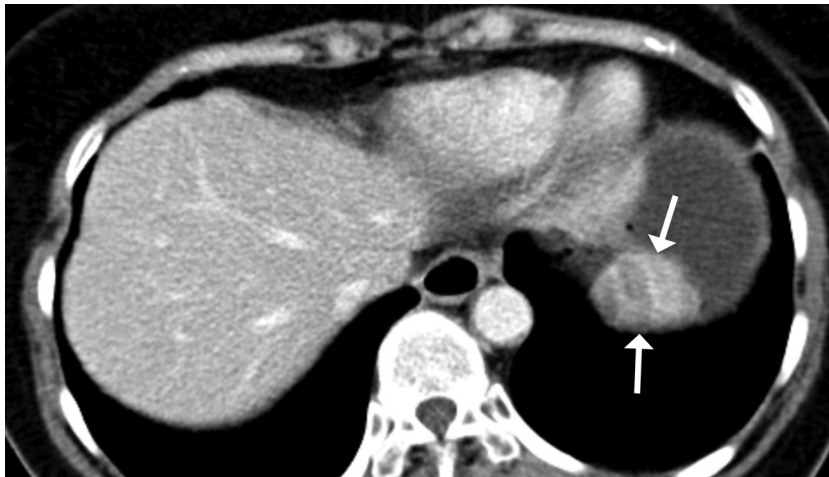


Fig. 1. Preoperative CT image of the first tumour. Axial view.

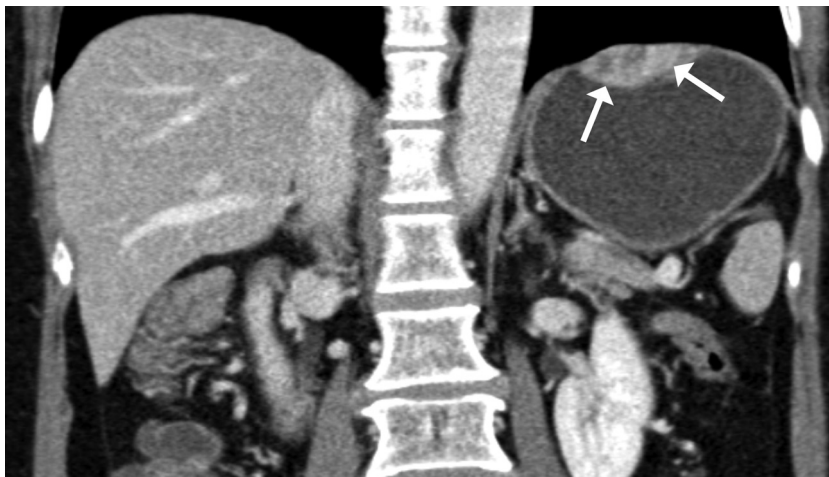


Fig. 2. Preoperative CT image of the first tumour. Coronal view.

1.1. Presentation of case

A 64-year-old Asian woman with no history of previous hepatic disease presented with atypical abdominal complaints. Abdominal computed tomography (CT) revealed a tumor in the upper left abdominal quadrant (Figs. 1 and 2). The tumor was initially thought to originate from the gastric fundus, but following gastroscopy compression from a tumor located outside the stomach was suspected. Serum alpha-fetoprotein (AFP) was 200 ng/ml. Laparoscopic resection of a 35 × 25 × 10 mm tumor located in the diaphragm was performed. Although macroscopically radically resected, microscopy revealed tumor tissue in the resection margins. It was histologically concluded that the patient had HCC originating from ectopic liver tissue. CT showed no liver pathology.

The postoperative period was uneventful. Two weeks later the patient was examined with magnetic resonance imaging (MRI) of the liver and a contrast enhanced ultrasound (US) without findings of malignancy. Three weeks later the patient tested positive for Hepatitis A and B virus antibodies, while Hepatitis C and HIV antibodies were negative. The Hepatitis B virus antigen was negative. She then underwent a positron emission tomography (PET)-CT and there were no signs of viable tumor tissue. Control CT scans at 3, 9, 14 and 22 months postoperative were all negative and the AFP remained in the normal area.

At 2 years her AFP levels had increased to 45 ng/ml and four months later the AFP was 72 ng/ml. A CT scan did not show evidence of liver pathology, but a 1 cm lymph node on the right side of the abdomen near the falciform ligament was detected. The lymph node showed contrast enhancement in the arterial phase. A repeat MRI showed no sign of intracellular tumor uptake of the hepatocyte-specific contrast medium gadolinium ethoxybenzyl diethylenetriamine pentaacetic acid (Gd-EOB-DTPA) (Primovist, Bayer healthcare). US guided fine needle aspiration cytology (FNAC) of the extrahepatic lesion showed HCC cells.

Laparoscopic resection of the lymph node was made 30 months after the initial resection. Preoperative AFP was 58 ng/ml. On gross laparoscopic evaluation, the liver appeared normal with no signs of cirrhosis or focal lesions. No other lesions were observed in the peritoneal cavity. In the falciform ligament, in close proximity to the round ligament of the liver, an umbilication of the ligament could be seen. The lesion was resected, with macroscopically free margins, and frozen sections of the lesion confirmed the presence of HCC.

Postoperatively the AFP level remained elevated at 47 ng/ml, but CT 4 months later was without pathology. Repeat thoracoabdominal CT scan 8 months after the second operation, revealed two new lesions in relation to the pylorus/duodenum suspicious of recurrent disease. The diameters of the suspected lymph nodes were 10 mm and 4 mm, respectively. The AFP level had increased to 161 ng/ml.

Table 1
Combinations of surveillance test used in case reports of ectopic HCC.

| Authors | Year | Journal | CT | AFP | US | MRI |
|---------------------|------|---|------------------|------------------|----------------|-----|
| Takayasu K. et al. | 1994 | <i>Clin. Radiol.</i> | | | X | |
| Asselah T. et al. | 2001 | <i>Eur. J. Gastroenterol. Hepatol.</i> | X | | X | X |
| Iwase K. et al. | 2001 | <i>J. Hepatobiliary Pancreat. Surg.</i> | X | X | | |
| Kim K.A. et al. | 2003 | <i>Eur. Radiol.</i> | X | | | |
| Leone N. et al. | 2004 | <i>Eur. J. Gastroenterol. Hepatol.</i> | X ^{a,b} | X ^{a,b} | X ^b | |
| Shigemori M. et al. | 2006 | <i>J. Gastroenterol.</i> | X | X | | |
| Huang T.W. et al. | 2007 | <i>Dig. Dis. Sci.</i> | X | | X | |
| Steen S. et al. | 2013 | <i>Clin. Case Rep.</i> | | X | | X |
| Soofi Y. et al. | 2014 | <i>Diagn. Cytopathol.</i> | X | X | | |
| Oldani A. et al. | 2014 | <i>Ann. Ital. Chir.</i> | X | X | | |
| Total | | | 10 | 7 | 4 | 2 |

CT = Computed tomography, AFP = Alpha-fetoprotein, US = Ultrasonography, MRI = Magnetic resonance imaging.

^a Refers to case 1.

^b Refers to case 2.

The patient underwent a third laparoscopic resection of the two lesions 1 month later. At surgery, the first lesion was located in relation to the duodenal wall, immediately distal to the pylorus. The lesion was partly necrotic and was meticulously dissected out and removed. The second lesion at the descending part of the duodenum was easily removed. Histology of the 2 lesions both showed HCC. On a subsequent thoracoabdominal CT 8 months after the third operation, a new lesion was detected in relation to the middle colic artery. MRI examination with Gd-EOB-DTPA did not show signs of intracellular contrast uptake in the tumor. A fourth laparoscopic resection was performed again of a topical extrahepatic HCC confirmed by histology. Upon further follow-up, she is now without any signs of disease almost four years after the initial resection.

2. Discussion

Laparoscopic resection of intrahepatic HCC may have short-term advantages compared to open surgery in blood loss and post-operative morbidity, but similar long-term outcome [9]. A recent meta-analysis by Xiong et al. concluded that laparoscopic resection of intrahepatic HCC is a feasible and safe treatment [10]. Ectopic HCCs are generally well-defined anatomical structures. This fact makes them amenable to laparoscopic curative resection [8]. The laparoscopic approach may facilitate repeated resections. In our patient the presence of minimal postoperative adhesions allowed easy access to the recurrences during all three repeated procedures.

Available literature brings little evidence in regard to postoperative follow-up following resection of ectopic HCC. In the total of 30 case reports since 1990, only ten case reports indicate the tests applied for surveillance (Table 1). For example Leone et al. describe two cases that are followed up differently: the first one with CT and AFP and the second one with US, CT and AFP [7]. Table 1 also demonstrates the great variation in the combination of tests used for postoperative surveillance of ectopic HCC.

We will in the following paragraphs present a rationale for optimal postoperative surveillance and control of patients with ectopic HCC. This is based on the knowledge of the nature of HCC in intrahepatic liver tissue and the deduced practical clinical guidelines for management of intrahepatic HCC that we have reviewed.

We reviewed the clinical practical guidelines of the Asian-Pacific Association for the Study of the Liver [11], the American Association for the Study of the Liver Diseases [12] and the European association for the study of the liver [13] with focus on surveillance. These guidelines are based on screening of patients with chronic liver disease and not on patients that underwent intended curative treatment for HCC. Surveillance frequency and the test methods of choices are the same in the three guidelines, and consist of US of

the liver and AFP measurement every 6 months. The European and American guidelines consider an AFP concentration ≥ 200 ng/ml diagnostic for HCC.

US, CT and MRI are all applied in the surveillance of intrahepatic HCC. The benefits of US is wide availability, low cost and lack of ionizing radiation [14]. The drawbacks for using US is a very variable sensitivity for detecting HCC, with a low sensitivity for lesions less than 1–2 cm. CT is the most frequently used imaging technique to evaluate patients with HCC and to survey for recurrent HCC. It has improved sensitivity compared to US (69 vs. 60%), high specificity (93%) and wide availability, and is also the preferred method for description of anatomic relationship between the tumor and vascular structures. The main disadvantages are accumulated radiation exposure and potential nephrotoxicity of the contrast agents. Contrast-enhanced MRI is probably the most sensitive imaging modality for detection of HCC, in particular for detection of intrahepatic disease [1]. A recent study found gadoxetic acid-enhanced MRI superior to multidetector CT (MDCT) in diagnostic accuracy and detection of intrahepatic recurrent HCC [15]. Another advantage of MRI is lack of radiation exposure. Disadvantages are cost, availability, suboptimal description of vascular structures and that it requires a high degree of patient cooperation [1]. An important annotation is that these findings apply to detection of intrahepatic HCC. CT being the preferred study of choice in a total radiologic investigation of the abdomen is generally accepted in the field of radiology. While MRI is prone to artifacts due to peristalsis and other types of movements, a CT scan now allows so rapid recordings that this no longer is an issue. Furthermore CT imaging allows better geometrical reconstruction of the intraabdominal structures than MRI. An early investigation with MRI of the liver for intrahepatic HCC should nevertheless be performed to exclude primary intrahepatic HCC.

The guidelines for management of HCC do not address the post-operative surveillance of patients undergoing curative treatment of HCC. A recent review article by Hatzaras et al. recommends surveillance with follow-up every 3–4 months the first 3 years. After 3 years, surveillance should be undertaken every 6–12 months. They recommend the surveillance to include cross-sectional imaging of the liver and measurement of serum AFP levels [1].

3. Conclusion

Ectopic HCC is a rare condition. In our patient repeated laparoscopic resections were feasible for HCC recurrences at varying intraabdominal locations. We recommend that patients with ectopic HCC should be followed every 6 months with measurement of AFP and abdominal CT imaging. MRI of the liver should also be made initially to exclude primary intrahepatic HCC.

Conflict of interest

None.

Funding

None.

Ethical approval

None.

Consent

Written informed consent was obtained from the patient for publication of this case report and accompanying images.

Author contribution

Arne Marino Aarås: First author. Literature review. Preparing and writing the paper.

Truls André Reitan-Gjersøe: First author. Literature review. Preparing and writing the paper.

Anne Waage: Data acquisition.

Tom Mala: Data acquisition. Revising the article.

Bjørn Edwin: Data acquisition.

Else Marit Løberg: Data acquisition.

Andreas Abildsgaard: Data acquisition. Revising the article.

Bård Ingvald Røsok: Supervising the first authors. Preparing and revising the paper.

Guarantor

Arne Marino Aarås and Truls André Reitan-Gjersøe.

References

- [1] I. Hatzaras, D.A. Bischof, B. Fahy, D. Cosgrove, T.M. Pawlik, Treatment options and surveillance strategies after therapy for hepatocellular carcinoma, *Ann. Surg. Oncol.* 21 (2014) 758–766.
- [2] C.P. Caygill, P.A. Gatenby, Ectopic liver and hepatocarcinogenesis, *Eur. J. Gastroenterol. Hepatol.* 16 (2004) 727–729.
- [3] P. Eiserth, Beiträge zur Kenntnis der Nebenlebern, *Virchows Arch. Pathol. Anat. Physiol. Klin. Med.* 307 (1941) 307–313.
- [4] M. Watanabe, T. Matsura, Y. Takatori, K. Ueki, T. Kobatake, M. Hidaka, et al., Five cases of ectopic liver and a case of accessory lobe of the liver, *Endoscopy* 21 (1989) 39–42.
- [5] R. Kanzaki, T. Yamada, K. Gotoh, H. Takahashi, H. Ohigashi, O. Ishikawa, Ectopic hepatocellular carcinoma arising in the left triangular ligament of the liver, *Case Rep. Gastroenterol.* 4 (2010) 138–143.
- [6] M. Arakawa, Y. Kimura, K. Sakata, Y. Kubo, T. Fukushima, K. Okuda, Propensity of ectopic liver to hepatocarcinogenesis: case reports and a review of the literature, *Hepatology* 29 (1999) 57–61.
- [7] N. Leone, P. De Paolis, M. Carrera, P. Carucci, A. Musso, E. David, et al., Ectopic liver and hepatocarcinogenesis: report of three cases with four years' follow-up, *Eur. J. Gastroenterol. Hepatol.* 16 (2004) 731–735.
- [8] U.H. Seo, H.J. Lee, W.S. Ryu, J.M. Kwak, B.K. Shin, W.B. Kim, et al., Laparoscopic resection of a hepatocellular carcinoma arising from an ectopic liver, *Surg. Laparosc. Endosc. Percutan. Tech.* 18 (2008) 508–510.
- [9] Z. Yin, X. Fan, H. Ye, D. Yin, J. Wang, Short- and long-term outcomes after laparoscopic and open hepatectomy for hepatocellular carcinoma: a global systematic review and meta-analysis, *Ann. Surg. Oncol.* 20 (2013) 1203–1215.
- [10] J.J. Xiong, K. Altaf, M.A. Javed, W. Huang, R. Mukherjee, G. Mai, et al., Meta-analysis of laparoscopic vs open liver resection for hepatocellular carcinoma, *World J. Gastroenterol.* 18 (2012) 6657–6668.
- [11] M. Omata, L.A. Lesmana, R. Tateishi, P.J. Chen, S.M. Lin, H. Yoshida, et al., Asian Pacific association for the study of the liver consensus recommendations on hepatocellular carcinoma, *Hepatol. Int.* 4 (2010) 439–474.
- [12] J. Bruix, M. Sherman, Practice guidelines committee AaFtSoLD. Management of hepatocellular carcinoma, *Hepatology* 42 (2005) 1208–1236.
- [13] J.M. Llovet, M. Ducreux, et al., European Association for the Study of the Liver and European Organisation for Research and Treatment of Cancer, EASL-EORTC clinical practice guidelines: management of hepatocellular carcinoma, *J. Hepatol.* 56 (2012) 908–943.
- [14] H. Arif-Tiwari, B. Kalb, S. Chundru, P. Sharma, J. Costello, R.W. Guessner, et al., MRI of hepatocellular carcinoma: an update of current practices, *Diagn. Interv. Radiol.* 20 (2014) 209–221.
- [15] K.A. Kim, M.J. Kim, J.Y. Choi, M.S. Park, J.S. Lim, Y.E. Chung, et al., Detection of recurrent hepatocellular carcinoma on post-operative surveillance: comparison of MDCT and gadoteric acid-enhanced MRI, *Abdom. Imaging* 39 (2014) 291–299.

Open Access

This article is published Open Access at scimedirect.com. It is distributed under the [IJSCR Supplemental terms and conditions](#), which permits unrestricted non commercial use, distribution, and reproduction in any medium, provided the original authors and source are credited.