

# Early anti IL-1 treatment replaces steroids in refractory Kawasaki disease: clinical experience from two case reports

Maria Vincenza Mastrolia<sup>ID</sup>, Giulia Abbati, Claudia Signorino, Iliaria Maccora, Edoardo Marrani, Iliaria Pagnini and Gabriele Simonini<sup>ID</sup>

*Ther Adv Musculoskel Dis*

2021, Vol. 13: 1–7

DOI: 10.1177/  
1759720X211002593

© The Author(s), 2021.  
Article reuse guidelines:  
sagepub.com/journals-  
permissions

**Abstract:** Refractory Kawasaki disease (KD) is related to a major risk of coronary arteries abnormalities and its treatment is not standardized. In this regard, anakinra (ANA), an interleukin (IL)-1 receptor antagonist, represents an emerging therapeutic option. We report two cases of children, diagnosed with KD, nonresponsive to two doses of intravenous immunoglobulins, successfully treated with ANA, without a prior use of steroids. Patient 2 developed a coronary dilatation, that improved significantly after ANA therapy. Our experience highlights IL-1 blockade effectiveness in reducing KD inflammation and suggests ANA adoption as second-line therapy, with a timesaving and steroid-sparing strategy. Our results, combined with the evidence of the IL-1 key role in KD and coronary arteritis pathogenesis and to the recent clinical evidence reported by the KAWAKINRA trial, encourage an earlier recourse to ANA in patients with refractory KD, in order to fight inflammation, and to treat and prevent the development of coronary artery aneurysms. Further studies are needed to better define the place of IL-1 blockade in KD step-up treatment.

**Keywords:** anakinra, coronary artery aneurysms, interleukin 1, Kawasaki disease

Received: 5 January 2021; revised manuscript accepted: 23 February 2021.

## Introduction

Kawasaki disease (KD) is an acute inflammatory vasculitis of the medium and small-sized arteries, generally occurring in children under 5 years of age. It is associated with the development of coronary artery aneurysms (CAAs) or ecstasies. The cardiac involvement is the main determinant of the long-term prognosis of patients with KD, as coronary lesions may lead to ischemic heart disease and even sudden death.<sup>1</sup>

The first-line treatment, a single infusion of 2 g/kg intravenous immunoglobulin (IVIg) along with aspirin, reduces CAA frequency from 25–30% to about 5%.<sup>2,3</sup> However, 10–20% of patients with KD are resistant to standard treatment, thus leading to a major risk of cardiac complications.<sup>2,4</sup> Therefore, the management of refractory KD still represents a challenge for clinicians.

Interleukin (IL)-1 plays a key role in KD physiopathology and in CAA development. This pathogenetic observation leads to the therapeutic implication of the potential use of IL-1 blockade in the treatment of refractory KD,<sup>5,6</sup> as potential rescue treatment after steroid treatment, traditionally representing the most recommended second-line approach in these patients.<sup>2,7</sup> However, the possibility that anti-IL-1 strategy may subside steroid treatment has been advocated.<sup>1,6</sup>

At this regard, we report two cases of KD resistant to IVIg, successfully treated with anakinra (ANA), without receiving a previous steroid course.

## Patient 1

A 4-year-old Hispanic boy presented to our emergency department with a chief complaint of fever

Correspondence to:  
**Gabriele Simonini**  
NEUROFARBA  
Department, University of  
Florence, Rheumatology  
Unit, Meyer Children's  
University Hospital,  
Florence, Viale Gaetano  
Pieraccini, 24, Firenze,  
50139, Italy  
[gabriele.simonini@unifi.it](mailto:gabriele.simonini@unifi.it)

**Giulia Abbati**  
**Claudia Signorino**  
Pediatric Residency, Meyer  
Children's University  
Hospital, University of  
Florence, Firenze, Italy

**Iliaria Maccora**  
**Edoardo Marrani**  
**Iliaria Pagnini**  
**Maria Vincenza Mastrolia**  
Rheumatology Unit, Meyer  
Children's University  
Hospital, Firenze, Italy



for 5 days, maculopapular rash, nonpurulent conjunctivitis, mucositis, slight swelling of the hands and feet and submandibular lymphadenopathy. Blood tests showed neutrophilic leucocytosis ( $21,360/\text{mm}^3$ , neutrophils 77%) and high level of C-reactive protein [(CRP) 12.0 mg/dl], erythrocyte sedimentation rate [(ESR) 54 mm/h] and alanine aminotransferase [(ALT) 153 U/l]. Infectious investigations, including SARS-CoV-2 on nasal swab and serology test, resulted negative. The urinalysis was positive for pyuria. Abdomen ultrasound reported nonlithiasic gallbladder distension. According to the American Heart Association, he fulfilled the criteria of complete KD. Echocardiography was then performed, documenting normal diameter and echogenicity of the coronary vessels, ruling out the presence of coronary lesions. At the fifth day of fever, 2 g/kg IVIg was administered in association with high-dose aspirin. Due to the failure of the first IVIg dose, a second one was given after 36 h achieving apyrexia. At 3 days later, fever recurred, and blood exams confirmed the persistence of elevated inflammatory markers, albeit a new cardiac evaluation again ruled out the presence of coronary lesions. Hence, ANA was started at a dosage of 4 mg/kg/day subcutaneously. After a few hours, the fever disappeared and CRP reached normal values in 2 days. The patient was discharged without any complication after 9 days of treatment. ANA was discontinued after 4 weeks following stable evidence of normal laboratory and cardiologic findings at last follow-up.

#### Patient 2

A 1-year-old White boy was admitted to a secondary hospital with 4 days fever, macular rash, cheilitis and pharyngitis. Blood tests evidenced high values of CRP (12.8 mg/dl), ALT (233 U/l) and aspartate aminotransferase (AST 136 U/l). The patient was negative for SARS-CoV-2 on nasal swab and serological test. During the hospitalization, he developed latero-cervical lymphadenopathy and conjunctivitis, leading to a diagnosis of complete KD. Echocardiography revealed diffuse wall hyper-echogenicity and ectasia of the coronary vessels, particularly of the left anterior descending (LAD) artery (2.6 mm,  $z$  score 3) [Figure 1(a)]. A first IVIg dose (2 g/kg) together with high-dose aspirin reported a prompt remission of symptoms. The recurrence of fever after 2 days required a second IVIg dose. Due to persistence of fever, high inflammatory markers and

coronary involvement progression, the child was taken to our tertiary hospital after 11 days from disease onset and ANA was started at 4 mg/kg/day subcutaneously. A rapid improvement of coronary wall hyper-echogenicity and a significant decrease of CRP was observed. Serial cardiologic evaluations showed a progressive reduction of ectasia (LAD 2.4 mm,  $z$  score 2.6) and inflammatory markers restored to normal values at discharge. At 4 weeks after starting therapy, a normal diameter of coronary arteries with a minimal residual ectasia of the LAD (2.2 mm,  $z$  score 2.3) in absence of wall hyper-echogenicity allowed ANA suspension [Figure 1(b)].

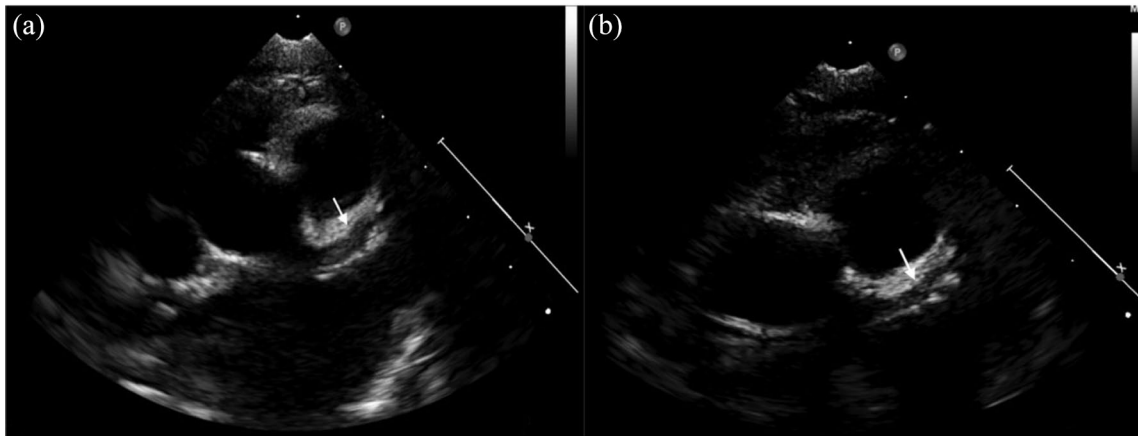
#### Discussion

Current evidence about refractory KD management is not standardized and different treatment options have been proposed, including corticosteroids, cyclosporine, methotrexate, cyclophosphamide, antitumour necrosis factor- $\alpha$  and anti-IL-1 drugs.<sup>5</sup>

IL-1 mediates local and systemic inflammation and plays a key role in rheumatic and autoinflammatory diseases pathogenesis.<sup>3</sup> In terms of KD, IL-1 promotes antigen-driven CD8<sup>+</sup> T cell differentiation, proliferation and tissue migration with possible infiltration of coronary artery walls, induces proliferation of smooth muscle cells and myofibroblasts, prolongs neutrophil survival and induces matrix enzymes, including metalloproteinases, thus contributing to the destructive process leading to aneurysm development.<sup>8,9</sup>

In a *Lactobacillus casei* cell wall extract-induced mouse vasculitis model, the administration of an IL-1 antagonist was able to prevent aortic aneurysms and to improve cardiac ejection fraction by controlling myocarditis, suggesting that its early use might better prevent or treat coronary lesions.<sup>10,11</sup>

An abundance of IL-1 $\alpha$ - and  $\beta$ -related transcripts has been described in KD blood samples and compared with pediatric subjects with different acute infectious diseases and with healthy controls.<sup>12</sup> In addition, IL-1 polymorphisms could be related to IVIg response or resistance and IVIg-resistant patients with KD have reported a decreased expression of IL-1 receptor antagonist.<sup>13</sup> Therefore, IL-1 blockade represents an interesting target for its strong role in the pathogenesis of KD and CAAs.<sup>6</sup>



**Figure 1.** Echocardiographic images of coronary arteries in patient 2. (a) Left coronary artery ectasia, in particular of the LAD artery, before anakinra therapy (z score 3). (b) The improvement of LAD dilatation after 28 days of anakinra therapy (z score 2.3). LAD, left anterior descending.

ANA, the recombinant IL-1 receptor antagonist blocking both IL-1 $\alpha$  and IL-1 $\beta$ , was the first anti-IL-1 agent employed in clinical practice. Since blood levels significantly drop within few hours after discontinuation, it became a manageable drug with a remarkable safety profile.

Few previous studies reported the use of ANA in refractory KD cases (Table 1). In most patients, it has been used as rescue therapy subsequently to the failure of multiple therapeutic strategies.<sup>14-21</sup> ANA administration was preceded or associated to further IVIg doses,<sup>18</sup> methylprednisolone pulses,<sup>14,15,18,19,21</sup> infliximab<sup>15,20</sup> and cyclophosphamide.<sup>21</sup> ANA appeared to be effective in obtaining prompt defervescence and significant reduction of inflammatory markers.<sup>14-16,18-23</sup> Furthermore, ANA treatment showed a total or partial improvement in most patients with KD who developed coronary complications, although the effects on coronary dilations were heterogeneous.<sup>15,18,19</sup>

The open-label phase IIA clinical trial KAWAKINRA, recently appeared, enrolled 16 patients with KD (12 of 16 showing coronary involvement) unresponsive to one or more IVIg infusions to receive ANA by subcutaneous daily injections without a prior use of steroids or immunosuppressants.<sup>25</sup> However, only 8 children were afterwards included in the per-protocol population and 5 of 16 patients received corticosteroids after ANA use and after the primary timepoint at day 3. ANA treatment was started within 14 days after fever onset and it was administered at the starting dose of 2 mg/kg, with possible increase to

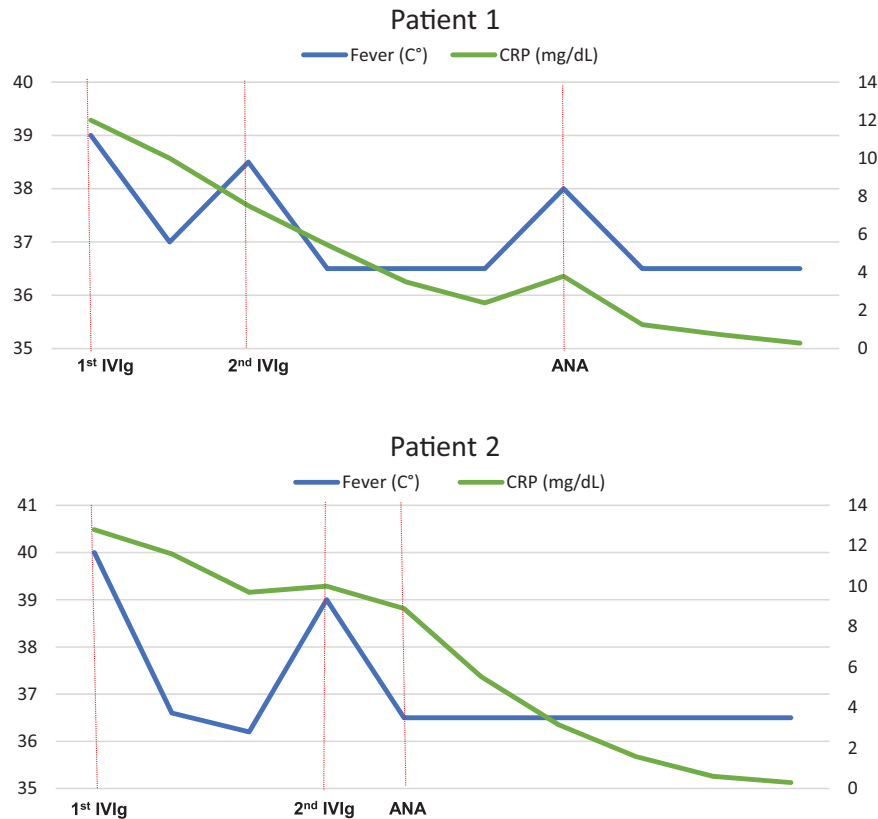
4 mg/kg/dose up to a maximum of 6 mg/kg/dose in case of persistent or recrudescing fever; for patients <10 kg and <8 months an incremental dosage of 4, 6 and 8 mg/kg/dose was scheduled. Daily ANA treatment was continued for a maximum of 15 days and the median duration of treatment was 15 days (10 patients).<sup>25</sup> ANA resulted effective in controlling fever and disease activity and reduced inflammatory markers, indeed 87.5% of patients in the per-protocol group became afebrile within 48 h, a reduction of disease activity by 50% was reached by 93.3% of children with KD of physician's evaluations and by 100% of parent's evaluations and CRP values were normalized at day 30 from disease onset (13 of 16). In addition, ANA seems effective in both treating and preventing coronary involvement, since 10 patients (62.5%) evidenced a coronary z score >2.5 at the initial screening visit with decreased <2.5 in 5 patients (31%) at the end of therapy.<sup>25</sup> It also showed good safety and tolerability profiles with primarily reported nonserious adverse events and no opportunistic infections.<sup>25</sup>

In our two patients with refractory KD, ANA was adopted as second-line option after two IVIg doses and it was not preceded or followed by administration of steroids or further immunosuppressive drugs. Differently from the KAWAKINRA study, a nonincremental dosage was adopted, and ANA was administered subcutaneously at the daily dose of 4 mg/kg; the drug was started 10 and 11 days after KD onset respectively, similarly to KAWAKINRA study patients (range 5–12 days), but earlier if compared to the variable interval

Table 1. Previous studies reporting use of ANA in refractory KD.

	Type of study (no. patients)	No. patients treated with ANA	ANA dosage	Previous treatments	Coronary artery ectasia/aneurysm	Days from KD onset to ANA start	Response	Adverse events	Follow-up (days)
Cohen <i>et al.</i> <sup>14</sup>	Case report (1)	1	1 mg/kg/die	2 IVig doses, multiple methylprednisolone pulses (30 mg/kg/dose)	Yes	18	Remission of fever and normalization of giant CAAs	NA	180
Shaffer <i>et al.</i> <sup>15</sup>	Case report (1)	1	6 mg/kg/day for 3 days, then 9 mg/kg/day	2 IVig doses, 3 methylprednisolone pulses (30 mg/kg/dose)	No	NA	Failure in preventing CAAs	NA	240
Guillaume <i>et al.</i> <sup>17</sup>	Case report (1)	1	6 mg/kg/day 10 weeks, 6 mg/kg/day every 2 days 4 weeks, 6 mg/kg/day every 3 days 4 weeks	2 IVig doses, 2 methylprednisolone pulses (30 mg/kg/dose)	Yes	25	Remission of fever and partial CAAs regression	None	180
Sánchez-Manubens <i>et al.</i> <sup>16</sup>	Case report (1)	1	2 mg/kg/day	2 IVig doses, 4 methylprednisolone pulses (30 mg/kg/dose), oral prednisone	No	19	Complete clinical and laboratory remission	None	112
Blonz <i>et al.</i> <sup>24</sup>	Letter to the editor (1)	1	100 mg/day	2 IVig doses	Yes	NA	Complete clinical and laboratory remission, improvement of CAAs	NA	600
Koné-Paut <i>et al.</i> <sup>18</sup>	Retrospective study (11)	11	2–8 mg/kg/day	NA	Yes (11/11)	8–87	Complete clinical and laboratory remission (9/11), improvement of CAAs (10/11)	NA	6 to 81
Flinn <i>et al.</i> <sup>22</sup>	Retrospective study (32)	1	NA	2 IVig doses, methylprednisolone pulse (30 mg/kg/dose), infliximab, cyclophosphamide	Yes	NA	NA	NA	NA
Gamez-Gonzalez <i>et al.</i> <sup>23</sup>	Retrospective study (103)	2	NA	NA	NA	NA	NA	NA	NA
Maggio <i>et al.</i> <sup>21</sup>	Case report (2)	1	4 mg/kg/day	1 IVig dose, 3 methylprednisolone pulses (30 mg/kg/dose)	Yes	NA	Normalization of coronary arteries	NA	60
Lind-Holst <i>et al.</i> <sup>19</sup>	Case report (1)	1	5 mg/kg/day and then 10 mg/kg/day	2 IVig doses, infliximab (5 mg/kg), 2 high-dose methylprednisolone (15 mg/kg/day), oral prednisolone	Yes	18	Complete clinical and laboratory remission, no progression in coronary artery dilatation	NA	480
Gambacorta <i>et al.</i> <sup>20</sup>	Case report (1)	1	6 mg/kg/day	2 IVig doses, infliximab (5 mg/kg)	Yes	40	Complete clinical and laboratory remission, normalization of coronary arteries	None	360
Koné-Paut <i>et al.</i> <sup>25</sup>	Open-label phase IIA clinical trial (16)	16	From 2 mg/kg/day to 10 mg/kg/day	2 IVig doses	Yes (12/16)	14	Complete clinical and laboratory remission, normalization of coronary arteries (7/12) and improvement of CAAs (5/12)	3 SAE	45

ANA, anakinra; CAA, coronary artery aneurism; IVig, intravenous immunoglobulin, KD, Kawasaki disease; NA, not available; SAE, severe adverse event.



**Figure 2.** Graph of the trend of fever and CRP values in both patients in relation to therapy. ANA, anakinra; CRP, C-reactive protein; IVIg, intravenous immunoglobulin.

reported in previous cases (5–87 days). Both of our patients achieved apyrexia and a significant decrease of inflammatory markers in a few days of therapy (Figure 2) and a complete regression of coronary ectasia was observed in patient 2. Of note, both patients, were diagnosed close to the COVID-19 pandemic and tested for SARS-CoV-2 by nasal-pharyngeal swab and serological test, resulting negative. Therefore, a paediatric inflammatory multisystem syndrome temporary associated with SARS-CoV-2 infection was excluded.

Our experience highlights IL-1 blockade effectiveness in reducing KD systemic inflammation and further suggest ANA adoption as second-line therapy, with a timesaving and steroid-sparing strategy. Even if limited to two cases, our results, combined with the evidence of the IL-1 key role in KD coronary arteritis pathogenesis and with the recent clinical evidence reported by Koné-Paut *et al.*,<sup>25</sup> could suggest an earlier use of ANA in patients with refractory KD to prevent the development of CAAs.<sup>26,27</sup>

In this regard, a clinical trial with the aim of assessing safety and tolerability of ANA in IVIg-resistant patients with KD with severe coronary involvement ( $z$  score  $\geq 3$ ) is currently being conducted in the United States (ANAKID Trial, ClinicalTrials.gov identifier: NCT2179853)<sup>28</sup> and the recently approved ANACOMP trial will compare ANA efficacy and safety *versus* an additional IVIg dose in patients with KD who are not responsive to a first IVIg course.<sup>29</sup> We hope these studies will further define the place of IL-1 blockade in KD step-up treatment, in association with or in replacement of IVIg and steroids.

#### Conflict of interest statement

The authors declare that there is no conflict of interest.

#### Funding

The authors received no financial support for the research, authorship, and/or publication of this article.




### Research ethics and patient consent

Written informed consent for patients' information and images to be published were provided by the legally authorized representatives.

### ORCID iDs

Maria Vincenza Mastrolia  <https://orcid.org/0000-0002-9784-3543>

Gabriele Simonini  <https://orcid.org/0000-0002-5919-4861>

### References

1. Burns JC. Kawasaki disease update. *Indian J Pediatr* 2009; 76: 71–76.
2. McCrindle BW, Rowley AH, Newburger JW, *et al.* Diagnosis, treatment, and long-term management of Kawasaki disease: a scientific statement for health professionals from the American Heart Association. *Circulation* 2017; 135: e927–e999.
3. Burns JC, Capparelli EV, Brown JA, *et al.* Intravenous gamma-globulin treatment and retreatment in Kawasaki disease. US/Canadian Kawasaki Syndrome study group. *Pediatr Infect Dis J* 1998; 17: 1144–1148.
4. Tremoulet AH, Best BM, Song S, *et al.* Resistance to intravenous immunoglobulin in children with Kawasaki disease. *J Pediatr* 2008; 153: 117–121.
5. Dusser P and Koné-Paut I. IL-1 inhibition may have an important role in treating refractory Kawasaki disease. *Front Pharmacol* 2017; 8: 163.
6. Lee Y, Schulte DJ, Shimada K, *et al.* Interleukin-1 $\beta$  is crucial for the induction of coronary artery inflammation in a mouse model of Kawasaki disease. *Circulation* 2012; 125: 1542–1550.
7. Chen S, Dong Y, Yin Y, *et al.* Intravenous immunoglobulin plus corticosteroid to prevent coronary artery abnormalities in Kawasaki disease: a meta-analysis. *Heart Br Card Soc* 2013; 99: 76–82.
8. Brown TJ, Crawford SE, Cornwall ML, *et al.* CD8 T lymphocytes and macrophages infiltrate coronary artery aneurysms in acute Kawasaki disease. *J Infect Dis* 2001; 184: 940–943.
9. Lee Y, Wakita D, Dagvadorj J, *et al.* IL-1 signaling is critically required in stromal cells in Kawasaki disease vasculitis mouse model: role of both IL-1 $\alpha$  and IL-1 $\beta$ . *Arterioscler Thromb Vasc Biol* 2015; 35: 2605–2616.
10. Gorelik M, Lee Y, Abe M, *et al.* M. IL-1 receptor antagonist, anakinra, prevents myocardial dysfunction in a mouse model of Kawasaki disease vasculitis and myocarditis. *Clin Exp Immunol* 2019; 198: 101–110.
11. Noval Rivas M and Arditi M. Kawasaki disease: pathophysiology and insights from mouse models. *Nat Rev Rheumatol* 2020; 16: 391–405.
12. Hoang LT, Shimizu C, Ling L, *et al.* Global gene expression profiling identifies new therapeutic targets in acute Kawasaki disease. *Genome Med* 2014; 6: 541.
13. Weng K-P, Ho T-Y, Chiao Y-H, *et al.* Cytokine genetic polymorphisms and susceptibility to Kawasaki disease in Taiwanese children. *Circ J* 2010; 74: 2726–2733.
14. Cohen S, Tacke CE, Straver B, *et al.* A child with severe relapsing Kawasaki disease rescued by IL-1 receptor blockade and extracorporeal membrane oxygenation. *Ann Rheum Dis* 2012; 71: 2059–2061.
15. Shafferman A, Birmingham JD and Cron RQ. High-dose anakinra for treatment of severe neonatal Kawasaki disease: a case report. *Pediatr Rheumatol Online J* 2014; 12: 26.
16. Sánchez-Manubens J, Gelman A, Franch N, *et al.* A child with resistant Kawasaki disease successfully treated with anakinra: a case report. *BMC Pediatr* 2017; 17: 102.
17. Guillaume M-P, Reumaux H and Dubos F. Usefulness and safety of anakinra in refractory Kawasaki disease complicated by coronary artery aneurysm. *Cardiol Young* 2018; 28: 739–742.
18. Koné-Paut I, Cimaz R, Herberg J, *et al.* The use of interleukin 1 receptor antagonist (anakinra) in Kawasaki disease: a retrospective cases series. *Autoimmun Rev* 2018; 17: 768–774.
19. Lind-Holst M, Hartling UB and Christensen AE. High-dose anakinra as treatment for macrophage activation syndrome caused by refractory Kawasaki disease in an infant. *BMJ Case Rep* 2019; 12: e229708.
20. Gambacorta A, Buonsenso D, De Rosa G, *et al.* Resolution of giant coronary aneurysms in a child with refractory Kawasaki disease treated with anakinra. *Front Pediatr* 2020; 8: 195.
21. Maggio MC, Cimaz R, Alaimo A, *et al.* Kawasaki disease triggered by parvovirus infection: an atypical case report of two siblings. *J Med Case Rep* 2019; 13: 104.
22. Flinn AM, Gavin PJ, McMahon CJ, *et al.* Kawasaki disease - a review of treatment and

- outcomes in an Irish paediatric cohort 2010-14. *Ir Med J* 2018; 111: 691.
23. Gamez-Gonzalez LB, Moribe-Quintero I, Cisneros-Castolo M, *et al.* Kawasaki disease shock syndrome: unique and severe subtype of Kawasaki disease. *Pediatr Int* 2018; 60: 781-790.
24. Blonz G, Lacroix S, Benbrik N, *et al.* Severe Late-Onset Kawasaki Disease Successfully Treated With Anakinra. *J Clin Rheumatol* 2020; 26: e42-e43.
25. Koné-Paut I, Tellier S, Belot A, *et al.* Open-label, phase II study with anakinra in intravenous immunoglobulin-resistant Kawasaki disease. *Arthritis Rheumatol*. Epub ahead of print 17 November 2020. DOI: 10.1002/art.41481.
26. Burns JC, Koné-Paut I, Kuijpers T, *et al.* Review: found in translation: international initiatives pursuing interleukin-1 blockade for treatment of acute Kawasaki disease: IL-1 blockade for treatment of acute Kawasaki disease. *Arthritis Rheumatol* 2017; 69: 268-276.
27. Soni PR, Noval Rivas M and Arditi M. A comprehensive update on Kawasaki disease vasculitis and myocarditis. *Curr Rheumatol Rep* 2020; 22: 6.
28. Tremoulet AH, Jain S, Kim S, *et al.* Rationale and study design for a phase I/IIa trial of anakinra in children with Kawasaki disease and early coronary artery abnormalities (the ANAKID trial). *Contemp Clin Trials* 2016; 48: 70-75.
29. Ferrara G, Giani T, Caparello MC, *et al.* Anakinra for treatment-resistant Kawasaki disease: evidence from a literature review. *Paediatr Drugs* 2020; 22: 645-652.

Visit SAGE journals online  
[journals.sagepub.com/  
home/tab](https://journals.sagepub.com/home/tab)

 SAGE journals