

Central neurogenic hyperventilation related to post-hypoxic thalamic lesion in a child

Pinar Gençpınar,¹ Kamil Karaali,²
Şenay Haspolat,³ Oğuz Dursun⁴

¹Department of Pediatric Neurology, Tepecik Training of Research Hospital, Izmir; ²Department of Radiology, ³Department of Pediatric Neurology, ⁴Department of Pediatric Intensive Care Unit, Akdeniz University Hospital, Antalya, Turkey

Abstract

Central neurogenic hyperventilation (CNH) is a rare clinical condition, whose mechanism is still unclear. Here, we report a 3-year-old male patient, who had bilateral thalamic, putaminal and globus pallidum infarction resulted in CNH without brainstem involvement. This case may illustrate a possible role for the thalamus in regulating ventilation.

Introduction

Central neurogenic hyperventilation (CNH) is a rare condition and defined as a syndrome comprising normal or elevated arterial oxygen tension, decreased arterial carbon dioxide tension, and respiratory alkalosis with hyperventilation even during sleep.¹⁻³ The diagnosis of CNH requires the exclusion of pulmonary, cardiac, and metabolic disorders that can result in hyperventilation. To date, 44 cases have been reported in the literature and majority of these cases were secondary to tumoral lesions involving the brainstem. We report here a 3-year-old male patient presented with asphyxia and diagnosed as CNH related to diffuse thalamic infarction.

Case Report

A 3-year-old boy, who was intubated, was admitted to the emergency care unit. His parents had found him unconscious and cyanotic in the garden and there was a mark of his rainhood on his neck, which suggested suffocation. He was resuscitated twice before his admission to our hospital. On admission his Glasgow coma score (GCS) was 3. Electrocardiogram and chest radiograph were

normal. An emergency brain magnetic resonance imaging (MRI) was performed. Although there was no apparent lesion in the brain stem, bilateral diffuse thalamic, putaminal and globus pallidum lesions were detected on MRI (Figures 1 and 2). Examination revealed tachypnea (respiratory rate, 42/min), but other findings were normal. Arterial blood gases (ABGs) were pH, 7.52; PaCO₂, 29 mmHg; and PaO₂, 142 mmHg. The chest radiograph, electrocardiogram, and echocardiogram were normal. Laboratory studies disclosed the following values: hematocrit, 33.7%, white blood cell count, 10.6×10⁹/L; sodium, 140 mEq/L; potassium, 3.7 mEq/L; serum urea nitrogen; 6 mg/dL; creatinine, 0.21 mg/dL; and glucose, 110 mg/dL. Liver transaminases levels were normal. Serum lactate level was 1.97 mmol/L (normal range 0.5-2.2). His electroencephalogram was normal. His tachypnea could not be treated with analgesia (fentanyl infusion) and sedation (midazolam infusion). On the 16th day of admission hyperventilation resolved spontaneously. Tracheostomy was performed and he was discharged from the intensive care unit in vegetative state with normal ventilation.

Discussion

The pathophysiologic mechanism of CNH is unclear. It has been shown that in animal models, stimulation of the lateral parabrachial nucleus increased the respiratory rate.^{4,5} Stimulation of respiratory control areas in the pons and medulla could explain CNH but it is not sufficient. It has been known that pontine respiratory group neurons modulate the respiratory rhythm. But animal models that disconnect the pontine respiratory group from the medulla have not resulted in CNH.^{6,7} Elevated CNS lactate levels could be a reason of hyperventilation by stimulation of medullary chemoreceptors.⁸⁻¹¹ The lactate levels of our case were in normal range during hyperventilation state. Theoretically, hyperventilation could be seen in ictal-period during convulsions. Nevertheless intermittent hyperventilation would be more likely explanation in these cases.^{12,13} No ictal or interictal discharges were determined on electroencephalogram of our case during hyperventilation. The thalamus has multiple functions in the brain. The thalamus plays a major role in regulating arousal, the level of awareness, and activity. It also plays an important role in regulating states of consciousness. Similar to our case, Johnston *et al.* described chronic dyspnea and hyperventilation in a patient with subcortical infarcts in the medial thalamus bilaterally.¹⁴ These cases suggested a possible role for the thalamus in regulating ventilation in addition

Correspondence: Pinar Gençpınar, Department of Pediatric Neurology, Tepecik Training and Research Hospital, Izmir, Turkey.
Tel.: +90.505.887.9258.
E-mail: pinargencpinar@yahoo.com.tr

Key words: Central neurogenic hyperventilation; thalamus; tachypnea; children.

Contributions: PG prepared the manuscript; KK prepared the figures and edited in this respect; OD and SH edited this manuscript and made final version.

Conflict of interest: the authors declare no potential conflict of interest.

Received for publication: 23 January 2016.

Revision received: 1 February 2016.

Accepted for publication: 2 February 2016.

This work is licensed under a Creative Commons Attribution NonCommercial 4.0 License (CC BY-NC 4.0).

©Copyright P. Gençpınar *et al.*, 2016
Licensee PAGEPress, Italy
Neurology International 2016; 8:6428
doi:10.4081/ni.2016.6428

to the brainstem. Based on these information's, we thought that thalamic lesion may be more likely causing to CNH in our patient.

To date 44 cases were reported with CNH in the literature (Supplementary Table S1). Detailed clinical information of five cases was not available. Thirty of 39 patients (77%) had malignancies such as lymphoma, astrocytoma, glioblastoma and medulloblastoma. Other three underlying pathologies of CNH were multiple sclerosis, encephalitis and Anti N-metil-D-aspartat encephalitis. Similar to our case one patient, who was 79 years old, had CNH due to thalamic infarction without brainstem involvement.¹⁴ Kramer *et al.* described a male awake patient, who had chronic lymphocytic inflammation with pontine perivascular enhancement responsive to steroids syndrome (CLIPPERS) and diagnosed CNH.¹⁵ Majority of cases (77%) were adult. To our knowledge our case is the youngest patient diagnosed with CNH in the published literature.

Conclusions

In this report, a 3-year-old male patient, whom had bilateral diffuse thalamic lesion due to post-hypoxic damage resulted in CNH, was presented. Findings of this case support the possible role of thalamus in respiratory control.

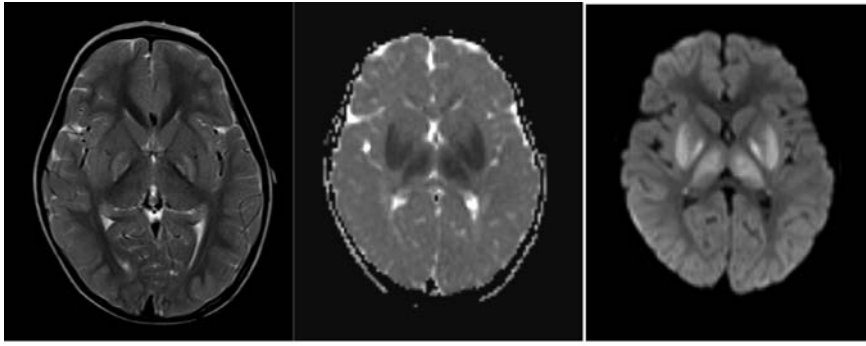


Figure 1. T2-weighted and diffusion weighted images. Increased intensity on both globus pallidus is present on T2-weighted image. Restricted diffusion is prominent on both thalami, putamina and globus pallidus.

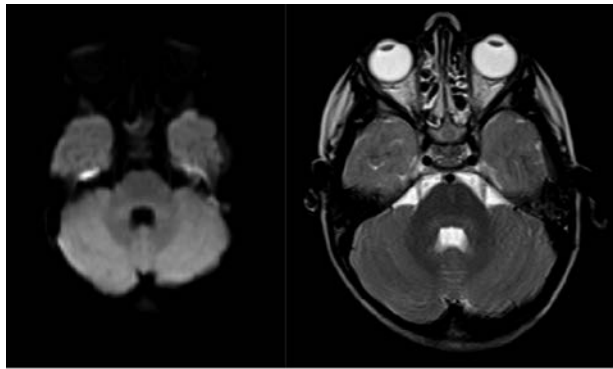


Figure 2. T2-weighted and diffusion weighted images show no pathologic intensity on pons.

References

1. Plum F, Swanson AG. Central neurogenic hyperventilation in man. *Arch Neurol Psychiatry* 1959;81:535-49.
2. Tarulli AW, Lim C, Bui JD, et al. Central neurogenic hyperventilation. A case report and discussion of pathophysiology. *Arch Neurol* 2005;62:1632-4.
3. Puzner R, Moullem M, Sadeh M, et al. High incidence of primary cerebral lymphoma in tumor-induced central neurogenic hyperventilation. *Arch Neurol* 1989;46:510-2.
4. Chamberlin NL, Saper CB. Topographic organization of respiratory responses to glutamate microstimulation of the parabrachial nucleus in the rat. *J Neurosci* 1994;14:6500-10.
5. Takayama K, Miura M. Respiratory responses to microinjection of excitatory amino acid agonists in ventrolateral regions of the lateral parabrachial nucleus in the cat. *Brain Res* 1993;604:217-23.
6. Plum F. Mechanisms of central hyperventilation. *Ann Neurol* 1982;11:636-7.
7. Bianchi AL, Denavit-Saubie M, Champagnat J. Central control of breathing in mammals: neuronal circuitry, membrane properties, and neurotransmitters. *Physiol Rev* 1995;75:1-45.
8. Nattie E. CO₂, brainstem chemoreceptors and breathing. *Prog Neurobiol* 1999;59:299-331.
9. Severson CA, Wang W, Pieribone VA, et al. Midbrain serotonergic neurons are central pH chemoreceptors. *Nat Neurosci* 2003;6:1139-40.
10. Richerson GB. Serotonergic neurons as carbon dioxide sensors that maintain pH homeostasis. *Nat Rev Neurosci* 2004;5:449-61.
11. Krendel DA, Pilch JF, Stahl RL. Central hyperventilation in primary CNS lymphoma: evidence implicating CSF lactic acid. *Neurology* 1991;41:1156-7.
12. Suzuki M, Kawakatsu T, Kamoshita S, et al. A case of pontine tumor associated with repeated episodes of hyperventilation and ketosis. *Paediatr Univ Tokyo* 1964;10:58-62.
13. Gottlieb D, Michowitz SD, Steiner I, Wald U. Central neurogenic hyperventilation in a patient with medulloblastoma. *Eur Neurol* 1987;27:51-4.
14. Johnston SC, Slingh V, Ralston HJ, Gold WM. Chronic dyspnea and hyperventilation in an awake patient with small sub-cortical infarcts. *Neurology* 2001;57:2131-3.
15. Kramer CL, Wijdicks EF. Central neurogenic hyperventilation. *Neurology* 2014;83:376.