

One year survivor of metastatic renal cell carcinoma treated with pazopanib

Fam Xeng Inn, Nurzarina Ahmed, Erica Yee Hing¹, Mohd Hafidzul Jasman

Department of Surgical, Urology Unit, UKM Medical Center, ¹Department of Radiology, UKM Medical Center, 56000 Cheras, Kuala Lumpur, Malaysia

Abstract

Tyrosine kinase inhibitor (TKI) and its side effects are well known. However, these are mainly descriptive, with pictorial data lacking. Here, in we report a case of metastatic renal cell carcinoma, treated with TKI, with classic side effects; supplemented with images that demonstrate the adverse effects of the drug. In addition, we discuss and demonstrate the computed tomography changes.

Key Words: Hair depigmentation, metastatic renal cell carcinoma, pazopanib, tyrosine kinase inhibitor

Address for correspondence:

Dr. Fam Xeng Inn, Department of Surgical, UKM Medical Center, Jalan Yaacob Latif, Bandar Tun Razak, 56000 Cheras, Kuala Lumpur, Malaysia.

E-mail: xenginn@gmail.com

Received: 03.09.2016, Accepted: 24.10.2016

INTRODUCTION

The introduction of tyrosine kinase inhibitors (TKIs) has changed the treatment options for patients with metastatic renal cell carcinoma (MRCC). The survival benefits of TKIs have been well studied, and it is recommended as a treatment option for MRCC. Knowledge and management of its side effects are essential to reduce patient's discomfort and avoid unnecessary treatment interruption. Using the case of a survivor of MRCC, who was treated with pazopanib for 1 year, we report the change of this patient's physical appearance, tumor features in computed tomography (CT) scan and the patient's adaptation to treatment toxicity.

CASE REPORT

A 47-year-old man presented with a 1 month history of gross hematuria. CT scan showed left renal enlargement with

hypoattenuating mass replacing the normal renal parenchyma without breaching renal capsule. The left renal vein was dilated and contained heterogeneously enhancing mass suggestive of tumor thrombus [Figure 1]. The tumor thrombus extended all the way up the inferior vena cava (IVC) into the right atrium. Bone scan showed a tumor metastasis to the right tibial. He was offered left radical nephrectomy, thrombectomy that would involve sternotomy, extracorporeal circulation, and replacement inferior vena cava graft if thrombus infiltrated to IVC. He preferred not to proceed with the surgery in view of it was a major and high-risk surgery. Biopsy of the renal tumor was done and confirmed advanced left renal cell carcinoma of the clear cell type. He underwent embolization of the left lower pole segmental renal artery, intended to treat postbiopsy tumoral bleeding. He was treated with pazopanib, due to the extent of the disease.

This is an open access article distributed under the terms of the Creative Commons Attribution-NonCommercial-ShareAlike 3.0 License, which allows others to remix, tweak, and build upon the work non-commercially, as long as the author is credited and the new creations are licensed under the identical terms.

For reprints contact: reprints@medknow.com

How to cite this article: Inn FX, Ahmed N, Hing EY, Jasman MH. One year survivor of metastatic renal cell carcinoma treated with pazopanib. *Urol Ann* 2017;9:194-6.

Access this article online

Quick Response Code:



Website:

www.urologyannals.com

DOI:

10.4103/0974-7796.204178

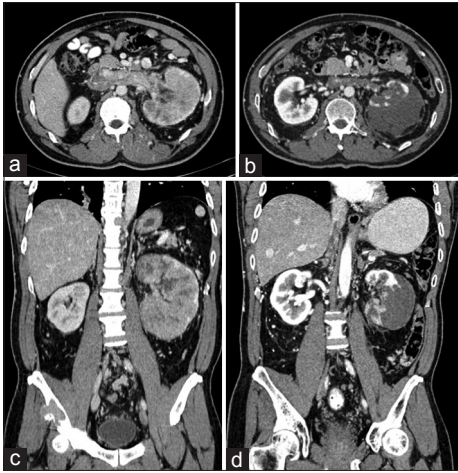


Figure 1: Contrast-enhanced computed tomography abdomen before (a and c) and 1 year following initiation of pazopanib (b and d)

Two months after, the initiation of pazopanib, progressive skin discoloration, and hair depigmentation was observed [Figure 2]. Subsequently, he complained of numbness and redness of his hands and feet. He was also noted with elevated liver enzymes and required interruption of treatment for 2 weeks.

He was followed up with a 6 monthly CT scan. The CT scan after 1 year demonstrated in Figure 1.

He returned to work and normal daily activities after 4 months of treatment. He has now been treated with pazopanib for 1 year; the side effects experienced are mainly nausea and lethargy; which are tolerable and do not require medical treatment. Surgery was offered to him again; however, he was not keen for surgery due to the positive treatment response and his tolerability to the treatment.

DISCUSSION

Pazopanib is a TKI that inhibits vascular endothelial growth factor (VEGF) and platelet-derived growth factor receptors on cancer cells and vascular endothelial cells. Hence, stopping the proliferation of tumor cells and development of tumor blood vessels.^[1] It is the first line treatment of MRCC with clear cell histologic component, and for patients who have received prior cytokine therapy for advanced disease, and an Eastern Cooperative Oncology Group performance status of 0 or I.^[2] It is not inferior to sunitinib with comparable efficacy in terms of overall survival with fewer side effects.^[3]

Toxicities are class effects of the VEGF pathway that can occur at different times but do not affect all patients. Intensity varies depending on its potencies within its class group. It has unique nonhematologic adverse effects that differ from immunotherapy and cytotoxic chemotherapy.



Figure 2: Photos of patient before (left) and 1 year following initiation of pazopanib (right)

Adverse events that are reported more frequently with pazopanib include changes in hair color, hypertension, weight loss, alopecia, and increased liver enzymes.^[2] Sunitinib is reported with higher-grade hand-foot syndrome. The differences in safety profile reflect the selectivity of multitargeted kinases.^[3]

Hair depigmentation is thought to be caused by blockade of c-Kit signaling, which is important for melanocyte proliferation, differentiation, and proper pigment production.^[1] This toxicity has been reported in studies involving pazopanib. However, no literature reports the appearance of hair depigmentation. We show the appearance changes following pazopanib treatment. The management plan, for managing dermatological toxicities, includes dose reduction or interruption; when the side effects become intolerable or interfere with daily living activities.

There is no reported case regarding patient's functional status after pazopanib treatment. This patient showed good functional status along with good cancer control. This drug allowed him to return to work and carry on his normal daily life.

The CT scan after 1 year demonstrated a small left kidney with subcapsular fluid collection from the previous biopsy. The tumor bulk had significantly reduced, and corticomedullary differentiation had returned in the upper pole. Irregular renal parenchymal outline and reduced enhancement in the lower pole were likely due to previous embolization of the left lower pole segmental renal artery, which was intended to treat postbiopsy tumoral bleeding. The left renal vein tumor thrombus was smaller and less enhanced [Figure 2]. These changes showed the effectiveness of pazopanib on controlling renal cell carcinoma. The residual normal nephron can be functional after malignant cells were controlled by pazopanib. This CT appearance is a useful guide for patients who are given a similar treatment.

CONCLUSION

This patient obtained good tumor control and tolerable toxicity with pazopanib.

Declaration of patient consent

The authors certify that they have obtained all appropriate patient consent forms. In the form the patient(s) has/have given his/her/their consent for his/her/their images and other clinical information to be reported in the journal. The patients understand that their names and initials will not be published and due efforts will be made to conceal their identity, but anonymity cannot be guaranteed.

Financial support and sponsorship

Nil.

Conflicts of interest

There are no conflicts of interest.

REFERENCES

1. Kollmannsberger C, Soulieres D, Wong R, Scalera A, Gaspo R, Bjarnason G. Sunitinib therapy for metastatic renal cell carcinoma: Recommendations for management of side effects. *Can Urol Assoc J* 2007;1 2 Suppl: S41-54.
2. National Institute for Health and Care Excellence. Pazopanib for the First-line Treatment of Advanced Renal Cell Carcinoma. UK: NICE. Published 23 February, 2011. Available from: <https://www.nice.org.uk/guidance/ta215/resources/pazopanib-for-the-firstline-treatment-of-advanced-renal-cell-carcinoma-82600251340741>. [Last accessed on 2016 Sep 02].
3. Motzer RJ, Hutson TE, Cella D, Reeves J, Hawkins R, Guo J, *et al.* Pazopanib versus sunitinib in metastatic renal-cell carcinoma. *N Engl J Med* 2013;369:722-31.