

# Detecting Pneumoperitoneum via Point-of-Care Abdominal Ultrasound: To See Beyond Touch

Wee Ming Peh<sup>1</sup>, Teng Joo Lok<sup>2</sup>

<sup>1</sup>Department of General Medicine, Seng Kang General Hospital, Singapore, Singapore

<sup>2</sup>Department of General Medicine, Khoo Teck Puat Hospital, Singapore, Singapore

Doi: 10.12890/2019\_001193 - European Journal of Case Reports in Internal Medicine - © EFIM 2019

Received: 29/06/2019

Accepted: 10/07/2019

Published: 29/07/2019

**How to cite this article:** Peh WM, Lok TJ. Detecting pneumoperitoneum via Point-of-Care abdominal ultrasound: to see beyond touch. *EJCRIM* 2019;6: doi:10.12890/2019\_001193.

**Conflicts of Interests:** The Authors declare that there are no competing interest

This article is licensed under a [Commons Attribution Non-Commercial 4.0 License](#)

## ABSTRACT

Point-of-care ultrasound is increasingly important in the management of acute medical emergencies. An elderly man was brought to the emergency department after 2 days of fever and urinary retention. He was drowsy and had peri-arrest arrhythmia. He was hypoperfused peripherally with a systolic blood pressure of 45 mmHg and so was managed as for septic shock with no obvious aetiology. Chest and abdominal physical examinations were unremarkable. The source of sepsis was unclear. A point-of-care abdominal ultrasound was performed by the reviewing internist which detected a pneumoperitoneum, leading to a change in diagnosis to a perforated viscus which was confirmed later by a CT of the abdomen and pelvis.

## LEARNING POINTS

- Pneumoperitoneum leading to septic shock is a medical emergency, but diagnosis is frequently delayed as the physical examination and chest and abdominal x-rays may fail to detect the condition in the critically ill patient, leading to delayed medical and surgical intervention.
- There is a role for point-of-care abdominal ultrasound for the early diagnosis of pneumoperitoneum with the air reverberation artefact.
- Point-of-care ultrasound of the abdomen to identify intra-abdominal air is an important physical examination adjunct in undifferentiated septic shock and should be incorporated into the routine care of patients and included in the acute medicine training syllabus.

## KEYWORDS

Point-of-care ultrasound, pneumoperitoneum, abdominal air reverberation artefact, perforated viscus

## CASE DESCRIPTION

A 70-year-old nursing home resident with diabetic mellitus, hypertension and peripheral vascular disease was noted to have 2 days of fever with urinary retention. He declined bladder catheterization. He was found drowsy and brought to hospital. His systolic blood pressure was 45 mmHg, and oxygen saturation was 68% under a non-rebreather mask, with a peripheral refilling time of 5 seconds. Chest examination was unremarkable. The abdomen was distended but soft with sluggish bowel sounds and otherwise unremarkable. A presumptive diagnosis of septic shock secondary to urosepsis was made.

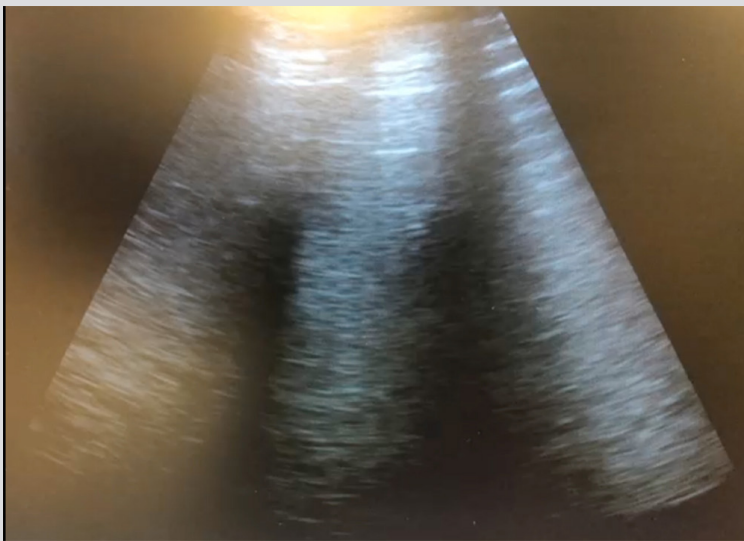
The patient's blood counts, renal profile and liver panels were unremarkable but hyperlactataemia of 14.2 mmol/l was noted. Blood gas analysis revealed severe mixed metabolic and respiratory acidosis with pCO<sub>2</sub> of 60.5 mmHg and serum bicarbonate of 12.4 mmol/l. The patient was given fluid resuscitation and started noradrenaline via a central venous catheter. He was intubated for airway protection and empirically started broad-spectrum antibiotics with a working diagnosis of suspected sepsis.

His chest and abdominal plain radiographs were unremarkable. There was no air under the diaphragm on the chest x-ray and there was

no 'double wall' Rigler sign on the abdominal x-ray. Both chest x-ray and abdominal x-ray were reviewed and discussed urgently with the consultant radiologist.

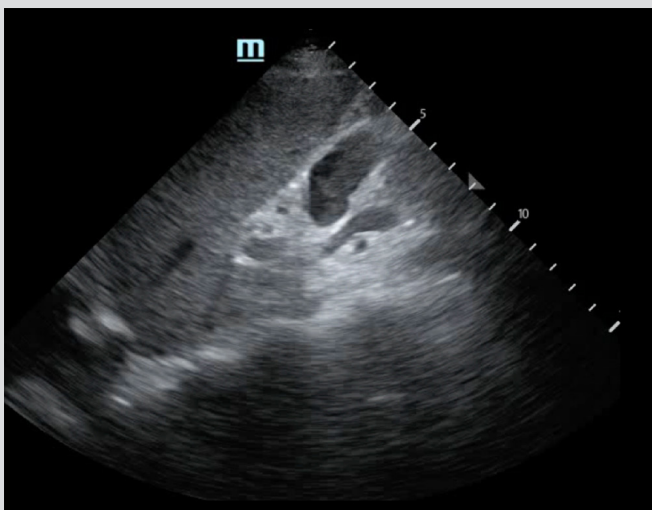
As part of the point-of-care ultrasound examination in the assessment of shock, an attempt was made to obtain a subxiphoid subcostal view of the heart and an inferior vena cava view with the phase array ultrasound probe. This was performed with cardiac preset in the longitudinal orientation. There was a reverberation air artefact, preventing visualization of the heart and the inferior vena cava.

The phase array probe was moved laterally to the right subcostal view in the longitudinal (cephalad-caudal) orientation. The usual liver echogenicity was lost from the hepatogram and was replaced with a reverberation artefact (*Fig. 1*).

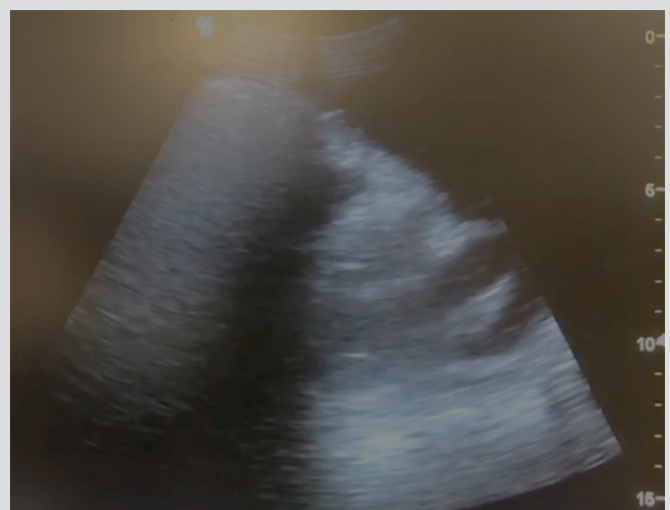


*Figure 1. Air reverberation artefacts at the right subcostal margin. Similar views were obtained in the left subcostal and subxiphoid regions*

The probe was manipulated in the same fashion, but to the left of the subcostal margin. The usual spleen echogenicity was also lost and the spleen could not be visualized on the ultrasound. An attempt was made to obtain a transverse view of the liver. The probe was oriented with the probe marker pointing towards the floor of the room at the mid-axillary line below the right lowest rib. A reverberation air artefact was noted, anterior to the right kidney obscuring the view of the liver (*Figs. 2 and 3*). A diagnosis of pneumoperitoneum was made.

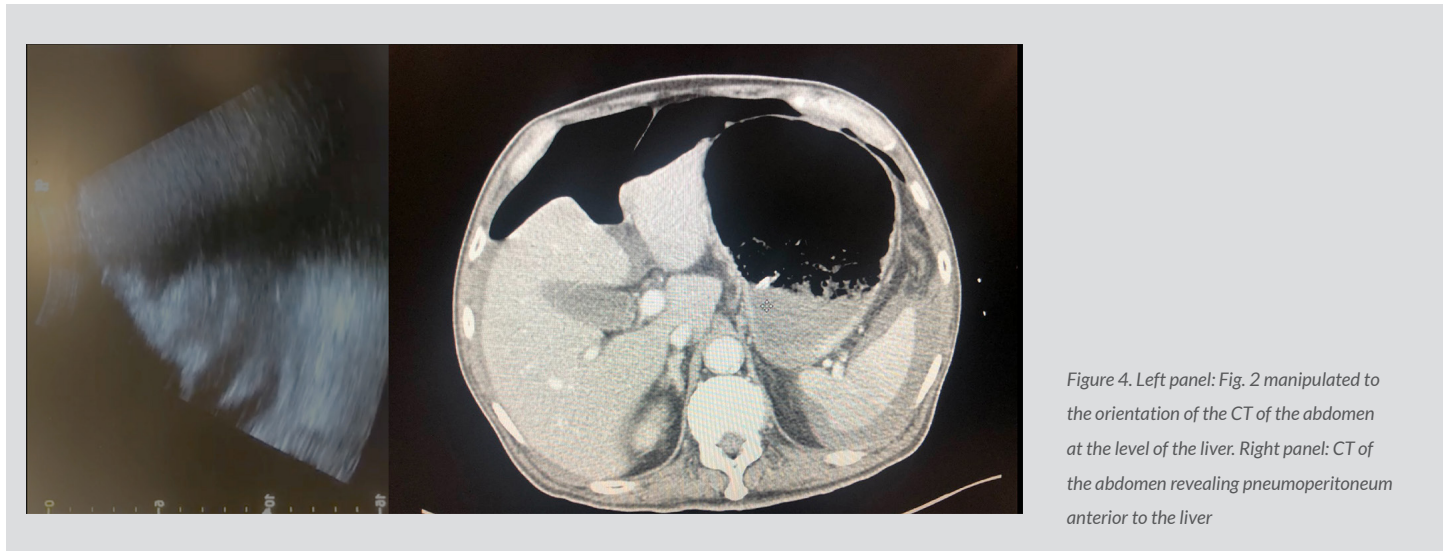


*Figure 2. Typical ultrasound image of the liver with gallbladder*



*Figure 3. Transverse ultrasound view of the liver. Air reverberation artefacts obscure the liver and anterior right transverse right kidney at the right mid-axillary margin*

A CT of the abdomen revealed a perforated sigmoid colon with faecal content. Pneumoperitoneum was confirmed with air detected above the liver, spleen and epigastric region (Fig. 4). A large amount of faeces was found in the peritoneal cavity.



## DISCUSSION

Perforated hollow viscus is an important differential diagnosis in patients who present with an acute abdomen. Symptoms are vague and non-specific. In patients who are critically ill, an accurate history and physical examination may be limited, and transfers for advanced imaging may be hazardous as the patient may be unstable. Early recognition of pneumoperitoneum is vital to guide management as perforated hollow viscus can cause shock through a complex mechanism. The patient will eventually need surgical intervention both for infection source control and for release of intra-abdominal pressure.

Ultrasound utilizes the reflection of high frequency sound waves to create images, making it promising for detecting pneumoperitoneum. If free air is present beneath the abdominal wall, the usual echogenicity of visceral organs is replaced by reverberation artefacts<sup>[1]</sup>. This phenomenon of air present within the abdomen and between the abdominal wall and organs is similar to the shadow seen in patients with pneumothorax obtained during lung ultrasound. In the context of acute abdomen, detection of air suggests an underlying perforated hollow viscus.

Point-of-care abdominal ultrasound is a good adjunct to routine physical examinations in terms of time-efficiency and convenience. Several studies have proven that ultrasound is more sensitive than currently used modalities. One study compared ultrasonography with plain abdominal radiography for the detection of pneumoperitoneum in 188 patients suspected of visceral perforation. The authors found that ultrasound had higher sensitivity (92% versus 78%), accuracy (88% versus 76%) and negative predictive value (39% versus 20%)<sup>[2]</sup>. X-ray imaging alone may not be sensitive enough to differentiate between perforated viscus and other causes of abdominal pain. This point was especially evident in the above case where chest x-ray and abdominal x-ray findings did not support a diagnosis of perforated viscus. In another study, senior physicians with experience in ultrasound identified patterns associated with pneumoperitoneum with an accuracy of up to 90%<sup>[3]</sup>.

Point-of-care abdominal ultrasound can also be used as an adjunct in decision-making for justifying the risks of transporting a critically ill patient for further imaging. A recent study designed to identify the most effective diagnostic strategy for patients with acute abdominal pain demonstrated that the highest sensitivity for detecting urgent diagnoses is achieved when ultrasonography is performed in all patients and CT only in the event of inconclusive or negative ultrasonography (conditional CT strategy). When this strategy is used, CT is only needed in 49% of patients<sup>[4]</sup>. Nonetheless, CT remains the gold standard for diagnosing a perforated viscus<sup>[5]</sup>.

However, this novel technique has several limitations. No studies have been done regarding the amount of free air needed for ultrasound to detect pneumoperitoneum. Also, ultrasound alone cannot differentiate other causes of pneumoperitoneum including peritoneal dialysis, recent laparoscopic/open abdominal surgery, intrathoracic causes and gynaecological causes. Lastly, point-of-care ultrasound is still operator dependant.

Nevertheless, we believe that ultrasonography should have a more prominent role in acute medicine today. Point-of-care ultrasound of the abdomen for the detection of pneumoperitoneum is an important adjunct to the physical examination and should be included in acute medicine training.

---

## REFERENCES

1. Moore CL, Copel JA. Point-of-care ultrasonography. *N Engl J Med* 2011;**364**:749–757.
2. Romero JA, Castaño N. Ultrasonography is superior to plain radiography in the diagnosis of pneumoperitoneum. *Br J Surg* 2002;**89**(3):351–354.
3. Nazerian P, Tozzetti C, Vanni S, Bartolucci M, Gualtieri S, Trausi F, et al. Accuracy of abdominal ultrasound for the diagnosis of pneumoperitoneum in patients with acute abdominal pain: a pilot study. *Crit Ultrasound J* 2015;**7**:15.
4. Lameris W, Van Randen A, Van Es HW, Van Heesewijk JPM, van Ramshorst B, Bouma WH, et al. Imaging strategies for detection of urgent conditions in patients with acute abdominal pain: diagnostic accuracy study. *Br Med J* 2009;**338**:b2431.
5. Stapakis JC, Thickman D. Diagnosis of pneumoperitoneum: abdominal CT vs upright chest film. *J Comput Assist Tomogr* 1992;**16**(5):713–716.