



Contents lists available at ScienceDirect

## International Journal of Surgery Case Reports

journal homepage: [www.casereports.com](http://www.casereports.com)

## A case report of parotid mammary analogue secretory carcinoma and reviews

Luona Sun<sup>a,\*</sup>, Teagan Thorson<sup>a</sup>, Roger Zhu<sup>a</sup>, Jerry Huo<sup>a</sup>, Jiankun Tong<sup>b</sup>, William H. Rodgers<sup>b</sup>, Larry Shemen<sup>a</sup><sup>a</sup> Department of Surgery, New York Presbyterian Queens Medical Center/Weill Cornell Medical College, 56-45 Main Street, Flushing, New York, United States<sup>b</sup> Department of Pathology, New York Presbyterian Queens Medical Center/Weill Cornell Medical College, 56-45 Main Street, Flushing, New York, United States

## ARTICLE INFO

## Article history:

Received 25 July 2018

Received in revised form

20 December 2018

Accepted 14 January 2019

Available online 19 January 2019

## Keywords:

Parotid

Salivary

Cancer

Head-and-neck

Case report

## ABSTRACT

**INTRODUCTION:** Mammary analog secretory carcinoma (MASC) is a new diagnosis of head and neck tumors first reported in 2010. It was often misdiagnosed as salivary acinic cell carcinoma (AciCC). We present a patient with an asymptomatic parotid tumor that underwent deep lobe parotidectomy and postoperative radiation therapy. The final pathology showed MASC.

**CASE PRESENTATION:** A 57-year-old male presented with an asymptomatic enlarging right parotid mass. A CT neck with IV contrast showed a 1.2 cm heterogeneously enhancing mass in the center of the right parotid gland without extraparotid extension. An FNA showed an epithelial neoplasm with papillary features. The patient underwent a right deep lobe parotidectomy with facial nerve dissection. The final pathology confirmed the diagnosis of MASC. He subsequently completed a 6-week course of radiation therapy and remained asymptomatic at his 30-month follow up.

**DISCUSSION/CONCLUSION:** Although MASC is considered a low-grade tumor in most cases, recurrence and disseminated disease are not uncommon. No standard treatment protocol has been established. This report aims to enhance the awareness of this diagnosis and provide a review of current treatments for head and neck oncology care providers.

© 2019 The Authors. Published by Elsevier Ltd on behalf of IJS Publishing Group Ltd. This is an open access article under the CC BY-NC-ND license (<http://creativecommons.org/licenses/by-nc-nd/4.0/>).

## 1. Introduction

Mammary analog secretory carcinoma (MASC) is a new entity in the differential diagnosis of salivary tumors originally reported by Skálová et al. [1]. MASC presents almost equally in both genders; some studies show a slight male predominance. The average age of presentation is in the mid-40s. While most tumors are reported in parotid glands, some may present in other parts of the oral cavity. The most common symptom is a slow-growing painless mass with the duration of months to years prior to presentation [1–8]. MASC is often misdiagnosed as other tumors such as salivary acinic cell carcinoma (AciCC). MASC was shown that translocation t(12;15)(p13;q25) resulted in ETV6-NTRK3 gene fusion, which was not present in AciCC [1,2]. We present a patient with an asymptomatic parotid tumor who underwent deep lobe parotidectomy and postoperative radiation therapy, and the final pathology

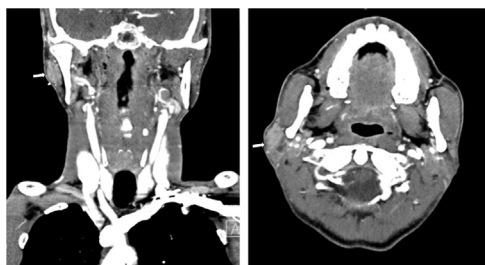
showed MASC. Current case report is in line with the SCARE criteria [9].

## 2. Case presentation

A 57-year-old male presented with an asymptomatic enlarging right parotid mass. He had no prior medical or surgical history and took no medications. He was an active smoker with 1.5 packs for 45 years with no alcohol or drug use. A CT neck with IV contrast showed a 1.2 cm heterogeneously enhancing mass in the center of the right parotid gland without extraparotid extension (Fig. 1). No lymph node abnormality was observed. An FNA was performed and the cytology report suggested an epithelial neoplasm with papillary features. The patient underwent a right deep lobe parotidectomy with facial nerve dissection and facial nerve monitoring. He tolerated the procedure well and was discharged home the same day. He recovered without incident, noting only mild right-sided earlobe numbness. A final pathology showed a well differentiated 1.6 cm tumor with no extraparenchymal extension, however, with focal positive margin adjacent to the facial nerve. The tumor cells were positive for alpha-1-anti-trypsin, Mammaglobin and S100. FISH

\* Corresponding author.

E-mail address: [lus9036@nyp.org](mailto:lus9036@nyp.org) (L. Sun).



**Fig. 1.** CT neck with contrast was performed. An approximately 1.2 cm heterogeneously enhancing mass (white arrow) in the center of the right parotid gland was noted. No extraparotid extension was seen. The left parotid, as well as the submandibular glands, were unremarkable. Axial and coronal views of the mass are shown in the figure.

study indicated a rearrangement of ETV 6 gene at 12p13.2, which had been reported in MASC. The invasive cystic morphology of the tumor, immunostaining profile, and FISH study were diagnostic of salivary gland mammary analog secretory carcinoma (MASC). He was referred to hematology/oncology and began radiation therapy 3 weeks postoperatively. He completed a 6-week course of radiation treatment and remained asymptomatic 30 months post surgery.

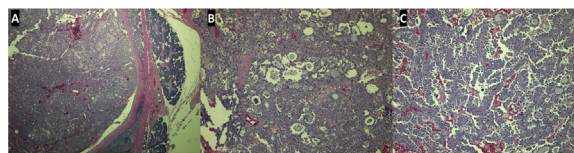
### 3. Differential diagnosis

The differential diagnoses include acinic cell carcinoma, low-grade cribriform cystadenocarcinoma, low-grade mucoepidermal carcinoma, polymorphous low-grade adenocarcinoma, and cystadenocarcinoma or adenocarcinoma, squamous cell carcinoma, malignant lymphoepithelial lesions of parotid gland. The most common tumor in the parotid gland that is easily misdiagnosed with this entity is acinic cell carcinoma.

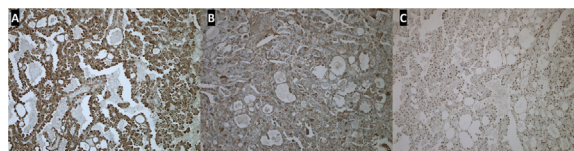
### 4. Discussion

Since the study by Skálová et al. MASC was recognized as a new diagnosis in head and neck oncology with the histologic features resembling secretory carcinoma of the breast. Numerous subsequent cases and retrospective studies reassigned previous diagnoses to this new entity. Histopathologic features, immunohistochemistry, demographic distributions and clinical behaviors were described [2–5]. Currently, the guidelines for surgical treatment, chemoradiation, and follow up have not been standardized due to the small number of cases. With the exception of a meta-analysis, the maximum number of patients in a case series that has been reported was 16 in Skálová et al. [1–8,10–14].

Histologically, these tumors are lobulated in an eosinophilic vacuolated background with an abundant extracellular secretory material which stains positive for periodic acid-Schiff (PAS) and alcian blue. Mitotic figures and necrosis are rare. Lack of zymogen granules is often noted. Microinvasion can be observed but usually, the tumor is well-circumscribed with septae in cystic and papillary patterns. These tumors can demonstrate different morphologies including microcystic, macrocystic, papillary, solid, and tubular structures, and they are characterized by a proliferation of small to medium-sized cells with eosinophilic and vacuolated cytoplasm and small nuclei. In our case, the tumor showed predominantly microcystic (Fig. 2B) and papillary growth patterns (Fig. 2C). These tumors may also show strong mammaglobin, vimentin, and S-100 protein positivity. These pathologic features resemble AcicCC, which also has a microcystic growth pattern. However, AcicCC has the distinctive feature of having zymogen vacuoles which is not present in MASC, while MASC has strong S-100 positivity which is absent in AcicCC. Other differential diagnostic tools include evaluating for



**Fig. 2.** Mammary analog secretory carcinoma is a malignant neoplasm that mimics secretory carcinoma of breast and acinic cell carcinoma occurring in the parotid. It shows different morphologies including solid, microcystic, macrocystic, and papillary architecture. Fig. 2A shows well-circumscribed capsulated tumor adjacent to the normal parenchyma of parotid gland (HE x 4). Fig. 2B shows microcystic architecture (HE x 10). Fig. 2C shows papillary architecture (HE x 10).



**Fig. 3.** Immunohistochemistry for mammary analog secretory carcinoma. The tumor cells are positive for S100 (Fig. 3A), Mammaglobulin (Fig. 3B), and Gata-3 (Fig. 3C).

the ETV6-NTRK3 gene fusion  $t(12;15)(p13;q25)$  translocation via Fluorescent In Situ Hybridization (FISH) analysis. With this recognition and criteria, multiple cases that were previously diagnosed as AcicCC were re-classified as MASC [1,3–6,8,11]. Most recently, new diagnostic features were also reported. Irregularity of nuclear membrane in addition to the solid/cystic component of the tumor was found in MASC cases [11].

Various imaging modalities have been used in different case reports including ultrasound (US), CT and MRI [4,6,11,14]. MASC appears to be hypoechoic on US and hyperintense on the T1 phase of MRI. Most reported cases included FNA, which can be supplemented with immunohistochemical evaluation for mammaglobin, S-100, and vimentin. Hormonal receptor status has been mentioned in the report by Balanza et al., as “triple negative” (ER/PR/HER-2 negative) [6]. Not all cases reported had been investigating hormonal receptors and the indication for checking hormonal receptor status is not clear. In our case, the tumor tested negative for androgen receptors. In the final pathology, the tumor was positive for alpha-1-anti-trypsin (AAT), CK-7, EMA, HMCK (34BE12), Lysosome, S100 (Fig. 3A), Mammaglobin (Fig. 3B), GATA-3 (Fig. 3C), and Vimentin, while negative for androgen receptor (AR), BRST-2, CK-20, P63, and SMA. PAS, D-PAS, and Mucicarmin were equivocal. The proliferation index as assessed by Ki-67 was approximately 5–10%. FISH analysis indicated the tumor cells had a rearrangement of the ETV6 locus.

Although MASC is considered a low-grade malignant tumor in most cases, recurrence and disseminated disease are not uncommon. In studies by Skálová et al., Bishop et al., Majewska et al., and Serrano-Arévalo et al., recurrence, disseminated disease and mortality were reported [1–3,6,7]. In some studies, MASC is considered as a more aggressive disease compared to AcicCC due to the increased number of positive lymph nodes on dissection and a higher rate of recurrence. However, this has not been proven with statistical significance due to the small number of cases. As a newly introduced neoplasm, MASC does not have an official grading system for pathology [4–6,10]. Ki-67 was reported in our case but has not been routinely checked in other case reports.

Currently, management of MASC follows the treatment of low-grade malignant salivary gland neoplasms, which includes complete surgical excision for local, less aggressive disease. Adjunctive neck dissection, radiation, and chemotherapy have been reserved for more invasive or metastatic disease or for positive margins. However, no standard protocol for multidisciplinary

treatment has been established due to the rarity of this disease [4–8,10–14]. In the cases reported, almost all patients underwent surgical excision, with either a total or superficial parotidectomy. Neck dissections were performed in a subset of patients considered to have high-grade transformation or lymph nodes at presentation. No standard clinical indications for neck dissection have been documented [1–4,6,5–8]. A rare presentation of MASC was also reported with an individual institution's experience of treatment. In the report by Suzuki, a MASC tumor presented as a metastatic lymph node with unknown primary origin. The patient underwent radical neck dissection without adjuvant treatment and remained asymptomatic for 9 months follow up [14].

Genetic targeted therapy has been showing potential in MASC. A promising oral agent, Entrectinib, is a tyrosine kinases inhibitor of TRKA/B/C. The most well-known case study by Drilon et al. reported a female patient with MASC with an NTRK3-rearrangement previously diagnosed as AcicC. She received pan-Trk inhibitor entrectinib. The patient initially responded with symptom resolution and tumor bulk resolution on imaging surveillance. However, she developed resistance to TrkC inhibition due to the NTRK3 G623R mutation. Despite the mutation mediated drug resistance, this study introduced a targeted pharmacological intervention for this rare malignancy [5,10,15,16]. Following this initial study, Drilon et al. carried out two Phase 1 protocols, ALKA-372-001 and STARTRK-1, evaluating entrectinib and its treatment response in MASC, Non-Small Cell Lung Cancer (NSCLC), colorectal cancer, melanoma, and renal cell carcinoma with TRKA/B/C, ROS1, or ALK mutations. Currently, STARTRK (Studies of Tumor Alterations Responsive to Targeting Receptor Kinases)-2 is an ongoing Phase 2 study [16].

## 5. Conclusion

We have presented a patient with an asymptomatic parotid tumor who underwent deep lobe parotidectomy and postoperative radiation therapy with the final diagnosis of MASC. No chemotherapy or genetic targeted therapy has been administered. The patient has been disease-free for 30 months. MASC has been underdiagnosed due to its rarity and confusion with AcicC in past decades. In the past two years, new and rare presentations of MASC had been reported clinically and histologically. This report aims to enhance the awareness of the diagnosis and reviews the current treatments for head and neck oncologic care providers.

## Conflicts of interest

N/A.

## Funding

N/A.

## Ethical approval

The New York Presbyterian Queens IRB has reviewed and determined that the proposed project does not meet the definition of research involving human subjects as per federal regulations (45CFR46.102); therefore, it may be conducted without further IRB review.

## Consent

Written informed consent was obtained from the patient for publication of this case report and accompanying images. A copy

of the written consent is available for review by the Editor-in-Chief of this journal on request.

## Author contribution

Luona Sun – Writing and review of literature.  
Teagan Thorson – Writing and editing of manuscript.  
Roger Zhu – Writing and editing of manuscript.  
Jerry Huo – Review of manuscript.  
Jiankun Ton – Review of manuscript and pathology review.  
William Rodgers – pathology review.  
Larry Shemen – Review and editing of manuscript, Management of patient.

## Registration of research studies

Case Report.

## Guarantor

Luona Sun, MD.  
Larry Shemen, MD.

## Provenance and peer review

Not commissioned, externally peer-reviewed.

## References

- [1] A. Skálová, T. Vanecek, R. Sima, J. Laco, I. Weinreb, B. Perez-Ordóñez, I. Starek, M. Geierova, R.H.W. Simpson, F. Passador-Santos, A. Ryska, I. Leivo, Z. Kinkor, M. Michal, Mammary analogue secretory carcinoma of salivary glands, containing the ETV6-NTRK3 fusion gene: a hitherto undescribed salivary gland tumor entity, *Am. J. Surg. Pathol.* 34 (2010) 599–608.
- [2] H. Majewska, A. Skálová, D. Stodulski, A. Klimková, P. Steiner, C. Stankiewicz, W. Biernat, Mammary analogue secretory carcinoma of salivary glands: a new entity associated with ETV6 gene rearrangement, *Virchows Arch.* 466 (2015) 245–254.
- [3] J.A. Bishop, R. Yonescu, D. Batista, D.W. Eisele, W.H. Westra, Most nonparotid “acinic cell carcinomas” represent mammary analog secretory carcinomas, *Am. J. Surg. Pathol.* 37 (2013) 1053–1057.
- [4] R. Sethi, E. Kozin, A. Remenschneider, J. Meier, P. VanderLaan, W. Faquin, D. Deschler, R. Frankenthaler, Mammary analogue secretory carcinoma: update on a new diagnosis of salivary gland malignancy, *Laryngoscope* 124 (2014) 188–195.
- [5] I. Damjanov, F. Skenderi, S. Vranic, Mammary Analogue Secretory Carcinoma (MASC) of the salivary gland: a new tumor entity, *Bosn. J. Basic Med. Sci.* 16 (2016) 237–238.
- [6] J. Albus, J. Batanian, B.M. Wenig, C.I. Vidal, A unique case of a cutaneous lesion resembling mammary analog secretory carcinoma: a case report and review of the literature, *Am. J. Dermatopathol.* 37 (2015) e41–44.
- [7] M.L. Serrano-Arévalo, A. Mosqueda-Taylor, H. Domínguez-Malagón, M. Michal, Mammary analogue secretory carcinoma (MASC) of salivary gland in four Mexican patients, *Med. Oral Patol. Oral Cir. Bucal* 20 (2015) e23–9.
- [8] S.I. Chiosea, C. Griffith, A. Assaad, R.R. Seethala, Clinicopathological characterization of mammary analogue secretory carcinoma of salivary glands, *Histopathology* 61 (2012) 387–394.
- [9] R.A. Agha, A.J. Fowler, A. Saeta, The SCARE statement: consensus-based surgical case report guidelines, *Int. J. Surg.* 34 (2016) 180–186.
- [10] T.M. Stevens, V. Parekh, Mammary analogue secretory carcinoma, *Arch. Pathol. Lab. Med.* 140 (2016) 997–1001, <http://dx.doi.org/10.5858/arpa.2015-0075-RS>.
- [11] M.F. Gonzalez, I. Akhtar, V. Manucha, Additional diagnostic features of mammary analogue secretory carcinoma on cytology, *Cytopathology* 29 (2018) 100–103.
- [12] L.J. Shemen, A.G. Huvos, R.H. Spiro, Squamous cell carcinoma of salivary gland origin, *Head Neck Surg.* 9 (March–April (4)) (1987) 235–240.
- [13] D.L. Wu, L. Shemen, T. Brady, D. Saw, Malignant lymphoepithelial lesion of the parotid gland: a case report and review of the literature, *Ear Nose Throat J.* 80 (November (11)) (2001) 803–806.
- [14] K. Suzuki, M. Yagi, A. Kanda, Y. Kobayashi, M. Konishi, C. Miyasaka, T. Tashiro, H. Iwai, Mammary analogue secretory carcinoma presenting as a cervical lymph node metastasis of unknown primary site: a case report, *Case Rep. Oncol.* 10 (2017) 192–198.
- [15] A. Drilon, G. Li, S. Dogan, M. Gounder, R. Shen, M. Arcila, L. Wang, D.M. Hyman, J. Hechtman, G. Wei, N.R. Cam, J. Christiansen, D. Luo, E.C. Maneval, T. Bauer, M. Patel, S.V. Liu, S.H.I. Ou, A. Farago, A. Shaw, R.F. Shoemaker, J. Lim, Z.

Hornby, P. Multani, M. Ladanyi, M. Berger, N. Katabi, R. Ghossein, A.L. Ho, What hides behind the MASC: clinical response and acquired resistance to entrectinib after ETV6-NTRK3 identification in a mammary analogue secretory carcinoma (MASC), *Ann. Oncol.* 27 (2016) 920–926.

[16] A. Drilon, K.K. Sankhala, S.V. Liu, B.C. Cho, C. Blakely, C.E. Chee, M. Fakih, J. Polikoff, Z. Hornby, L. Schechet, D. Luo, E.C. Maneval, P.S. Multani, R.C. Doebele, Abstract CT060: STARTRK-2: a global phase 2, open-label, basket study of entrectinib in patients with locally advanced or metastatic solid tumors harboring TRK, ROS1, or ALK gene fusions, *Cancer Res.* 77 (2017) CT060.

#### Open Access

This article is published Open Access at [sciencedirect.com](https://www.sciencedirect.com). It is distributed under the [IJSCR Supplemental terms and conditions](#), which permits unrestricted non commercial use, distribution, and reproduction in any medium, provided the original authors and source are credited.