

Tuberculosis-associated IgA nephropathy

Journal of International Medical Research

2018, Vol. 46(7) 2549–2557

© The Author(s) 2018

Reprints and permissions:

sagepub.co.uk/journalsPermissions.nav

DOI: 10.1177/0300060518774127

journals.sagepub.com/home/imrYamei Wang^{1,2} and Yuhong Tao¹ 

Abstract

Immunoglobulin A nephropathy (IgAN) is the most frequent pathological diagnosis of tuberculosis (TB)-associated glomerulonephritis. Diagnosing TB-associated IgAN (TB-IgAN) is difficult because of its non-specific and insidious symptoms. An inaccurate diagnosis of TB-IgAN could result in the spread of TB and reduced renal function. Haematuria and proteinuria in conjunction with TB should be assessed because of the potential for diagnosis of IgAN. Renal biopsy is important in securing an accurate diagnosis prior to initiating treatment. Detection of *Mycobacterium tuberculosis* DNA and assessment of early secreted antigenic target of 6 kDa in renal biopsy tissues may have great potential diagnostic value in patients with TB-IgAN. Anti-TB therapy can effectively alleviate TB and TB-IgAN.

Keywords

Immunoglobulin A nephropathy, tuberculosis, $\gamma\delta$ T cells, haematuria, glomerulonephritis, *Mycobacterium tuberculosis*, renal function, T cell-secreted transforming growth factor β 1

Date received: 15 January 2018; accepted: 10 April 2018

Introduction

Immunoglobulin A nephropathy (IgAN) refers to a set of clinical syndromes with IgA immune complex deposition in mesangial areas and (or) capillary loops. This condition is accompanied by varying degrees of mesangial cell and mesangial matrix proliferation.¹ IgAN has been discovered in 40% of renal biopsy specimens acquired from patients with primary glomerulonephritis in China and Japan, 30% in Europe, and 20% in the United States.² Approximately

¹Department of Pediatrics, West China Second University Hospital, Sichuan University, Sichuan Province, China

²Key Laboratory of Birth Defects and Related Diseases of Women and Children (Sichuan University), Ministry of Education, China

Corresponding author:

Yuhong Tao, Department of Pediatrics, West China Second University Hospital, Sichuan University, No. 20, Section 3, Renmin Nan Lu, Chengdu 610041, China.
Email: hxyth@sina.com



one-third of patients with IgAN will experience renal failure in 10 years after diagnosis.³ In most cases, the cause of IgAN remains unclear. Cases of secondary IgAN have been reported, and underlying environmental triggers are associated with IgAN. Secondary IgAN is most frequently found in patients with liver disease or mucosal inflammation.⁴ Generally, IgAN may relapse or be aggravated after an upper respiratory infection or gastrointestinal infection. Tonsillectomy may improve renal function in patients with IgAN. IgA1 is often deposited in the kidney in the form of polymeric IgA1, which is mainly produced by mucosa-localized plasma cells. All of the above-mentioned findings indicate that infection may represent a pathogenic risk factor in IgAN and that antigens of microbial origin may participate in the pathogenesis of IgAN.

Tuberculosis (TB) has plagued people worldwide for thousands of years. *Mycobacterium tuberculosis* (*M. tuberculosis*; *MTB*) is believed to infect one-third of people. During 2007, *MTB* infection caused an estimated 9.27 million new cases and led to 1.7 million deaths.⁵ *MTB* can infect the urinary tract and typically results in cystitis. However, *MTB* infection may also be associated with the occurrence of IgAN.⁶ Patients can exhibit glomerular disease instead of classic renal TB.⁷ Currently, few cases of TB-associated IgAN (TB-IgAN) have been reported. Early diagnosis and treatment of TB could assist in reducing the risk of exacerbating infection because immunosuppressive agents are administered for IgAN. This review provides an overview of TB-IgAN.

Pathogenesis of TB-IgAN

The exact pathogenesis of TB-IgAN is not well defined and an appropriate disease model is unavailable. The immune response against *MTB* has been traditionally

considered as cellular immunity. A recent study showed that humoral immunity plays a vital role in the immune response to *MTB*.⁸ Active TB is frequently associated with a substantial increase in serum IgA levels because generation of specific IgA is aimed at the mycobacterial antigen A-60.^{9,10} Circulating immune complexes with IgA and mycobacterial antigens have been separated in serum from patients with TB.^{11,12} Therefore, deposition of these immune complexes in the kidney, activation of the alternative complement pathway, and the lectin pathway can cause IgAN.

$\gamma\delta$ T cells are the major lymphocyte subsets that regulate and initiate anti-infection immune responses. Another type of $\gamma\delta$ T cells is distributed in epithelial tissues and these cells become part of intraepithelial lymphocytes (IELs). $\gamma\delta$ T cells account for 10% to 18% of human intestinal IELs, and these levels reach 25% to 37% in human large intestinal IELs.^{13,14} Fortune et al.¹⁵ showed that the amount of $\gamma\delta$ T cells in the blood of patients with IgAN was substantially increased, and the proportion of $\gamma\delta$ T cells was positively correlated with serum IgA levels. B cells differentiate into plasma cells and generate antibodies. Therefore, these cells need co-stimulation signals, which result from the reciprocal influence between CD40L on activated T cells and CD40 on B cells, and stimulation by activated T cell-secreted transforming growth factor β 1 (TGF- β 1).¹⁶ Toyabe et al.¹⁷ reported that $\gamma\delta$ T cells isolated from patients with IgAN secrete greater amounts of TGF- β 1 compared with $\gamma\delta$ T cells isolated from healthy individuals. Stable TGF- β 1 can be detected in the supernatants of proliferating $\gamma\delta$ T cells, peripheral blood mononuclear cells (PBMCs), and $\gamma\delta$ T-depleted PBMC cultures.¹⁸ Murakami et al.¹⁹ reported that TGF- β 1 levels in plasma, serum, and urine of patients with IgAN were increased compared with patients who had IgA-negative

mesangial proliferative glomerulonephritis. Lai et al.²⁰ noted that TGF- β 1 mRNA expression specifically in CD4⁺ cells of patients with IgAN was higher compared with that in healthy controls and patients who experienced other chronic forms of nephritis. TGF- β 1 mRNA in CD4⁺ cells correlated with serum IgA levels. Bucket et al.²¹ used antibody immobilization to amplify $\gamma\delta$ T cells by activating anti-human CD3 monoclonal antibodies to produce a large amount of TGF- β 1 in *in vitro* cultures. Activated $\gamma\delta$ T cells are an important factor involved in increased TGF- β 1 levels in peripheral blood. Pathogenic microorganism infection increases $\gamma\delta$ T cell proliferation and cellular secretion of TGF- β 1. High TGF- β 1 levels stimulate plasma cells to produce a large amount of IgA, which can result in IgAN.

Patients with TB show a significant increase in $\gamma\delta$ T cell numbers at the infected site(s).²² Furthermore, a significant memory response occurs after re-infection.²³ Natural or synthetic phosphate antigen produced in the body of patients with TB can activate $\gamma\delta$ T cells and cause them to proliferate.^{24,25} Dieli et al.²⁶ co-cultured PBMCs that were extracted from *M. bovis*-infected calves and the purified antigen of *M. bovis* for 24 hours, and found that most of the $\gamma\delta$ T cells were activated. Additionally, this activation was significant for 7 consecutive days. In contrast, only a small proportion of $\alpha\beta$ T cells was activated, and the degree of activation was gradually reduced. Dieli et al.²⁶ also reported that children with positive purified protein derivative (PPD) skin tests showed strong V γ 9/V δ 2 T cell proliferation *in vivo* under stimulation of different phosphate antibodies. This occurred regardless of whether they were healthy children or paediatric patients with different clinical types of TB. Additionally, weak V γ 9/V δ 2 T cell proliferation was noted in healthy children with negative PPD skin tests. This finding suggests that $\gamma\delta$ T cells

have a close relationship with immunity against TB.

Therefore, the low molecular peptide antigen of *MTB* can stimulate $\gamma\delta$ T cell activation and proliferation on the human mucosal surface to secrete a large amount of TGF- β 1.^{24,25} High TGF- β 1 levels stimulate B cells to differentiate into plasma cells. These plasma cells subsequently produce defective IgA1^{17,20,27} and promote IgA1 deposition in the mesangial areas to cause IgAN (Figure 1).

Early secreted antigenic target of 6 kDa (ESAT-6) of *MTB* is a T cell antigen and a promising vaccine candidate.²⁸ ESAT-6 is commonly used as a diagnostic reagent to distinguish *MTB* infection from previous Bacille Calmette Guerin vaccination.²⁹ ESAT-6 is also associated with the virulence and pathogenicity of *MTB*.²⁸ Because ESAT-6 can bind to laminin, leading to lysis of alveolar epithelial cells, ESAT-6 may play a crucial role in the dissemination of *MTB*.³⁰ ESAT-6 also modulates cytokine production by immune cells, including inducing interleukin-1 secretion by macrophages³¹ and preventing interferon- γ generation by T-cells.³² Gao et al.³³ showed that ESAT-6 could lead to renal injury.

Manifestations of TB-IgAN

Classical renal TB is characterized by malaise, weight loss, and urinary symptoms, such as frequency, urgency, and flank pain. Radiological imaging of renal TB typically shows a unilateral destructive process involving the cortex and medulla with scarring, calcification, and even papillary necrosis.

By contrast, the clinical manifestation of TB-IgAN is atypical and nonspecific. TB-IgAN typically presents as active TB in the lungs and other organs before any symptoms of kidney diseases are observed. Local urinary symptoms are uncommon. Most patients TB-IgAN with may present

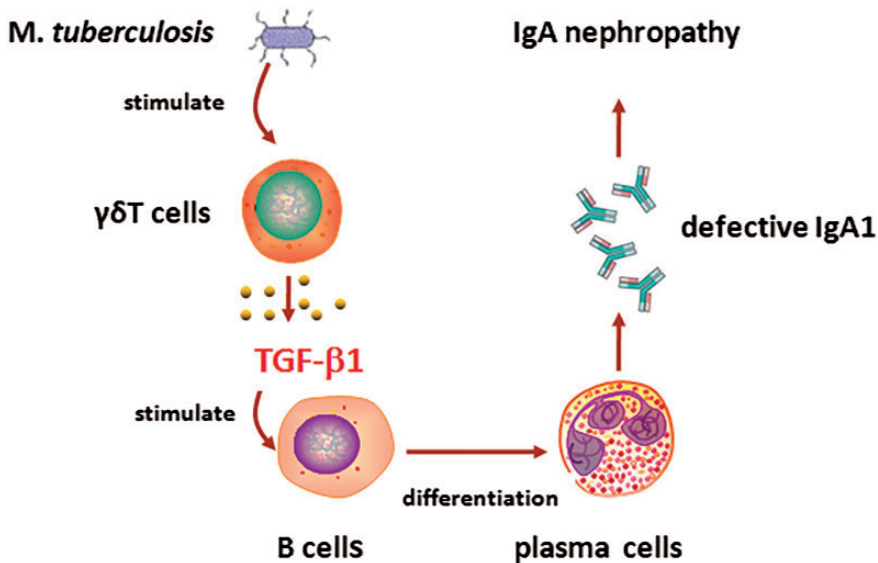


Figure 1. Preliminary pathogenesis of tuberculosis-associated immunoglobulin A nephropathy.

with systemic symptoms, such as fever, weight loss, and anorexia. Haematuria and culture-negative pyuria may be noted during urine analysis.⁶

Although some TB-IgAN cases have been documented in the English language literature,³⁴⁻⁴² a greater understanding of the clinical characteristics of TB-IgAN is necessary to raise awareness and improve disease treatment. As shown in Table 1, the clinical manifestations of TB-IgAN are atypical and nonspecific. Among the nine reported cases of TB-IgAN, one of the patients died.⁴² Among the eight patients who survived, seven cases were in adults, and one case was in a child. Six of the patients were males, and two were females. TB-IgAN presented as active TB in the lungs and other organs before any symptoms of kidney diseases were noted. Two patients had disseminated TB, five had pulmonary TB, and one case had lymphoid TB and cutaneous TB. The majority of patients presented with oedema, proteinuria, and hypertension, but some patients had advanced renal failure instead of classic renal TB symptoms.

Seven patients had nonspecific extrarenal manifestations, such as fever, weight loss, and cough. Haematuria was identified in all of the patients. Other presentations included nephrotic proteinuria in four patients, microscopic haematuria in five, macroscopic haematuria in one, oliguria in two, acute renal failure in two, oedema in one, and hypertension in one. Renal biopsy was performed in all of the patients, but the pathological change was similar to primary IgAN. Unfortunately, tests to detect *MTB* antigens were not performed on the biopsy samples.

Diagnosis and differential diagnosis of TB-IgAN

TB-IgAN is difficult to diagnose because of its non-specific symptoms and insidious onset. Early diagnosis of TB-IgAN is important because numerous patients do not receive an appropriate diagnosis of TB-IgAN and are diagnosed with primary IgAN instead. This condition should be highly suspected in patients with the following features: glomerulonephritis along with a

Table 1. Overview of previously reported cases of TB-IgAN

Author	Age (years)	Sex	Extrarenal manifestation	Type of TB	Haematuria	Proteinuria	Oliguria	Oedema	Hypertension	Renal failure	Renal deposit	Follow-up (months)	Outcome
Cohen A ³⁴	59	Male	-	DT	Microscopic	Negative	-	-	-	-	IgA	18	Remission
De Siati L ³⁵	31	Male	Fever	PT	Macroscopic	5.13 g/L	+	-	-	-	IgA, IgG, IgM, C3	24	Remission
Keven K ³⁶	36	Male	Dyspnoea, cough	PT	Microscopic	6.8 g/24 h	-	+	-	-	IgA	12	Remission
Matsuzawa N ³⁷	35	Female	Fever, pleural effusion, abdominal pain	DT	Microscopic	5.6 g/24 h	-	+	-	-	IgA, C3	9	Remission
Ortmann J ³⁸	36	Male	Pleural effusions	PPT	Microscopic	Negative	-	-	+	-	IgA	2	Partial remission
Singh P ³⁹	34	Male	Fever, weight loss	PPT	Microscopic	2.04 mg/dl	-	-	-	-	IgA	1	Remission
Khaira A ⁴⁰	14	Female	Rash, lymph node enlargement, haematuria	CT, LT	Microscopic	Negative	-	-	-	-	IgA	1	Remission
Mercadal L ⁴¹	78	Male	Cough	PT	Microscopic	-	+	-	-	+	IgA, C3	1	Remission
Fofi C ⁴²	75	Male	Purpura, anaemia	PT	Macroscopic	6.0 g/24 h	+	-	-	+	IgA	0	Died

TB-IgAN: tuberculosis-associated immunoglobulin A nephropathy; TB: tuberculosis; DT: disseminated tuberculosis; PPT: pleuro-pulmonary tuberculosis, PT: pulmonary tuberculosis, LT: lymphoid tuberculosis; CT: cutaneous tuberculosis; +: positive; -: negative; IgA: immunoglobulin A; IgG: immunoglobulin G; C3: complement 3.

history of TB, a strong positive result on a tuberculin PPD skin test, a positive result with a TB antigen assay, and a pathological diagnosis of IgAN.

According to a previous study,⁴³ patients who meet the following criteria can be diagnosed with TB-IgAN: (1) evidence of *MTB* infection, (2) elevated serum levels of a specific circulating immune complex in TB and reduced serum complement component 3 levels, (3) clinical manifestation of renal involvement, (4) renal pathological changes that are consistent with IgAN and exclude renal TB, (5) exclusion of secondary IgAN, and (6) *MTB*-specific antigen deposition in renal tissues.

Renal biopsy is important for obtaining an accurate diagnosis of TB-IgAN. However, no pathogenic features are observed on a renal biopsy. The final diagnosis of TB-IgAN is based on positive detection of *MTB* in the urine or kidney; however, finding evidence of *MTB* infection remains a challenge. Previously, a urine culture that was positive for *MTB* was thought to be the gold standard for diagnosing renal TB, but this method takes a long time to confirm the diagnosis. Most samples do not show visible colonies of *MTB* for at least 1 month, thus delaying the diagnosis. Some evaluations have demonstrated that the specificity of polymerase chain reaction in diagnosing *MTB* is substantially greater than with a urine *MTB* culture, with decreased rates of false-positive and false-negative outcomes. *MTB* DNA detected by polymerase chain reaction in renal biopsy specimens has a considerably increased positive rate compared with that found with urine culture.⁴³ Therefore, *MTB* DNA detection in renal biopsy tissues could be used to verify the diagnosis of TB-IgAN. A current study also showed that ESAT-6 could assist in the early diagnosis of IgAN caused by *MTB* infection.^{28,44} However, a patient's favourable response to anti-TB

therapy may also demonstrate a cause-and-effect relationship between IgAN and TB.

Treatment of TB-IgAN

As shown in Table 1, kidney damage in patients with TB-IgAN is alleviated to varying degrees after anti-TB therapy. Anti-TB drugs, which decrease the mycobacterial load from the circulation, may reduce the antigen load, and consequently reduce immune complex formation. There is no consensus whether to administer glucocorticoids and/or immunosuppressive therapy to patients who do not respond to anti-TB therapy. Patients with manifestations of nephrotic syndrome can be treated with small doses of glucocorticoids to alleviate allergies associated with TB. However, physicians should avoid glucocorticoids alone, which facilitate the spread of TB. These patients require long-term follow-up to monitor renal disease recurrence.

Conclusions

TB is a rare cause of IgAN. TB-IgAN may be misdiagnosed as primary IgAN because of nonspecific manifestations. Haematuria and proteinuria in patients with TB should be investigated for the potential diagnosis of IgAN. A renal biopsy is important in obtaining an accurate diagnosis before initiating treatment. Detection of *MTB* DNA and assessment of ESAT-6 in renal biopsy tissues may be of possible diagnostic value in patients with TB-IgAN. Anti-TB therapy can effectively alleviate TB and TB-IgAN; however, IgAN is rare in patients with TB. The pathogenesis of TB-IgAN needs further research to improve our understanding of this rare complication of TB.

Ethics approval

An ethics application was not required to conduct this review.

Declaration of conflicting interest

The authors declare that there is no conflict of interest.

Funding

This research received no specific grant from any funding agency in the public, commercial, or not-for-profit sectors.

ORCID iD

Yuhong Tao  <http://orcid.org/0000-0001-8074-4170>

References

1. Robert T, Berthelot L, Cambier A, et al. Molecular Insights into the Pathogenesis of IgA Nephropathy. *Trends Mol Med* 2015; 21: 762–775.
2. Hodgkin JB, Berthier CC, John R, et al. The molecular phenotype of endocapillary proliferation: novel therapeutic targets for IgA nephropathy. *PLoS One* 2014; 9: e103413.
3. Khositseth S, Kanitsap N, Warnnissorn N, et al. IgA nephropathy associated with Hodgkin's disease in children: a case report, literature review and urinary proteome analysis. *Pediatr Nephrol* 2007; 22: 541–546.
4. Pouria S and Barratt J. Secondary IgA nephropathy. *Semin Nephrol* 2008; 28: 27–37.
5. Kendall EA, Azman AS, Cobelens FG, et al. MDR-TB treatment as prevention: The projected population-level impact of expanded treatment for multidrug-resistant tuberculosis. *PLoS One* 2017; 12: e0172748.
6. Eastwood JB, Corbishley CM and Grange JM. Tuberculosis and the kidney. *J Am Soc Nephrol* 2001; 12: 1307–1314.
7. Baradaran A and Nasri H. Rare association of cutaneous vasculitis, IgA nephropathy and antiphospholipid antibody syndrome with tuberculous lymphadenitis. *Clinics (Sao Paulo)* 2013; 68: 1072.
8. Demkow U, Ziołkowski J, Białas-Chromiec B, et al. Humoral immune response against mycobacterial antigens in children with tuberculosis. *J Physiol Pharmacol* 2006; 57(Suppl 4): 63–73.
9. Radin RC, Zeiss CR and Phair JP. Antibodies to purified protein derivative in different immunoglobulin classes in the diagnosis of tuberculosis in man. *Int Arch Allergy Appl Immunol* 1983; 70: 25–29.
10. Alifano M, Sofia M, Mormile M, et al. IgA immune response against the mycobacterial antigen A60 in patients with active pulmonary tuberculosis. *Respiration* 1996; 63: 292–297.
11. May JJ, Katilus J, Henson PM, et al. The purification and identification of circulating immune complexes in tuberculosis. *Am Rev Respir Dis* 1983; 128: 920–925.
12. Raja A, Ranganathan UD and Ramalingam B. Clinical value of specific detection of immune complex-bound antibodies in pulmonary tuberculosis. *Diagn Microbiol Infect Dis* 2006; 56: 281–287.
13. Haas W, Pereira P and Tonegawa S. Gamma/delta cells. *Annu Rev Immunol* 1993; 11: 637–685.
14. Kabelitz D. Human gamma delta T lymphocytes. *Int Arch Allergy Immunol* 1993; 102: 1–9.
15. Fortune F, Courteau M, Williams DG, et al. T and B cell responses following immunization with tetanus toxoid in IgA nephropathy. *Clin Exp Immunol* 1992; 88: 62–67.
16. Zan H, Cerutti A, Dramitinos P, et al. CD40 engagement triggers switching to IgA1 and IgA2 in human B cells through induction of endogenous TGF-beta: evidence for TGF-beta but not IL-10-dependent direct S mu→S alpha and sequential S mu→S gamma, S gamma→S alpha DNA recombination. *J Immunol* 1998; 161: 5217–5225.
17. Toyabe S, Harada W and Uchiyama M. Oligoclonally expanding gammadelta T lymphocytes induce IgA switching in IgA nephropathy. *Clin Exp Immunol* 2001; 124: 110–117.
18. Rhodes SG, Hewinson RG and Vordermeier HM. Antigen recognition and immunomodulation by gamma delta T cells in bovine tuberculosis. *J Immunol* 2001; 166: 5604–5610.
19. Murakami K, Takemura T, Hino S, et al. Urinary transforming growth factor-beta in

- patients with glomerular diseases. *Pediatr Nephrol* 1997; 11: 334–336.
20. Lai KN, Ho RT, Leung JC, et al. Increased mRNA encoding for transforming factor-beta in CD4+ cells from patients with IgA nephropathy. *Kidney Int* 1994; 46: 862–868.
 21. Buck KS, Foster EM, Watson D, et al. Expression of T cell receptor variable region families by bone marrow gammadelta T cells in patients with IgA nephropathy. *Clin Exp Immunol* 2002; 127: 527–532.
 22. Modlin RL, Pirmez C, Hofman FM, et al. Lymphocytes bearing antigen-specific gamma delta T-cell receptors accumulate in human infectious disease lesions. *Nature* 1989; 339: 544–548.
 23. Shen Y, Zhou D, Qiu L, et al. Adaptive immune response of Vgamma2Vdelta2+ T cells during mycobacterial infections. *Science* 2002; 295: 2255–2258.
 24. Gossman W and Oldfield E. Quantitative structure–activity relations for gammadelta T cell activation by phosphoantigens. *J Med Chem* 2002; 45: 4868–4874.
 25. Dieli F, Sireci G, Di SC, et al. Predominance of Vgamma9/Vdelta2 T lymphocytes in the cerebrospinal fluid of children with tuberculous meningitis: reversal after chemotherapy. *Mol Med* 1999; 5: 301–312.
 26. Dieli F, Sireci G, Caccamo N, et al. Selective depression of interferon-gamma and granulysin production with increase of proliferative response by Vgamma9/Vdelta2 T cells in children with tuberculosis. *J Infect Dis* 2002; 186: 1835–1839.
 27. Noh JW, Wiggins R and Phan SH. Urine transforming growth factor-beta activity is related to the degree of scarring in crescentic nephritis in the rabbit. *Nephron* 1993; 63: 73–78.
 28. Boggaram V, Gottipati KR, Wang X, et al. Early secreted antigenic target of 6 kDa (ESAT-6) protein of Mycobacterium tuberculosis induces interleukin-8 (IL-8) expression in lung epithelial cells via protein kinase signaling and reactive oxygen species. *J Biol Chem* 2013; 288: 25500–25511.
 29. Kashyap RS, Ramteke SS, Morey SH, et al. Diagnostic value of early secreted antigenic target-6 for the diagnosis of tuberculous meningitis patients. *Infection* 2009; 37: 508–513.
 30. Kinhikar AG, Verma I, Chandra D, et al. Potential role for ESAT6 in dissemination of M. tuberculosis via human lung epithelial cells. *Mol Microbiol* 2010; 75: 92–106.
 31. Mishra BB, Moura-Alves P, Sonawane A, et al. Mycobacterium tuberculosis protein ESAT-6 is a potent activator of the NLRP3/ASC inflammasome. *Cell Microbiol* 2010; 12: 1046–1063.
 32. Peng H, Wang X, Barnes PF, et al. The Mycobacterium tuberculosis early secreted antigenic target of 6 kDa inhibits T cell interferon- γ production through the p38 mitogen-activated protein kinase pathway. *J Biol Chem* 2011; 286: 24508–24518.
 33. Gao YT, Sun L and Feng JM. Roles of mycobacterium tuberculosis ESAT-6 in the development of renal injury. *Int J Clin Exp Med* 2015; 8: 21964–21974.
 34. Cohen AJ and Rosenstein ED. IgA nephropathy associated with disseminated tuberculosis. *Arch Intern Med* 1985; 145: 554–556.
 35. De Siati L, Paroli M, Ferri C, et al. Immunoglobulin A nephropathy complicating pulmonary tuberculosis. *Ann Diagn Pathol* 1999; 3: 300–303.
 36. Keven K, Ulger FA, Oztas E, et al. A case of pulmonary tuberculosis associated with IgA nephropathy. *Int J Tuberc Lung Dis* 2004; 8: 1274–1275.
 37. Matsuzawa N, Nakabayashi K, Nagasawa T, et al. Nephrotic IgA nephropathy associated with disseminated tuberculosis. *Clin Nephrol* 2002; 57: 63–68.
 38. Ortmann J, Schiffl H and Lang SM. Partial clinical remission of chronic IgA nephropathy with therapy of tuberculosis. *Dtsch Med Wochenschr* 2010; 135: 1228–1231.
 39. Singh P, Khaira A, Sharma A, et al. IgA nephropathy associated with pleuropulmonary tuberculosis. *Singapore Med J* 2009; 50: e268–269.
 40. Khaira A, Rathi OP, Mahajan S, et al. Lupus vulgaris with tubercular lymphadenitis and IgA nephropathy. *Clin Exp Nephrol* 2008; 12: 79–81.

41. Mercadal L, Hulot JS, Isnard-Bagnis C, et al. Favorable outcome of IgA nephropathy on antituberculous treatment. *Minerva Urol Nefrol* 2006; 58: 355–357.
42. Fofi C, Cherubini C, Barbera G, et al. Extracapillary IgA nephropathy and pulmonary tuberculosis. *Clin Pulm Med* 2005; 12: 305–308
43. Sun L, Yuan Q, Feng J, et al. Be alert to tuberculosis-mediated glomerulonephritis: a retrospective study. *Eur J Clin Microbiol Infect Dis* 2012; 31: 775–779.
44. Li S, Siyuan T, Jiangmin F, et al. Analysis of the association between Mycobacterium tuberculosis infection and Immunoglobulin A nephropathy by early secreted antigenic target 6 detection in renal biopsies: a prospective study. *Postgrad Med* 2017; 129: 307–311.