

Case Report

# Tubular laminectomy and percutaneous vertebroplasty for aggressive vertebral hemangioma

Dimitrios Papadakos, Spiros Boulieris, Andreas Theofanopoulos, Dionysia Fermeli, Constantine Constantoyannis

Department of Neurosurgery, University Hospital of Patras, Rio University Hospital, Patras, Achaia, Greece.

E-mail: Dimitris Papadakos - jimppadak@hotmail.gr; Spiros Boulieris - spirosb95@hotmail.com; Andreas Theofanopoulos - andreastheofano@gmail.com; Dionysia Fermeli - deniafml@gmail.com; \*Constantine Constantoyannis - cconst@upatras.gr



**\*Corresponding author:**

Constantine Constantoyannis,  
Department of Neurosurgery,  
University Hospital of Patras,  
Rio University Hospital, Patras,  
Achaia, Greece.

cconst@upatras.gr

Received : 08 December 2020

Accepted : 23 December 2020

Published : 20 January 2021

DOI

10.25259/SNI\_888\_2020

Quick Response Code:



## ABSTRACT

**Background:** Vertebral hemangiomas (VH) are the most common benign vascular neoplasms of the spine. Aggressive VH (AVH) may become symptomatic due to soft-tissue expansion/extraspinal extension into the paraspinal and/or epidural spaces. There are several options for treating painful AVH, including radiotherapy and/or open surgery.

**Case Description:** A 59-year-old male presented with a 2-year history of intermittent back pain and progressive thoracic myelopathy in the past 2 months. MRI revealed a T9 level lesion, with high-intensity signal on both T1 and T2 images and an extraosseous component with significant cord compression. We performed minimally invasive tubular unilateral laminotomy for bilateral decompression of the thoracic spine at the T9 level, followed by bilateral percutaneous vertebroplasty with biopsy. Postoperatively, the pain was immediately relieved, and the myelopathy improved. The biopsy confirmed the diagnosis of a VH.

**Conclusion:** Combining minimally invasive techniques consisting of tubular laminectomy and percutaneous vertebroplasty are safe and effective ways for treating AVHs.

**Keywords:** Aggressive vertebral hemangiomas, Percutaneous vertebroplasty, Tubular laminectomy

## INTRODUCTION

Vertebral hemangiomas (VH) are benign vasoformative neoplasms of endothelial cells that grow within marrow spaces in the bone and encase bony trabeculae.<sup>[2,7]</sup> They affect 10–20% of the population and they are often incidental findings detected during imaging of the thoracolumbar spine.<sup>[3,10]</sup> Only 0.9–1.2% of hemangiomas cause symptoms consisting of local back pain (e.g., involving a vertebral body), radiculopathy from nerve root compression/myelopathy (e.g., due to epidural expansion/spinal cord compression).<sup>[3,5,10,16]</sup> A common choice of treatment for painful aggressive VH (AVH) without neurological compromise is vertebroplasty or kyphoplasty, while those with spinal cord compression may require decompression with/without tumor removal.<sup>[11,13,15,16]</sup>

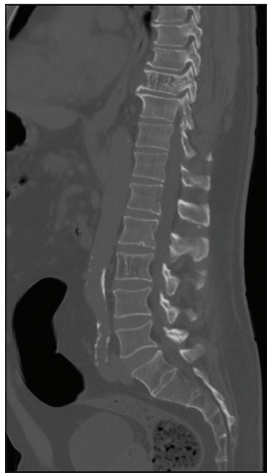Hereby, we present a patient with an AVH and a progressive paraparesis who benefitted from a minimally invasive T9 decompression with vertebroplasty.

This is an open-access article distributed under the terms of the Creative Commons Attribution-Non Commercial-Share Alike 4.0 License, which allows others to remix, tweak, and build upon the work non-commercially, as long as the author is credited and the new creations are licensed under the identical terms.

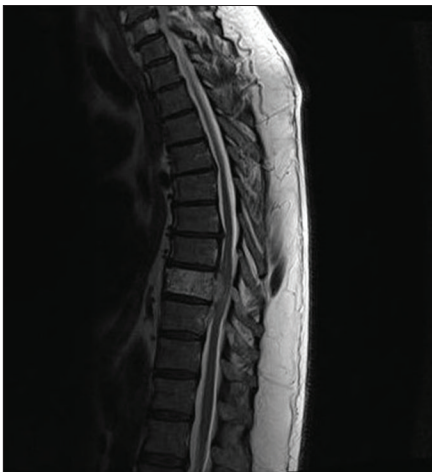©2020 Published by Scientific Scholar on behalf of Surgical Neurology International

## CASE PRESENTATION

A 59-year-old male presented with a 2-year history of intermittent back pain and in the past 2 months progressive myelopathy. On examination, he exhibited tenderness over the midline thoracic spinous processes, diffuse lower extremity hyperreflexia and spasticity. The thoracic CT revealed an osteolytic lesion with the characteristic “polka dot” or “salt and pepper” sign on the axial images and the “corduroy cloth” or “jail bar” sign on the sagittal images involving T9 [Figure 1]. There were also signs of extraosseous soft-tissue expansion into the spinal canal. The MRI revealed thickened trabeculae with high intensity signal areas on both T1 and T2 images; the extraosseous component had also high T1 and T2 signals [Figures 2 and 3]. There was also a high T2 cord signal opposite the T9 vertebral level reflecting significant cord compression.



**Figure 1:** A sagittal bone CT-scan with the characteristic appearance of a hemangioma of the T9 vertebra.



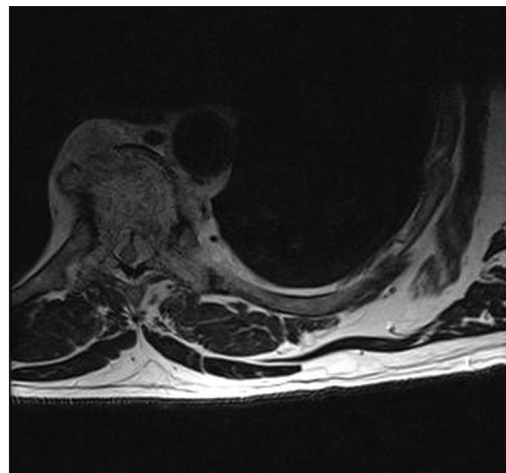
**Figure 2:** A sagittal T2 MRI scan with a high intensity signal of the T9 vertebra and signs of extraosseous soft tissue expansion into the spinal canal.

## Surgery

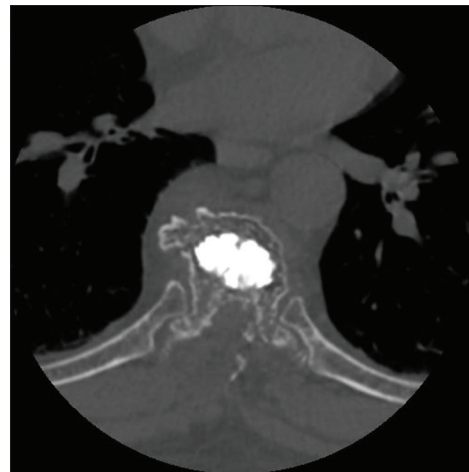
A minimally invasive T9 tubular unilateral laminotomy was performed to achieve decompression of the spinal canal. This was followed by a bilateral percutaneous vertebroplasty with biopsy. The postoperative CT and MRI scans showed adequate decompression of the thoracic spine, satisfactory cement location within the T9 body, with no cement leakage [Figures 4-7]. The biopsy confirmed the presence of a VH. Postoperatively, the patient was immediately asymptomatic and remained neurologically intact at 6 months follow-up.

## DISCUSSION

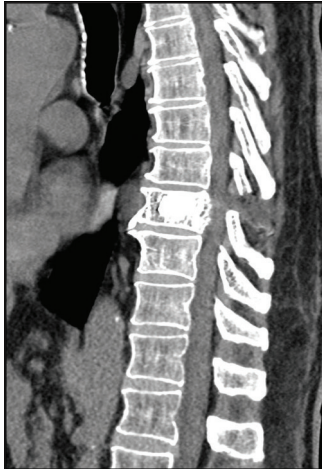
AVHs are rare conditions with varied available treatment options.<sup>[4,12,14]</sup> Here, we treated a patient with progressive



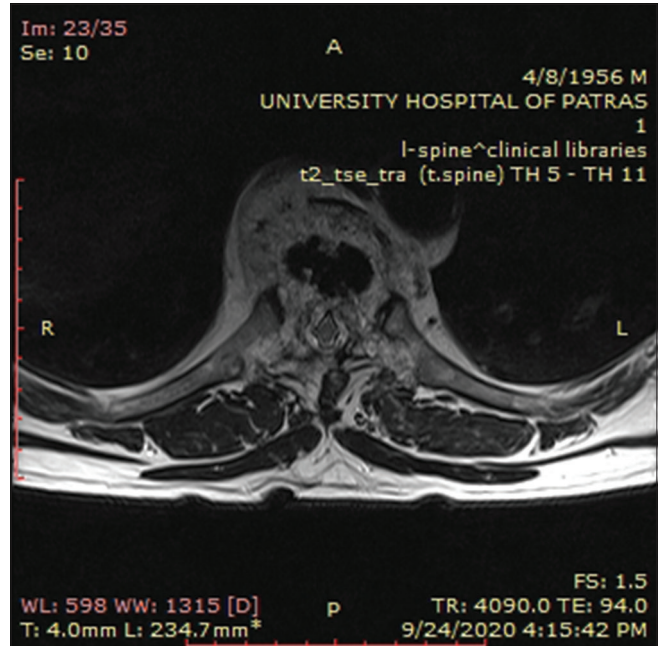
**Figure 3:** An axial T2 MRI scan of the T9 vertebra showing the extraosseous expansion of the hemangioma.



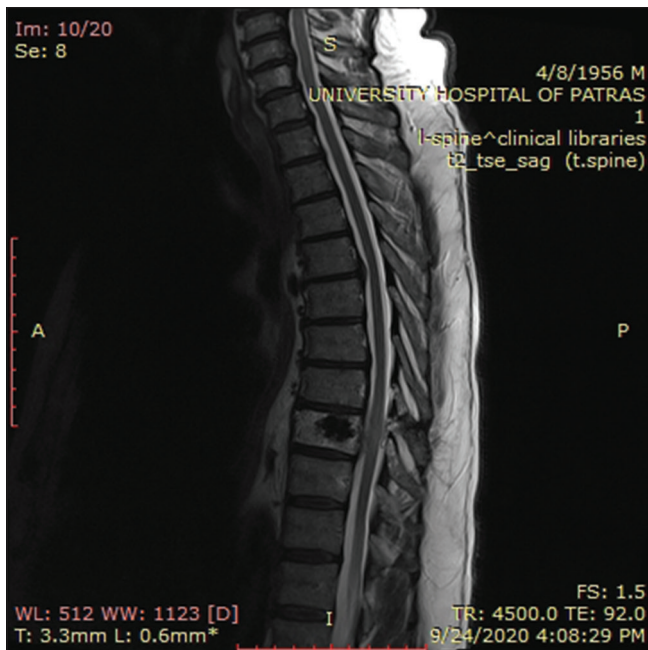
**Figure 4:** An axial CT scan postoperatively showing the adequate decompression of the canal and a satisfactory quantity of cement injected.



**Figure 5:** A sagittal CT scan postoperatively showing the vertebral body with the injected cement.



**Figure 7:** An axial T2 MRI scan, 6 months postoperatively showing the spinal canal decompressed by soft-tissue protrusion.



**Figure 6:** A sagittal T2 MRI, 6 months postoperatively showing the injected cement and the elimination of the spinal cord compression by the soft tissue.

myelopathy with a T9 minimal invasive tubular laminectomy and percutaneous vertebroplasty and biopsy. Utilizing a unilateral laminotomy for bilateral decompression as used in this case has gained popularity since 2002.<sup>[8]</sup> Kyphoplasty has also been supported in such cases.<sup>[1,13]</sup> Postoperatively, the patient developed no instability or kyphosis and has remained asymptomatic without the need for a secondary fusion.

On CT studies, the classic diagnosis of AVH is established by the typical “honeycomb” or “polka dot” signs attributed to trabecular involvement of vertebral bodies. On MRI, these lesions appear hyperintense on both T1W1 and T2W1 with contrast enhancement.<sup>[10]</sup>

Preoperative angiography to determine the vascularity of the tumor, followed by tumor embolization, is useful to decrease intraoperative blood loss.<sup>[6,8,16]</sup> Radiotherapy is usually used as adjuvant therapy after surgery and can result in radiation necrosis or radiation induced sarcomas.<sup>[2,5,6,9,16]</sup>

## CONCLUSION

Minimally invasive tubular laminectomy combined with percutaneous cement vertebroplasty and biopsy is a safe and efficacious procedure for the treatment of thoracic symptomatic AVHs.

## Declaration of patient consent

The authors certify that they have obtained all appropriate patient consent.

## Financial support and sponsorship

Nil.

## Conflicts of interest

There are no conflicts of interest.

## REFERENCES

1. Acosta FL, Sanai N, Chi JH, Dowd CF, Chin C, Tihan T, *et al.* Comprehensive management of symptomatic and aggressive vertebral hemangiomas. *Neurosurg Clin N Am* 2008;19:17-29.
2. Aich RK, Deb AR, Banerjee A, Karim R, Gupta P. Symptomatic vertebral hemangioma: Treatment with radiotherapy. *J Cancer Res Ther* 2010;6:199-203.
3. Barzin M, Maleki I. Incidence of vertebral hemangioma on spinal magnetic resonance imaging in Northern Iran. *Pak J Biol Sci* 2009;12:542-4.
4. Bas T, Aparisi F, Bas JL. Efficacy and safety of ethanol injections in 18 cases of vertebral hemangioma: A mean follow-up of 2 years. *Spine (Phila Pa 1976)* 2001;26:1577-82.
5. Cloran FJ, Pukenas BA, Loevner LA, Aquino C, Schuster J, Mohan S. Aggressive spinal haemangiomas: Imaging correlates to clinical presentation with analysis of treatment algorithm and clinical outcomes. *Br J Radiol* 2015;88:20140771.
6. Faria SL, Schlupp WR, Chiminazzo H. Radiotherapy in the treatment of vertebral hemangiomas. *Int J Radiat Oncol Biol Phys* 1985;11:387-90.
7. Fox MW, Onofrio BM. The natural history and management of symptomatic and asymptomatic vertebral hemangiomas. *J Neurosurg* 1993;78:36-45.
8. Guiot BH, Khoo LT, Fessler RG. A minimally invasive technique for decompression of the lumbar spine. *Spine (Phila Pa 1976)* 2002;27:432-8.
9. Heyd R, Seegenschmiedt MH, Rades D, Winkler C, Eich HT, Bruns F, *et al.* Radiotherapy for symptomatic vertebral hemangiomas: Results of a multicenter study and literature review. *Int J Radiat Oncol Biol Phys* 2010;77:217-25.
10. Laredo JD, Reizine D, Bard M, Merland JJ. Vertebral hemangiomas: Radiologic evaluation. *Radiology* 1986;161:183-9.
11. Mishra GM, Sharma NK, Gaikwad A, Mohanty SB, Sharma BK. Alcohol ablation of symptomatic vertebral hemangiomas. *AJNR Am J Neuroradiol* 1999;20:1091-6.
12. Rajeev MP, Waykule PY, Pavitharan VM, Nandeesh BN. Spinal epidural capillary hemangioma: A rare case report with a review of literature. *Surg Neurol Int* 2017;8:123.
13. Rawat S, Nangia S, Ezhilalan RB, Bansal AK, Ghosh D. Variance in the treatment of vertebral haemangiomas. *J Indian Med Assoc* 2007;105:42, 44-5, 48.
14. Sansur CA, Pouratian N, Dumont AS, Schiff D, Shaffrey CI, Shaffrey ME. Part II: Spinal-cord neoplasms-primary tumours of the bony spine and adjacent soft tissues. *Lancet Oncol* 2007;8:137-47.
15. Schrock WB, Wetzel RJ, Tanner SC, Khan MA. Aggressive hemangioma of the thoracic spine. *J Radiol Case Rep* 2011;5:7-13.
16. Sewell MD, Dbeis R, Bliss P, Watkinson T, Hutton M. Radiotherapy for acute, high-grade spinal cord compression caused by vertebral hemangioma. *Spine J* 2016;16:195-6.

**How to cite this article:** Papadakos D, Boulieris S, Theofanopoulos A, Fermeli D, Constantoyannis C. Tubular laminectomy and percutaneous vertebroplasty for aggressive vertebral hemangioma. *Surg Neurol Int* 2021;12:27.