

Quantitative and qualitative assessment of argyrophilic nucleolar organizer regions in normal, premalignant and malignant oral lesions

Buddhdev P Khushbu, Monali Chalishazar¹, Hemant Kale¹, Malay Baranwal², Tapan Modi³

Department of Oral Pathology, Manubhai Patel Dental College, Vadodara, ¹Department of Oral Pathology, Ahmedabad Dental College and Hospital, ³Department of Oral Pathology, College of Dental Sciences and Research Bopal Dental College, Ahmedabad, Gujarat, ²Department of Oral Pathology, Career Dental College, Lucknow, Uttar Pradesh, India

Abstract

Aim: The aim of the study was to assess the cell proliferation and biologic aggressiveness of the lesions by evaluating the significance of number and dispersal pattern of Argyrophilic Nucleolar organizing Regions (AgNORs) using silver colloid technique in normal mucosa, premalignant and malignant lesions.

Settings and Design: In-vitro study, lab setting

Methods and Material: The study sample consisted of five groups each with a sample size of 10 and a control group. Group I (Control), Group II (Oral Submucous Fibrosis - Mild dysplasia), Group III (Oral Submucous Fibrosis - Moderate dysplasia), Group IV (Leukoplakia - Mild dysplasia), Group V (Leukoplakia - Moderate dysplasia) and Group VI (Squamous cell carcinoma). Two sections were cut, of which one was stained with H/E stain for histopathological analysis and the second one with Silver nitrate for AgNOR counting and grading. The data obtained were analyzed both qualitatively and quantitatively.

Statistical Analysis Used: Student's Unpaired T test and One- way ANOVA

Results: The Mean AgNOR count increased in the following ascending order: i.e OSMF with mild dysplasia, leukoplakia with mild dysplasia, OSMF with moderate dysplasia, leukoplakia with moderate dysplasia and squamous cell carcinoma. Qualitatively, Type II AgNOR pattern was found to be the predominant one in all the samples. Type III AgNOR pattern was found to be increasing with the increase in the grade of dysplasia.

Conclusions: AgNOR quantity is proportional to the proliferative activity of the cell and does not necessarily always indicate malignancy. It is the qualitative characteristics of AgNOR that help to differentiate the premalignant and malignant lesions.

Keywords: Argyrophilic nucleolar organizer regions, malignant, premalignant, qualitative, quantitative

Address for correspondence: Dr. Buddhdev P Khushbu, A-19 Amruta Society, Near Mehsanagar Ground, Nizampura, Vadodara - 390 002, Gujarat, India.
E-mail: 4khushbu@gmail.com

Received: 23.09.2017, **Accepted:** 23.10.2017

INTRODUCTION

The normal epithelium is subjected to many assaults and to some extent can maintain its normal integrity by adaptation.

The oral cavity is the first part of the orodigestive system with which the food particles establish contact and is also the site which is subjected to insults and assaults by

This is an open access article distributed under the terms of the Creative Commons Attribution-NonCommercial-ShareAlike 3.0 License, which allows others to remix, tweak, and build upon the work non-commercially, as long as the author is credited and the new creations are licensed under the identical terms.

For reprints contact: reprints@medknow.com

How to cite this article: Khushbu BP, Chalishazar M, Kale H, Baranwal M, Modi T. Quantitative and qualitative assessment of argyrophilic nucleolar organizer regions in normal, premalignant and malignant oral lesions. J Oral Maxillofac Pathol 2017;21:360-6.

Access this article online

Quick Response Code:



Website:

www.jomfp.in

DOI:

10.4103/jomfp.JOMFP_52_15

exogenous materials, microorganisms and other noxious agents. Initially, the epithelial changes are reactive and reversible, but with progressive loss of normal control mechanisms, they may lead to a premalignant state or progressively, to cancer.

The idea of “precancer” has been a slowly changing and often confusing concept, beginning with the 1805 suggestion by a European panel of physicians that there are benign diseases which will always develop into invasive malignancy if left untreated long enough. Due to the continuing challenge and confusion surrounding oral precancer concepts, the World Health Organization (WHO) has periodically convened international workshops to redefine the term “precancer” and the various oral precancerous lesions. A workshop, held in London in 2005, actually recommended the elimination of the term “precancer” and the use of the presumably more illuminating term “potentially malignant lesions.”^[1] Potentially malignant disorder (PMD) is defined by the WHO (2005) as the risk of malignancy being present in a lesion or condition either at time of initial diagnosis or at a future date.^[2]

To date, no clear markers for distinguishing mild and moderate epithelial dysplasia have evolved, and histological criteria for diagnosing the grade of a “dysplastic” lesion are still subjective. Thus, there is a need to have a good, objective, quantifiable and consistently reproducible measure for epithelial dysplasia.

Nucleolar organizer regions (NORs) are loops of ribosomal DNA which occur in the nuclei of cells possessing the genes for synthesizing rRNA. These are situated in the nucleolus and are thought to reflect the proliferative activity of the cell. NORs can be demonstrated in tissue sections by staining their associated proteins with colloidal silver, and these silver-stained reaction products represent the argyrophilic nucleolar organizer regions (AgNORs).^[3]

The AgNOR count is an important index for the assessment of proliferating cells. In normal cells, the AgNORs are tightly packed in the nucleoli and are indiscernible. In rapidly proliferating cells such as neoplastic cells, nucleolar disaggregation may take place resulting in dispersion of individual AgNOR. Several studies have shown that AgNOR counts can be used to differentiate between benign and malignant lesions, whereas a few others have stated that it is the morphological characteristics of AgNOR that is more informative than their absolute numbers.^[4]

The present study is conducted to assess the cell proliferation and biologic aggressiveness of the premalignant lesions by

evaluating the significance of number and the dispersal pattern of AgNORs using the silver colloid technique.

“Special stains are wonderful. They allow us to see what we still do not recognize in a different color.”

Aim and objectives

The aim of the study was to assess the cell proliferation and biologic aggressiveness of the lesions by evaluating the significance of number and dispersal pattern of AgNORs using silver colloid technique in normal mucosa, premalignant and malignant lesions.

The objectives were:

- To determine the AgNOR counts in normal mucosa, oral submucous fibrosis (OSMF), leukoplakia and squamous cell carcinoma (SCC)
- To analyze the “type” or “pattern” of nucleolar organizer regions in OSMF, leukoplakia and oral SCC and its correlation with histological grading
- To assess the significance of the silver colloid technique and the importance of AgNORs as a diagnostic tool in determining the malignant potential of a lesion.

MATERIALS AND METHODS

The present study was conducted in the Department of Oral and Maxillofacial Pathology, Ahmedabad Dental College and Hospital, Ahmedabad. Material for the study consisted of 50 biopsy specimens that included histologically diagnosed cases as mentioned below. The lesions were previously histologically categorized into various grades of epithelial dysplasia according to the WHO grading criteria. It was graded as mild, moderate and severe dysplasia. Five biopsies from the normal buccal mucosa were included as control specimens.

The final study sample consisted of following groups:

- Group 1: The control group consisting of 5 individuals with healthy normal oral mucosa
- Group 2: Consisted of 10 individuals with histopathologically confirmed OSMF (mild dysplasia)
- Group 3: Consisted of 10 individuals with histopathologically confirmed OSMF (moderate dysplasia)
- Group 4: Consisted of 10 individuals with histopathologically confirmed oral leukoplakia (mild dysplasia)
- Group 5: Consisted of 10 individuals with histopathologically confirmed oral leukoplakia (moderate dysplasia)
- Group 6: Consisted of 10 individuals with histopathologically confirmed SCC.

The formalin-fixed tissues were processed by manual processing technique and the paraffin-embedded tissue specimens were sectioned using the soft-tissue microtome. Two sections of 4–6 μ in thickness were cut, of which one was stained with hematoxylin and eosin stain for histopathological analysis and the second one with silver nitrate for AgNOR counting and grading.

Argyrophilic nucleolar organizer region staining procedure

The sections were deparaffinized in xylene and hydrated through grades of alcohol to running water. The staining method followed was by Ploton *et al.* The sections were then reacted with freshly prepared silver colloidal solution (containing one part by volume of 2% gelatin in 1% formic acid and two parts by volume of 50% aqueous silver nitrate solution) in a closed Coplin jar for 40 min at room temperature, ensuring a dark environment throughout the reaction time. The silver colloidal solution was washed with distilled water. A modification to the Ploton’s techniques was carried. The sections were then treated with 5% sodium thiosulfate for 5 min and washed in distilled water, dehydrated through increasing grades of ethanol, cleared in xylene and mounted.

Argyrophilic nucleolar organizer region counting (quantitative assessment)

One hundred epithelial cells were counted in each specimen under × 100 oil immersion objective of the light microscope following a zigzag manner. A standardized mean for the enumeration of NORs in the histological sections was proposed by Crocker *et al.*^[5] By careful focusing, AgNOR dots were counted; both intranucleolar and extranucleolar dots were included in the counting regime and where two or more dots were so closely aggregated within a nucleolus that the precise number within the aggregate could not be counted, the aggregate was recorded as one. Where the closely aggregated dots were separated by a halo of nucleoplasm, the dots were counted separately.^[6]

Argyrophilic nucleolar organizer region types (qualitative assessment)

Three types of AgNOR products are identified in histological sections according to Warnakulasuriya and Johnson:^[7]

- AgNORs-Type I– Single or few large dots within the nucleus representing the nucleolus
- AgNORs Type II– Discrete small dots within the nucleolus
- AgNORs Type III– Fine black dots dispersed throughout the nucleoplasm.

Statistical analysis

The data collected were analyzed independently by two observers and the mean value was taken into account.

The software that was used for statistical analyses was SPSS® (Statistical Package for the Social Sciences); the associations between the attributes were tested using the “Student’s unpaired *t*-test.” Since this study involves multiple groups, one-way analysis of variance (ANOVA) was used.

RESULTS

Quantitative analyses

The AgNOR count was compared in various groups and the control. In normal epithelium, the mean AgNOR count was 1.69. A mean count of 2.29 in OSMF with mild dysplasia, 2.57 in leukoplakia with mild dysplasia, 2.66 in OSMF with moderate dysplasia, 2.76 in leukoplakia with moderate dysplasia and a mean value of 3.90

Table 1: Argyrophilic nucleolar organizer region count (mean) in different groups

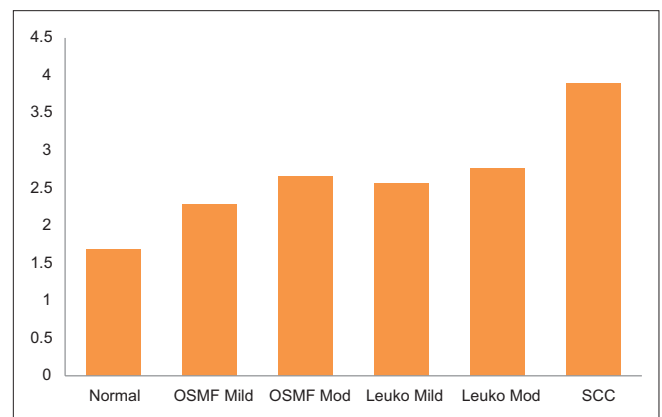
Groups/lesion	Sample size	Mean±SD	AgNOR range
Normal	5	1.69±0.15	1.51-1.84
OSMF (mild dysplasia)	10	2.29±0.19	2.05-2.75
Leukoplakia (mild dysplasia)	10	2.57±0.34	2.24-3.3
OSMF (moderate dysplasia)	10	2.66±0.39	2.22-3.5
Leukoplakia (moderate dysplasia)	10	2.76±0.25	2.43-3.3
Squamous cell carcinoma	10	3.90±0.40	3.36-4.78

One-way ANOVA $F=40.63$. $P=<0.001$ significant. SD: Standard deviation, AgNOR: Argyrophilic nucleolar organizer region, OSMF: Oral submucous fibrosis

Table 2: Statistical comparison of various groups with control

Groups compared	Mean±SD	<i>P</i> (<i>t</i> -test)
Normal	1.69±0.15	0.0001**
OSMF (mild dysplasia)	2.29±0.19	
Normal	1.69±0.15	0.0002**
OSMF (moderate dysplasia)	2.66±0.39	
Normal	1.69±0.15	0.0001**
Leukoplakia (mild dysplasia)	2.57±0.34	
Normal	1.69±0.15	0.001**
Leukoplakia (moderate dysplasia)	2.76±0.25	
Normal	1.69±0.15	0.001**
Squamous cell carcinoma	3.90±0.40	

$P<0.05$ (significant), ** $P<0.01$ (highly significant). SD: Standard deviation, OSMF: Oral submucous fibrosis



Graph 1: Argyrophilic nucleolar organizer region count (mean) in different groups

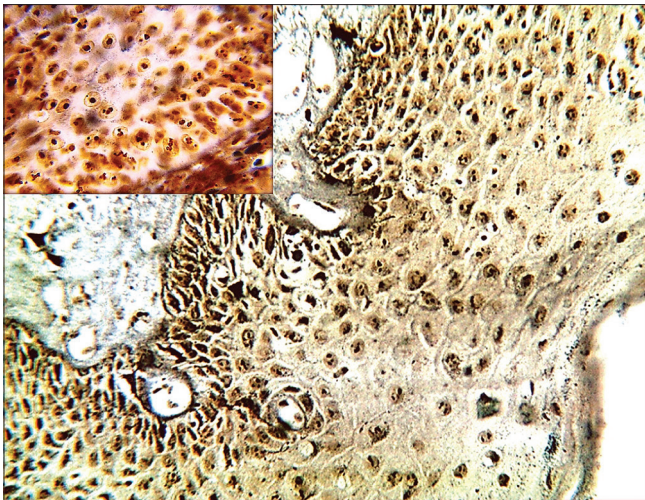


Figure 1: Photomicrograph of silver-stained section of oral submucous fibrosis with mild dysplasia (x40) and Inset (x100)

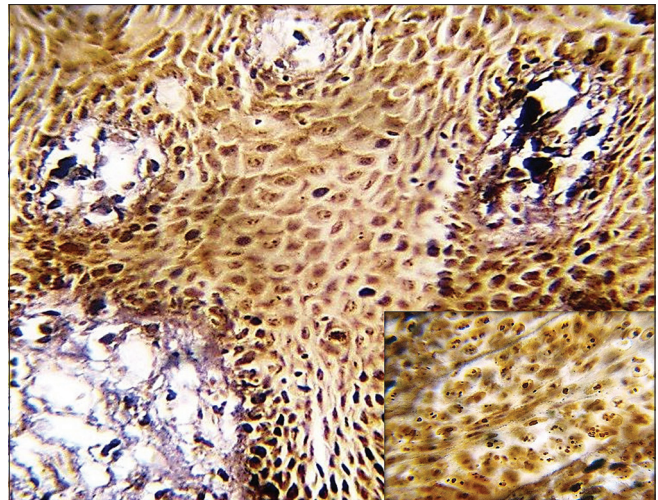


Figure 2: Photomicrograph of silver-stained section of leukoplakia with moderate dysplasia (x40) and Inset (x100)

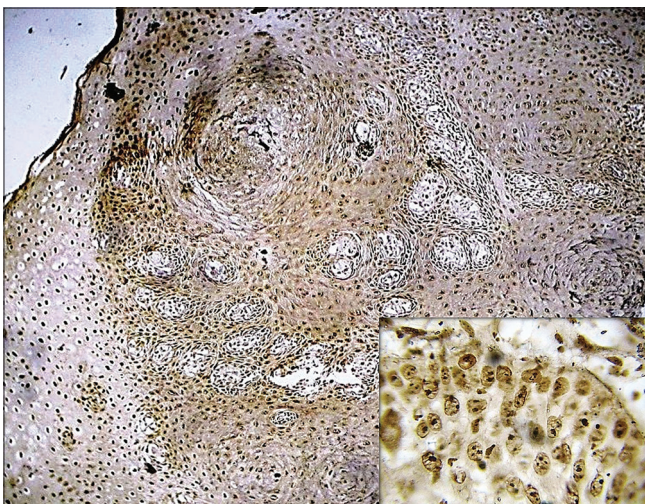


Figure 3: Photomicrograph of silver-stained section of well-differentiated squamous cell carcinoma (x40) and Inset (x100)

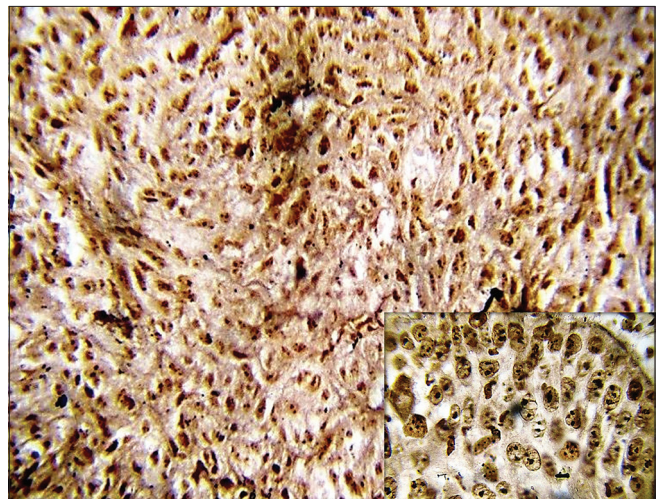


Figure 4: Photomicrograph of silver-stained section of moderately differentiated squamous cell carcinoma (x40) and Inset (x100)

was seen in SCC. It was observed that as the grade of dysplasia increased, the mean AgNOR count increased [Graph 1 and Figures 1-4].

Since this study involves multiple groups, one-way ANOVA was used for comparing the parameters for multiple groups, and the difference was found to be statistically significant ($F = 40.63, P \leq 0.001$) [Table 1].

All the groups were compared with the control group using the “Student’s *t*-test” and “*P*” values were obtained for the same as shown in Table 2.

OSMF with mild dysplasia was compared to that with moderate dysplasia; a statistically significant *P* value was obtained. Leukoplakia with mild dysplasia was compared to that with moderate dysplasia; a statistically nonsignificant

Table 3: Different argyrophilic nucleolar organizer region patterns in various groups (%)

Group	Type I (%)	Type II (%)	Type III (%)
Normal	57.6	41.9	0.5
OSMF (mild dysplasia)	30.1	66.65	3.25
OSMF (moderate dysplasia)	24.65	70.4	4.95
Leukoplakia (mild dysplasia)	16.55	78.3	5.15
Leukoplakia (moderate dysplasia)	15.8	75.85	8.35
Squamous cell carcinoma	9.85	72.25	17.9

OSMF: Oral submucous fibrosis

P value was obtained. OSMF with moderate dysplasia and leukoplakia with moderate dysplasia was compared to SCC and *P* value obtained was highly significant in both the cases.

Qualitative analyses

All the samples were analyzed qualitatively by the two observers. The morphological assessment of AgNORs was based on their size, shape and the pattern of distribution.

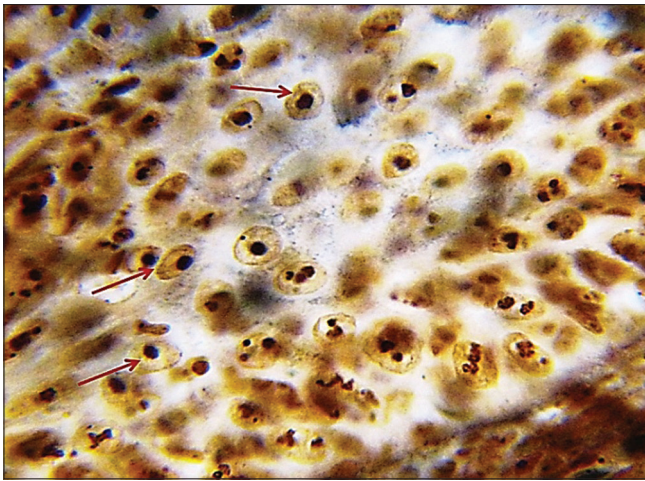


Figure 5: Photomicrograph of silver-stained section showing Type I argyrophilic nucleolar organizer region pattern (x100)

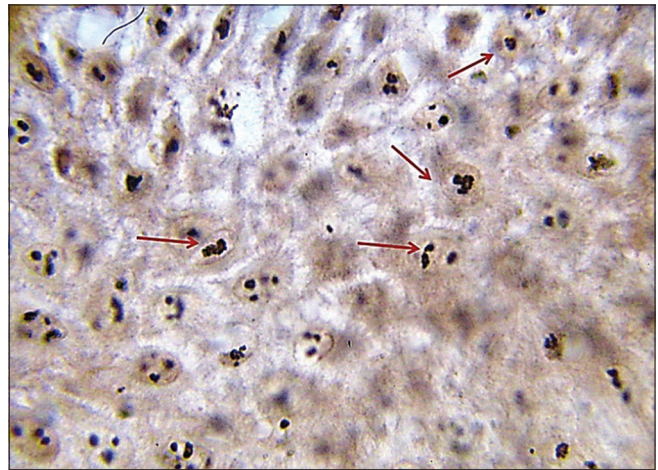


Figure 6: Photomicrograph of silver-stained section showing Type II argyrophilic nucleolar organizer region pattern (x100)

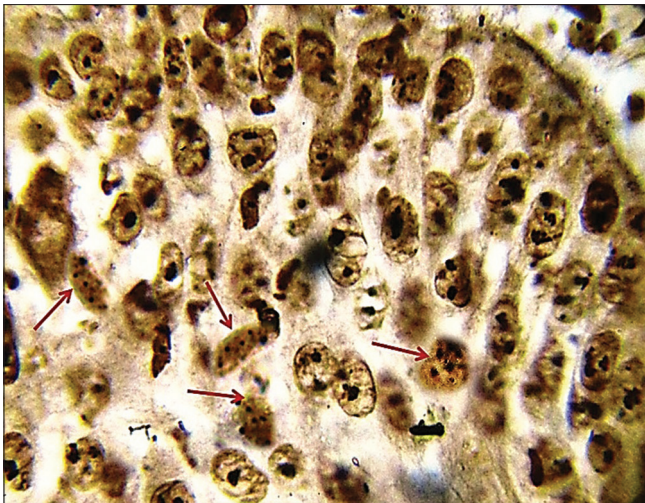
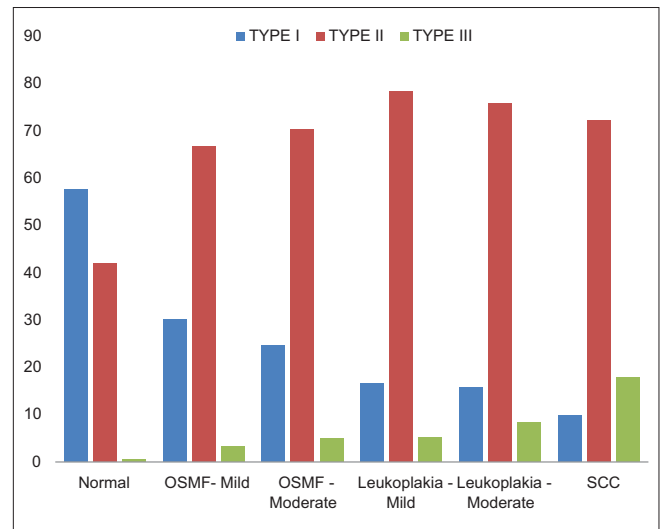


Figure 7: Photomicrograph of silver-stained section showing Type III argyrophilic nucleolar organizer region pattern (x100)



Graph 2: Comparison of the argyrophilic nucleolar organizer patterns in various groups

One hundred cells were assessed and categorized as Type I, II or III according to the patterns defined by Warnakulasuriya and Johnson.^[7]

The percentage of cells exhibiting AgNOR Type I, II and III pattern in all the groups are shown in Table 3. Different patterns of AgNOR i.e. Type I, II, III patterns observed in normal epithelium were 57.6%, 41.9% and 0.5%; 30.1%, 66.65% and 3.25% in OSMF with mild dysplasia; 24.65%, 70.4% and 4.95% in OSMF with moderate dysplasia; 16.55%, 78.3% and 5.15% in leukoplakia with mild dysplasia; 15.8%, 75.85% and 8.35% in leukoplakia with moderate dysplasia and 9.85%, 72.25% and 17.9%, respectively, in SCC.

It was observed that, as the grade of dysplasia increased, the incidence of Type III pattern increased, with SCC showing the maximum value (17.9%).

A comparison of the three AgNOR patterns in various study groups is well demonstrated in Graph 2 and Figures 5-7.

DISCUSSION

The histologic connotation to “pre malignancy” is marked by aberrant and uncoordinated cellular proliferation depicted basically at cellular level (atypia), reflections of which could be discerned at the tissue levels too (dysplasia).^[8] Dysplasia is basically a spectrum and no truly reproducible criteria exist to precisely divide the spectrum into mild, moderate and severe categories.^[9]

The presence of epithelial dysplasia as assessed by light microscopic examination is one of the various prognostic predictors of malignant transformation of

the PMD. Nevertheless, it is recognized that occasionally nondysplastic lesions may turn into cancer, while not all dysplastic lesions become malignant. Thus, the challenge within the field of oral precancer is to predict which lesions will eventually develop into carcinoma.^[9]

Mean AgNOR count in cases of OSMF with mild dysplasia was 2.28 ± 0.19 and that with moderate dysplasia was 2.66 ± 0.39 , respectively. Two cases reported an average AgNOR count being higher than that observed in cases of leukoplakia with moderate dysplasia suggesting the malignant potential of the lesion. Rajendran and Nair^[10] obtained a mean which was much higher than our observations. Type II AgNOR pattern was dominant in OSMF cases overall and Type III AgNOR dots were more in OSMF with moderate dysplasia than with mild dysplasia. Similar observations were made by Elangovan *et al.*,^[3] but in contrast, De Sousa *et al.*^[11] observed that most of the cases exhibited Type I pattern. Warnakulasuriya and Jhonson^[7] reported an admixture of all three types of patterns.

Mean AgNOR count in cases of leukoplakia with mild dysplasia was 2.57 ± 0.34 and that in moderate dysplasia was 2.76 ± 0.25 , respectively. Elangovan *et al.*,^[3] Mekhri *et al.*,^[4] Chattopadhyay and Ray^[12] and Kulkarni *et al.*^[13] reported a mean AgNOR count which corroborated our observations. Comparing the two grades, they were found to be statistically nonsignificant which was in contrast to Mekhri *et al.*^[4] who found them to be significant. Two lesions of moderate leukoplakia in the study had comparable and even higher AgNOR counts than some of the cases of malignant group. Type II pattern was the predominant one and Type III pattern was observed significantly higher in the moderate type. Elangovan *et al.*^[3] and Kulkarni *et al.*^[13] observed both Type I and Type II AgNOR patterns. Warnakulasuriya and Jhonson^[7] reported an admixture of all three types of patterns. Mekhri *et al.*^[4] and De Sousa *et al.*^[11] recorded Type I pattern which contradicted our observations.

The mean AgNOR count observed for SCC in the study was 3.90 ± 0.41 . Values obtained by Kulkarni *et al.*^[13] were comparable to our study. Warnakulasuriya and Jhonson,^[7] Mekhri *et al.*,^[4] Elangovan *et al.*^[3] and Rajendran and Nair^[10] reported a much higher mean which contradicted our study. De Sousa *et al.*^[11] recorded a mean value which was lower than our observations. Comparing the two grades of SCC, they were found to be statistically significant which was in harmony to Xie *et al.*^[14] and Elangovan *et al.*^[3] Observations by De Silva Fonseca *et al.*^[15] were in contrast, who found it to be statistically nonsignificant. Type II pattern was the predominant one, although the Type III pattern observed

was highest among all the study groups. Type III pattern exhibited an increase with the grade of SCC. This was in contrast to Elangovan *et al.*^[3] and Kulkarni *et al.*,^[13] who observed Type III pattern predominantly.

CONCLUSION

The following conclusions are drawn:

- The mean AgNOR count increased in the following ascending order: normal epithelium (1.69), OSMF with mild dysplasia (2.29), leukoplakia with mild dysplasia (2.57), OSMF with moderate dysplasia (2.66), leukoplakia with moderate dysplasia (2.76) and SCC (3.90). Thus, the AgNOR count increased with the increase in the grade of dysplasia
- The mean AgNOR count of each study group when compared to that of normal showed a positive statistical significance in each case
- The mean AgNOR count was higher in cases of oral SCC as compared to cases of OSMF with moderate dysplasia and leukoplakia with moderate dysplasia and showed a positive statistical significance
- The mean AgNOR count exhibited a positive statistical significance when OSMF with mild dysplasia was compared to that of moderate dysplasia
- No statistical significance was found between the mean AgNOR counts of leukoplakia with mild dysplasia and moderate dysplasia
- Type II AgNOR pattern was found to be the predominant one in all the samples
- Type III AgNOR pattern was found to be increasing with the increase in the grade of dysplasia, with SCC showing the highest percentage of cells demonstrating it.

Therefore, this method of quantification and analysis of its morphology can be used to provide information on the malignant potentiality in premalignant lesions and aggressiveness of the malignant lesions. Multiple larger studies need to be carried out to substantiate the effectiveness of this method in determining the aggressiveness of the PMD.

Financial support and sponsorship

Nil.

Conflicts of interest

There are no conflicts of interest.

REFERENCES

1. Bouquot JE, Suarez P, Vigneswaran N. Oral precancer and early cancer detection in the dental office – Review of new technologies. J Implant

- Adv Clin Dent 2010;2:47-63.
- George A, Sreenivasan BS, Sunil S, Varghese SS, Thomas J, Gopakumar D, *et al.* Potentially malignant disorders of oral cavity. *Oral Maxillofac Pathol J* 2011;2:95-100.
 - Elangovan T, Mani NJ, Malathi N. Argyrophilic nucleolar organizer regions in inflammatory, premalignant, and malignant oral lesions: A quantitative and qualitative assessment. *Indian J Dent Res* 2008;19:141-6.
 - Mekhri S, Iyenger AR, Nagesh KS, Bharati MB. Analysis of cell proliferation rate in oral leukoplakia and oral squamous cell carcinoma. *J Clin Exp Dent* 2010;2:173-7.
 - Crocker J, Boldy DA, Egan MJ. How should we count AgNORS? Proposals for a standardized approach. *J Pathol* 1989;158:185-8.
 - Coleman HG, Altini M, Groeneveld HT. Nucleolar organizer regions (AgNORs) in odontogenic cysts and ameloblastomas. *J Oral Pathol Med* 1996;25:436-40.
 - Warnakulasuriya KA, Johnson NW. Nucleolar organiser region (NOR) distribution as a diagnostic marker in oral keratosis, dysplasia and squamous cell carcinoma. *J Oral Pathol Med* 1993;22:77-81.
 - Rajendran R. Oral leukoplakia (leukokeratosis): Compilation of facts and figures. *J Oral Maxillofac Pathol* 2004;8:58-68.
 - Brennan M, Migliorati CA, Lockhart PB, Wray D, Al-Hashimi I, Axéll T, *et al.* Management of oral epithelial dysplasia: A review. *Oral Surg Oral Med Oral Pathol Oral Radiol Endod* 2007;103 Suppl:S19. e1-12.
 - Rajendran R, Nair SM. Silver-binding nucleolar organizer region proteins as a possible prognostic indicator in oral submucous fibrosis. *Oral Surg Oral Med Oral Pathol* 1992;74:481-6.
 - de Sousa FA, Paradella TC, Carvalho YR, Rosa LE. Comparative analysis of cell proliferation ratio in oral lichen planus, epithelial dysplasia and oral squamous cell carcinoma. *Med Oral Patol Oral Cir Bucal* 2009;14:e563-7.
 - Chattopadhyay A, Ray JG. AgNOR cut-point to distinguish mild and moderate epithelial dysplasia. *J Oral Pathol Med* 2008;37:78-82.
 - Kulkarni S, Mody RN, Jindal S, Sohi RS, Kaur B. Silver binding nucleolar organiser regions in oral submucous fibrosis, lichen planus, leukoplakia and squamous cell carcinoma. *J Cancer Res Exp Oncol* 2009;1:15-9.
 - Xie X, Clausan EP, Sudbo J, Boysen M. Diagnostic and prognostic value of nucleolar organizer regions in normal epithelial, dysplasia and squamous cell carcinoma of the oral cavity. *Cancer* 1997;79:2200-8.
 - Fonseca LM, do Carmo MA. AgNORs in hyperplasia, papilloma and oral squamous cell carcinoma. *Braz Dent J* 2000;11:105-10.