

LETTER TO THE EDITOR

Radiation Recall Dermatitis after Treatment with Paclitaxel and Cisplatin

Seung Woo Baek, M.D., Young Joon Seo, M.D.¹, Jun Sang Kim, M.D.², Hyo Jin Lee, M.D.

Departments of Internal Medicine, ¹Dermatology, ²Radiation Oncology, Chungnam National University Hospital, Chungnam National University College of Medicine, Daejeon, Korea

Dear Editor:

A 53-year-old man with recurrent penile carcinoma presented to his physician with an erythematous rash and pruritus. The patient had undergone a partial penectomy for the treatment of penile squamous cell carcinoma in 2002. Seven years later, he presented with penile stump and inguinal masses, and underwent a total penectomy and right superficial inguinal lymph node dissection. The histologic examination of the enlarged lymph node showed evidence of metastasis. At that time, a bilateral inguinal and pelvic lymphadenectomy was considered, but the patient refused it because of the significant risk of morbidity. As an alternative treatment, he received radiotherapy of 7,020 cGy. Four months later, he was referred for palliative chemotherapy due to disease progression. The patient was to be treated with paclitaxel 175 mg/m² and cisplatin 70 mg/m² every three weeks. Five days after the initiation of chemotherapy, he developed an erythematous rash with pruritus in the lower abdomen and pelvis which was compatible with the previous radiation field (Fig. 1). The diagnosis of radiation recall dermatitis was made based on the clinical history and appearance of the tissue. This observed skin change resolved completely with oral prednisolone and antihistamine over a course of six days. After a discussion with the patient, the paclitaxel and

cisplatin were continued with close observation of his skin reaction. The skin alterations reappeared to a milder degree than that observed with the initial occurrence. The patient completed six scheduled cycles of palliative chemotherapy with a partial response.

Radiation recall dermatitis refers to the reappearance of radiotherapy-like reactions in previously irradiated skin after the administration of drugs, especially chemo-

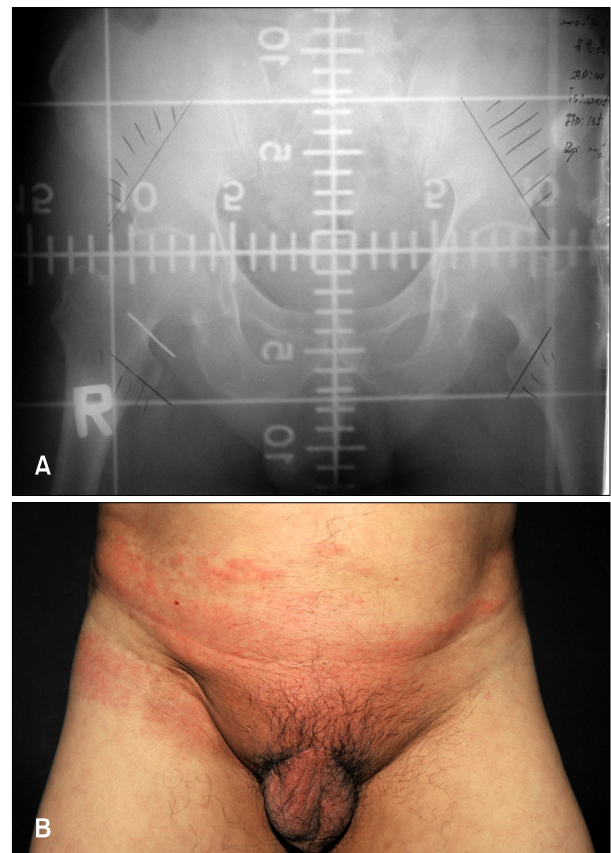


Fig. 1. (A) Radiotherapy plan and (B) dermatitis observed in irradiated skin.

Received March 28, 2011, Revised June 29, 2011, Accepted for publication July 5, 2011

Corresponding author: Hyo Jin Lee, M.D., Department of Internal Medicine, Chungnam National University Hospital, 640 Daesa-dong, Jung-gu, Daejeon 301-721, Korea. Tel: 82-42-280-8369, Fax: 82-42-257-5753, E-mail: cymed@cnu.ac.kr

This is an Open Access article distributed under the terms of the Creative Commons Attribution Non-Commercial License (<http://creativecommons.org/licenses/by-nc/3.0>) which permits unrestricted non-commercial use, distribution, and reproduction in any medium, provided the original work is properly cited.

therapeutic agents or antibiotics^{1,2}. It was first described by D'Angio et al.³ in 1959 with actinomycin D treatment. Subsequently, anticancer drugs have been associated with this phenomenon, including 5-fluorouracil, hydroxyurea, vinblastine, methotrexate, adriamycin, etoposide, tamoxifen, bleomycin, paclitaxel, docetaxel, gemcitabine, pemetrexed, trastuzumab, and erlotinib⁴⁻⁸. In our case, both paclitaxel and cisplatin could precipitate a radiation recall reaction because each drug was reported to be associated with the development of radiation recall dermatitis⁹. Although numerous organs can be affected, this phenomenon is rare and most reports describe the appearance of skin lesions. The time interval between the end of radiotherapy and the administration of the drug responsible for the cutaneous reaction can range from two days to 15 years, although the most frequent interval is several weeks or months, as reported in our case study. The typical skin lesion consists of a maculopapular rash, edema, erythema, vesicles, or desquamation. Pruritus is usually present, while pain and skin necrosis are possible in severe cases^{1,4,8}. The pathophysiology of this phenomenon remains poorly understood, although several hypotheses involving epithelial stem cell deficiency, vascular damage, drug hypersensitivity, or epithelial stem cell sensitivity have been proposed^{4,8}. Discontinuation of the responsible drug usually results in the resolution of radiation dermatitis. Steroids and antihistamines control the pruritus and pain. Repeat challenge with the offending drug may provoke another recall reaction, but this is not usually the case. Usually, the recurrence of radiation recall dermatitis presents with milder clinical signs than the original episode. However, the main question is still whether chemotherapy should be

continued after the first manifestation of radiation recall dermatitis, especially if there is a limited choice of available drugs. The decision should consider the benefits and potential risks of re-challenge with the same drug¹⁰. Considering the increased use of combination radiotherapy and chemotherapy in the treatment of malignant disease, clinicians need improved knowledge of radiation recall dermatitis and its management.

REFERENCES

1. Bronner AK, Hood AF. Cutaneous complications of chemotherapeutic agents. *J Am Acad Dermatol* 1983;9:645-663.
2. Kang SK. Images in clinical medicine. Radiation recall reaction after antimicrobial therapy. *N Engl J Med* 2006;354:622.
3. D'Angio GJ, Farber S, Maddock CL. Potentiation of x-ray effects by actinomycin D. *Radiology* 1959;73:175-177.
4. Hureaux J, Le Guen Y, Tuchais C, Savary L, Urban T. Radiation recall dermatitis with pemetrexed. *Lung Cancer* 2005;50:255-258.
5. Shrimali RK, McPhail NJ, Correa PD, Fraser J, Rizwanullah M. Trastuzumab-induced radiation recall dermatitis—first reported case. *Clin Oncol (R Coll Radiol)* 2009;21:634-635.
6. Dauendorffer JN, Dupuy A. Radiation recall dermatitis induced by erlotinib. *J Am Acad Dermatol* 2009;61:1086.
7. Khanfir K, Anchisi S. Pemetrexed-associated radiation recall dermatitis. *Acta Oncol* 2008;47:1607-1608.
8. Camidge R, Price A. Characterizing the phenomenon of radiation recall dermatitis. *Radiother Oncol* 2001;59:237-245.
9. Burris HA 3rd, Hurtig J. Radiation recall with anticancer agents. *Oncologist* 2010;15:1227-1237.
10. Ristić B. Radiation recall dermatitis. *Int J Dermatol* 2004;43:627-631.