

Exceptional Case

Sarcoidosis presenting as severe renin-dependent hypertension due to kidney vascular injury

Cedric Rafat¹, Guillaume Bobrie¹, Antoine Chedid¹, Dominique Nochy², Anne Hernigou³ and Pierre-François Plouin¹

¹Hypertension Unit, Université Paris Descartes, Assistance Publique-Hôpitaux de Paris, Hôpital Européen Georges Pompidou, Paris Cedex 15, France, ²Department of Pathology, Université Paris Descartes, Assistance Publique-Hôpitaux de Paris, Hôpital Européen Georges Pompidou, Paris Cedex 15, France and ³Department of Radiology, Université Paris Descartes, Assistance Publique-Hôpitaux de Paris, Hôpital Européen Georges Pompidou, Paris Cedex 15, France

Correspondence and offprint requests to: Cédric Rafat; E-mail: cedric.rafat@egp.aphp.fr

Abstract

Renal sarcoidosis embraces a wide variety of clinical patterns. Renal vascular involvement has seldom been reported and usually in the setting of systemic vasculitis. We report the case of a 22-year-old patient in whom inaugural manifestation of renal sarcoidosis consisted of severe hypertension associated with bilateral perfusion defects and tumour-like nodules. In the setting of renal sarcoidosis, our case suggests that renin-dependant hypertension may arise from renal ischaemia as a result of extrinsic compression of kidney blood vessels due to severe granulomatous inflammation.

Keywords: granulomatous vasculitis; hypertension; sarcoidosis; secondary hyperaldosteronism; tubulointerstitial nephritis

Background

Sarcoidosis is a multisystem disease of undetermined cause which is characterized by the widespread presence of non-caseating granuloma [1]. Autopsy-based series report prevalence rates of renal involvement between 7 and 27%, and the disease is well known for its protean manifestations [2–4]. Two non-mutually exclusive clinical and pathological patterns account for the great bulk of renal sarcoidosis, namely (i) nephrolithiasis and/or nephrocalcinosis-related to hypercalcaemia and hypercalciuria and (ii) interstitial nephritis with or without granulomatous formation [5, 6]. In contrast, renal vascular involvement is believed to be an exceptional complication of sarcoidosis and extensive retrospective series have failed to document any such complication [5, 6]. Likewise, renal imaging findings are scanty and, if present, usually restricted to nephrocalcinosis, striated nephrograms or urinary tract obstruction [7–9]. Here we report the case of a 22-year-old patient in whom the manifestation of renal sarcoidosis consisted of severe hypertension associated with bilateral vascular lesions and granulomatous interstitial nephritis.

Case presentation

Clinical history

A 22-year-old white woman with a medical history of idiopathic epilepsy and sarcoidosis was referred to our

institution for severe hypertension. Two years previously, she had presented an episode of spontaneously remitting bilateral uveitis. Six months before her referral to our institution she had been diagnosed with sarcoidosis during the follow-up of clinical features consistent with Löfgren's syndrome. During diagnostic work-up, blood pressure (BP) was shown to be within normal ranges (128/66 mmHg). Corticosteroid therapy was considered unnecessary at that point and symptoms resolved within a couple of weeks. Upon admission in our department, the patient's BP was 169/123 mmHg under therapy of diltiazem 200 mg LP once daily, without clinical or echocardiographic repercussions. No previous exposure to drugs known to cause hypertension was noted. Echocardiography showed normal levels of pulmonary artery systolic pressure (26 mmHg). Serum creatinine (SCr) was normal (68 µmol/L, i.e. eGFR = 98 mL/min/1.73 m², using the 4-variable MDRD [Modification of Diet in Renal Disease]) formula. Haematuria and urine infection were excluded by dipstick examination and microalbuminuria was within physiological ranges (8 mg/L). Hormonal investigations, carried out under euvolaemic conditions, substantiated secondary hyperaldosteronism with elevated levels of plasma renin and aldosterone levels in the supine (75 mU/L and 31 ng/dL; reference ranges 10–25 and 2.8–14.4, respectively) and upright positions (298 mU/L; and 2919 ng/dL; reference ranges 15–50 and 200–1000). The 24-h urine aldosterone levels were high (2487 ng/24 h; reference range 505–1694). Additional testing evidenced elevated levels of 25(OH) Vitamin D3 (85 nmol/L; reference range 11–57) but normal values of calcaemia (2.27 mmol/L), calcium urinary excretion

(2.42 mmol/L) and angiotensinogen-converting enzyme (11 mU/mL). An abdominal computed tomography scan (CT) revealed multiple bilateral wedge- and nodular-shaped hypo-dense foci affecting the renal cortex and medulla (Figure 1), with no evidence of urinary tract obstruction. The renal arteries were deemed normal. Small mesenteric lymph nodes were noted. Renal angiography was prompted by persistent suspicion of underlying renal ischaemia: multiple cortical and sub-cortical vascular defects were evidenced in both kidneys (Figure 2). In view of the equivocal nature of the lesions, a renal biopsy was carried out. Upon light microscopy, granulomatous inflammation was found around tubes and arterioles and interlobular arteries. There were no signs of vessel destruction or of small-vessel angitis in this specimen, and the rest of the examination was unremarkable (Figure 3).

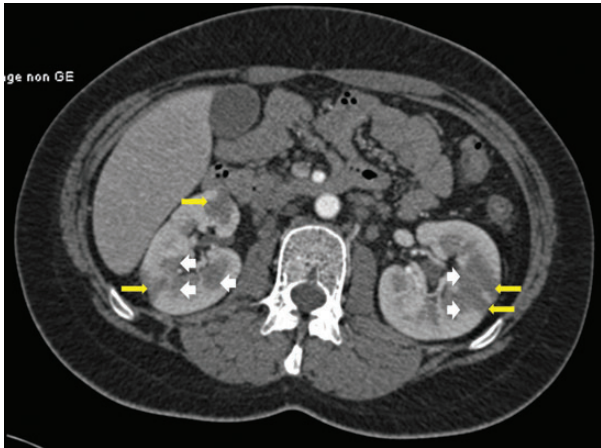


Fig. 1. Transverse contrast-enhanced abdominal CT during corticomedullary acquisition time displaying multiple, low-attenuation wedge-shaped foci seated in the cortex of both kidneys (yellow arrows) and low-attenuation corticomedullary nodules (white arrowheads) also present in both kidneys.

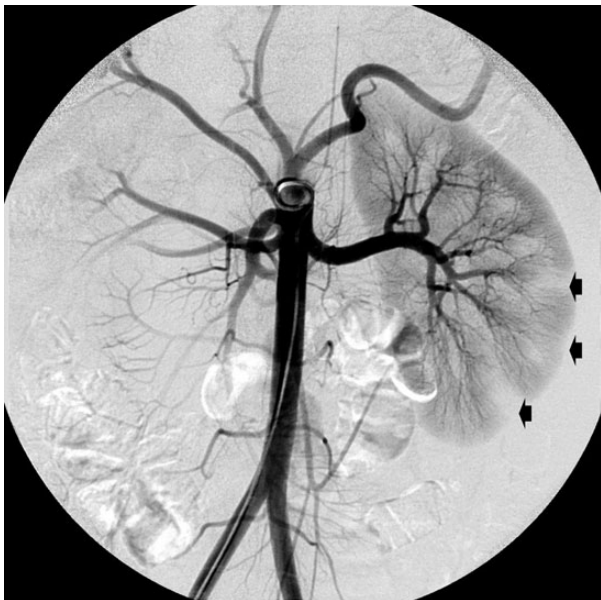


Fig. 2. Selective left kidney angiography showing multiple cortical and sub-cortical vascular defects (black arrows). Note the patent left renal artery.

Follow-up

The patient was subsequently started on tapering doses of prednisone (1 mg/kg/day) and ramipril (5 mg once daily). BP control was achieved and SCr remained stable (SCr, 68 $\mu\text{mol/L}$; eGFR, 98 mL/min/1.73 m²). An abdominal MRI performed 9 months after the initiation of corticosteroid therapy exhibited only minimal cortical defects in both kidneys whereas the lesions located in the medulla had receded. Two years following the patient's initial referral and progressive corticosteroid tapering, the patient presented with a recurrent bout of uveitis. Concurrently, renal impairment was evidenced (SCr, 126 $\mu\text{mol/L}$; eGFR, 45 mL/min/1.73 m²). Corticosteroids were reinitiated but proved to be unsuccessful as the patient's kidney function failed to improve during the following year. Three years after initial referral, CT imaging (Figure 4) substantiated major bilateral cortical atrophy, predominant in the right kidney. Both kidneys displayed irregular contours with focal areas of cortical thinning where vascular defects had previously been noted (white arrowheads). There were also multiple left lateral aortic

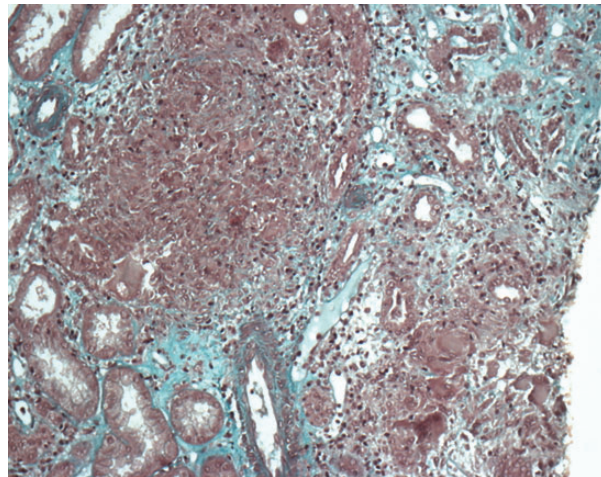


Fig. 3. First renal biopsy demonstrating the presence of sarcoidotic granulomatous inflammation in the vicinity of two normal interlobular arteries (Masson trichrome, original magnification $\times 200$).

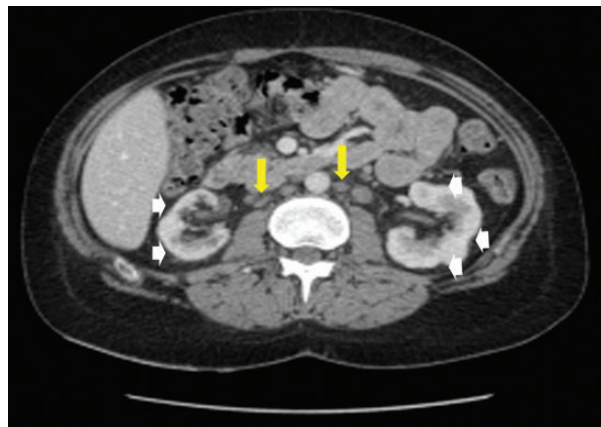


Fig. 4. Transverse contrast-enhanced abdominal CT during corticomedullary acquisition showing major bilateral kidney atrophy, predominant in the right kidney. Both kidneys displayed irregular contours with focal areas of cortical thinning where vascular defects had previously been noted (white arrowheads). Note the presence of multiple left lateral aortic and caval lymph nodes (yellow arrows).

and caval lymph nodes, of increased size compared with the reference CT. A repeat biopsy examination disclosed widespread interstitial fibrosis, arteriosclerosis and glomerulosclerosis.

Discussion

This case reports an unusual presentation of renal sarcoidosis with prominent clinical features consisting of severe hypertension with bilateral vascular injury. Despite a history strongly suggestive of sarcoidosis, renal biopsy was carried out because of the indeterminate aspect of the renal lesions on imaging. Indeed, the presence of nodular corticomedullary-located hypodense foci entertained the possibility of a coexisting tumoural process. Only sparse case reports have documented this rare pseudonodular presentation [9–13]. In the even fewer instances where a renal biopsy was conducted, this lesional pattern was almost invariably related to extensive sarcoid granulomatous inflammation as in our case [11–13]. Renal sarcoidosis is usually associated with marked renal impairment on presentation [6]. Nevertheless, in three cases of bilateral, ‘pseudotumoral’, renal sarcoidosis (out of a total of four reports) the initial kidney function was shown to be normal as in the case presented here [13–15].

Renal pathology examination was also motivated by the triangular-shaped lesions located in the cortex which could be interpreted as post-ischaemic or evidence of infectious insults. Renal angiography ultimately confirmed the suspicion of renal ischaemia by demonstrating multiple vascular voids in the renal cortex and sub-cortex. Although no pathological process involving the renal arterioles could be demonstrated on pathology, this may be ascribed to a sampling bias given the focal distribution of the

renal perfusion defects. We postulate that renal ischaemia arose from granulomatous inflammation via extrinsic compression. Regardless of the underlying mechanism, this process caused severe hypertension associated with secondary hyperaldosteronism and, *in fine*, widespread glomerular ischaemia and tubulointerstitial fibrosis.

Although sarcoidosis is known to embrace a wide variety of clinical and pathological manifestations (Table 1), this case is different from the other rarely reported clinical patterns consisting of severe hypertension associated with small and medium-vessel injury [16]. Aside from its rarity, sarcoidosis-induced vascular injury has been shown to involve all types of renal vessels. In most cases, renal vascular damage is but one of the multiple manifestations of multisystem vasculitis, a rare life-threatening complication associated with sarcoidosis. In the case of small and medium-sized vascular involvement, the prominent clinical features also include pulmonary angitis, cerebral vasculitis and skin sarcoidosis consistent with leukocytoclastic vasculitis and granulomatous vasculitis [17, 18]. Large vessel damage may either present as renal artery stenosis with concurring severe hypertension [19] or aortic and renal aneurysms placing patients at high risk of subsequent rupture [18, 20]. In stark contrast, at no point of the disease process did we record any extra-renal vascular involvement. Furthermore, vascular wall involvement with elastic lamina dissolution—as exemplified by previous case reports—was not observed on pathological examination in our case [17, 21].

Corticosteroids are regarded as the mainstay of renal sarcoidosis and retrospective studies have highlighted their effectiveness [22]. However, several pitfalls should be kept in mind: (i) reversal of renal impairment is not universal and some patients may require other immunosuppressive therapy such as azathioprine and mycophenolate

Table 1. Summary of clinical and pathological patterns of renal sarcoidosis

Pattern and/or cause of renal injury	Frequency	Renal function on presentation	Prominent laboratory features	Pathological findings on kidney biopsy	Abdominal Imaging findings (on CT scan)
Granulomatous or non-granulomatous tubulointerstitial nephritis	+++	Altered, severe impairment is frequent	Mild proteinuria, microhematuria, Sterile leukocyturia, +/- renal tubular acidosis +/- Fanconi syndrome	Tubulo-interstitial nephritis +/- non necrotizing granuloma with epithelioid-like giant cells +/- Schaumann bodies	Normal ++ Striated nephrogram +/- Pseudotumoral renal masses (rare)
Nephrocalcinosis/nephrolithiasis	++	Altered, severe impairment is frequent	Hypercalcaemia, Hypercalciuria, Elevated levels of 1-25(OH)vitD3 +/-renal tubular acidosis +/- Fanconi syndrome	Intratubular and peritubular aggregation of calcium	Intrarenal calcifications +/- Urinary obstruction
Glomerular disease	Rare	Generally normal, mild to moderate impairment is possible	Nephrotic range proteinuria	Membranous nephritis ^a +++ IgA nephritis ^a ++	NR
Renal vascular involvement	Very rare	?	?	Coexisting GIN Granuloma-associated vascular injury	Renal artery stenosis or aneurysm Small- and medium-vessel occlusion Multisystem vascular involvement
Retroperitoneal fibrosis	Very rare	?	?	NR	Bilateral ureterohydronephrosis Large and widespread lymph nodes

?, No consistent data given the small number of cases; a, most frequently described glomerular patterns; GIN, granulomatous interstitial nephritis; NR, not relevant.

mofetil, (ii) residual renal failure is common, and not all patients regain their baseline renal function, (iii) relapses are frequent on corticosteroid weaning although patients may respond on reinitiation of therapy and (iv) response to therapy is negatively correlated to the extent of renal fibrosis [6, 22]. Our case illustrates the three latter points. Relapse of renal sarcoidosis was manifest 2 years after the patient's initial referral. However, by the time repeat imaging and biopsy were carried out the bilateral hypodense lesions thought to indicate the presence of granulomatous inflammation had resolved. Instead, these lesions had given way to extensive renal fibrosis and the reintroduction of corticosteroids was of no avail.

Conclusion

Renal sarcoidosis encompasses a broad range of clinical, imaging and pathological patterns. Our case conveys further evidence that hypodense renal masses upon CT imaging may be regarded as a possible, albeit rare, manifestation of sarcoidosis. It also suggests that renal ischaemia and hypertension may arise via extrinsic compression from granulomatous inflammation in the absence of renal or extra-renal vasculitis. The occurrence of severe hypertension in a patient with a history of sarcoidosis should urge physicians to consider this complication.

Author's contributions

G.B., A.C., P.F.P. were involved in the clinical management of the case. A.H. and D.N. provided the expertise in the imaging and histopathological examinations, respectively. C.R. undertook the data collection and analysis as well as the initial drafting of the report. All other authors critically reappraised the draft. All authors have read and approved the final version of the manuscript.

Conflict of interest statement. None declared.

References

1. Newman LS, Rose CS, Maier LA. Sarcoidosis. *N Engl J Med* 1997; 336: 1224–1234
2. Ricker W, Clark M. Sarcoidosis; a clinicopathologic review of 300 cases, including 22 autopsies. *Am J Clin Pathol* 1949; 19: 725–749
3. Longcope WT, Freiman DG. A study of sarcoidosis; based on a combined investigation of 160 cases including 30 autopsies from The Johns Hopkins Hospital and Massachusetts General Hospital. *Medicine (Baltimore)* 1952; 31: 1–132

4. Kettritz R, Goebel U, Fiebeler A et al. The protean face of sarcoidosis revisited. *Nephrol Dial Transplant* 2006; 21: 2690–2694
5. Hannedouche T, Grateau G, Noel LH et al. Renal granulomatous sarcoidosis: report of six cases. *Nephrol Dial Transplant* 1990; 5: 18–24
6. Mahevas M, Lescure FX, Boffa JJ et al. Renal sarcoidosis: clinical, laboratory, and histologic presentation and outcome in 47 patients. *Medicine (Baltimore)* 2009; 88: 98–106
7. Folz SJ, Johnson CD, Swensen SJ. Abdominal manifestations of sarcoidosis in CT studies. *J Comput Assist Tomogr* 1995; 19: 573–579
8. Koyama T, Ueda H, Togashi K et al. Radiologic manifestations of sarcoidosis in various organs. *Radiographics* 2004; 24: 87–104
9. Goldsmith S, Harris M, Scherer K et al. Sarcoidosis manifesting as a pseudotumorous renal mass. *J Radiol Case Rep* 2013; 7: 23–34
10. Herman TE, Shackelford GD, McAlister WH. Pseudotumorous sarcoid granulomatous nephritis in a child: case presentation with sonographic and CT findings. *Pediatr Radiol* 1997; 27: 752–754
11. Heldmann M, Behm W, Reddy MP et al. Pseudotumorous renal sarcoid: MRI, PET, and MDCT appearance with pathologic correlation. *AJR Am J Roentgenol* 2005; 185: 697–699
12. Ardalan M, Esmaili H. Renal mass: a confusing feature of sarcoidosis. *Ren Fail* 2012; 34: 661–663
13. Mizunoe S, Yamasaki T, Tokimatsu I et al. Sarcoidosis associated with renal masses on computed tomography. *Intern Med* 2006; 45: 279–282
14. Lockhart ME, Smith JK, Kenney PJ et al. Pseudotumorous renal involvement of sarcoidosis. *J Urol* 2001; 165: 895
15. Hughes JJ, Wilder WM. Computed tomography of renal sarcoidosis. *J Comput Assist Tomogr* 1988; 12: 1057–1058
16. Coburn JW, Hobbs C, Johnston GS et al. Granulomatous sarcoid nephritis. *Am J Med* 1967; 42: 273–283
17. Agrawal V, Crisi GM, D'Agati VD et al. Renal sarcoidosis presenting as acute kidney injury with granulomatous interstitial nephritis and vasculitis. *Am J Kidney Dis* 2012; 59: 303–308
18. Fernandes SR, Singen BH, Hoffman GS. Sarcoidosis and systemic vasculitis. *Semin Arthritis Rheum* 2000; 30: 33–46
19. Gross KR, Malleson PN, Culham G et al. Vasculopathy with renal artery stenosis in a child with sarcoidosis. *J Pediatr* 1986; 108(5 Pt 1): 724–726
20. Hatta T, Tanda S, Kusaba T et al. Sarcoid granulomatous interstitial nephritis and sarcoid abdominal aortic aneurysms. *Nephrol Dial Transplant* 2005; 20: 1480–1482
21. Bottcher E. Disseminated sarcoidosis with a marked granulomatous arteritis. *Arch Pathol* 1959; 68: 419–423
22. Rajakariar R, Sharples EJ, Raftery MJ et al. Sarcoid tubulointerstitial nephritis: long-term outcome and response to corticosteroid therapy. *Kidney Int* 2006; 70: 165–169

Received for publication: 6.4.14; Accepted in revised form: 27.5.14