

Partial splenic embolization for refractory thrombocytopenia

Irwin M. Best

Emory University School of Medicine,
Department of Radiology, Interventional
Radiology, Atlanta, GA, USA

Abstract

When the platelet count falls below $20 \times 10^9/L$, the risk of spontaneous life threatening hemorrhage is concerning for both physician and patient. When medical management fails, splenectomy is often used to manage the severe thrombocytopenia before spontaneous, life-threatening gastrointestinal or intracranial bleeding occurs. We present the non surgical management of such a patient with refractory severe thrombocytopenia who refused surgical intervention. She underwent partial splenic embolic therapy with 500-700 μ particles. Her platelet count spontaneously recovered from less than $20 \times 10^9/L$ to normal range. Her counts remained in normal range after discharge home. Further study is needed to determine the most appropriate role for embolization in patients who are refractory to medical management and those with chronically low platelet counts requiring frequent plate transfusions for invasive procedures.

Introduction

In the USA there are about 50-66 cases per million children in children usually less of idiopathic thrombocytopenic purpura (ITP) 10 years of age and in adults between 20-50 years old respectively. In children the disease is acute and regresses spontaneously in about 80% of cases. Unfortunately for adults the disease is more likely to take a chronic course. In both child and adult, steroid therapy is the first line treatment when patient become symptomatic or appear to be at risk for severe bleeding complications. When medical management fails about 80% will have a complete response to splenectomy. However, elderly patients have higher failure rates for both medical management and splenectomy. In selected series, splenic embolization has been used in preparation for surgery but in the following case partial splenic embolization was used as the definitive therapy since the patient rejected surgery. The technique and short term results are presented.

Case Report

An 80-year-old woman with a recent diagnosis of ITP had initially been treated with steroids but became intolerant to steroid therapy while treated at another hospital and then as an outpatient. When her condition worsened and her skin was covered with petechiae, she was admitted to the second hospital. Upon admission, her platelet count was less than $20 \times 10^9/L$. There were no other signs of hemorrhage. Computed tomography of the head was negative for occult hemorrhage. Despite multiple platelet transfusions, her platelet count could not be maintained above $20 \times 10^9/L$. She refused a surgical splenectomy. Consultation was requested for splenic artery embolization.

A celiac angiogram was performed from a right femoral artery approach using a 5F introducer sheath and a Cobra 2 glide catheter to define the arterial anatomy (Figure 1). The glide catheter was advanced into the splenic artery beyond the major tributaries to the pancreas (Figure 2). Partial embolization was performed with 500-700 μ Embosphere particles (Merit Medical Systems, Inc., South Jordan, Utah, USA). Note a reduced flow of contrast into the splenic branches in (Figure 3).

Results

Two platelet packs were administered after the splenic embolization. The right femoral introducer sheath was removed without complication. After 48 h the platelet count rose above $60 \times 10^9/L$. She was discharged home on the third post procedure day. Her platelet count was above $150 \times 10^9/L$ at four weeks post operatively at her follow-up visit. She was followed up by her local physician and had no further problems.

Discussion

Idiopathic thrombocytopenic purpura also known as primary immune thrombocytopenia occurs in the presence of normal bone marrow and no identifiable causal agent or disease process. This condition was first described in two young girls with epistaxis and purpura by Dr. Paul Gottlieb Werlhof in Germany in 1735.¹ Spontaneous intracranial bleeding is a dreaded complication of ITP when platelet count falls below $30 \times 10^9/L$. The overall mortality is about 2% in patients less than 40 years. However, in a risk adjusted Markov model of over 1817 patients from series reported in the medical literature, Cohen et al calculated a 47.8% 5-year mortality for patients older than

Correspondence: Irwin M. Best, Emory University, School of Medicine, Department of Radiology, Interventional Radiology, 1364 Clifton Road NE, Atlanta, GA 30322, USA.
Tel. +1.404.712.7033 - Fax +1.404.712.7970.
E-mail: ibest@emory.edu

Key words: ITP, thrombocytopenia, partial splenic embolization.

Received for publication: 28 September 2011.

Revision received: 11 November 2011.

Accepted for publication: 15 November 2011.

This work is licensed under a Creative Commons Attribution NonCommercial 3.0 License (CC BY-NC 3.0).

©Copyright I.M. Best, 2011
Licensee PAGEPress, Italy
Clinics and Practice 2011; 1:e126
doi:10.4081/cp.2011.e126

60 years.² Surgical management is reserved for patients who have failed medical management or those with acute life threatening bleeding. Puapong et al reported on the successful splenic embolization in a child with intracranial bleeding and persistent thrombocytopenia before neurosurgical management of the intracranial hematoma.³ From this case it would seem reasonable to embolize the spleen before serious bleeding complications develop. Additionally, Takahashi *et al.* reported their results on five children who had splenic embolization one day before surgical splenectomy. These children had either ITP or hereditary spherocytosis. The average blood loss was 9 mL and none of these patients had post operative complications.⁴ Neuret *et al.* studied 863 children with newly diagnosed ITP to evaluate their risk for bleeding at admission and in the four weeks that followed. They found that 505 of these patients had a platelet count

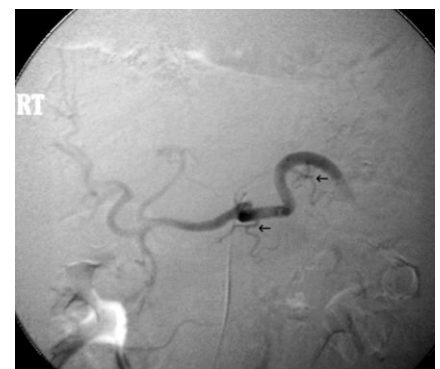

Figure 1. Celiac artery angiogram showing the proximal splenic artery and the blood supply to the body of the pancreas (black arrowheads).

less than $20 \times 10^9/L$ and that 2.9% had severe bleeding at admission and none had severe bleeding in the 4-week follow-up period.⁵ This patient had been refractory to medical management but was reluctant to consider surgical intervention. Partial splenic artery embolization was considered a temporizing measure since. Reso et al have reported on the

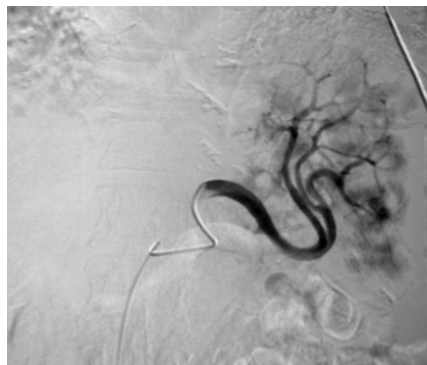


Figure 2. Partial splenic embolization using 500-700 μ embolic particles.

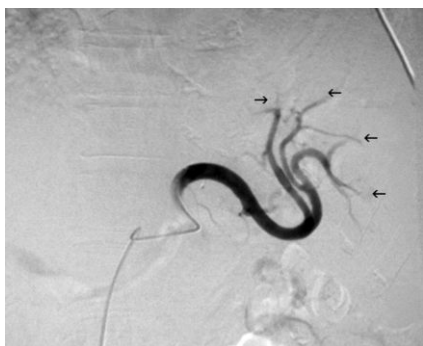

Figure 3. The intrasplenic vascular tree is significantly pruned (black arrows).

use of splenic artery embolization before successful laparoscopic splenectomy in 19 patients with massively enlarged spleens. The operative blood loss was 200 mL; one patient required reoperation for bleeding.⁶ In the recent 2011 update of guidelines by The American Society of Hematology, the author noted that the timing of splenectomy should be delayed for a year if possible in children who might be failures to first line therapy. In the adult, those who fail steroids and immunoglobulin therapy and other therapies might be considered for adjunctive medical management. They noted that this is an area that needs further investigation to determine what salvage therapies are appropriate when frontline therapy has failed. They also pointed out that where strong data was lacking physicians should use their best medical judgment and consideration for the patient's wishes.⁷ This patient lived alone and was fearful of having an abdominal operation at her age and was even more fearful of an intracranial bleed or stroke and loss of her independence. However, when her platelet count rose to acceptable clinical levels she was discharged from the hospital. Her platelet count continued to rise to over $150 \times 10^9/L$ four weeks after discharge.

Conclusions

Further study is needed to determine if splenic artery embolization could have an expanded role in the treatment of patients with severe ITP and those who might be treatment failures of first line therapy and other chronic forms of thrombocytopenia particular that associated with advanced liver disease.

References

1. Liebman HA. Immune Thrombocytopenia (ITP): An Historical Perspective. *Hematology Am Soc Hematol Educ Program* 2008; 205.
2. Cohen YC, Djuibegovic B, Shamai-Lubovitz O, et al. The bleeding risk and natural history of idiopathic thrombocytopenic purpura in patients with persistent low platelet counts. *Arch Intern Med* 2000;160:1630-8.
3. Puapong D, Terasaki K, Lacerna M, et al. Splenic artery embolization in the management of an acute immune thrombocytopenic purpura-related intracranial hemorrhage. *J Pediatr Surg* 2005;40:869-71.
4. Takahashi T, Arima Y, Yokomuro S, et al. Splenic artery embolization before laparoscopic splenectomy in children. *Surg Endosc* 2005;19:1345-8.
5. Neunert CE, Buchanan GR, Imbach P, et al. Intercontinental Childhood ITP Study Group Registry II Participants. Severe hemorrhage in children with newly diagnosed immune thrombocytopenic purpura. *Blood* 2008;112:4003-8.
6. Reso A, Brar MS, Church N, et al. Outcome of laparoscopic splenectomy with preoperative splenic artery embolization for massive splenomegaly. *Surg Endosc* 2010;24: 2008-12.
7. Neunert C, Lim W, Crowther M, et al. The American Society of Hematology 2011 evidence-based practice guideline for immune thrombocytopenia. *Blood* 2011;117: 4190-207.