

# Bradycardia-induced polymorphic ventricular tachycardia after radiofrequency catheter ablation for right atrial flutter



Matthew Zada, BMedSc(Hons), MBBS,\* David Tanous, MBBS, PhD,\*†  
Stuart P. Thomas, MBBS, PhD, FHRS,\*† Saurabh Kumar, MBBS, PhD, FHRS,\*†  
Eddy Kizana, MBBS, PhD, FHRS\*††

From the \*Department of Cardiology, Westmead Hospital, Westmead, Australia, †Sydney Medical School, The University of Sydney, Sydney, Australia, and ‡Centre for Heart Research, The Westmead Institute for Medical Research, Westmead, Australia.

## Introduction

Atrial flutter is readily amenable to radiofrequency (RF) catheter ablation in most patients. RF for atrial flutter can stave off complications such as tachycardia-induced cardiomyopathy.<sup>1</sup> However, RF catheter ablation is not without significant risk. Polymorphic ventricular tachycardia is a recognized life-threatening complication of atrioventricular junction (AVJ) catheter ablation for rate control of atrial fibrillation (AF).<sup>2,3</sup> Here we report the first case of a 75-year-old woman who developed polymorphic ventricular tachycardia after RF catheter ablation for atrial flutter and discuss potential mechanisms contributing to the development of this arrhythmia.

## Case report

A 75-year-old woman with a history of coronary artery disease, heart failure, and persistent and inadequately rate-controlled atrial flutter was referred for catheter ablation. Eighteen years prior the patient underwent coronary artery bypass grafting and mitral valve repair. Over recent years the patient experienced episodes of paroxysmal atrial flutter, with a persistent episode occurring 12 months prior to referral to our hospital. Two attempts at transesophageal echocardiogram with cardioversion were aborted owing to thrombus in the atrial appendage despite oral anticoagulation with apixaban 5 mg twice a day or warfarin. Following anticoagulation with dabigatran 150 mg twice a day and a subsequent transesophageal echocardiogram confirming resolution of the atrial thrombus, the decision was made to proceed to catheter ablation. The patient's regular

**KEYWORDS** Arrhythmia; Atrial flutter; Catheter ablation; Fibrillation; Polymorphic ventricular tachycardia; Radiofrequency (Heart Rhythm Case Reports 2019;5:414–418)

**Address reprint requests and correspondence:** Dr Eddy Kizana, Department of Cardiology, Westmead Hospital, Hawkesbury Rd, Westmead, NSW 2150, Australia. E-mail address: [eddy.kizana@sydney.edu.au](mailto:eddy.kizana@sydney.edu.au).

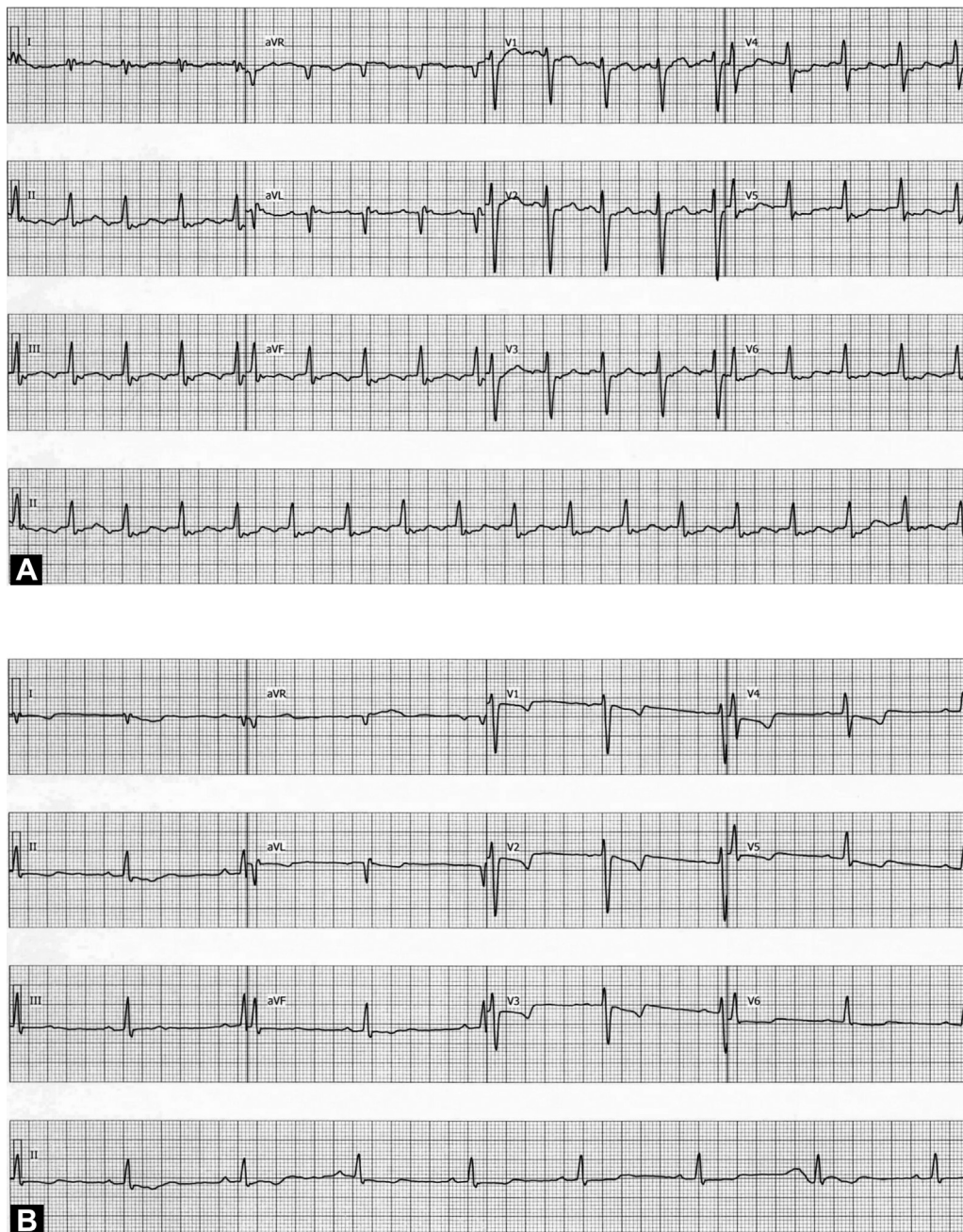
## KEY TEACHING POINTS

- While polymorphic ventricular tachycardia is a life-threatening complication of atrioventricular junction catheter ablation for atrial fibrillation, we describe the first case seen after radiofrequency catheter ablation of typical cavotricuspid-dependent atrial flutter.
- Risk factors for the development of ventricular arrhythmias after catheter ablation for atrial flutter have not been investigated; however, similar to atrial fibrillation, they may include dilated cardiomyopathy and structural heart disease.
- Prolonged repolarization in the context of an abrupt reduction in heart rate after catheter ablation for atrial flutter should heighten suspicion for the development of malignant ventricular arrhythmias in the periprocedural period.

medications included aspirin, dabigatran, perindopril, metoprolol, digoxin, isosorbide mononitrate, rosuvastatin and pantoprazole.

## Baseline investigations

A 24-hour Holter monitor obtained 8 months prior to the procedure showed persistent atrial flutter with an average heart rate of 101 beats per minute (bpm). A transthoracic echocardiogram prior to the procedure showed mild left ventricular (LV) dilatation and mildly impaired LV systolic function with biplane LV ejection fraction of 49%; severely dilated left atrium; mild mitral stenosis with mild mitral regurgitation; and mild aortic stenosis. The right ventricle was also mildly dilated with mild-to-moderate right ventricular systolic impairment. There was evidence of moderate



**Figure 1** A: Twelve-lead electrocardiogram preablation showing atrial flutter with rapid ventricular response. B: Twelve-lead electrocardiogram after cavo-tricuspid isthmus ablation showing sinus bradycardia and prolonged QTc.

pulmonary hypertension with an estimated systolic pressure of 61 mm Hg.

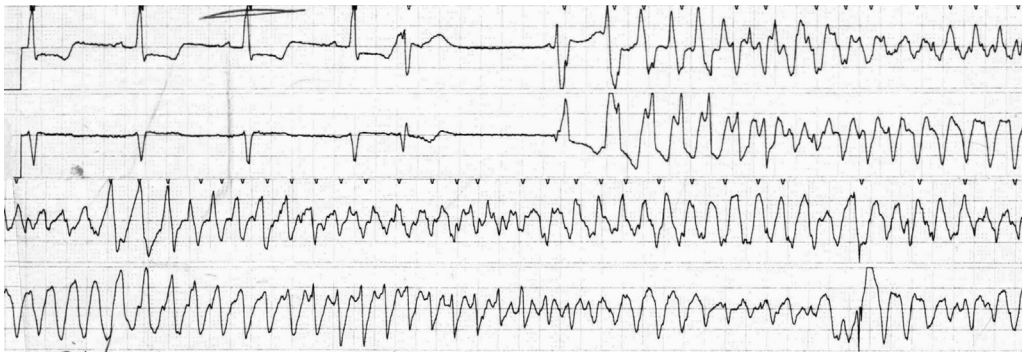### Procedure

The procedure was performed under general anesthetic with the patient receiving fentanyl, propofol, rocuronium, metaraminol and ondansetron. The preprocedure electrocardiogram (ECG) showed atrial flutter with a ventricular rate of 103 bpm (Figure 1A). A 20-pole tricuspid annulus mapping catheter demonstrated counter-clockwise atrial activation. There was concealed entrainment with a postpacing interval equal to the tachycardia cycle length from the cavotricuspid isthmus

(CTI) during atrial flutter. The CTI was ablated with an irrigated-tip ablation catheter and 25–40 watts of power. Following block at the CTI a second right atrial flutter was transiently observed and terminated spontaneously. No further RF was performed. At the end of the procedure the ECG showed sinus bradycardia with a heart rate of 52 bpm (Figure 1B).

### Postprocedure

Seven hours postprocedure, the patient developed polymorphic ventricular tachycardia, which was terminated after 2 minutes with a single 200 J biphasic DC shock (Figure 2). The average monitored heart rate prior to the ventricular arrhythmia was



**Figure 2** Rhythm strip showing polymorphic ventricular tachycardia initiated by “R-on-T” phenomenon.

between 60 and 65 bpm. The blood chemistry revealed a pH of 7.35, potassium of 4.7 mmol/L (normal range 3.2–5.0 mmol/L), and magnesium 0.91 mmol/L (normal range 0.70–1.10 mmol/L). A transthoracic echocardiogram done following cardiac arrest revealed stable cardiac structure and function with no new regional wall motion abnormalities. The patient was hospitalized for 14 days after the cardiac arrest as a result of musculoskeletal injury secondary to cardiopulmonary resuscitation and a catheter-related urinary tract infection, as well as for further investigations, which included coronary angiography (which showed native coronary artery disease but patent bypass grafts) and an electrophysiology study (which failed to induce ventricular arrhythmia with programmed stimulation and up to 4 extrastimuli, without isoprenaline). The patient was monitored on telemetry for 14 days post cardiac arrest and there was no recurrence of ventricular arrhythmia. Serial daily ECGs after ablation identified that it took 48 hours for the QTc to shorten to 450 ms and 10 days to shorten to less than 440 ms. An ECG 13 days after cardiac arrest demonstrated that the QTc was 408 ms (Figure 3A). There was no recurrent syncope or arrhythmia at 1, 3, and 6 months follow-up (including 24-hour Holter monitor). Furthermore, an ECG at 6 months follow-up showed that the QTc remained normal at 423 ms (Figure 3B).

## Discussion

AF with rapid ventricular rate refractory to maximal medical therapy can be managed with AVJ ablation.<sup>2</sup> A successful AVJ ablation results in a stable escape rhythm with complete atrioventricular block; a permanent pacemaker is concurrently inserted to ensure adequate heart rate response.<sup>2</sup> There is a small risk of sudden cardiac death and ventricular arrhythmias within 48 hours of AVJ ablation.<sup>2,4</sup> It is postulated that the underlying mechanism for the transiently increased risk of ventricular arrhythmias in the immediate phase following AVJ ablation is analogous to acquired forms of the long QT syndrome and include the following:

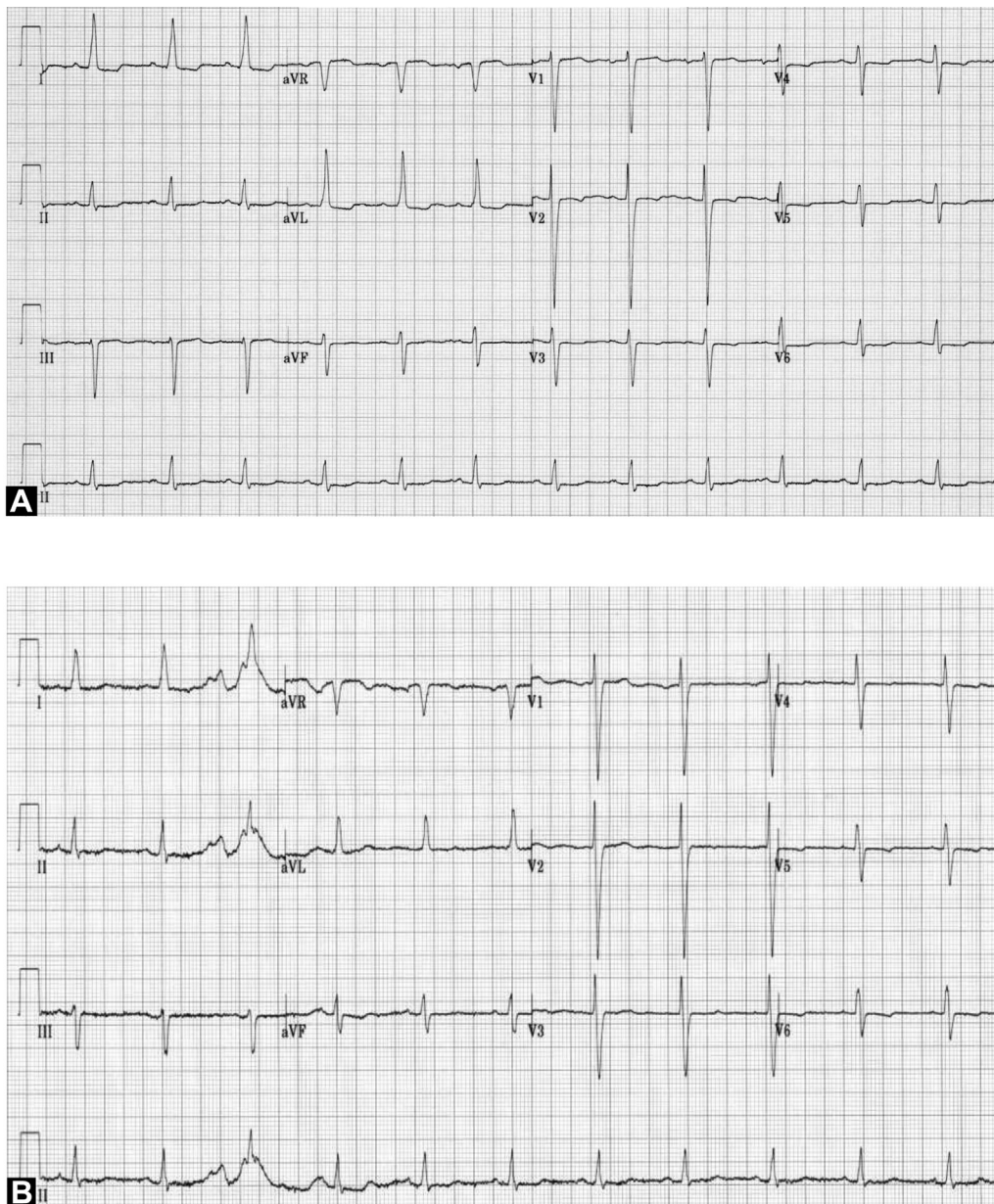
1) Prolonged repolarization. After ablation, there is often a prolonged QT interval indicating repolarization abnormalities secondary to an abrupt reduction in heart

rate.<sup>2,4–6</sup> The prolonged QT interval progressively shortens during the first week postprocedure.<sup>4,6</sup> The risk of ventricular arrhythmia is almost completely eliminated by programming a high pacing rate (greater than 80 bpm) for 8–12 weeks postprocedure.<sup>2</sup> In a study of 235 patients who underwent RF catheter ablation of AVJ for AF, atrial flutter, and atrial tachycardia, 6 of 100 patients had ventricular arrhythmia or sudden death when they were paced at a rate of 70 bpm postprocedure; whereas there was no ventricular arrhythmia or sudden death in the 135 patients paced at 90 bpm postprocedure.<sup>7</sup>

- 2) Altered ventricular activation due to pacing. There have been case reports of ventricular arrhythmia occurring after AVJ ablation despite minimal difference between the preablation and postablation heart rates.<sup>8</sup> Therefore, other mechanisms have also been postulated to contribute to the development of ventricular arrhythmias, including altered activation of the ventricle, being paced from the right ventricular apex as opposed to activation via the His-Purkinje system.<sup>2,4,6</sup>
- 3) Heterogeneity of repolarization. After ablation the reduction in heart rate and change in ventricular activation increases the heterogeneity or “dispersion” of repolarization, which creates a substrate for sustained polymorphic ventricular arrhythmia.<sup>6</sup> This mechanism is thought to be responsible for sustained torsades de pointes in congenital and acquired long QT syndromes.<sup>6</sup>
- 4) Other factors. Heart failure, hypokalemia, and female sex can prolong repolarization and also increase the risk of ventricular arrhythmias after ablation.<sup>6</sup>

The risk factors for sudden death after AVJ ablation and pacemaker insertion for AF have been investigated. The presence of dilated cardiomyopathy, structural heart disease (particularly mitral stenosis, but also aortic stenosis and aortic regurgitation), New York Heart Association functional class greater than II, preprocedure ventricular arrhythmia, diabetes, and chronic obstructive pulmonary disease were all associated risk factors.<sup>5,9,10</sup> Sudden death was exclusively seen in patients who had narrow QRS complex or right bundle branch block prior to AVJ ablation but not in patients with preexisting left bundle branch block.<sup>9</sup>





**Figure 3** **A:** Twelve-lead electrocardiogram 13 days after catheter ablation showing that the QTc had normalized. **B:** Twelve-lead electrocardiogram 6 months after catheter ablation showing that the QTc remained normal.

The patient had several risk factors described previously, including dilated cardiomyopathy and structural heart disease (mixed mitral valve disease, mild aortic stenosis). After ablation, atrial flutter was terminated and the patient's rhythm reverted to sinus bradycardia. The heart rate was 52 bpm, compared to 103 bpm preprocedure, and the QTc prolonged to 559 ms, compared to 419 ms preprocedure (Figure 1A and B). This is consistent with the studies described previously, which showed prolonged repolarization secondary to an abrupt reduction in heart rate after ablation. An acute coronary occlusion was ruled out with angiography and a lack of substrate for reentrant ventricular tachycardia by programmed stimulation. We acknowledge that certain medications can contribute to QT prolongation and the development

of torsades de pointes. Of the medications being taken by the patient regularly prior to and at the time of the procedure, none are known to prolong the QT interval; and of the medications given during the procedure only ondansetron is known to prolong the QT interval.<sup>11</sup> Importantly, our patient only received 4 mg of ondansetron. In a double-blind randomized controlled study investigating the effect of ondansetron on the QTc interval, the QTc prolonged by less than 10 ms after an 8 mg intravenous dose of ondansetron and prolonged by approximately 20 ms after a 32 mg intravenous dose.<sup>12</sup> Therefore, we postulate that the 4 mg intravenous dose of ondansetron administered to our patient had minimal effect on prolonging the QTc. Additionally, in this patient, the QTc markedly prolonged by 140 ms (from 419 ms to

559 ms) immediately after RF catheter ablation (as shown in Figure 1A and B) and persisted for several days, making drug-induced QT prolongation highly unlikely. Therefore, we postulate that the prolonged QTc was primarily due to prolonged repolarization and heterogeneity of repolarization postablation, and that these mechanisms established the substrate for sustained polymorphic ventricular tachycardia, the latter initiated by an “R-on-T phenomenon” as demonstrated in the rhythm strip (Figure 2).

## Conclusion

We report a case of a patient who developed polymorphic ventricular tachycardia after catheter ablation for atrial flutter. There are no studies that evaluate risk factors for the development of ventricular arrhythmias after catheter ablation for atrial flutter. These may or may not be similar to those for AF and, therefore, such studies would have significant clinical implications in identifying patients at higher risk, allowing for safer periprocedural planning, such as close cardiac monitoring and temporary pacing until the transient proarrhythmic state subsides.

## References

1. Pizzale S, Lemery R, Green MS, Gollob MH, Tang AS, Birnie DH. Frequency and predictors of tachycardia-induced cardiomyopathy in patients with persistent atrial flutter. *Can J Cardiol* 2009;25:469–472.
2. Patel D, Daoud EG. Atrioventricular junction ablation for atrial fibrillation. *Heart Fail Clin* 2016;12:245–255.
3. Brembilla-Perrot B, Jacquemin L, Houplon P, et al. Bradycardia-induced polymorphic ventricular tachycardia after radiofrequency catheter modification of atrioventricular junction. *J Interv Card Electrophysiol* 1997;1:153–155.
4. Nowinski K, Gadler F, Jensen-Urstad M, Bergfeldt L. Transient proarrhythmic state following atrioventricular junctional radiofrequency ablation. *Pacing Clin Electrophysiol* 2002;25:291–299.
5. Ozcan C, Jahangir A, Friedman PA, et al. Sudden death after radiofrequency ablation of the atrioventricular node in patients with atrial fibrillation. *J Am Coll Cardiol* 2002;40:105–110.
6. Nowinski K, Gadler F, Jensen-Urstad M, Bergfeldt L. Transient proarrhythmic state following atrioventricular junction radiofrequency ablation: pathophysiologic mechanisms and recommendations for management. *Am J Med* 2002;113:596–602.
7. Geelen P, Brugada J, Andries E, Brugada P. Ventricular fibrillation and sudden death after radiofrequency catheter ablation of the atrioventricular junction. *Pacing Clin Electrophysiol* 1997;20:343–348.
8. Squara F, Theodore G, Scarlatti D, Ferrari E. Ventricular fibrillation occurring after atrioventricular node ablation despite minimal difference between pre- and post-ablation heart rates. *Ann Cardiol Angeiol (Paris)* 2017;66:48–51.
9. Wang RX, Lee HC, Li JP, et al. Sudden death and its risk factors after atrioventricular junction ablation and pacemaker implantation in patients with atrial fibrillation. *Clin Cardiol* 2017;40:18–25.
10. Darpo B, Walfridsson H, Aunes M, et al. Incidence of sudden death after radiofrequency ablation of the atrioventricular junction for atrial fibrillation. *Am J Cardiol* 1997;80:1174–1177.
11. Fazio G, Vernuccio F, Grutta G, Re GL. Drugs to be avoided in patients with long QT syndrome: focus on the anaesthesiological management. *World J Cardiol* 2013;5:87–93.
12. Zuo P, Haberer LJ, Fang L, Hunt TL, Ridgway D, Russo MW. Integration of modeling and simulation to support changes to ondansetron dosing following a randomized, double-blind, placebo-, and active-controlled thorough QT study. *J Clin Pharmacol* 2014;54:1221–1229.