

[CASE REPORT]

Persistent Gastrointestinal Angiodysplasia in Heyde's Syndrome after Aortic Valve Replacement

Takashi Akutagawa¹, Takero Shindo², Kohei Yamanouchi¹, Masaki Hayakawa³, Hiroshi Ureshino², Nanae Tsuruoka¹, Yasuhisa Sakata¹, Ryo Shimoda¹, Ryo Noguchi⁴, Kojiro Furukawa⁴, Shigeaki Morita⁴, Ryuichi Iwakiri¹, Shinya Kimura², Masanori Matsumoto³ and Kazuma Fujimoto¹

Abstract:

A 67-year-old woman with recurrent gastrointestinal bleeding and aortic valve stenosis presented with spurting bleeding from angiodysplasia of the upper jejunum. As electrophoresis revealed decreased levels of high-molecular-weight (HMW) von Willebrand factor (VWF) multimers, she was diagnosed with Heyde's syndrome. After aortic valve replacement, her HMW VWF levels quickly recovered to normal, and the gastrointestinal bleeding ceased. However, capsule endoscopy still revealed gastrointestinal angiodysplasia six months later. This case shows that minute analyses of VWF multimers enable the diagnosis and confirmation of the resolution of Heyde's syndrome, and implies that gastrointestinal angiodysplasia can be attributed to unknown factors other than decreased VWF multimers.

Key words: Heyde's syndrome, von Willebrand factor, gastrointestinal angiodysplasia

(Intern Med 56: 2431-2433, 2017)

(DOI: 10.2169/internalmedicine.8603-16)

Introduction

Gastrointestinal (GI) angiodysplasia presents with endoscopic findings of small, flat, cherry-red mucosal changes, or ectatic blood vessels in the GI tract. It can be detected during colonoscopy in about 3% of asymptomatic people > 65 years of age (1) and is a common cause of recurrent GI bleeding and persistent anemia in the elderly. Recent studies have suggested that deficiency of von Willebrand factor (VWF) causes angiodysplasia (2); however, the exact etiology has not yet been fully elucidated (3).

Heyde's syndrome is characterized by angiodysplastic GI bleeding accompanied by aortic valve stenosis (AVS) (4). The narrow valve causes abnormal shear stress in the blood flow, which enhances the cleavage of VWF multimers by a disintegrin and metalloproteinase with a thrombospondin type 1 motif, member 13 (ADAMTS13) (5). Decreased

VWF levels result in no platelet aggregation, leading to an increased risk of bleeding (1).

We herein report the case of a 67-year-old woman with Heyde's syndrome, in which the course of VWF multimers and angiodysplasia was closely observed before and after aortic valve replacement (AVR). Our case indicates that a sensitive VWF assay is indispensable to diagnose and confirm the resolution of Heyde's syndrome, and that the pathogenesis of GI angiodysplasia in Heyde's syndrome may include other unknown factors.

Case Report

In February 2015, a 67-year-old woman with blood type A was admitted to our hospital with tarry stool and severe microcytic anemia. She had experienced recurrent GI bleeding for the past six years and had undergone multiple endoscopic clipping and argon plasma laser coagulation proce-

¹Department of Internal Medicine and Gastrointestinal Endoscopy, Saga University School of Medicine, Japan, ²Department of Hematology, Respiratory Medicine and Oncology, Saga University School of Medicine, Japan, ³Department of Transfusion Medicine, Nara Prefectural Medical College, Japan and ⁴Department of Thoracic and Cardiovascular Surgery, Saga University School of Medicine, Japan

Received: November 24, 2016; Accepted: January 29, 2017; Advance Publication by J-STAGE: August 21, 2017

Correspondence to Dr. Takero Shindo, takeros@kuhp.kyoto-u.ac.jp

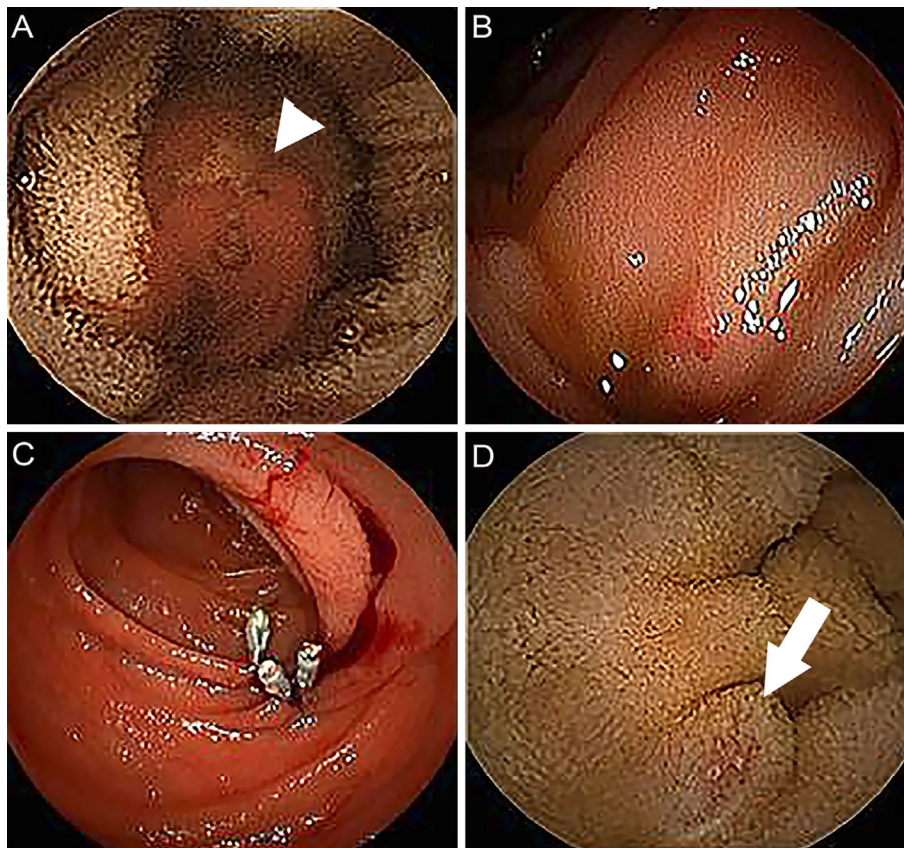


Figure 1. Endoscopic images of the gastrointestinal tract of a 67-year-old female with Heyde's syndrome. (A) Capsule endoscopy revealed spurting bleeding from angiodyplasia (Yano-Yamamoto classification type 2a) in the jejunum [arrow head]. (B) Double-balloon endoscopy revealed angiodyplasia at the upper jejunum. (C) Endoscopic clipping and injection of hyperosmotic saline epinephrine at the bleeding portion resolved the bleeding. (D) Angiodyplasia (Yano-Yamamoto classification type 1b) persisted six months after aortic valve replacement in the jejunum [arrow].

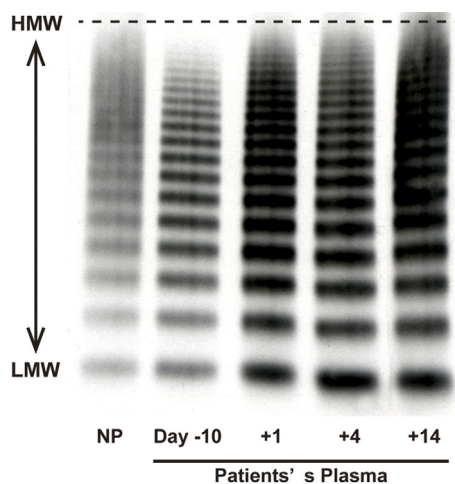


Figure 2. Sodium dodecyl sulfate agarose gel electrophoresis results. The patient's plasma was collected multiple times, and sodium dodecyl sulfate agarose gel electrophoresis was used to detect the von Willebrand factor (VWF) multimers. Compared with normal plasma, the patient's plasma lacked high-molecular-weight VWF on day -10, but it quickly recovered to normal by day 4 after the operation. Day 0 represents the day of the aortic valve replacement operation. HMW: high-molecular-weight, LMW: low-molecular-weight, NP: normal plasma

dures to resolve bleeding from colonic angiodyplasia. A pansystolic murmur was auscultated, and her hemoglobin level was 6.1 g/dL. While esophagogastroduodenoscopy and colonoscopy could not detect the bleeding site, capsule endoscopy revealed spurting bleeding from angiodyplasia at the upper jejunum (Fig. 1A). Angiodyplasia was detected in six lesions in total: two in duodenum and four in jejunum. We performed clipping and injection of hyperosmotic saline epinephrine solution with double-balloon endoscopy, and the bleeding resolved (Fig. 1B, C).

The patient had been diagnosed with AVS in 2013. A transthoracic echocardiogram revealed that the AVS had progressed; the mean aortic valve pressure gradient was 61 mmHg, peak aortic blood flow 4.84 m/s, aortic valve area 0.77 cm², and aortic valve area index 0.55 cm²/m², which suggested that AVR was indicated. As sodium dodecyl sulfate agarose gel electrophoresis of VWF multimers revealed a marked lack of high-molecular-weight (HMW) VWF multimers in the plasma (Fig. 2), she was diagnosed with Heyde's syndrome and underwent AVR with a bioprosthetic valve. The level of the HMW VWF multimers dramatically recovered within the first postoperative week (Fig. 2), and her GI bleeding immediately ceased. However, six months

later, follow-up capsule endoscopy revealed that angiodysplasia persisted in two lesions in the duodenum and one lesion in the jejunum (Fig. 1D), although there had been no major bleeding episodes or severe anemia since the AVR.

Discussion

Heyde's syndrome is the association of acquired von Willebrand disease type IIA (lack of HMW VWF multimers) with AVS (4). While the efficacy of endoscopic treatment or intestinal resection is limited, AVR quickly resolves bleeding (6), and it has been successfully resolved using transcatheter aortic valve implantation (7). Although Heyde's syndrome is not very common, capsule endoscopy can be useful for diagnosing this disease. All clinical gastroenterologists should be reminded of this disease when encountering patients with recurrent gastrointestinal bleeding, as quickly referencing cardiovascular surgeons is more important than performing endoscopic hemostasis. In the present case, although some angiodysplasia persists, gastrointestinal bleeding has not occurred since AVR, which strongly supports the efficacy of AVR in treating Heyde's syndrome.

A VWF multimer assay is usually performed by electrophoresis with sodium dodecyl sulfate and agarose gel (8), although the methodology has not been standardized. Our analysis (9) clearly revealed decreased levels of HMW VWF multimers, which quickly recovered within one week after AVR. This highlights the importance of a minute VWF multimers assay that sensitively detects the lack of HMW VWF.

Starke et al. reported that a lack of VWF in endothelial cells leads to atypical angiogenesis in mice, (2) and decreased VWF levels are also thought to be involved in the pathogenesis of angiogenesis in humans. However, the association between VWF and angiodysplasia has not been fully explored, and other pathways may also be involved (3). In the present case, although the levels of HMW VWF multimers quickly recovered to normal one week postoperatively, follow-up capsule endoscopy revealed persistent angiodysplasia. This implies that angiodysplasia is sometimes irreversible in Heyde's syndrome, possibly due to the patient's elderly age or the delay in performing AVR. Alternatively, other factors might have caused her angiodysplasia. For ex-

ample, Gola and Lelonek have suggested that degenerative processes and hypoxemia may cause angiodysplasia (10), and several cases of persistent angiodysplasia and hemorrhagic episodes even after AVR have been reported (11, 12).

The authors state that they have no Conflict of Interest (COI).

References

1. Veyradier A, Balian A, Wolf M, et al. Abnormal von Willebrand factor in bleeding angiodysplasias of the digestive tract. *Gastroenterology* **120**: 346-353, 2001.
2. Starke RD, Ferraro F, Paschalaki KE, et al. Endothelial von Willebrand factor regulates angiogenesis. *Blood* **117**: 1071-1080, 2011.
3. Lenting PJ, Casari C, Christophe OD, Denis CV. von Willebrand factor: the old, the new and the unknown. *J Thromb Haemost* **10**: 2428-2437, 2012.
4. Loscalzo J. From clinical observation to mechanism - Heyde's syndrome. *N Engl J Med* **367**: 1954-1956, 2012.
5. Warkentin TE, Moore JC, Morgan DG. Aortic stenosis and bleeding gastrointestinal angiodysplasia: is acquired von Willebrand's disease the link? *Lancet* **340**: 35-37, 1992.
6. Anderson RP, McGrath K, Street A. Reversal of aortic stenosis, bleeding gastrointestinal angiodysplasia, and von Willebrand syndrome by aortic valve replacement. *Lancet* **347**: 689-690, 1996.
7. Godino C, Pavon AG, Mangieri A, Margonato A. Aortic valvuloplasty as bridging for TAVI in high-risk patients with Heyde's syndrome: a case report. *Case Rep Med* **2012**: 946764, 2012.
8. Ruggeri ZM, Zimmerman TS. Variant von Willebrand's disease: characterization of two subtypes by analysis of multimeric composition of factor VIII/von Willebrand factor in plasma and platelets. *J Clin Invest* **65**: 1318-1325, 1980.
9. Nishigori N, Matsumoto M, Koyama F, et al. von Willebrand Factor-Rich Platelet Thrombi in the Liver Cause Sinusoidal Obstruction Syndrome following Oxaliplatin-Based Chemotherapy. *PLoS One* **10**: e0143136, 2015.
10. Gola W, Lelonek M. Clinical implication of gastrointestinal bleeding in degenerative aortic stenosis: an update. *Cardiol J* **17**: 330-334, 2010.
11. Bhutani MS, Gopalswamy N, Gupta SC. Heyde's syndrome: The controversy continues. *Am J Gastroenterol* **89**: 954, 1994.
12. Giovannini I, Chiarla C, Murazio M, et al. An extreme case of Heyde syndrome. *Dig Surg* **23**: 387-388, 2006.

The Internal Medicine is an Open Access article distributed under the Creative Commons Attribution-NonCommercial-NoDerivatives 4.0 International License. To view the details of this license, please visit (<https://creativecommons.org/licenses/by-nc-nd/4.0/>).