

Case Report

Case report of a combined oncocytoma and type 1 papillary renal cell carcinoma: a rare entity

R. Gaeta¹, A. Tognetti², E.F. Kauffmann³, L.E. Pollina²

¹ Department of Translational Research and of New Technologies in Medicine and Surgery, University of Pisa, Italy;

² U.O. Pathological Anatomy II, Pisa University Hospital, Italy; ³ Division of General and Transplant Surgery, University of Pisa, Italy

Summary

An extremely rare renal hybrid tumor composed of papillary renal cell carcinoma (PRCC) and renal oncocytoma (RO) within the same tumor is described. Only eight previous cases are documented in the literature. A 44-year-old man showed a 3.5 cm renal mass composed by areas with tubulo-papillary structures made up with small cells with scanty cytoplasm adjacent to polygonal cells forming solid sheet and tubules with abundant eosinophilic cytoplasm and uniform, round central nuclei without mitoses. Complete immunohistochemical panel suggested a diagnosis of type 1 PRCC combined with RO. Contrary to previous cases of hybrid renal tumors reported in the literature, no pseudocapsule divided the two histotypes of tumors. Our patient is the youngest among the previous reports being 44. Collision tumours have previously been described, although mixed renal tumours composed of oncocytoma and PRCC is extremely rare. There is no evidence to suggest a relationship between oncocytoma and papillary RCC since they originate from different cells and have different prognoses. Given the possibility of oncocytomas to harbour other tumours, we suggest careful examination of the samples to exclude the presence of an associated malignant neoplasm, which might have a significantly worse prognosis than oncocytoma. Differential diagnosis is needed, and immunohistochemical stains are of great help in distinguishing between the two histological components.

Key words

Kidney • Oncocytoma • Papillary renal cell carcinoma • Combined • Immunohistochemistry

Introduction

According to the World Health Organization, kidney cancer is the ninth most common cancer in men and the fourteenth most common in women worldwide, but the sixteenth most common cause of death from cancer for both gender ¹. Among these, Renal Cell Carcinoma (RCC) is the most frequent type of kidney cancer in adults (average age at diagnosis 55 to 60 years) ², responsible for approximately 90-95% of cases ³. The second most common histologic variant of RCC (10-15%) is the papillary type (PRCC) ⁴, a malignant tumour derived from renal tubular epithelium. It is usually a well circumscribed papillary or tubulo-papillary cancer which occurs in the renal cortex and might be related to end-stage renal disease or acquired cystic disease ¹. Two subtypes are recog-

nized: type 1 tumours, composed by papillae covered by a single layer of small uniform cells; type 2 tumours, characterized by pseudostratified cells with eosinophilic cytoplasm and high nuclear grade covering the papillae ⁴.

Renal oncocytoma (RO) is a benign epithelial tumour of the intercalated cells of collecting tubules ⁵ and is composed by uniform round or polygonal cells with abundant, intensely eosinophilic and granular cytoplasm. It represents 4-7% of adult renal epithelial tumours (mean age 62 years) and it is usually incidental ⁶. A hybrid tumor composed of PRCC and RO within the same tumor is extremely rare, in fact, there are only eight cases documented in the literature ⁷. The second case of intimately mixed RO and PRCC in a single mass is described in this article ⁷. Our patient is the youngest among the previous reports being 44.

How to cite this article: Gaeta R, Tognetti A, Kauffmann EF, et al. *Case report of a combined oncocytoma and type 1 papillary renal cell carcinoma: a rare entity*. Pathologica 2019;111:37-40. <https://doi.org/10.32074/1591-951X-52-18>

Correspondence: Raffaele Gaeta, Department of Translational Research and of New Technologies in Medicine and Surgery, University of Pisa, via Paradisa 2, 56124 Pisa, Italy - Tel. +39 050 992889 - E-mail: raffaele.gaeta@med.unipi.it

Case report

A 44-year-old man with history of hiatal hernia and gastro-oesophageal reflux disease presented to the hospital emergency department due to asthenia, nausea, fever, jaundice, hyperchromic urine and hypochromic faeces caused by HBV.

Abdominal ultrasound performed to investigate the symptoms incidentally identified a solid exophytic mass in the lower left renal pole. Subsequent computed tomography (CT) with contrast media (Visipaque 320) disclosed that the neoplasm was 3.5 x 2.0 cm in size with 3.8 cm longitudinal diameter with non-homogeneous contrast enhancement, compatible with a solid cortical tumour (Fig. 1 a-c).

According to the well-consolidated concept of the nephron sparing surgery in case of suspected RCC⁸⁻⁹, the patient underwent robot-assisted enucleation of the tumour with preoperative placement of ureteral stent in

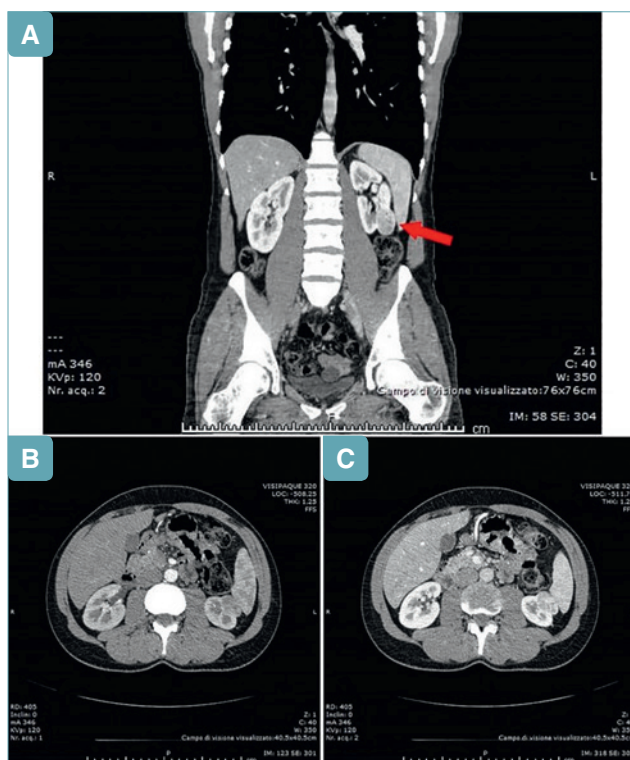


Fig. 1. a-c) Computed tomography (CT) with Contrast Media (Visipaque 320). Lower left renal pole solid exophytic mass (red arrow). The neoplasm was 3.5x2.0 cm in size with 3.8 cm longitudinal diameter with non-homogeneous contrast enhancement (a; b. arterial phase image; c. portal-venous phase image).

order to prevent post-operative urinous fistula¹⁰ due to the proximity of the neoplasm to the calices.

Macroscopical, histological and immunohistochemical results

Gross examination revealed a 3.5 x 2.5 x 2.5 cm well-capsulated mahogany to dark brown solid mass with focal haemorrhagic areas.

At haematoxylin and eosin staining, areas with tubulo-papillary structures made up with small cells with scanty cytoplasm, arranged in a single layer on the papillary basement membrane were observed. Nuclei showed finely granular “open” chromatin; nucleoli at 100X were small and inconspicuous while appeared well visible and eosinophilic at 400X. Diffuse haemorrhage was present.

The appearances were those of a type 1, papillary renal cell carcinoma, Fuhrman nuclear grade 2.

Adjacent to this neoplasm, polygonal cells forming solid sheet and tubules with abundant eosinophilic cytoplasm and uniform, round central nuclei without mitoses have been observed. The morphology was compatible with the diagnosis of oncocytoma. Contrary to previous cases of hybrid renal cancer reported in literature, no pseudocapsule divided the two histotypes of tumors (Fig. 2).

Surgical margins were free of tumour and there was no extra capsular tumor infiltration into perinephric fat tissue. According to the American Joint Committee on Cancer (AJCC) classification, the tumour was staged as T1aN0MX.

Immunohistochemical staining revealed a heterogeneous profile. The papillary component of the neoplas-

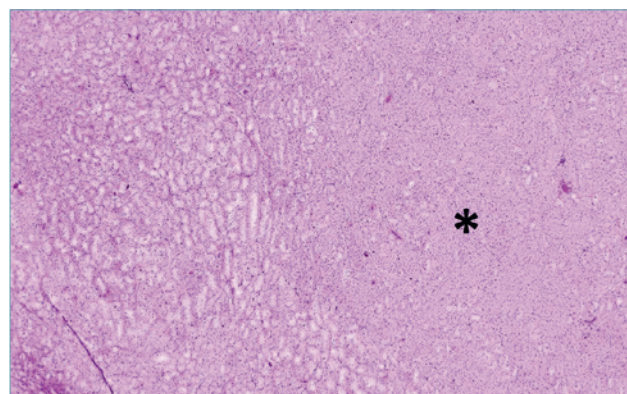


Fig. 2. Type 1, papillary renal cell carcinoma (left) in continuity with oncocytoma (asterisk). No pseudocapsule divided the two histotypes of tumours (E&E, 40X).

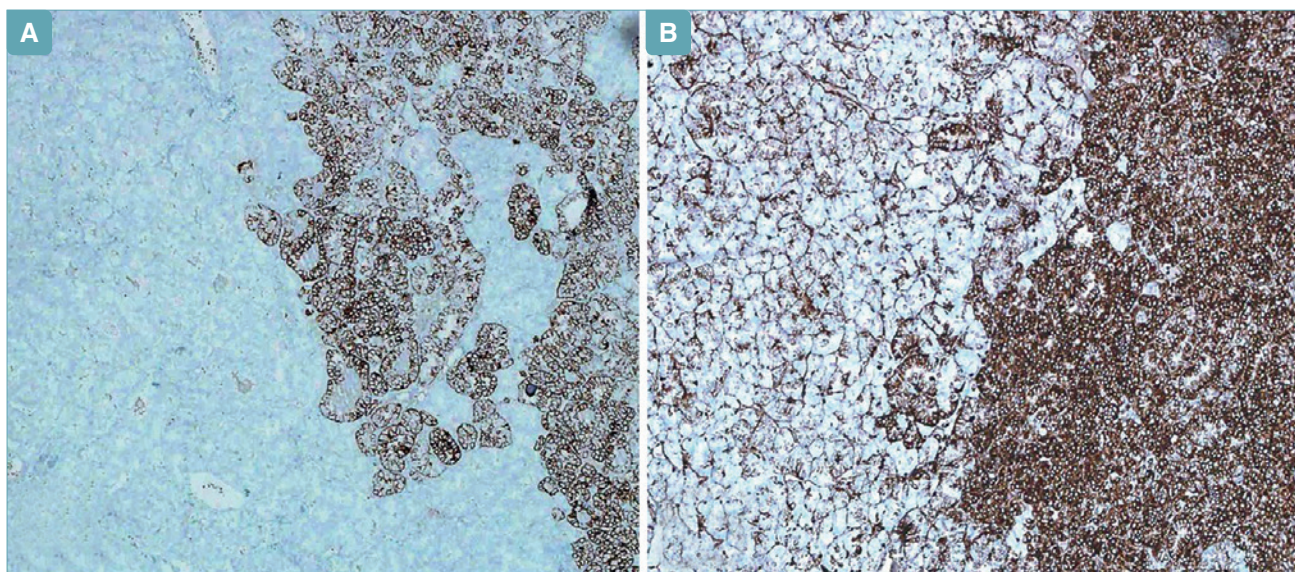


Fig. 3. a-b) Immunohistochemistry of the two different constituents within the tumor: CK7 and vimentin are positive in papillary RCC, but negative in oncocytoma (a. CK7, 40X; b. anti-vimentin, 100X).

Tab. I. Immunohistochemical panel used in the study.

	Papillary Renal Cell Carcinoma	Renal Oncocytoma
Cytokeratin 7	Positive	Negative
Vimentin	Positive	Negative
CD10	Positive	Negative
BerEP4	Positive	Negative
CD117	Negative	Positive

sia showed the typical panel of the PRCC, i.e. positivity for CK7, vimentin, BerEP4 and a weak positivity for CD10, instead the oncocytoma areas were positive for CD117 and negative for the cytokeratines, vimentin and CD10 (Fig. 3 a-b).

Immunohistochemical panel used in the study is summarized in Table I.

Discussion and conclusions

“Collision tumours” refer to coexistent but histologically distinct tumours that result from two separate but adjacent neoplasm¹¹. In the kidney, collision tumours have been previously described, however they were mainly composed of oncocytoma and chromophobe renal cell carcinoma (ChRCC)¹². They are seen in three settings, namely Birt-Hogg-Dubé Syndrome, renal oncocytosis, and as sporadic neoplasia⁷. Mixed renal tumours composed of a component other than ChRCC in addition to oncocytoma are unusual. In

particular, combined oncocytoma-PRCC is extremely rare^{7 11-18}.

There is no evidence to suggest a relation between oncocytoma and papillary RCC since they originate from different cells. PRCC derives from proximal or distal convoluted tubule, while oncocytoma arises from the distal nephron, probably from the epithelium of the collecting tubule¹⁹.

Given the possibility of oncocytomas to harbour other tumours, we suggest, particularly in large oncocytomas, careful examination of the samples to exclude the presence of an associated malignant neoplasm, which might have a significantly worse prognosis than oncocytoma. Differential diagnosis is needed since the prognosis of the two histotypes changes critically. Sporadic oncocytomas are benign neoplasm with an excellent prognosis: they typically do not recur after surgical treatment and the lifespan of affected people is usually not impacted by the tumour²⁰. Papillary RCC is a malignant tumour whose prognosis strictly depends upon a set of several factors, which include the histomorphology (e.g. mitosis, necrosis), the stage, the surgical respectability of the tumour, the age of the individual and the response to treatment²¹. Immunohistochemical stains is of great help in distinguishing the two components.

In the literature, only eight cases of combined oncocytoma-PRCC have been described^{7 11-18}. Previously reported cases showed that the PRCC component within the oncocytoma was well delineated and distinct on

both gross and microscopic examination. Our case differs from the others since the PRCC area is not well shaped, but is closely intermingled to the oncocytoma. By comparing the previous cases, there is an evident prevalence for males since only one combined oncocytoma-PRCC in a woman is described¹⁶. Type 1 and type 2 PRCC show an equal percentage of incidence (50%). Moreover, our patient is the youngest among the previous reports being 44 years of age. New cases of combined oncocytoma-PRCC tumours could provide additional information useful for optimal treatment policy that can have a strong impact on the prognosis of affected patients.

CONFLICT OF INTEREST STATEMENT

None declared.

References

- 1 WHO. *WHO classification of tumours of the urinary system and male genital organs*. Lyon: WHO Press 2016.
- 2 Motzer RJ, Bander NH, Nanus DM. *Renal cell carcinoma*. N Engl J Med 1996;335:865-75.
- 3 Curti B, Jana BRP, Javeed M, et al. (26 February 2014). *Renal Cell Carcinoma*. In: Harris JE. Medscape Reference. WebMD. Retrieved 7 March 2014.
- 4 Murphy WM, Grignon DJ, Perlman EJ. *Tumors of the kidney, bladder and related urinary structures. AFIP Atlas of Tumor Pathology, Series 4*. American Registry of Pathology, Washington, 2004.
- 5 Kuroda N, Toi M, Hiroi M, et al. *Review of renal oncocytoma with focus on clinical and pathobiological aspects*. Histol Histopathol 2003;18:935.
- 6 Ziadie M. *Oncocytoma*. PathologyOutlines.com website. <http://www.pathologyoutlines.com/topic/kidneytumoroncocytoma.html>
- 7 Baydar DE. *Mixed oncocytoma and papillary renal cell carcinoma*. Ann Clin Case Rep 2016;1:1025.
- 8 Fergany AF, Hafez KS, Novick AC. *Long-term results of nephron sparing surgery for localized renal cell carcinoma: 10-year follow-up*. J Urol 2000;163:442-5.
- 9 Herr HW. *Partial nephrectomy for unilateral renal carcinoma and a normal contralateral kidney: 10-year follow-up*. J Urol 1999;161:133-34.
- 10 Spana G, Haber GP, Dulabon LM, et al. *Complications after robotic partial nephrectomy at centers of excellence: multi-institutional analysis of 450 cases*. J Urol 2011;186:417-21.
- 11 Goyal R, Parwani AV, Gellert L, et al. *A collision tumor of papillary renal cell carcinoma and oncocytoma*. Am J Clin Pathol 2015;144:811-6.
- 12 Anani W, Amin M, Pantanowitz L, et al. *A series of collision tumors in the genitourinary tract with a review of the literature*. Pathol Res Pract 2014;210:217-23.
- 13 Al-Saleem T, Balsara BR, Liu Z, et al. *Renal oncocytoma with loss of chromosomes Y and 1 evolving to papillary carcinoma in connection with gain of chromosome 7. Coincidence or progression?* Cancer Genet Cytogenet 2005;163:81-5.
- 14 Vasuri F, Fellegara G. *Collision renal tumors*. Int J Surg Pathol 2009;17:338-9.
- 15 Rowsell C, Fleschner N, Marrano P, et al. *Papillary renal cell carcinoma within a renal oncocytoma: case report of an incidental finding of a tumour within a tumour*. J Clin Pathol 2007;60:426-8.
- 16 Floyd MS, Javed S, Pradeep KE, et al. *Composite oncocytoma and papillary renal cell carcinoma of the kidney treated by partial nephrectomy: a case report*. Sci World J 2011;11:1173-7.
- 17 Sejben I, Szabó Z, Lukács N, et al. *Papillary renal cell carcinoma embedded in an oncocytoma: case report of a rare combined tumour of the kidney*. Can Urol Assoc J 2013;7:E513-6.
- 18 Özer C, Gören MR, Egilmez T, et al. *Papillary renal cell carcinoma within a renal oncocytoma: case report of very rare coexistence*. Can Urol Assoc J 2014;8:E928-930.
- 19 Cairns P. *Renal cell carcinoma*. Cancer Biomark 2011;9:461-73.
- 20 Kuroda N, Toi M, Hiroi M, et al. *Review of renal oncocytoma with focus on clinical and pathobiological aspects*. Histol Histopathol 2003;18:935-42.
- 21 Henry N, Rouach Y, Nguyen K, et al. *Papillary renal cell carcinoma: morphological subtypes, clinical and histopathological considerations*. Prog Urol 2010;20:393-401.