

Ruptured Spinal Dermoid Cysts with Lipid Droplets into the Syrinx Cavity : Reports of Fourteen Cases

Cheng Cheng,^{1,2,*} Rong Li,² Haihao Gao,¹ Benzhang Tao,^{1,*} Hui Wang,¹ Mengchun Sun,¹ Gan Gao,¹ Jianzhen Wang,² Aijia Shang¹

Department of Neurosurgery,¹ The First Medical Centre, Chinese PLA General Hospital, Beijing, China
Department of Neurosurgery,² The Third Medical Centre, Chinese PLA General Hospital, Beijing, China

Objective : Dermoid cysts are uncommon in spinal cord tumors, and the phenomenon of their spontaneous rupture into the syrinx cavity is quite rare. We aimed to analyze the imaging characteristics and etiologies, and propose some surgical strategies, for this uncommon phenomenon.

Methods : We retrospectively reviewed 14 cases with spinal dermoid cysts that ruptured into the cervical and thoracic syrinx cavity. There were six male and eight female cases, aged 21 to 46 years, who had lipid droplets in the syrinx cavity from C1 to L3. The dermoid cysts were always located at the conus. Based on patients' complaints, clinical manifestations, and imaging results, we adopted tumor excision and/or syrinx cavity aspiration in one stage or multiple stages.

Results : Three patients had only a syrinx cavity aspiration surgery due to a history of dermoid cyst excision. Eight patients had dermoid cyst resection and syrinx cavity aspiration in one stage. One patient was operated upon in two stages due to the development of new symptoms at nine months follow-up. Two patients underwent only tumor resection since they did not show similar symptoms or signs caused by the cervicothoracic syrinx. The axial magnetic resonance imaging indicated that the lipid droplets were always not at the center but were eccentric. The clinical effect was satisfactory during the follow-up period in this group.

Conclusion : The lipid droplets filled the spinal syrinx cavity, not entirely confined to the central canal. Based on the chief complaints and associated signs, we adopted different surgical strategies and had satisfactory clinical results.

Key Words : Dermoid cysts · Lipid droplets · Spinal cord · Syringomyelia.

INTRODUCTION

Spinal dermoid cysts, which are composed of keratinized

squamous epithelium, are covered with connective tissue with islands of dermis containing sebaceous glands and hair follicles. They arise from ectopic embryonic remnants of ecto-

• Received : June 25, 2021 • Revised : October 3, 2021 • Accepted : October 7, 2021

• Address for reprints : **Aijia Shang**

Department of Neurosurgery, The First Medical Centre, Chinese PLA General Hospital, 28 Fuxing Road, Beijing 100853, China
Tel : +86-10 66875540, Fax : +86-10 57976556, E-mail : shangaj@126.com, ORCID : <https://orcid.org/0000-0003-0002-5331>

Jianzhen Wang

Department of Neurosurgery, The Third Medical Centre, Chinese PLA General Hospital, 69 Yongding Road, Beijing 100069, China
Tel : +86-10 57976614, Fax : +86-10 57976556, E-mail : wangjianzhen200588@163.com, ORCID : <https://orcid.org/0000-0002-0584-4822>

*Cheng Cheng and Benzhang Tao contributed equally to this study.

This is an Open Access article distributed under the terms of the Creative Commons Attribution Non-Commercial License (<http://creativecommons.org/licenses/by-nc/4.0>) which permits unrestricted non-commercial use, distribution, and reproduction in any medium, provided the original work is properly cited.

derm and mesoderm in the spinal canal during neural tube closure of the fetal life^{4,16}). However, they can also be acquired through iatrogenic procedures like spinal surgery, lumbar puncture, or trauma, since the dermal components could be introduced into the subarachnoid space.

It is reported that spinal dermoid cysts account for less than 1% of all spinal cord tumors⁶). They are rare, slow-growing, and benign lesions, that can be located intramedullary, intradural-extramedullary, and extradurally¹²). The lumbosacral

spinal canal is the segment that is most commonly affected with a spinal dermoid cyst. The conus medullaris and cauda equina are always involved. The least common affected segment is the cervical and upper thoracic regions. They can also be associated with split cord malformation, tethered cord, myelomeningocele, bony malformation, dermal sinus tract, or hypertrichosis.

The dermoid cyst rupture into the syrinx cavity or central canal alone is a rare occurrence and has been reported in few

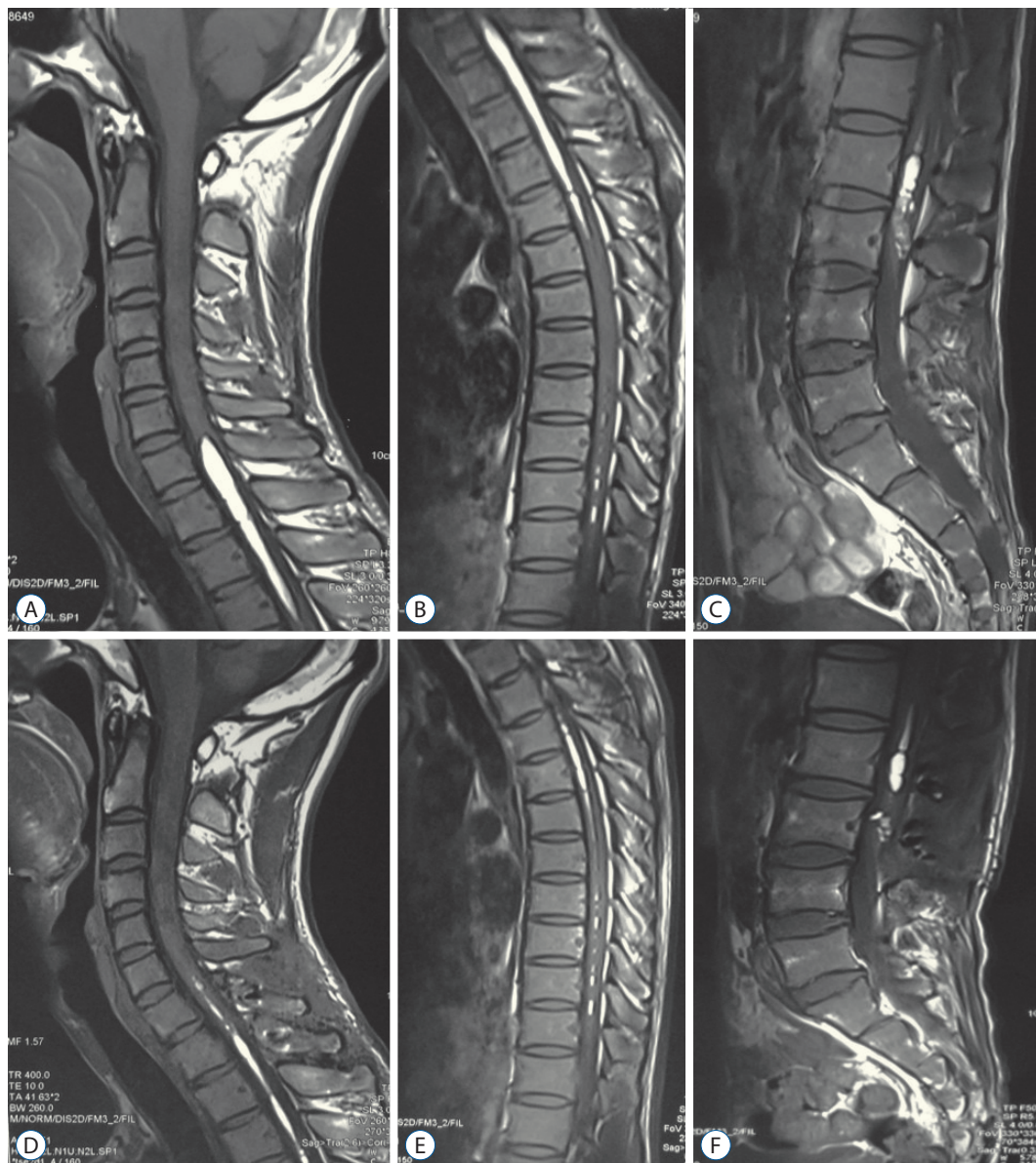


Fig. 1. Case 6. Preoperative magnetic resonance imaging (MRI) revealed a tethered conus lesion with heterogeneous hyperintense on lumbosacral T1-weighted images, and homogeneously spindle or linear signal on the cervical and thoracic spinal cord (A-C). Postoperative MRI showed subtotal resection of the conus dermoid cyst, and lipid droplets reduced significantly in the cervical and thoracic regions (D-F).

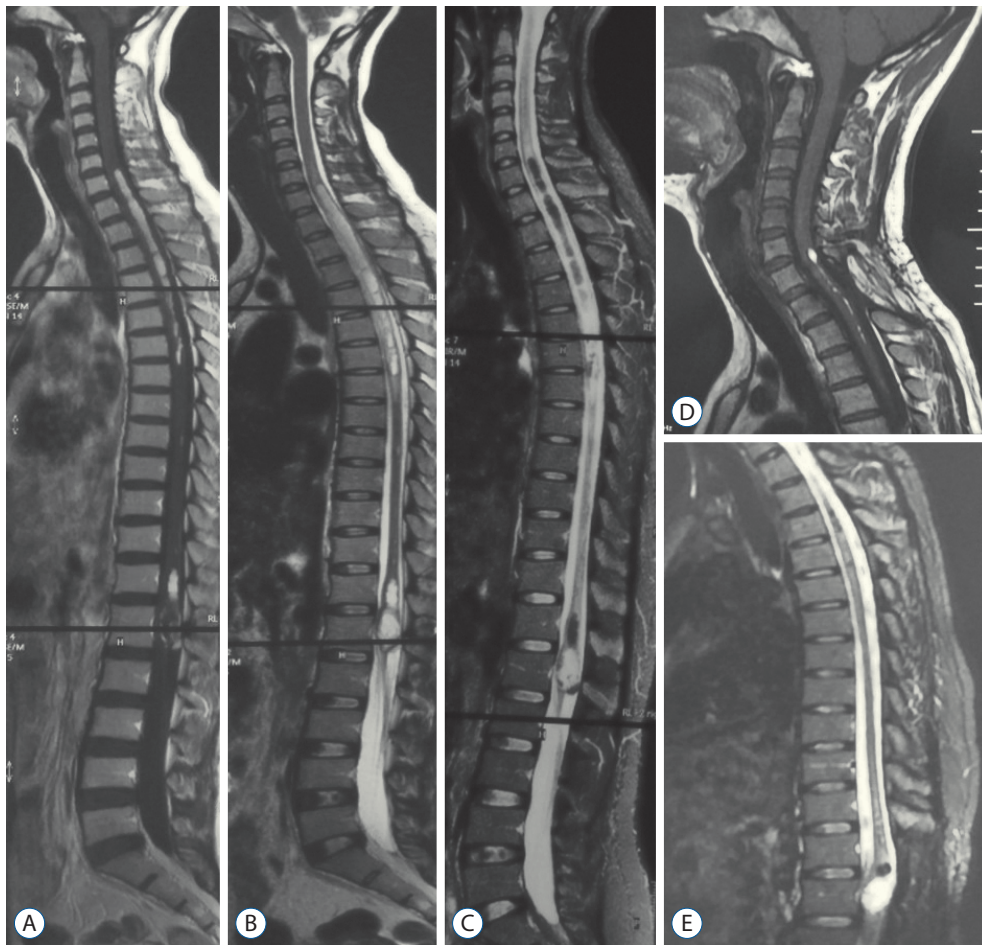


Fig. 2. Case 3. The preoperative whole spine magnetic resonance imaging images revealed C7-T6 intramedullary lipid droplets (short T1-weighted and long T2-weighted signal on A and B), which were suppressed on fat-suppressed sequences (C). The heterogeneous signals were seen at the level of conus medullaris, indicating a possible dermoid cyst. After conus tumor surgery at another clinical center, the patient was admitted to our hospital and had a T1 syrinx cavity aspiration surgery. The cervical intramedullary lipid droplets almost disappeared, and the conus dermoid cyst showed recurrent signs even though the patient did not have apparent symptoms at 72 months follow-up (D and E).

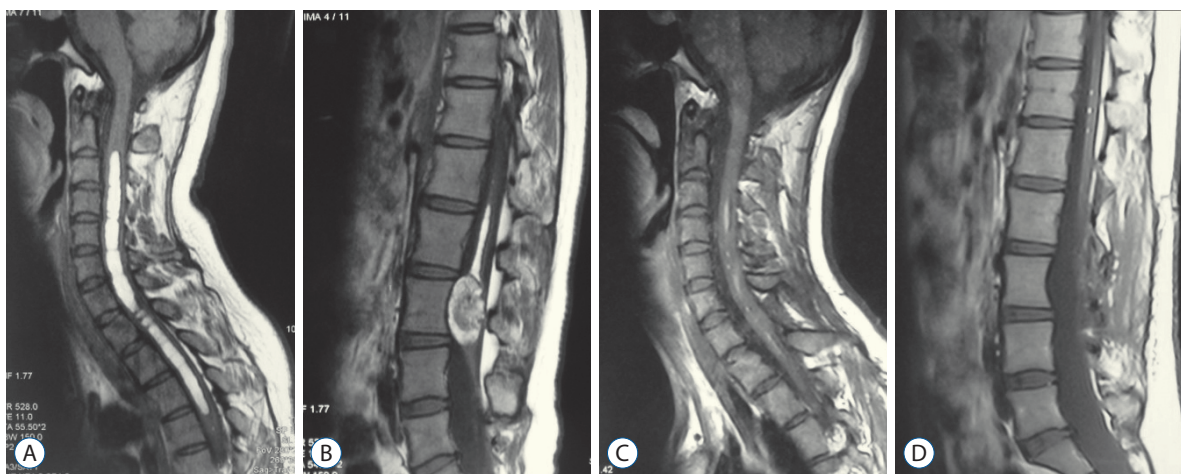


Fig. 3. Case 1. Preoperative magnetic resonance imaging (MRI) showed short-T1 cervical intramedullary lesion and mixed-signal lumbar dermoid cyst (A and B). Postoperative MRI revealed the tumor subtotal resection in one stage (C and D).

studies^{2,3}). Interestingly, no fatty droplets were found in the subarachnoid space in the cases presented. We propose that the lipid droplets are mostly located in the syrinx cavity, not entirely confined to the central canal, which is associated with the development of the dermoid cyst. In this study, we reported on 14 cases with ruptured spinal dermoid cysts into the cervicothoracic intramedullary syrinx. Compared to previous studies, and yet most of them are case reports, we involved relatively larger cases and tried to analyze the etiology of ruptured spinal dermoid cysts, the imaging characteristics and clinical results, and proposed some surgical strategies.

MATERIALS AND METHODS

The study was approved by the Institutional Research Ethics Committee of Chinese PLA General Hospital (No. [2016]1024). We retrospectively studied 14 patients with ruptured spinal dermoid cysts between May 2012 and September 2020. All patients, four males, and eight females, aged 21 to 46 years, had lipid droplets in the syrinx cavity from C1 to L3, and the dermoid cysts were located at the conus. The neurological examination also revealed no cranial nerve dysfunction. The most common clinical presentation was paresis of the extremities; other symptoms or signs such as gait problems, spastic weakness, excretion difficulties, back pain, radiculopathy, and myelopathy were also noted. On T1-weighted sequence magnetic resonance imaging (MRI), the fat manifested as high signals. However, it could be suppressed into low signals on a fat-suppression MRI, which is an excellent

tool to evaluate the characteristic information (Figs. 1-3; cases 1, 3, and 6). Neurological functions were evaluated using the modified McCormick grading (mMG) system, from grade I to grade IV (from the best neurologic function to the worst state). The follow-up time ranged from 3 to 93 months and was characterized by routine neurological examination, regular MRI, and computerized tomography (CT) scan.

According to the chief complaints and physical signs, combined with the character of imageology results, we adopted different surgical strategies. Tumor resection and syrinx cavity aspiration were performed in one stage or stages. The patients were placed in the prone position if the syrinx aspiration was conducted in the region of the cervical or cervicothoracic junction. The Mayfield 3-point skull stabilization and fixation device was used. A dorsal midline incision was made until a pale, grayish, or yellowish dermoid cyst was exposed. Evacuation of the contents, management of the capsule wall, and near-total resection was carried out under neurophysiological monitoring. We tried to strip the majority of the capsule to prevent tumor recurrence. In the intramedullary cervicothoracic syrinx cavity filled with lipid droplets, we performed about 10–20-mm length midline myelotomy. Ivory or yellow lipid droplets flowed out (Fig. 4) : aspiration of the liquid fatty material, repeated irrigation, and aspiration was conducted. For the patients with tethered cord simultaneously, we released the spinal cord and nerve roots and/or resected the thick filum terminale. Intraoperative monitoring was used to prevent possible neurological injuries during the surgery.

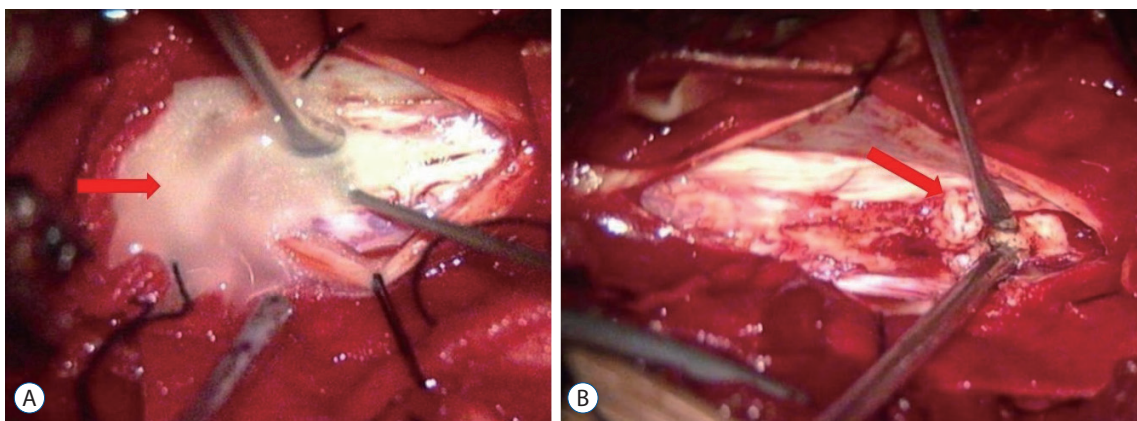


Fig. 4. Intraoperative views showed ivory lipid droplets flowed out (A; red arrow) after cervical spinal cord myelotomy; revealed yellowish dermoid cyst contents exposure (B; red arrow).

Table 1. Demographic and clinical profile of the patients

Patient No.	Sex	Age (years)	Chief complaints	Site of dermoid cyst	Level of syrinx	Preoperative mMG	Operation	Follow-up months	Follow-up mMG
1	F	24	Bladder disfunction Paralysis of the upper limbs	L2-3	C3-T4	II	Tumor resection+T1 syrinx aspiration (one stage)	78	Ib
2	M	28	Back pain Right upper extremity paralysis	L1-2	T2-L1	II	Tumor resection+T5 syrinx aspiration (two stages)	36	Ib
3	F	30	Paresthesia of cervicothoracic region	T12-L1	C7- T6	Ib	T1 syrinx aspiration	93	I
4	F	32	Lower extremity weakness Neck and back pain	T12-L1	C3-T8	II	Tumor resection+C5 syrinx aspiration (one stage)	24	Ib
5	M	29	Back pain	L1	C3-T10	Ib	T2 syrinx aspiration	9	I
6	M	27	Bladder and bowel disfunction Upper back tight feeling	L2-3	C7-T11	II	Tumor resection+T2 syrinx aspiration (one stage)	6	Ib
7	F	34	Lower extremities weakness Upper limbs paresthesia	T12-L4	C7-T11	III	Tumor resection+T1 syrinx aspiration (one stage)	12	II
8	F	28	Lower back pain	L2-3	C1-L1	II	Tumor resection	12	I
9	F	39	Cervicothoracic pain	L1-2	C2-T4	Ib	T1 syrinx aspiration	33	I
10	F	25	Right lower extremity paralysis	L1-2	C2-T12	Ib	Tumor resection	39	I
11	M	33	Bilateral lower extremities numbness Back pain	L4-5	C1-L3	II	Tumor resection+T8 syrinx aspiration (one stage)	60	Ib
12	F	30	Bladder disfunction Neck pain	L2-3	C1-L1	II	Tumor resection+C5 syrinx aspiration (one stage)	82	Ib
13	M	46	Left lower extremity weakness Upper back tight feeling	L1-3	C2-L1	II	Tumor resection+T2 syrinx aspiration (one stage)	9	Ib
14	M	21	Lower back pain Cervicothoracic pain	L1-3	T1-4	II	Tumor resection+T1-2 syrinx aspiration (one stage)	3	I

mMG : modified McCormick grading, F : female, M : male

open and only accepted as a potential space in the adults^{7,14}. The lipids are not only confined to the central canal, which is a potential non-patent space, and a syringomyelia cavity may have probably pre-existed with the dermoid cyst; furthermore, the association of intramedullary tumors with syringomyelia is well-recognized^{8,13}. The syrinx cavity may not communicate with the central canal in most cases. On an MRI scan, the cavity was always eccentric on axial images (Fig. 5). That is similar to syringomyelia in Chiari malformation. The intramedullary fluid was thought to be located in the enlarged central canal in the past; however, some experts proposed that the syrinx cavity was not the enlarged central canal in the majority of patients in recent years¹¹. The syringomyelia cavity caused by the developmental dermoid cyst might explain the entry of dermoid contents into the syrinx. Since the contents have low specific gravity, they always float on top of the cerebral spinal fluid. The collapse of the tumor may result in intramedullary entrapment of these fat droplets, leading to the development of a cavity¹⁴, which cannot be absorbed automatically. This feature is different from the fluid in Chiari syringomyelia, where the cavity could shrink or even disappear after the surgery. Based on this phenomenon, after the excision of the lumbosacral dermoid cyst, a follow-up aspiration of the cervicothoracic intramedullary lipid droplets is recommended when there are associated symptoms or signs.

MRI is the essential radiologic modality in diagnosing spinal dermoid cyst and observing the syrinx cavity. Generally, dermoid cysts are hyperintense on T1 MRI, and on fat-suppressed sequences, the signal is suppressed, and this could help to confirm the diagnosis. However, not all dermoid cysts displayed a high T1-weighted signal, and they sometimes demonstrate heterogeneous signals based on the complicated tumor contents such as hair, bone, cartilage, or other debris. The ruptured dermoid cysts into the cervicothoracic syrinx cavity could be seen as multiple, discrete, rounded, or oval, hyperintense signals on T1-weighted images. They are suggestive of tiny intramedullary lipomas. We found that most syrinx cavities on axial images were eccentric; this could support that the dermoid cyst ruptured into the syrinx cavity. Dissemination of high signal T1-weighted lipid droplets in the syrinx following the rupture is characteristic of ruptured dermoid cysts². CT is a useful tool to observe whether there is bone or calcification in the tumor or spinal dysraphism, and the Hounsfield unit can be used to differentiate lipid and pneu-

mocephalus when small lipids disseminated into the cranial cavity is observed.

In the differential diagnosis, many pathologies such as astrocytoma, ependymoma, lipoma, epidermoid cyst, or arachnoid cyst, can be partially differentiated using MRI. Every pathology has its characteristics, the difference between the dermoid and epidermoid cyst, which is difficult to be differentiated on images. These cysts come from the absence or presence of cutaneous type adnexal structures and are two major variants of ectodermal-derived neuraxis cysts. Both are produced by the inward displacement of ectoderm during embryonic development. The possibility to find dermoid cysts in the lumbosacral region is more common, owing to the closure of the ectoderm to the neural tube starts from the cranial end⁵. The spinal location of dermoid cysts occurs more often than epidermoid cysts, which are more common in the cranium.

Most patients with spinal dermoid cysts were admitted to the hospital due to the mass effect on neural tissues, which caused low back pain or radiculopathy. When the cyst ruptures into the cervicothoracic region, the patients may present with neck pain, back pain, or upper extremity motor deficit. They occur predominantly in the lumbosacral region (60%), involving the conus medullaris and cauda equina, and are quite rare in the cervical (5%) and the thoracic regions (10%)¹⁶. Unlike the rupture of the cranial dermoid cyst, which always manifests as acute presentation, rupture and subsequent release of lipid contents into the syrinx cavity are usually asymptomatic or only present with nonspecific and mild symptoms. The rupture of an intracranial dermoid cyst is frequently symptomatic. The existence of lipid droplets in the ventricular and subarachnoid spaces may cause ventriculitis, arachnoiditis, vasospasm, aseptic chemical meningitis, or hydrocephalus. Clinical symptoms of acute rupture may include vertigo, headache, nausea, vomiting, hemiplegia, mental changes, or even coma^{1,8}.

Due to a limited number of papers that have reported on ruptured dermoid cyst into the syrinx cavity, there are no unified standards for surgery. In this study, eight patients were treated in one stage, where both excision of the dermoid cyst and aspiration of the intramedullary lipid droplets were performed. The decision was based on the patient's chief complaints, clinical manifestations, and imaging results. If the complaints were bladder or bowel dysfunction, sensory or motor deficits of the lower extremities, which were caused by

the lumbosacral tumor, we recommend that resection surgery be considered first. When the patients' complaints were paresis or paralysis of the upper limbs, neck, and chest region, which were caused by the cervicothoracic intramedullary lipid syrinx, we suggest that syrinx aspiration should be performed. If the patient did not have these associated lumbosacral complaints, but only presented with the cervicothoracic symptoms or signs, we still suggest that the tumor should be resected and combined with the aspiration surgery. That is different from the reverse situation; the intramedullary lipid syrinx could be managed conservatively when there were no associated complaints, or they are quite tiny without a space-occupying effect. The reason is that the origin of intramedullary lipid droplets is from the ruptured dermoid cyst, so the tumor needs to be excised even without associated symptoms. Of course, if the cervicothoracic and lumbosacral complaints exist simultaneously, the tumor excision and lipid droplets aspiration should be performed in one stage, not in stages.

In deciding on the level of the cervicothoracic syrinx region to operate on, we chose the largest diameter segment on the MRI. After myelotomy, yellow or white lipid flowed out. Afterward, aspiration and repeated irrigation were performed. The septa always existed in the cavity, and it was challenging to aspirate the entire intramedullary lipid completely when the syrinx cavity was extended over a long area. Close follow-up and stage-by-stage surgery might be considered in this condition¹¹. The dermoid cyst was excised by midline myelotomy. Then evacuation of the contents, including pearly colored, white-yellowish pulaceous material mixed with hair, or even bone and calcified materials, were removed with special care. Then was followed by the excision of the capsule wall of the cyst, which was tightly adherent to the spinal cord but could not be separated completely. Leakage of tumor contents into the subdural region should be inhibited during the surgery to prevent possible postoperative aseptic chemical meningitis. Comparing to intramedullary ependymoma, the contents of the dermoid cyst are more complex, while the low-grade ependymoma could always reach to *en bloc* complete resection. With respect to intramedullary astrocytoma, it has ill-defined tumor margins with no or mild enhancement, partial resection is necessary to preserve neurological status with higher rates of recurrence. Neurophysiological monitoring was conducted to protect neurological functions. Attempt to complete resection may lead to permanent neurological

damage⁹. However, we still need to make an effort to resect the capsule wall under intraoperative monitoring to reduce the risk of recurrence¹⁰.

The limitation of this study is that this is a retrospective study, and due to its rare incidence of this disease, the majority of the earlier papers were individual case reports, whereas this study included a relatively larger number of patients. Furthermore, the exact etiology of ruptured spinal dermoid cysts is not clear and requires further research.

CONCLUSION

Ruptured spinal dermoid cyst into the syrinx cavity is a rare entity. The lipid droplets were always not at the center but eccentric on axial images. The lipid droplets were filled in the syringomyelia cavity, not only confined to the central canal, which may be caused by the developmental tumor. Based on the patients' chief complaints and associated neurological signs, we adopted different surgical strategies and underwent tumor resection and/or syrinx aspiration at one stage or in stages.

AUTHORS' DECLARATION

Conflicts of interest

No potential conflict of interest relevant to this article was reported.

Informed consent

This type of study does not require informed consent.

Author contributions

Conceptualization : AS, JW; Data curation : CC, RL, HG, BT, HW, MS, GG; Formal analysis : CC, BT, RL; Funding acquisition : AS, HG; Methodology : AS, JW, CC, BT; Project administration : AS, JW, CC; Visualization : AS, JW, CC, BT; Writing - original draft : CC, BT; Writing - review & editing : CC, BT, JW, AS

Data sharing

None

Preprint

None

ORCID

Cheng Cheng <https://orcid.org/0000-0003-4443-6407>
Rong Li <https://orcid.org/0000-0001-5525-9114>
Haihao Gao <https://orcid.org/0000-0002-4100-6463>
Benzhang Tao <https://orcid.org/0000-0002-0677-3296>
Hui Wang <https://orcid.org/0000-0002-1152-5860>
Mengchun Sun <https://orcid.org/0000-0003-4184-5395>
Gan Gao <https://orcid.org/0000-0001-7090-5583>
Jianzhen Wang <https://orcid.org/0000-0002-0584-4822>
Aijia Shang <https://orcid.org/0000-0003-0002-5331>

• Acknowledgements

We are grateful to the research grant from the Beijing Municipal Science & Technology Commission, PR China, No. Z171100001017140 (to AJS) and the Science Foundation of Military Medical Research and Clinical Research Foundation of PLA General Hospital in China, No. 2017FC-TSYS-2026.

References

1. Altay H, Kitiş O, Calli C, Yünter N : A spinal dermoid tumor that ruptured into the subarachnoidal space and syrinx cavity. **Diagn Interv Radiol** **12** : 171-173, 2006
2. Bishnoi I, Bishnoi S, Gahlawat N, Bhardwaj L, Duggal G, Singal G, et al. : Management of a rare case of intraventricular ruptured dermoid cyst and chemical meningitis. **Br J Neurosurg** **19** : 1-4, 2018
3. Calabrò F, Capellini C, Jinkins JR : Rupture of spinal dermoid tumors with spread of fatty droplets in the cerebrospinal fluid pathways. **Neuroradiology** **42** : 572-579, 2000
4. Falavigna A, Righesso O, Teles AR : Concomitant dermoid cysts of conus medullaris and cauda equina. **Arq Neuropsiquiatr** **67(2A)** : 293-296, 2009
5. Fernández-de Thomas RJ, Vicenty-Padilla JC, Sánchez-Jiménez JG, Labat EJ, Carballo-Cuello CM, De Jesús O, et al. : Obstructive hydrocephalus and chemical meningitis secondary to a ruptured spinal epidermoid cyst. **World Neurosurg** **132** : 173-176, 2019
6. Goyal A, Singh D, Singh AK, Gupta V, Sinha S : Spontaneous rupture of spinal dermoid cyst with disseminated lipid droplets in central canal and ventricles. **J Neurosurg Sci** **48** : 63-65, 2004
7. Karaaslan B, Ülkü G, Ucar M, Demirdağ TB, İnan A, Börcek AÖ : Intramedullary dermoid cyst infection mimicking holocord tumor: should radical resection be mandatory?-a case report. **Childs Nerv Syst** **32** : 2249-2253, 2016
8. Karadağ D, Karagülle AT, Erden A, Erden I : MR imaging of a ruptured intraspinal dermoid tumour with fat droplets in the central spinal canal. **Australas Radiol** **46** : 444-446, 2002
9. Kasliwal MK, Sinha S, Sharma BS, Garg A : Symptomatic central canal rupture heralding the presence of an asymptomatic conus dermoid. **J Neurooncol** **84** : 39-40, 2007
10. Kuyumcu G, Jhaveri M : Ruptured spinal dermoid cyst. **Can J Neurol Sci** **44** : 601-602, 2017
11. Liu T, Deng X, Xu Y, Xin Y : Spinal dermoid cyst with spontaneous rupture into the syrinx cavity alone. **World Neurosurg** **118** : e395-e404, 2018
12. Petit-Lacour MC, Lasjaunias P, Iffenecker C, Benoudiba F, Hadj Rabia M, Hurth M, et al. : Visibility of the central canal on MRI. **Neuroradiology** **42** : 756-761, 2000.
13. Samii M, Klekamp J : Surgical results of 100 intramedullary tumors in relation to accompanying syringomyelia. **Neurosurgery** **35** : 865-873; discussion 873, 1994
14. Sanaullah M, Mumtaz S, Memon AA, Hashim AS, Bashir S : Intramedullary dermoid cyst with relatively atypical symptoms: a case report and review of the literature. **J Med Case Rep** **7** : 104, 2013
15. Searce TA, Shaw CM, Bronstein AD, Swanson PD : Intraventricular fat from a ruptured sacral dermoid cyst: clinical, radiographic, and pathological correlation. Case report. **J Neurosurg** **78** : 666-668, 1993
16. Watanabe E, Tanaka K, Takeda N, Takayasu H, Yokota K, Watanabe M : Surgical technique to prevent spillage of cyst fluid during operation for cystic ovarian tumors. **Pediatr Surg Int** **29** : 645-649, 2013